

Bond University
Research Repository



Vestibular influence on cranio-cervical pain

A case report

Gargano, Frank; Hing, Wayne; Cross, Caroline

Published in:
New Zealand Journal of Physiotherapy

Published: 01/07/2012

Document Version:
Publisher's PDF, also known as Version of record

[Link to publication in Bond University research repository.](#)

Recommended citation(APA):

Gargano, F., Hing, W., & Cross, C. (2012). Vestibular influence on cranio-cervical pain: A case report. *New Zealand Journal of Physiotherapy*, 40(2), 51-58.

General rights

Copyright and moral rights for the publications made accessible in the public portal are retained by the authors and/or other copyright owners and it is a condition of accessing publications that users recognise and abide by the legal requirements associated with these rights.

For more information, or if you believe that this document breaches copyright, please contact the Bond University research repository coordinator.

Vestibular influence on cranio-cervical pain: a case report

Frank Gargano (DPT)

Physical Therapist Rehabilitex Incorporated, Solon, Ohio, United States of America

Wayne Hing (PhD)

Professor of Physiotherapy, ¹Bond University, Queensland, Australia; ²AUT University, Auckland, New Zealand

Caroline Cross (PGDip Health Science)

AUT University, Auckland, New Zealand

ABSTRACT

This case report describes a 39 year old woman with a 10 month history of right-sided temporal headaches. In addition, she experienced a 'wobble' feeling when rolling toward her right side and reported suboccipital pain, tinnitus and a mild visual disturbance. Objective assessment revealed she had a positional upbeat clockwise torsional nystagmus, that is, a positive Dix-Hallpike test for benign paroxysmal positional vertigo. Furthermore, manual assessment revealed right upper cervical joint dysfunction. She was treated with a four stage canalith repositioning manoeuvre for the vestibular system which abolished her 'wobble' symptom. Subsequently, manual therapy techniques were applied to the cervical joints and suboccipital musculature resulting in the relief of the patient's headache, suboccipital pain and mild visual disturbance. This case report discusses the importance of considering the peripheral vestibular system in patients who present with headache and dizziness. The purpose of this case study is to highlight that the vestibular system along with cervicogenic originating symptoms of headache and visual symptoms should all be considered and assessed accordingly.

Gargano F, Hing W and Cross C (2012): Vestibular influence on cranio-cervical pain: a case report. New Zealand Journal of Physiotherapy 40(2) 51-58.

Key words: Dizziness, BPPV, Headache, SNAGs

INTRODUCTION

Dizziness is a term that encompasses four subtypes. Vertigo describes a sensation of the environment spinning, presyncope depicts a feeling of impending fainting, disequilibrium refers to a feeling of loss of balance in standing and non-specific dizziness is considered a vague light headed or heavy headedness that cannot be described with the other three terms (Eaton and Roland 2003, Vidal and Huijbregts 2005). The exact prevalence of dizziness in the general population is not known; however, a community based study of 4869 German adults between the ages of 18-79 years estimates that 29.3% of the population suffers a moderate to severe episode of dizziness in their lifetime (Neuhauser et al 2008). The aetiology of dizziness is varied and can arise from numerous body systems, presenting a diagnostic challenge to clinicians (Huijbregts and Vidal 2004, Kristjansson and Treleaven 2009). Medical conditions such as anxiety, low blood pressure, endocrine and cardiac disease, hyperventilation and drug interaction can cause dizziness and clinicians should be aware of these. In their practice, clinicians need to have the ability to identify and differentiate between several types of dizziness, including dizziness that is cervicogenic in origin, that which is related to vestibular disorders, or due to vertebrobasilar insufficiency (VBI), to determine whether referral or treatment is warranted.

Cervicogenic dizziness is characterised by imbalance or disequilibrium, which is commonly associated with neck pain, stiffness or headache (Wrisley et al 2000). The exact aetiology of cervicogenic dizziness is not well understood but may occur from a whiplash-associated disorder (WAD) that results after a flexion/extension injury. It is estimated that 0.1% of the population annually will experience a WAD (Spitzer et al 1995).

Pain and headache are often immediate whereas dizziness or disequilibrium are likely to manifest latently in 20-58% of individuals diagnosed with a WAD (Oostendorp et al 1999, Rubin 1973).

Vestibular disorders can arise from both central and peripheral structures. Peripheral vestibular disorders, predominantly benign paroxysmal positional vertigo (BPPV), account for a large proportion of dizziness cases (Huijbregts and Vidal 2004, Rashad 2010). According to epidemiological research by Neuhauser et al (2008) vestibular disorders affect 25.2% of those who experience moderate to severe dizziness over a lifetime. Of these, 2.4% suffer from BPPV (Bhattacharyya et al 2008, von Brevern et al 2007). The term BPPV relates to otoconia (microscopic calcium carbonate crystals) that are normally present in the utricle of the inner ear being displaced into the semi-circular canals (Barany 1921). The presence of these crystals in the semi-circular canals causes the canal to abnormally sense gravity. This creates an asymmetry of vestibular input to the central nervous system, resulting in vertigo. BPPV can arise idiopathically with ageing or due to trauma, inflammation or degeneration of the inner ear (Huijbregts and Vidal 2004).

Symptoms of dizziness due to ischemia of the vertebrobasilar arteries may include any one of the four dizziness subtypes (Thiel and Rix 2005). Epidemiological research from 529 asymptomatic Russians between the ages of 36-84 years estimates a prevalence of 2.1% of the population with \geq 50% stenosis in a vertebral artery (Harer and Gusev 1996). Furthermore, it is estimated that 52% of patients presenting with isolated dizziness of no known origin have anomalies in their posterior cerebral circulation (Cloutier and Saliba 2008).

VBI dizziness may occur following trauma but commonly has no known causative event. Although dizziness can occur in isolation, it is often associated with other motor or sensory disturbances (Cloutier and Saliba 2008). The aetiology of VBI symptoms can arise from both internal vascular compression such as atherosclerosis, a thromboembolus or arterial dissection as well as from external factors such as mechanical compression from hypertonic musculature, osteophytes, cervical fracture or dislocation and head posture (Huijbregts and Vidal 2004).

Physiotherapists need to combine a thorough subjective and objective assessment to determine the cause of dizziness in patients. Specific questioning and assessment of the positions that cause the onset of dizziness, the latency and duration of dizziness symptoms, the fatigability of a dizzy episode and observing for the presence of nystagmus can aid differential diagnosis. Furthermore, in the absence of trauma, dizziness of VBI origin should be considered as vascular pathology, which is the most common risk factor for VBI dizziness (Cloutier and Saliba 2008).

Huijbregts and Vidal (2004) have clearly summarised the factors that will assist the differential diagnosis between cervicogenic dizziness, BPPV and VBI dizziness. The onset of both cervicogenic dizziness and dizziness due to BPPV are due to alterations in head position whereas VBI dizziness arises from a sustained head position rather than a change. A change in head position will bring about immediate symptoms in cervicogenic dizziness; however, with BPPV a short latency of 1-5 seconds will be experienced while dizziness of VBI origin has a long latency of 55 (SD 18) seconds. If the head is maintained in the initially provocative position, cervicogenic and BPPV dizziness will fatigue whereas VBI dizziness will increase. Nystagmus due to VBI is in a vertical direction but with BPPV, the nystagmus is torsional or horizontal depending on the involved canal.

There are several objective measures to aid physiotherapists further in their differential diagnosis of these three forms of dizziness (Vidal and Huijbregts 2005). Active and passive range of motion testing of the cervical spine may demonstrate musculoskeletal dysfunction and elicit headache and/or dizziness symptoms with cervicogenic dizziness. The neck torsion test can differentiate between cervicogenic dizziness and vestibular dizziness. With this test the head is held stationary, which limits stimulation to the peripheral vestibular system, while the patient rotates the trunk, thus implicating cervicogenic dizziness if positive. There is, however, no gold standard test to confirm cervicogenic dizziness and more often this is a diagnosis of exclusion when there is a history of trauma and the reported dizziness correlates with neck pain (Huijbregts and Vidal 2004). Although debate exists in the literature regarding the value of vertebral artery testing due to the low sensitivity of available tests (Thiel and Rix 2005), the sustained neck rotation test for VBI may elicit dizziness due to vascular compromise. The Dix-Hallpike manoeuvre used to assess for BPPV can distinguish between cervicogenic dizziness and BPPV.

The vestibular system integrates information from the proprioceptors of the eyes and neck to determine the position of the head in space (Armstrong et al 2008) and the vestibulocollic reflex (VCR) can be considered the conduit for the transformation of vestibular signals into cervical movements. Wilson et al (1995) describe the neural circuitry for the VCR as a three-neuron arc that consists of primary vestibular afferents,

vestibulocollic neurons, and cervical motor neurons. This establishes a direct and indirect neurological pathway between the peripheral vestibular sensory receptors and cervical motor neurons, which needs consideration when evaluating dizziness and dysfunction in the cranio-cervical region. The correlation about treatment between the vestibular system and the cervical spine is not well documented; few authors have considered the vestibular and cervical systems together in their treatment models (Kristjansson and Treleaven 2009, Schenk et al 2006).

The purpose of this case study is to demonstrate the need to assess and when appropriate, sequentially treat both the vestibular and cervical region to reduce dizziness and pain when a dual pathology is present. Full informed consent was gained from the patient concerned in this report.

CASE PRESENTATION

History

A 39 year old female physiotherapist (PB) attending a course pertaining to manual therapy reported that she was experiencing right sided temporal headaches, suboccipital pain and a mild visual disturbance that began insidiously approximately 10 months prior. Upon further questioning she also described a 'wobble' feeling when rolling toward her right side which would last 20-30 seconds then diminish. She reported the 'wobble' symptom arose around the same time as the headache and suboccipital pain. PB was otherwise healthy besides suffering from asthma.

Relevant past medical history revealed PB was involved in three rear-end collision motor vehicle accidents. The first accident was 15 years earlier and the second and third occurred two weeks apart a year prior to her presentation. She reported recovering from these accidents without residual problems. PB also reported she had tinnitus that had been present for more than a year and that she was not taking any medications and had not sought any prior treatment.

Objective Assessment

Based on her presenting symptoms, the Dix-Hallpike manoeuvre (Figures 1A and 1B) was the only assessment performed on Day One. This was done before any joint or muscle assessment to rule in or rule out the presence of BPPV and reduce the risk of symptom provocation from multi-system assessment. The Dix-Hallpike manoeuvre is considered the test of choice when diagnosing BPPV (Bhattacharyya et al 2008). The validity of this test has been compared to a side lying test and reported to have a sensitivity of 79% and a specificity of 75% (Halker et al 2008). It is a reliable test in the diagnosis of BPPV when a paroxysmal positional nystagmus is produced (Norre 1995). The left ear down Dix-Hallpike manoeuvre was performed first and produced no symptoms or nystagmus. In the right ear down position (Figure 1B) the patient demonstrated an upbeat torsional nystagmus and her wobble symptoms were reproduced for approximately 10 seconds. On bringing the patient back to an upright position the nystagmus reversed (downbeat torsional) indicating a posterior canal BPPV (Gianoli and Smullen 2008).

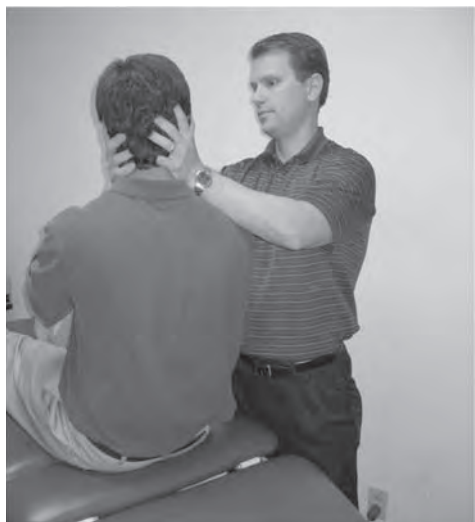
A cervical assessment was performed on Day Two. In restful sitting, PB was observed to assume a right laterally flexed cervical posture. Prior to assessing the cervical joints, the sustained active rotation test for VBI was performed in sitting

Figure 1. Dix-Hallpike manoeuvre 1A-1B. Canalith repositioning manoeuvre 1A-1E. Figures include images of the semi-circular canals to indicate the force of gravity within the canals during the canalith repositioning manoeuvre.

G = gravitational force.

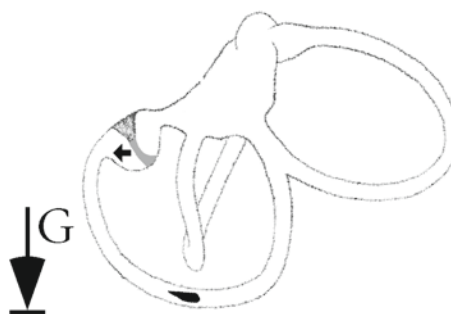
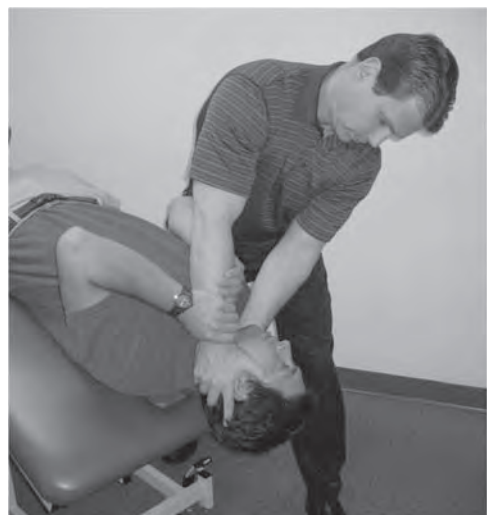(For purposes of publication a model has been utilised for the following figures)

A)



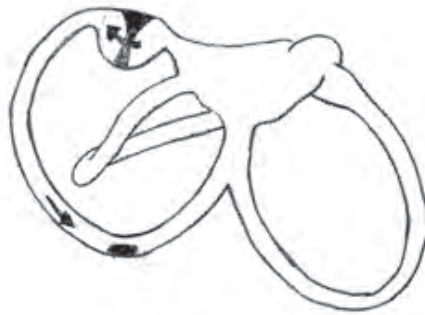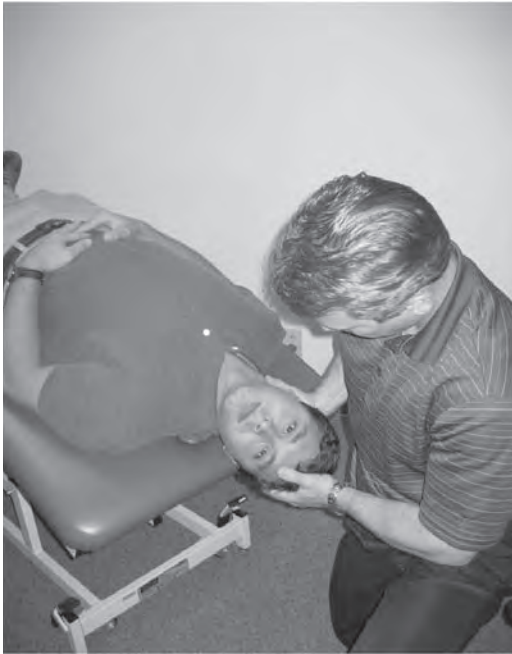45° passive right horizontal rotation in sitting

B)



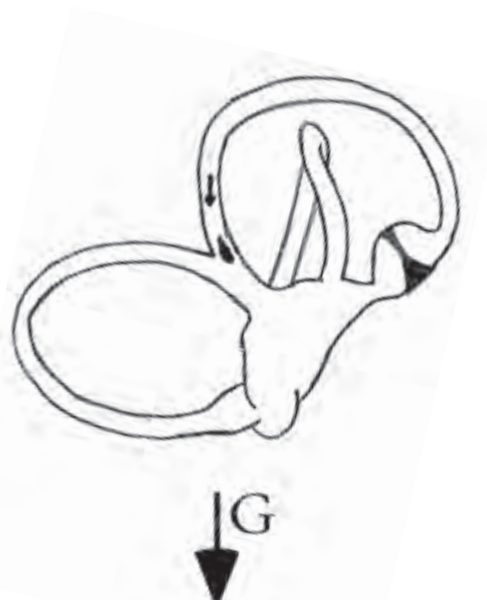
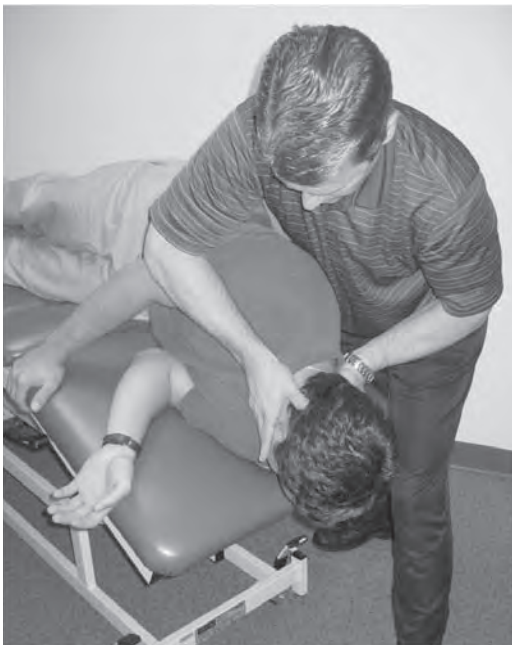Patient quickly assisted into supine with 30° of extension

c)



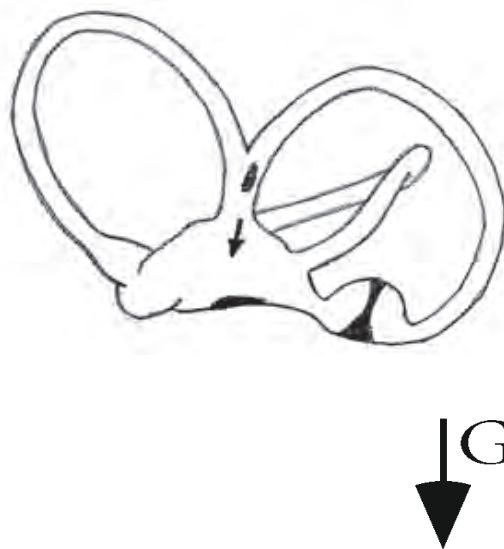
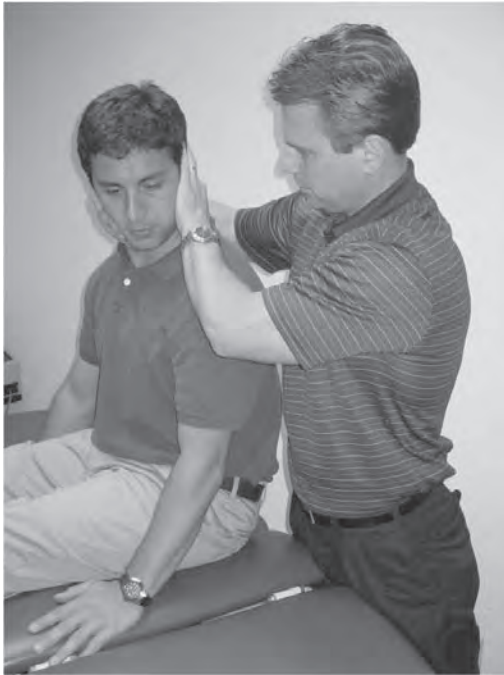90° passive left rotation ending with 45° rotation with 30° extension maintained

d)



Patient actively rolls onto their left side as the clinician passively controls the head ensuring the head is slightly flexed and the nose pointing down in relation to gravity

E)



Return to sitting maintaining left rotation and flexion

in both left and right directions. PB did not experience any of her wobble or tinnitus symptoms; however, on turning to the right she had a painful restriction and noted an alteration to her peripheral vision. These symptoms reduced when the head was held at the end of the available rotation for more than 10 seconds. The supine flexion-rotation test was used to assess upper cervical passive range of motion. The supine flexion-rotation test was validated for determining the presence of a C1-C2 rotation restriction in patients with a cervicogenic headache and has a sensitivity of 91% and specificity of 90% ($p < 0.001$) with an overall diagnostic accuracy of 91% ($p < 0.001$) (Ogince et al 2007). PB demonstrated approximately 40° of rotation to the left but a unilateral painful restriction of approximately 20° on the right. The C2-C3 segment was also found to be hypomobile through manual palpation of combined physiological right rotation, right side bending and extension. This assessment technique of intersegmental motion was shown to have a sensitivity of 98% and a specificity of 91% with a positive likelihood ratio of 10.9 (Humphreys et al 2004). Palpation of the suboccipital region demonstrated increased muscle tone on the right compared to the left.

Clinical Impression

A primary diagnosis of BPPV was made due to the positioning nature of PB's 'wobble' symptoms, the brief latency of these symptoms and the positive Dix-Hallpike test demonstrating a positional upbeat clockwise torsional nystagmus. A secondary diagnosis of cervicogenic headache was made due to the unilateral nature of her headache and suboccipital pain and the cervical assessment demonstrating right sided joint restriction and altered muscle tone. These symptoms meet the Cervicogenic Headache International Study Group (CHISG) diagnostic criteria for cervicogenic headache (Sjaastad et al 1998).

Intervention

Day One - Vestibular Intervention

The primary diagnosis on Day One of BPPV prompted using the canalith repositioning manoeuvre (CRM) described by Epley (1992) to reposition the otoconia suspected to be present in the right posterior semi-circular canal (refer to Figures 1A-1E). Randomised controlled trials using the CRM were recently reviewed by the Cochrane group and concluded that CRM is an effective treatment for BPPV (Hillier and McDonnell 2011). The right ear down Dix-Hallpike manoeuvre was repeated to establish it was negative, that is, no torsional nystagmus or 'wobble' feeling were present. Although negative, the CRM was repeated to ensure that all of the otoconia particles were cleared from the posterior canal. There is some controversy in the literature regarding the need to have the patient sit in an upright position for 24-48 hours following CRM (Cohen 1999, Nuti and Passali 2000). The upright protocol relates to the use of gravity to maintain the otoconia in the utricle where it can be reabsorbed. In this situation PB was required to be upright for the next day and teach a course, thus she was instructed to sleep as she normally would. The decision was made that if the symptoms generated by BPPV returned, then repositioning treatment could be repeated.

Day Two - Upper Cervical Intervention

On Day Two PB had no further 'wobble' symptoms when rolling to her right; however, the right temporal headache, suboccipital pain, tinnitus and blurred right peripheral vision were present. To treat the cervicogenic headache, trigger point therapy was performed on the hypertonic suboccipital muscles in sitting. Pressure was maintained for 15 seconds and repeated twice until the perception of pain eased and muscle tone was reduced in each trigger point. Travell and Simons (1983) describe this type of tone reduction as an ischemic compression.

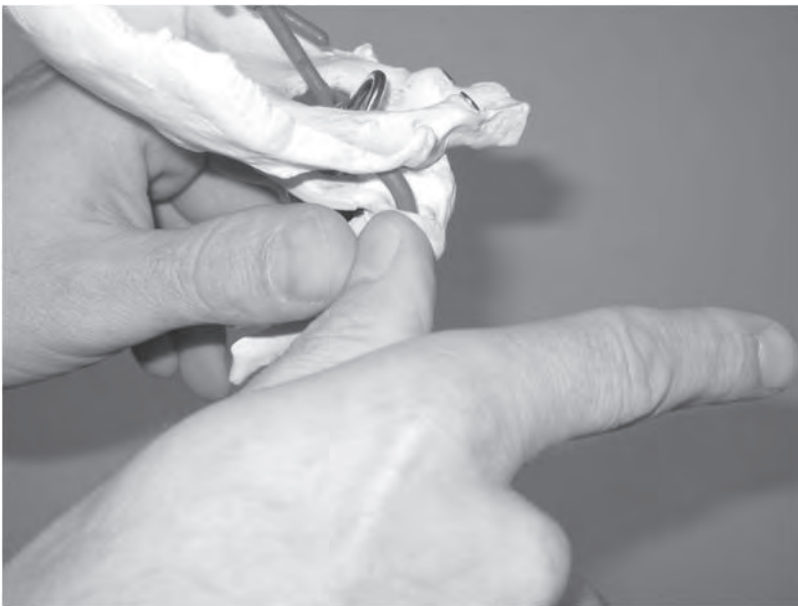Management of the upper cervical joint restriction was addressed by the application of specific Mobilisations with Movements (MWM's) termed sustained natural apophyseal glides (SNAGS) as described by Mulligan (1999) (Figures 2A-C). MWMs to the cervical spine have been shown to be beneficial in the treatment of cervicogenic headaches (Hall et al 2007). The C1-C2 and C2-C3 segments were treated with the aim of restoring segmental mobility and this procedure was repeated for six repetitions according to Mulligan recommendations (Mulligan 1999).

Outcome

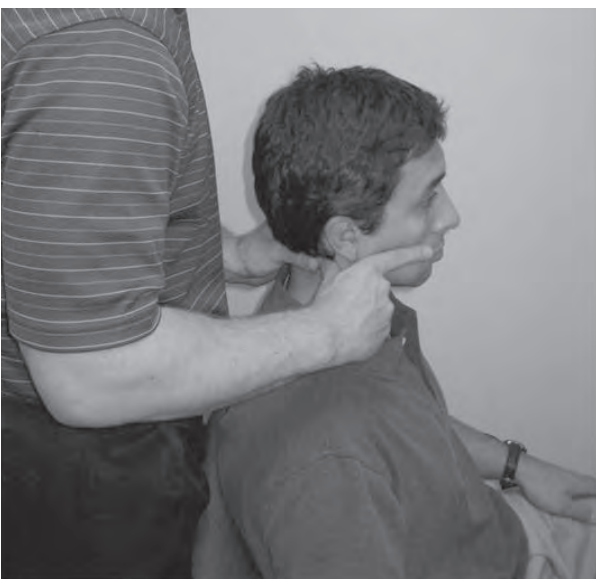Following manual therapy treatment on Day Two PB stated that it was the best that she had felt in a long time. She immediately reported that her right side temporal headache, suboccipital pain and blurred vision had ceased, but her tinnitus was still present. Several hours later, reassessment of the supine flexion-rotation test showed C1-C2 segmental rotation to be equal with 40° bilaterally. Combined physiological rotation (C2-C3), side bending and extension was equal bilaterally and pain free on

Figure 2. SNAG finger placement (A), start position (B) and end position (C)

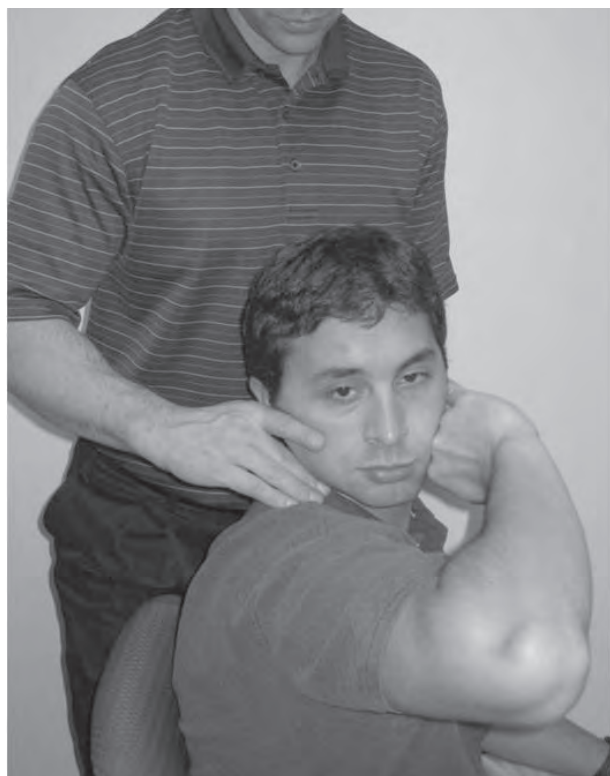A)



B)



C)



the right and she had normal muscle tone in the suboccipital region on palpation. No formal follow-up was performed. However, incidental meetings during subsequent physiotherapy courses at nine weeks, three years and five years established that PB had no further 'wobble' sensation when rolling to her right or had experienced any further temporal headaches, suboccipital pain or visual disturbance; however, her tinnitus remained unchanged.

DISCUSSION

The purpose of this case report is to demonstrate a need to evaluate all possible sources of a patient's complaints when determining the cause of their dizziness. This case report identifies an undiagnosed primary vestibular dysfunction in conjunction with cervicogenic headache. In similar cases clinicians may initially treat the patient's cervical spine, which could potentially reduce a patient's pain; however, this would not necessarily address dizziness or a 'wobble' sensation, as in the case of PB. Due to the neurological integration that occurs between the vestibular system and cervical proprioceptors, altered vestibular afferent signals may affect cervical spine proprioception. In turn, localised joint or muscle dysfunction in the cervical spine may not resolve after specific treatment to the cervical region if there is an underlying peripheral vestibular disorder. Additionally, it is known that the cervical spine proprioceptors have a direct influence on oculomotor control and, when dysfunctional, can create visual disturbances (Carlsson and Rosenhall 1990, Gimse et al 1996). This may have been the mechanism for PB's residual visual disturbance following CRM and why manual correction of the cervical dysfunction resolved this symptom (Carlsson and Rosenhall 1990). Therefore, it is theorised that in order to obtain a lasting clinical effect, it is important to identify and correct peripheral vestibular dysfunction, in particular BPPV, before initiating treatment to the cervical spine.

The patient's complaint of the 'wobble' sensation did not fit the typical BPPV presentation of experiencing vertigo. There is, however, a subset of the population that has symptomatic BPPV without the complaint of vertigo (spinning), sometimes referred to as 'BPPV Oops' (Oas 2001, Oghalai et al 2000). The 'V' in BPPV has been purposely left out owing to the absence of the familiar spinning sensation which is typically used to make the clinical decision to perform a Dix-Hallpike manoeuvre.

There are several limitations to this report. A major factor is that VBI testing and active range of cervical motion were not evaluated on initial assessment. Although the 'wobble' symptom reported by PB indicated that BPPV was the most likely diagnosis, current clinical guidelines recommend VBI testing (Magarey et al 2004). In particular, VBI testing should be performed in the presence of other motor or sensory disturbance such as tinnitus or visual disturbances as was present with PB. Standard clinical practice also involves active range of motion testing. Had this been performed, this would have added impetus to our differential diagnosis of BPPV as opposed to cervicogenic dizziness or dizziness due to VBI being the cause of PB's wobble sensation. In addition, objective assessments such as a visual analogue scale (VAS) for pain quantification, cervical proprioception and functional questionnaires should have been implemented to complete the differential diagnosis and clinical picture.

This clinical scenario does not represent what is typically seen in clinical practice and was an incidental finding on a physiotherapy course. Neuhauser et al (2008), in their dizziness prevalence study, established that a large proportion of the community who experience dizziness do not seek medical care. The incidental finding with PB perhaps indicates a common scenario in the community and should prompt therapists to carefully question patients on dizziness symptoms when treating cervical complaints.

In conclusion this clinical perspective suggests that a peripheral vestibular dysfunction should be considered in the differential diagnosis of patients with cervicogenic headache when dizziness is also present.

KEY POINTS

- The vestibular system should be considered in patients who present with dizziness and headache due to the integrated neurological pathways between vestibular, oculomotor and cervical motor neurons.
- Treatment of a dual pathology of dizziness and headache requires careful differential diagnosis and a sequential approach with applied techniques.
- The canalith repositioning manoeuvre is a useful technique to treat peripheral vestibular dysfunction.

ADDRESS FOR CORRESPONDENCE

Professor Wayne Hing, Bond University, Gold Coast 4226, Queensland, Australia. Phone 0061 (7) 559-53055. Email whing@bond.edu.au

REFERENCES

- Armstrong B, McNair P and Taylor D (2008): Head and neck position sense. *Sports Medicine* 38: 101-117.
- Barany R (1921): Diagnose von krankheitserscheinungen im bereich des otolithenapparatus. *Acta Oto-laryngologica* 2: 434-437.
- Bhattacharyya N, Baugh RF, Orvidas L, Barrs D, Bronston LJ, Cass S, Chalian AA, Desmond AL, Earll JM, Fife TD, Fuller DC, Judge JO, Mann NR, Rosenfeld RM, Schuring LT, Steiner RWP, Whitney SL and Haidari J (2008): Clinical practice guideline: benign paroxysmal positional vertigo. *Otolaryngology - Head and Neck Surgery* 139: S47-81.
- Carlsson J and Rosenhall U (1990): Oculomotor disturbances in patients with tension headache treated with acupuncture and physiotherapy. *Cephalgia* 10: 122-129.
- Cloutier JF and Saliba I (2008): Isolated vertigo and dizziness of vascular origin. *Journal of Otolaryngology - Head and Neck Surgery* 37: 331-339.
- Cohen HJ (1999): Efficacy of treatments for posterior canal benign paroxysmal positional vertigo. *Laryngoscope* 109: 584-590.
- Eaton DA and Roland PS (2003): Dizziness in the older adult, Part 2. Treatments for causes of the four most common symptoms. *Geriatrics* 58: 46, 49-52.
- Epley JM (1992): The canalith repositioning procedure: for treatment of benign paroxysmal positional vertigo. *Otolaryngology - Head and Neck Surgery* 107: 399-404.
- Gianoli GJ and Smullen JL (2008): Performing the physical examination: positioning tests. In Goebel JA (Ed.): *Practical Management of the Dizzy Patient* (2 ed.) Vol 2. Philadelphia: Wolters Kluwer, pp. 85-97.
- Gimse R, Tjell C, Bjørgen I and Saunte C (1996): Disturbed eye movements after whiplash due to injuries to the posture control system. *Journal of Clinical and Experimental Neuropsychology* 18: 178-186.
- Halker RB, Barrs DM, Wellik KE, Wingerchuk DM and Demaerschalk BM (2008): Establishing a diagnosis of benign paroxysmal positional vertigo through the dix-hallpike and side-lying maneuvers: a critically appraised topic. *Neurologist* 14: 201-204.

- Hall T, Chan HT, Christensen L, Odenthal B, Wells C and Robinson K (2007): Efficacy of a C1-C2 self-sustained natural apophyseal glide (SNAG) in the management of cervicogenic headache. *Journal of Orthopaedic and Sports Physical Therapy* 37: 100-107.
- Harer C and Gusev EI (1996): Asymptomatic cervical artery stenoses in Moscow. *Acta Neurologica Scandinavica* 93: 286-290.
- Hillier SL and McDonnell M (2011): Vestibular rehabilitation for unilateral peripheral vestibular dysfunction. *Cochrane Database of Systematic Reviews (Online)* 2: CD005397. DOI: 10.1002/14651858.CD005397.pub3
- Huijbregts P and Vidal P (2004): Dizziness in orthopaedic physical therapy practice: classification and pathophysiology. *Journal of Manual and Manipulative Therapy* 12: 199-214.
- Humphreys BK, Delahaye M and Peterson CK (2004): An investigation into the validity of cervical spine motion palpation using subjects with congenital block vertebrae as a 'gold standard'. *BMC Musculoskeletal Disorders* 5: 19.
- Kristjansson E and Treleaven J (2009): Sensorimotor function and dizziness in neck pain: implications for assessment and management. *Journal of Orthopaedic and Sports Physical Therapy* 39: 364-377.
- Magarey ME, Rebbeck T, Coughlan B, Grimmer K, Rivett DA and Refshauge K (2004): Pre-manipulative testing of the cervical spine review, revision and new clinical guidelines. *Manual Therapy* 9: 95-108.
- Mulligan B (1999): *Manual therapy: NAGS, SNAGS, MWMS etc.* (4th ed.). Wellington: Plane View Services Ltd., pp. 16-20.
- Neuhauser HK, Radtke A, von Brevern M, Lezius F, Feldmann M and Lempert T (2008): Burden of dizziness and vertigo in the community. *Archives of Internal Medicine* 168: 2118-2124.
- Norre ME (1995): Reliability of examination data in the diagnosis of benign paroxysmal positional vertigo. *American Journal of Otolaryngology* 16: 806-810.
- Nuti D, Nuti C and Passali D (2000): Treatment of benign paroxysmal positional vertigo: no need for postmaneuver restrictions. *Otolaryngology - Head and Neck Surgery* 122: 440-444.
- Oas JG (2001): Benign paroxysmal positional vertigo: a clinician's perspective. *Annals of the New York Academy of Sciences* 942: 201-209.
- Oghalai JS, Manolidis S, Barth JL, Stewart MG and Jenkins HA (2000): Unrecognized benign paroxysmal positional vertigo in elderly patients. *Otolaryngology - Head and Neck Surgery* 122: 630-634.
- Ogince M, Hall T, Robinson K and Blackmore AM (2007): The diagnostic validity of the flexion-rotation test in C1/2-related cervicogenic headache. *Manual Therapy* 12: 256-262.
- Oostendorp RAB, van Eupen AAJM, van Erp JMM and Elvers HWH (1999): Dizziness following whiplash injury: A neuro-otological study in manual therapy practice and therapeutic implication. *Journal of Manual and Manipulative Therapy* 7: 123-130.
- Rashad UM (2010): Patients with benign paroxysmal positional vertigo and cervical spine problems: is Epley's manoeuvre contraindicated, and is a proposed new manoeuvre effective and safer? *Journal of Laryngology and Otology* 124: 1167-1171.
- Rubin W (1973): Whiplash with vestibular involvement. *Archives of Otolaryngology* 97: 85-87.
- Schenk R, Coons L, Bennett S and Huijbregts P (2006): Cervicogenic dizziness: A case report illustrating orthopaedic manual and vestibular physical therapy comanagement. *Journal of Manual and Manipulative Therapy* 14: E56-E68.
- Sjaastad O, Fredriksen TA and Pfaffenrath V (1998): Cervicogenic headache: diagnostic criteria. The Cervicogenic Headache International Study Group. *Headache* 38: 442-445.
- Spitzer WO, Skovron ML, Salmi LR, Cassidy JD, Duranceau J, Suissa S and Zeiss E (1995): Scientific monograph of the Quebec Task Force on Whiplash-Associated Disorders: redefining "whiplash" and its management. *Spine* 20: 1S-73S.
- Thiel H and Rix G (2005): Is it time to stop functional pre-manipulation testing of the cervical spine? *Manual Therapy* 10: 154-158.
- Travell JG and Simons DG (1983): *Myofascial pain and dysfunction: the Trigger Point Manual*. Baltimore: Williams and Wilkins, pp. 27.
- Vidal P and Huijbregts P (2005): Dizziness in orthopaedic physical therapy practice: history and physical examination. *Journal of Manual and Manipulative Therapy* 13: 221-250.
- von Brevern M, Radtke A, Lezius F, Feldmann M, Ziese T, Lempert T and Neuhauser H (2007): Epidemiology of benign paroxysmal positional vertigo: a population based study. *Journal of Neurology, Neurosurgery and Psychiatry* 78: 710-715.
- Wilson VJ, Boyle R, Fukushima K, Rose PK, Shinoda Y, Sugiuchi Y and Uchino Y (1995): The vestibulocollic reflex. *Journal of Vestibular Research* 5: 147-170.
- Wisley DM, Sparto PJ, Whitney SL and Furman JM (2000): Cervicogenic dizziness: a review of diagnosis and treatment. *Journal of Orthopaedic and Sports Physical Therapy* 30: 755-766.