



THE UNIVERSITY *of* EDINBURGH

Edinburgh Research Explorer

Tokyo Guidelines 2018 diagnostic criteria and severity grading of acute cholecystitis (with videos)

Citation for published version:

Yokoe, M, Hata, J, Takada, T, Strasberg, SM, Asbun, HJ, Wakabayashi, G, Kosaka, K, Endo, I, Deziel, DJ, Miura, F, Okamoto, K, Hwang, T-L, Huang, WS-W, Ker, C-G, Chen, M-F, Han, H-S, Yoon, Y-S, Choi, I-S, Yoon, D-S, Noguchi, Y, Shikata, S, Ukai, T, Higuchi, R, Gabata, T, Mori, Y, Iwashita, Y, Hibi, T, Jagannath, P, Jonas, E, Liau, K-H, Dervenis, C, Gouma, DJ, Cherqui, D, Belli, G, Garden, OJ, Giménez, ME, de Santibañes, E, Suzuki, K, Umezawa, A, Supe, AN, Pitt, HA, Singh, H, Chan, ACW, Lau, WY, Teoh, AYB, Honda, G, Sugioka, A, Asai, K, Gomi, H, Itoi, T, Kiriya, S, Yoshida, M, Mayumi, T, Matsumura, N, Tokumura, H, Kitano, S, Hirata, K, Inui, K, Sumiyama, Y & Yamamoto, M 2018, 'Tokyo Guidelines 2018 diagnostic criteria and severity grading of acute cholecystitis (with videos)' *Journal of Hepato-Biliary-Pancreatic Sciences*, vol. 25, no. 1. DOI: 10.1002/jhbp.515

Digital Object Identifier (DOI):

[10.1002/jhbp.515](https://doi.org/10.1002/jhbp.515)

Link:

[Link to publication record in Edinburgh Research Explorer](#)

Document Version:

Peer reviewed version

Published In:

Journal of Hepato-Biliary-Pancreatic Sciences

General rights

Copyright for the publications made accessible via the Edinburgh Research Explorer is retained by the author(s) and / or other copyright owners and it is a condition of accessing these publications that users recognise and abide by the legal requirements associated with these rights.

Take down policy

The University of Edinburgh has made every reasonable effort to ensure that Edinburgh Research Explorer content complies with UK legislation. If you believe that the public display of this file breaches copyright please contact openaccess@ed.ac.uk providing details, and we will remove access to the work immediately and investigate your claim.



Guideline

Tokyo Guidelines 2018 diagnostic criteria and severity grading of acute cholecystitis (with videos)

Masamichi Yokoe, Jiro Hata, Tadahiro Takada, Steven M. Strasberg, Horacio J. Asbun, Go Wakabayashi, Kazuto Kosaka, Itaru Endo, Daniel J. Deziel, Fumihiko Miura, Kohji Okamoto, Tsann-Long Hwang, Wayne Shih-Wei Huang, Chen-Guo Ker, Miin-Fu Chen, Ho-Seong Han, Yoo-Seok Yoon, In-Seok Choi, Dong-Sup Yoon, Yoshinori Noguchi, Satoru Shikata, Tomohiko Ukai, Ryota Higuchi, Toshifumi Gabata, Yasuhisa Mori, Yukio Iwashita, Taizo Hibi, Palepu Jagannath, Eduard Jonas, Kui-Hin Liao, Christos Dervenis, Dirk Joan Gouma, Daniel Cherqui, Giulio Belli, O. James Garden, Mariano Eduardo Giménez, Eduardo de Santibañes, Kenji Suzuki, Akiko Umezawa, Avinash Nivritti Supe, Henry A. Pitt, Harjit Singh, Angus C.W. Chan, Wan Yee Lau, Anthony Yuen Bun Teoh, Goro Honda, Atsushi Sugioka, Koji Asai, Harumi Gomi, Takao Itoi, Seiki Kiriyaama, Masahiro Yoshida, Toshihiko Mayumi, Naoki Matsumura, Hiromi Tokumura, Seigo Kitano, Koichi Hirata, Kazuo Inui, Yoshinobu Sumiyama, Masakazu Yamamoto

The author's affiliations are listed in the Appendix.

Corresponding author:

Tadahiro Takada, M.D., Ph.D.

Department of Surgery, Teikyo University School of Medicine, 2-11-1 Kaga, Itabashi-ku, Tokyo 173-8605, Japan

Email: t-takada@jshbps.jp

Key word: Cholecystitis, acute / Diagnosis/ Diagnostic Imaging/ Severity of Illness Index / Guidelines

Abstract

TG13 Tokyo guidelines for acute cholangitis and cholecystitis were globally disseminated and various clinical researches about the management of acute cholecystitis were reported by lots of researchers and clinicians from all over the world. The 1st edition of Tokyo Guidelines 2007 (TG07) was revised in 2013. According to that revision, the TG13 diagnostic criteria of acute cholecystitis provided better specificity and higher diagnostic accuracy. Thorough our literature search about diagnostic criteria for acute cholecystitis, new and strong evidence that had been released from 2013 to 2017 was not found with

This article has been accepted for publication and undergone full peer review but has not been through the copyediting, typesetting, pagination and proofreading process, which may lead to differences between this version and the Version of Record. Please cite this article as doi: 10.1002/jhbp.515

This article is protected by copyright. All rights reserved.

serious and important issues about using TG13 diagnostic criteria of acute cholecystitis. On the other hand, the TG13 severity grading for acute cholecystitis have been validated in numerous studies. As a result of review, the TG13 severity grading for acute cholecystitis was significantly associated with parameters including 30-day overall mortality, length of hospital stay, conversion rates to open surgery, and medical costs. In terms of severity assessment, breakthrough and intensive literature for revising severity grading was not reported. Consequently, TG13 diagnostic criteria and severity grading were judged from numerous validation studies as useful indicators in clinical practice and adopted as TG18/TG13 diagnostic criteria and severity grading of acute cholecystitis without any modification.

Introduction

The TG13 diagnostic criteria and severity grading of acute cholecystitis [1] have become widely adopted in recent years, being used not only in clinical practice but also in numerous research studies on this disease. These diagnostic criteria and severity grading of acute cholecystitis constitute guidelines produced on the basis of the consensus achieved during discussions by global experts at the Tokyo Consensus Meeting held in 2007, and the first version was published as Tokyo Guidelines 2007(TG07) [2]. Based on studies that have found the lifespan of guidelines to be around five years [3], the Tokyo Guidelines Revision Committee revised the TG07 guidelines in 2013. Validation of the TG07 diagnostic criteria and severity grading of acute cholecystitis had identified two issues with the diagnostic criteria in particular: the use of two categories for deciding a definitive diagnosis led to ambiguity in clinical practice, and criteria for suspected diagnosis were not specified [4]. That validation study found that the sensitivity and specificity of a definitive diagnosis according to TG07 were 84.9% and 50.0%, respectively, whereas Murphy's sign was of 20.5% sensitivity and 87.5% specificity. The diagnostic accuracy of the TG07 diagnostic criteria was thus significantly greater than that of Murphy's sign ($p = 1.31 \times 10^{-10}$). However, the authors pointed out that further improvement was required in the specificity of the diagnostic criteria for definitive diagnosis. Rather than changing the factors used for assessment, further consideration of new diagnostic criteria led to the decision to change the criteria by designating the presence of local signs of

Accepted Article

inflammation and systemic signs of inflammation as indicating a suspected diagnosis, and requiring confirmation by imaging findings in addition to these two factors for a definitive diagnosis. These new diagnostic criteria were validated by a multicenter joint study of 451 patients with acute cholecystitis [5], which found that their use improved sensitivity and specificity to 91.2% and 96.9%, respectively. On the basis of this result, the diagnostic criteria of TG13 were revised to reflect this new designation. At that point, no major problems with the use of the TG07 severity assessment criteria in clinical practice had been reported and no new evidence was available; therefore, the severity assessment criteria were adopted unchanged in TG13. However, Takada et al. expressed concern with the lack of evidence at the time preparations for the publication of TG13 were completed [6]. A large-scale epidemiological survey of acute biliary infection was therefore launched as a Japan-Taiwan Collaborative project: Defining the best practice of managing Acute Cholangitis and Cholecystitis since September 2012. This study gathered "big data" from over 7000 cases. Data from over 5000 patients with acute cholecystitis in that study were then used to describe patient characteristics, treatment status, and the status of use of the TG13 diagnostic criteria and severity grading in clinical practice, and this was published as a descriptive study [7]. A large-scale validation of the TG13 severity grading of acute cholecystitis was then carried out on the basis of those results [8], providing evidence for the current revisions. The inclusion of validation by "big data" in revision work on guidelines is far from common, but the work of revising TG18 can justly be said to be proceeding on the basis of clinical data.

In the Tokyo Guidelines Revision Committee, we searched for evidence published since TG13, and identified 216 articles related to the diagnostic criteria and severity grading of acute cholecystitis, including 19 randomized controlled trials (RCTs). Work on revision began in 2016. Based on these articles, we found that when considering new evidence gathered on the TG13 diagnostic criteria and severity grading of acute cholecystitis, such as validation studies, there was relatively little evidence concerning diagnostic criteria, with most validation studies instead being concerned with severity grading [9-13]. Some studies found that severity grading plays a useful role in predicting vital prognosis [9], and others that the length of hospitalization and the laparotomy conversion rate were significantly higher in more

severe cases [10]. Other studies, however, found that severe cholecystitis may be amenable to surgical treatment, even if percutaneous cholecystostomy is not always feasible and open cholecystectomy may be required [11,12]. Endo et al. carried out multivariate analysis of "big data" and used the results to propose a new treatment strategy for Grade III in accordance with TG13 severity grading [14]. Although the prognosis for acute cholecystitis is far from poor, survival prognosis is still determined by severity grading, and the discussion during the 2007 Tokyo consensus meeting in which it was decided that acute cholecystitis patients with organ failure affecting survival should therefore be graded as Grade III (severe) is still a recent memory.

In these present revisions, in light of the evidence accumulated so far, we report on our investigation of whether the diagnostic criteria and severity grading should be changed for TG18, and if so how. We also provide new information on diagnostic imaging in relation to diagnosis and severity grading.

CQ1. Is TG13 diagnostic criteria of acute cholecystitis recommended to use as TG18 diagnostic criteria?

[Foreground Question(Clinical question)]

The TG13 diagnostic criteria for acute cholecystitis have high sensitivity and specificity and good diagnostic yield; therefore, their use as the TG18 diagnostic criteria for acute cholecystitis is recommended.

(Recommendation 1, Level C)

To date, no diagnostic criteria for acute cholecystitis meriting that title have been established other than TG13 [1]. However, studies of the diagnostic yield of the TG13 diagnostic criteria are limited [5, 15, 16].

Studies have found that diagnostic accuracy ranges from 94.0% [5] to 60.4% [15] if pathological samples are used as the gold standard. In the former study, the sensitivity and specificity of the diagnostic criteria for acute cholecystitis were 91.2% and 96.9%, compared with 83.1% and 37.5% in the latter study.

However, the latter study found that neutrophil count was the only independent predictor of acute cholecystitis for which a significant difference was evident on the basis of multivariate analysis [15]. The use of neutrophil count alone for the definitive diagnosis of acute cholecystitis is unrealistic. The WSES guidelines for acute calculous cholecystitis, which are restricted to cholecystitis due to calculi, recommend the combined use of clinical, laboratory, and imaging findings for diagnosis, without designating new diagnostic criteria [16]. The TG13 diagnostic criteria for acute cholecystitis constitute exactly this combination, and we considered that they share the same concept for the designation of diagnostic criteria. A Japanese study of the association between diagnostic criteria and factors such as length of hospitalization and medical costs found statistically significant differences between definitive and suspected diagnoses [17], demonstrating the effectiveness of these diagnostic criteria. In light of the results of such validation studies, we considered that there are no major problems with the TG13 diagnostic criteria for acute cholecystitis, and recommend that they be used unchanged as the TG18/TG13 diagnostic criteria (Table 1).

CQ2. Is procalcitonin measurement useful for diagnosing and severity grading of acute cholecystitis?

[Future research question]

Few studies have addressed procalcitonin (PCT) in acute cholecystitis, and at present its value cannot be assessed.

(Level C)

Although systematic reviews of the value of procalcitonin (PCT) for the diagnosis and severity grading of sepsis have been published [18, 19], a meta-analysis has found that inconsistencies in study design mean that it is not helpful in distinguishing between sepsis and non-sepsis [20]. There has been only a single clinical study limited to patients with acute cholecystitis: this study found that it was correlated with the TG13 severity grading classification [21].

A number of studies that have collected cases of patients with acute cholangitis have reported that PCT is correlated with severity [22, 23, 24]. At this point, there is insufficient evidence to investigate the value of PCT measurement in acute cholecystitis, and as more evidence must be gathered in order for this to be assessed, this issue is therefore designated as a question for future research.

CQ3. Is ultrasonography recommended for diagnosing acute cholecystitis?

[Foreground Question (Clinical question)]

Although the diagnostic criteria for the diagnosis of acute cholecystitis by ultrasonography and its diagnostic yield vary in different studies, its low invasiveness, widespread availability, ease of use, and cost-effectiveness make it recommended as the first-choice imaging method for the morphological diagnosis of acute cholecystitis.

(Recommendation 1, Level C)

The use of ultrasonography (US) in acute cholecystitis has been well reported, and its ease of use and non-invasive modality have been described in case series studies [15, 25–28]. However, the diagnostic yield described in those articles varies according to the device, assessment criteria, and diagnostic criteria used in each of the studies, all of which were of small numbers of patients in single institutions. All studies that have compared the diagnostic yield of hepatobiliary scintigraphy (HIDA scanning) with that of US have found that the diagnostic yield is higher for HIDA scanning [26,27], but diagnostic imaging with US is nevertheless recommended in three newly proposed guidelines despite its limited diagnostic yield [16, 29,30].

US is comparatively inexpensive compared with modalities such as computed tomography (CT) and magnetic resonance imaging (MRI), and its non-invasive nature and comparatively high diagnostic yield make it the best option for the diagnostic imaging of acute cholecystitis [31,32]: its rate of use in clinical practice is reported to be 61.3% [7].

A meta-analysis comparing methods of diagnostic imaging for acute cholecystitis reported that US has 81% sensitivity (95% CI: 0.75–0.87) and 83% specificity (95% CI: 0.74–0.89) [33] (Fig. 1).

According to the TG13 diagnostic criteria for acute cholecystitis, diagnostic imaging findings are required for a definitive diagnosis, and US is the recommended method of diagnostic imaging (Fig.2) (Supplement Movie 1).

CQ4. Is color or power Doppler sonography useful for diagnosing acute cholecystitis?

[Future Research Question]

No recent studies have found that color or power Doppler sonography is useful for diagnosing acute cholecystitis. In terms of the underlying principles, the evaluation of blood flow by Doppler sonography is strongly affected by factors such as device performance and the patient's body type, which makes quantification difficult, and the designation of standard levels for use in diagnosis is therefore inappropriate.

(Level: D)

A study of the use of color Doppler sonography in acute cholecystitis found that although it was useful for the diagnosis of gallbladder adhesions, it was not predictive of the degree of surgical difficulty [34]. In our search of the color Doppler sonography literature, we were unable to identify any articles concerning the diagnosis of acute cholecystitis. None of the literature stated the type of device or device settings used (Doppler gain, high-pass filter, Doppler frequency, or speed range) or described patient characteristics (such as body wall thickness), and evaluation was subjective and qualitative in all cases. Potential problems include performance bias, detection bias, and inaccuracy. Although US in itself is not invasive and it is used more widely than other methods of morphological diagnosis, the use of color Doppler sonography for assessment is risky. Insufficient evidence is available to consider its value; as it cannot be assessed until further evidence has been gathered, this is regarded as a question for future research (Fig.3).

CQ5. Is MRI/MRCP useful for diagnosing acute cholecystitis?

[Foreground Question(Clinical question)]

MRI/MRCP is useful for diagnosing acute cholecystitis.

It is recommended if abdominal ultrasonography does not provide a definitive diagnosis.

(Recommendation 2, Level B)

Abdominal US should be the first method of diagnostic imaging used for acute cholecystitis. However, as a causative stone in the gallbladder or bile duct may not always be clearly identifiable on abdominal US and the diagnosis of gangrenous cholecystitis may be difficult (see CQ7), [35] it is also recommended that contrast-enhanced CT or MRI be performed if required[36,37].

The generally accepted imaging findings of acute cholecystitis are thickening of the gallbladder wall (≥ 4 mm), enlargement of the gallbladder (long axis ≥ 8 cm, short axis ≥ 4 cm), gallstones or retained debris, fluid accumulation around the gallbladder, and linear shadows in the fatty tissue around the gallbladder [38].

A 2012 meta-analysis of the MRI diagnosis of acute cholecystitis indicated the value of MRI/MRCP as shown in Figure 1, with the diagnostic yield of MRI for acute cholecystitis providing 85% sensitivity (95% CI: 0.66–0.95) and 81% specificity (95% CI: 0.69–0.90)[33]. However, that meta-analysis was based on three cohort studies and a cross-sectional study performed around the turn of the millennium, and the fact that contrast-enhanced MRI and MRCP were not yet in use at that point must be taken into account. Even non-contrast MRI/MRCP provides good visualization of thickening of the gallbladder wall, fluid retention around the gallbladder wall, and enlargement of the gallbladder, and one study has found that it is not inferior to contrast-enhanced MRI [39]. The anatomy of the biliary system is easy to assess on MRCP (by the visualization of accessory hepatic ducts and the common bile duct), making it useful for preoperative investigation. In terms of differentiation from chronic cholecystitis, thickening of the gallbladder wall and dense staining of the gallbladder bed in the early phase of contrast-enhanced MRI have been found to have 92% specificity for the diagnosis of acute cholecystitis [40] (Fig. 4), and another study also found that abnormal signals in fatty tissue around the gallbladder on MRI T2-weighted imaging had higher specificity

compared with CT findings [41] (Fig. 5). MRCP enables the anatomy of the biliary tract to be visualized without the use of a contrast agent, and is thus extremely useful. Although MRI/MRCP is expensive [16] compared with abdominal US, which is generally the lowest-cost method of imaging, its diagnostic yield is somewhat better than that of abdominal US, and its use is therefore recommended when abdominal US does not provide a definitive diagnosis. It is noteworthy that the image quality of MRI/MRCP may be deteriorated due to a patient with acute abdominal pain who may not be able to hold his/her breath or keep his/her at rest.

CQ6: Is TG13 severity grading of acute cholecystitis recommended to use as TG18 severity grading?

[Fore ground Question (Clinical question)]

Grade III (severe) acute cholecystitis in the TG13 severity grading of acute cholecystitis causes systemic symptoms due to organ damage and affects survival prognosis. The TG13 severity grading of acute cholecystitis is recommended for use as the TG18 severity grading of acute cholecystitis as a useful indicator from the perspective of predicting prognosis, among others.

(Recommendation 1, Level C)

(Addendum: Although moderate acute cholecystitis does not result in organ damage, this is still a risk, and as serious local complications may also arise, assessment using this severity grading may also be used to predict this risk.)

Grade III (severe) acute cholecystitis in the TG13 severity grading of acute cholecystitis is described as acute cholecystitis associated with organ system dysfunction, which in some circumstances may require treatment in an intensive care unit [1]. Severe acute cholecystitis is thus a condition that affects vital prognosis. However, the mortality rate for acute cholecystitis is only around 1% [7,42], and some studies, including case series studies, have also failed to find any association between severity grade and prognosis [12, 43]. Nevertheless, logistic regression analysis of the prediction of prognosis for acute cholecystitis

has shown that TG13 severity grading is a factor in predicting mortality on admission [9]. In a case series study of over 5000 patients, the prognosis for Grade III patients was also significantly worse than for Grades I and II [8] (Table 2).

The TG13 severity grading is thus well regarded as a factor predicting vital prognosis. Studies have also found that the length of hospital stay increases significantly for patients at higher grades according to the TG13 severity grading [10, 11, 12, 13, 17, 43,44](Table 3).

Conversion from laparoscopic cholecystectomy to open surgery has also been found to be significantly more likely for patients at higher TG13 severity grades [12,10,11,13,45,46] (Table 4).

In a study in the USA, multivariate analysis showed that TG13 severity grade was an independent predictor of both length of hospital stay and conversion to open surgery[10].

Complications are also significantly more common for patients at higher severity grades [44] (Table 5).

A study of intraoperative bile duct injury also found that complications occurred significantly more often in higher-grade cases [47]. Postoperative pathological findings of gangrenous cholecystitis and emphysematous cholecystitis have been found to be more severe in higher-grade cases [13]. The only study of medical costs so far performed is a Japanese study that found that medical costs are significantly higher in higher-grade cases [17].

A German study has proposed a new preoperative scoring system for acute cholecystitis [48]. This consists of eight factors identified as independent risk factors by multivariate analysis: sex, age, body mass index (BMI), American Society of Anesthesiologists (ASA) score, recurrent colic, gallbladder wall thickness, white blood cell count (WBC), and C-reactive protein (CRP) level. These factors are scored according to a scoring system with a maximum of 9 points, with a score of 7 points or more designated as severe (Grade III). This scoring system has been found to be correlated with operating time, ICU

admission, and length of hospital stay, but is not associated with complications or conversion rate. An

Italian group has also reported diagnostic criteria for severe cholecystitis in which gangrenous cholecystitis and phlegmonous cholecystitis are designated as severe, consisting of four factors: fever >38°C, distention

of gallbladder, wall edema, and preoperative adverse events [49]. The authors found that when two or more factors were positive this system had 54.9% sensitivity (95% CI: 44.1%–65.2%) and 81.2% specificity (95% CI: 75.4%–85.9%), and when three or more factors were positive it had 15.9% sensitivity (95% CI: 9.5%–25.3%) and 98.6% specificity (95% CI: 95.9%–99.5%). Neither of the two newly proposed guidelines indicate criteria for severity grading [16,29]. Studies have found that surgery for patients classed as Grade III according to the TG13 severity grading is feasible even if percutaneous cholecystectomy is not always performed, with conversion or subtotal cholecystectomy also possible procedures [11,12]. The TG13 severity grading cannot be used to assess surgical difficulty. If a set of severity grading criteria including such an element of surgical difficulty were to be produced in future, a large-scale validation study taking account of a large number of factors would be required. Rather than changing the Grade III assessment criteria, it may be possible to subdivide Grade III cases to enable safe surgery and select the appropriate treatment strategy. On this point, Endo et al. used multivariate analysis to investigate predictive factors in Grade III cases, and showed that factors including jaundice, neurological dysfunction, and respiratory dysfunction were associated with vital prognosis [14] (Table 6).

The assessment criteria used in the TG13 severity grading for acute cholecystitis have been validated in numerous studies, are significantly associated with parameters including vital prognosis, length of hospital stay, conversion to open surgery, and medical costs, and are useful indicators in clinical practice. Their use as the TG18/TG13 severity assessment criteria is therefore recommended (Table 7).

CQ7. What method of diagnostic imaging is recommended for diagnosing gangrenous cholecystitis?

[Foreground Question (Clinical question)]

Contrast-enhanced CT or contrast-enhanced MRI is recommended for diagnosing gangrenous cholecystitis.

(Recommendation 2, Level C)

Gangrenous cholecystitis exhibits specific findings on dynamic CT, including irregular thickening of the gallbladder wall, poor contrast enhancement of the gallbladder wall (interrupted rim sign), increased density of fatty tissue around the gallbladder, gas in the gallbladder lumen or wall, membranous structures within the lumen (intraluminal flap or intraluminal membrane), and peri-gallbladder abscess [50] (Fig. 6) . These signs of irregularity or rupture of the gallbladder wall are often underestimated on abdominal US [35], and studies have found that the presence of the interrupted rim sign on contrast-enhanced CT has 73% sensitivity and 95% negative predictive value[38] and that the appearance of intraluminal membranous structures on contrast-enhanced MRI has 80% diagnostic accuracy [51], exceeding the diagnostic yield of abdominal US. A retrospective image analysis study of patients diagnosed with acute cholecystitis also found that a combination of the perfusion defect of the gallbladder wall and no identifiable calculi had 92% diagnostic accuracy, 88.2% sensitivity, and 100% specificity for the diagnosis of acute gangrenous cholecystitis [51].

Gangrenous cholecystitis is classed as moderate (Grade II) acute cholecystitis according to the TG13 severity grading, and is a serious condition that may cause organ damage if its diagnosis is delayed.

Abdominal US is generally the lowest-cost method of imaging, and contrast-enhanced CT and contrast-enhanced MRI are expensive tests[52]. However, the diagnostic yield of contrast-enhanced CT and contrast-enhanced MRI is better than that of abdominal US for gangrenous cholecystitis, and the use of one of these methods is particularly recommended for patients with suspected gangrenous cholecystitis (Supplement Movie 2,3).

CQ8. What method of diagnostic imaging is recommended for diagnosing emphysematous cholecystitis?

[Foreground Question(Clinical question)]

CT is recommended for diagnosing emphysematous cholecystitis.

(Recommendation 2, Level D)

Emphysematous cholecystitis is an inflammation caused by aerogenic bacteria, and has a high perforation rate. It causes potentially fatal complications including intra-abdominal abscess, generalized peritonitis, gas gangrene of the abdominal wall, and sepsis; its clinical course is often extremely rapid. In TG13 it is classed as moderate acute cholecystitis (severe local inflammatory findings) [1]. An accurate assessment of the presence of gas within the gallbladder wall is important for the diagnosis of emphysematous cholecystitis, but in abdominal US it is very often difficult to distinguish between intramural gas, which appears hyperechoic, and porcelain gallbladder. As gas is sometimes found to be present within the gallbladder lumen after biliary surgery or sphincterotomy, distinguishing between intraluminal and intramural gas is important, but this may be difficult to diagnose correctly on abdominal US. Gas appears clearly hypodense on CT (usually near the -1000 HU), making detection extremely easy[36,50]. Intramural gas is often present also in gangrenous cholecystitis[38,51]. Contrast-enhanced CT should be considered for the evaluation of complications such as intraperitoneal abscess and peritonitis. Gas appears as a signal void on MRI[53], however this modality is inferior to CT in terms of spatial resolution for the detection of minute amounts of gas. Plain CT is thus the most useful method for diagnosing emphysematous cholecystitis (Fig.7).

The Results of discussion about the diagnostic criteria and severity grading for acute cholecystitis at the public hearing

In A-PHPBA at Yokohama Congress Center on June 9, 2017, public hearing was held and gathered various opinions about this topic. It was decided that TG13 diagnostic criteria and severity grading would be adopted TG18 without any modification by final vote (Fig. 8).

Acknowledgements

We express our deep gratitude to the Japanese Society of Hepato-Biliary-Pancreatic Surgery, the Japanese Society of Abdominal Emergency Medicine, the Japanese Society of Surgical Infection, and the Japan Biliary Association, for their substantial support and guidance in the preparation of this article. We also would like to express our deep gratitude to the Japanese Society of Hepato-Biliary-Pancreatic Surgery for the Article Processing Managing Office of the Tokyo Guidelines 18 for preparing this publication. We appreciate all secretariats of the Japanese Society of Hepato-Biliary-Pancreatic Surgery for their technical support.

Conflicts of interest

Anthony Yuen Bun TEOH has received consultant fees from Boston Scientific Corporation, USA, Cook Medical, USA, and Taewoong Medical, Korea. Goro Honda has received honoraria from Johnson and Johnson and Medtronic.

Appendix:

Masamichi Yokoe and Yoshinori Noguchi, Department of General Internal Medicine, Japanese Red Cross Nagoya Daini Hospital, Aichi, Japan; Jiro Hata, Department of Endoscopy and Ultrasound, Kawasaki Medical School, Okayama, Japan; Tadahiro Takada and Fumihiko Miura, Department of Surgery, Teikyo University School of Medicine, Tokyo, Japan; Steven M. Strasberg, Section of Hepato-Pancreato-Biliary Surgery, Washington University School of Medicine in St. Louis, St. Louis, MO, USA; Horacio J. Asbun, Department of Surgery, Mayo Clinic College of Medicine, Jacksonville, FL, USA; Go Wakabayashi, Department of Surgery, Ageo Central General Hospital, Saitama, Japan; Kazuto Kosaka, Department of Radiology, Kanazawa University Graduate School of Medical Sciences, Itaru Endo, Department of Gastroenterological Surgery, Yokohama City University Graduate School of Medicine, Kanagawa, Japan; Daniel J. Deziel, Department of Surgery, Rush University Medical Center, Chicago, IL, USA; Kohji Okamoto, Department of Surgery, Center for Gastroenterology and Liver Disease, Kitakyushu City Yahata

Hospital, Fukuoka, Japan; Tsann-Long Hwang and Miin-Fu Chen, Division of General Surgery, Linkou Chang Gung Memorial Hospital, Taoyuan, Taiwan; Wayne Shih-Wei Huang, Department of Surgery, Show Chwan Memorial Hospital, Changhua, Taiwan; Chen-Guo Ker, Department of Surgery, Yuan's General Hospital, Kaohsiung, Taiwan; Eduard Jonas, Surgical Gastroenterology/Hepatopancreatobiliary Unit University of Cape Town and Groote Schuur Hospital, Cape Town, South Africa; Ho-Seong Han and Yoo-Seok Yoon, Department of Surgery, Seoul National University Bundang Hospital, Seoul National University College of Medicine, Seoul, Korea; In-Seok Choi, Department of Surgery, Konyang University Hospital, Daejeon, Korea; Dong-Sup Yoon, Department of Surgery, Yonsei University Gangnam Severance Hospital, Seoul, Korea; Satoru Shikata, Director, Mie Prefectural Ichishi Hospital, Mie, Japan; Tomohiko Ukai, Department of Family Medicine, Mie Prefectural Ichishi Hospital, Mie, Japan; Ryota Higuchi and Masakazu Yamamoto, Department of Surgery, Institute of Gastroenterology, Tokyo Women's Medical University, Tokyo, Japan; Toshifumi Gabata, Director, General Kanazawa University Hospital, Yasuhisa Mori, Department of Surgery and Oncology, Graduate School of Medical Sciences, Kyushu University, Fukuoka, Japan; Yukio Iwashita, Department of Gastroenterological and Pediatric Surgery, Oita University Faculty of Medicine, Oita, Japan; Taizo Hibi, Department of Surgery, Keio University School of Medicine, Tokyo, Japan; Palepu Jagannath, Department of Surgical Oncology, Lilavati Hospital and Research Centre, Mumbai, India; Eduard Jonas, Surgical Gastroenterology /Hepatopancreatobiliary Unit University of Cape Town and Groote Schuur Hospital, Cape Town, South Africa; Kui-Hin Liao, Liao KH Consulting PL, Mt Elizabeth Novena Hospital, Singapore, Yong Loo Lin School of Medicine, National University of Singapore, Singapore; Christos Dervenis, First Department of Surgery, Agia Olga Hospital, Athens, Greece; Dirk Joan Gouma, Department of Surgery, Academic Medical Center, Amsterdam, The Netherlands; Daniel Cherqui, Hepatobiliary Center, Paul Brousse Hospital, Villejuif, France; Giulio Belli, Department of General and HPB Surgery, Loreto Nuovo Hospital, Naples Italy; O. James Garden, Clinical Surgery, University of Edinburgh, Edinburgh, UK; Mariano Eduardo Giménez, Chair of General Surgery and Minimal Invasive Surgery "Taquini", University of Buenos Aires, DAICIM Foundation, Buenos Aires, Argentina; Eduardo de Santibañes, Department of Surgery, Hospital Italiano,

University of Buenos Aires, Buenos Aires, Argentina; Kenji Suzuki, Department of Surgery, Fujinomiya City General Hospital, Shizuoka, Japan; Akiko Umezawa, Minimally Invasive Surgery Center, Yotsuya Medical Cube, Tokyo, Japan; Avinash Nivritti Supe, Department of Surgical gastroenterology, Seth G S Medical College and K E M Hospital, Mumbai, India; Henry A. Pitt, Lewis Katz School of Medicine at Temple University, Philadelphia, PA, USA; Harjit Singh, Department of Hepato-Pancreato-Biliary Surgery, Hospital Selayang, Malaysia; Angus C.W. Chan, Surgery Centre, Department of Surgery, Hong Kong Sanatorium and Hospital, Hong Kong, Hong Kong; Wan Yee Lau, Faculty of Medicine, The Chinese University of Hong Kong, Shatin, Hong Kong; Anthony Yuen Bun TEOH, Department of Surgery, The Chinese University of Hong Kong, Shatin, Hong Kong; Goro Honda, Department of Surgery, Tokyo Metropolitan Komagome Hospital, Tokyo, Japan; Atsushi Sugioka, Department of Surgery, Fujita Health University School of Medicine, Aichi, Japan; Koji Asai, Department of Surgery, Toho University Ohashi Medical Center, Tokyo, Japan; Harumi Gomi, Center for Global Health, Mito Kyodo General Hospital, University of Tsukuba, Ibaraki, Japan; Takao Itoi, Department of Gastroenterology and Hepatology, Tokyo Medical University Hospital, Tokyo, Japan; Seiki Kiriya, Department of Gastroenterology, Ogaki Municipal Hospital, Gifu, Japan; Masahiro Yoshida, Department of Hemodialysis and Surgery, chemotherapy research institute Kaken hospital, International University of Health and Welfare, Chiba, Department of EBM and Guidelines, Japan council for Quality Health Care, Tokyo, Japan; Toshihiko Mayumi, Naoki Matsumura, Hiromi Tokumura, Department of Surgery, Tohoku Rosai Hospital, Miyagi, Japan; Seigo Kitano, President, Oita University, Oita, Japan; Koichi Hirata, Department of Surgery, JR Sapporo Hospital, Hokkaido, Japan; Yoshinobu Sumiyama, Director, Toho University, Tokyo, Japan; Kazuo Inui, Department of Gastroenterology, Second Teaching Hospital, Fujita Health University, Aichi, Japan

References

- 1) Yokoe M, Takada T, Strasberg SM, Solomkin JS, Mayumi T, Gomi H, et al. TG13 diagnostic criteria and severity grading of acute cholecystitis (with videos). *J Hepatobiliary Pancreat Sci.* 2013; 20:35-46.
- 2) Hirota M, Takada T, Kawarada Y, Nimura Y, Miura F, Hirata K, et al. Diagnostic criteria and severity assessment of acute cholecystitis: TokyoGuidelines. *J Hepatobiliary Pancreat Surg.* 2007; 14:78-82.
- 3) Shekelle PG, Ortiz E, Rhodes S, Morton SC, Eccles MP, Grimshaw JM, Woolf SH. Validity of the Agency for Healthcare Research and Quality clinical practice guidelines: how quickly do guidelines become outdated? *JAMA.* 2001 Sep 26;286:1461-7.
- 4) Yokoe M, Takada T, Mayumi T, Yoshida M, Hasegawa H, Norimizu S, et al. Accuracy of the Tokyo Guidelines for the diagnosis of acute cholangitis and cholecystitis taking into consideration the clinical practice pattern in Japan. *J Hepatobiliary Pancreat Sci.* 2011;18:250-7.
- 5) Yokoe M, Takada T, Strasberg SM, Solomkin JS, Mayumi T, Gomi H, et al. New diagnostic criteria and severity assessment of acute cholecystitis in revised Tokyo guidelines. *J Hepatobiliary Pancreat Sci.* 2012;19:578-585.
- 6) Takada T. How far have we progressed since the Tokyo Guidelines 2013? *J Hepatobiliary Pancreat Sci.* 2017 Jun;24(6):307-309. doi: 10.1002/jhbp.483.
- 7) Yokoe M, Takada T, Hwang TL, Endo I, Akazawa K, Miura F, Mayumi T, Mori R, Chen MF, Jan YY, Ker CG, Wang HP, Itoi T, Gomi H, Kiriyaama S, Wada K, Yamaue H, Miyazaki M, Yamamoto M. Descriptive review of acute cholecystitis: Japan-Taiwan collaborative epidemiological study. *J Hepatobiliary Pancreat Sci.* 2017 Mar 18. doi: 10.1002/jhbp.450. [Epub ahead of print]
- 8) Yokoe M, Takada T, Hwang TL, Endo I, Akazawa K, Miura F, Mayumi T, Mori R, Chen MF, Jan YY, Ker CG, Wang HP, Itoi T, Gomi H, Kiriyaama S, Wada K, Yamaue H, Miyazaki M, Yamamoto M. Validation of TG13 severity grading in acute cholecystitis: Japan-Taiwan collaborative study for acute cholecystitis. *J Hepatobiliary Pancreat Sci.* 2017 Apr 17. doi: 10.1002/jhbp.457. [Epub ahead of print]
- 9) González-Muñoz JI, Franch-Arcas G, Angoso-Clavijo M, Sánchez-Hernández M, García-Plaza A, Caraballo-Angeli M, Muñoz-Bellvís L. Risk-adjusted treatment selection and outcome of patients

with acute cholecystitis. *Langenbecks Arch Surg.* 2017 Jun;402(4):607-614. doi: 10.1007/s00423-016-1508-y. Epub 2016 Oct 4.

- 10) Paul Wright G, Stilwell K, Johnson J, Hefty MT, Chung MH. Predicting length of stay and conversion to open cholecystectomy for acute cholecystitis using the 2013 Tokyo Guidelines in a US population. *J Hepatobiliary Pancreat Sci.* 2015 Nov;22(11):795-801. doi: 10.1002/jhbp.284. Epub 2015 Sep 15.
- 11) Kamalapurkar D, Pang TC, Siriwardhane M, Hollands M, Johnston E, Pleass H, Richardson A, Lam VW. Index cholecystectomy in grade II and III acute calculous cholecystitis is feasible and safe. *ANZ J Surg.* 2015 Nov;85(11):854-9. doi: 10.1111/ans.12986. Epub 2015 Feb 2.
- 12) Amirthalingam V, Low JK, Woon W, Shelat V. Tokyo Guidelines 2013 may be too restrictive and patients with moderate and severe acute cholecystitis can be managed by early cholecystectomy too. *Surg Endosc.* 2017 Jul;31(7):2892-2900. doi: 10.1007/s00464-016-5300-4. Epub 2016 Nov 1.
- 13) Ambe PC, Christ H, Wassenberg D. Does the Tokyo guidelines predict the extent of gallbladder inflammation in patients with acute cholecystitis? A single center retrospective analysis. *BMC Gastroenterol.* 2015 Oct 20;15:142. doi: 10.1186/s12876-015-0365-4.
- 14) Endo I, Takada T, Hwang TL, Akazawa K, Mori R, Miura F, Yokoe M, Itoi T, Gomi H, Chen MF, Jan YY, Ker CG, Wang HP, Kiriya S, Wada K, Yamaue H, Miyazaki M, Yamamoto M. Optimal treatment strategy for acute cholecystitis based on predictive factors: Japan-Taiwan multicenter cohort study. *J Hepatobiliary Pancreat Sci.* 2017 Jun;24(6):346-361. doi: 10.1002/jhbp.456. Epub 2017 May 31.
- 15) Naidu K, Beenen E, Gananadha S, Mosse C. The Yield of Fever, Inflammatory Markers and Ultrasound in the Diagnosis of Acute Cholecystitis: A Validation of the 2013 Tokyo Guidelines. *World J Surg.* 2016 Dec;40(12):2892-2897.
- 16) Ansaloni L, Pisano M, Coccolini F, Peitzmann AB, Fingerhut A, Catena F, et al. 2016 WSES guidelines on acute calculous cholecystitis. *World J Emerg Surg.* 2016 Jun 14;11:25. doi: 10.1186/s13017-016-0082-5. eCollection 2016.

- 17) Hayasaki A, Takahashi K, Fujii T, Kumamoto K, Fujii K, Matsumoto E, Miyahara S, Kusuta T, Azumi Y, Isaji S. Factor Analysis Influencing Postoperative Hospital Stay and Medical Costs for Patients with Definite, Suspected, or Unmatched Diagnosis of Acute Cholecystitis according to the Tokyo Guidelines 2013. *Gastroenterol Res Pract.* 2016;2016:7675953. doi: 10.1155/2016/7675953. Epub 2016 Apr 28.
- 18) Uzzan B, Cohen R, Nicolas P, Cucherat M, Perret GY. Procalcitonin as a diagnostic test for sepsis in critically ill adults and after surgery or trauma: a systematic review and meta-analysis. *Crit Care Med.* 2006 ;34:1996-2003.
- 19) Wacker C, Prkno A, Brunkhorst FM, Schlattmann P. Procalcitonin as a diagnostic marker for sepsis: a systematic review and meta-analysis. *Lancet Infect Dis.* 2013;13:426-35.
- 20) Tang BM, Eslick GD, Craig JC, McLean AS. Accuracy of procalcitonin for sepsis diagnosis in critically ill patients: systematic review and meta-analysis. *Lancet Infect Dis.* 2007 ;7:210-7.
- 21) Yuzbasioglu Y, Duymaz H, Tanrikulu CS, Halhalli HC, Koc MO, Tandoğan M, Coskun F. Role of Procalcitonin in Evaluation of the Severity of Acute Cholecystitis. *Eurasian J Med.* 2016;48:162-166.
- 22) Hamano K, Noguchi O, Matsumoto Y, Watabe T, Numata M, Yosioka A, Ito Y, Hosoi H. Usefulness of procalcitonin for severity assessment in patients with acute cholangitis. *Clin Lab.* 2013;59:177-83.
- 23) Shinya S, Sasaki T, Yamashita Y, Kato D, Yamashita K, Nakashima R, Yamauchi Y, Noritomi T. Procalcitonin as a useful biomarker for determining the need to perform emergency biliary drainage in cases of acute cholangitis. *J Hepatobiliary Pancreat Sci.* 2014;21:777-85.
- 24) Sato M, Matsuyama R, Kadokura T, Mori R, Kumamoto T, Nojiri K, Taniguchi K, Takeda K, Kubota K, Tanaka K, Endo I. Severity and prognostic assessment of the endotoxin activity assay in biliary tract infection. *J Hepatobiliary Pancreat Sci.* 2014;21:120-7.
- 25) Hwang H, Marsh I, Doyle J. Does ultrasonography accurately diagnose acute cholecystitis? Improving diagnostic accuracy based on a review at a regional hospital. *Can J Surg.* 2014 Jun;57:162-8.
- 26) Kaoutzanis C, Davies E, Leichtle SW, Welch KB, Winter S, et al. Abdominal ultrasound versus hepato-imino diacetic acid scan in diagnosing acute cholecystitis--what is the real benefit? *J Surg*

Res. 2014 May 1;188:44-52.

- 27) Rodriguez LE, Santaliz-Ruiz LE, De La Torre-Bisot G, Gonzalez G, Serpa MA, et al. Clinical implications of hepatobiliary scintigraphy and ultrasound in the diagnosis of acute cholecystitis. *Int J Surg*. 2016 Nov;35:196-200.
- 28) Villar J, Summers SM, Menchine MD, Fox JC, Wang R. The Absence of Gallstones on Point-of-Care Ultrasound Rules Out Acute Cholecystitis. *J Emerg Med*. 2015 Oct;49:475-80.
- 29) European Association for the Study of the Liver (EASL). EASL Clinical Practice Guidelines on the prevention, diagnosis and treatment of gallstones. *J Hepatol*. 2016 Jul;65:146-81.
- 30) Internal Clinical Guidelines Team (UK). Gallstone Disease: Diagnosis and Management of Cholelithiasis, Cholecystitis and Choledocholithiasis. London: National Institute for Health and Care Excellence (UK); 2014 Oct.
- 31) Yarmish GM, Smith MP, Rosen MP, Baker ME, Blake MA, et al. ACR appropriateness criteria right upper quadrant pain. *J Am Coll Radiol*. 2014 Mar;11:316-22.
- 32) Pinto A, Reginelli A, Cagini L, Coppolino F, Stabile Ianora AA, et al. Accuracy of ultrasonography in the diagnosis of acute calculous cholecystitis: review of the literature. *Crit Ultrasound J*. 2013 Jul 15;5 Suppl 1: S11
- 33) Kiewiet JJ, Leeuwenburgh MM, Bipat S, Bossuyt PM, Stoker J, et al. A systematic review and meta-analysis of diagnostic performance of imaging in acute cholecystitis. *Radiology*. 2012 Sep;264:708-20.
- 34) Çetinkünar S, Erdem H, Aktimur R, Soker G, Bozkurt H, et al. Evaluation of power Doppler sonography in acute cholecystitis to predict intraoperative findings: a prospective clinical study. *Ulus Travma Acil Cerrahi Derg*. 2015; 21: 51-56.
- 35) Yeh DD, Cropano C, Fagenholz P, King DR, Chang Y, Klein EN, et al. Gangrenous cholecystitis: Deceiving ultrasounds, significant delay in surgical consult, and increased postoperative morbidity! *J Trauma Acute Care Surg*. 2015;79:812-6.
- 36) Bates DD, LeBedis CA, Soto JA, Gupta A. Use of Magnetic Resonance in Pancreaticobiliary

Emergencies. *Magn Reson Imaging Clin N Am*. 2016;24:433-48.

- 37) Watanabe Y, Nagayama M, Okumura A, Amoh Y, Katsube T, Suga T, et al. MR Imaging of Acute Biliary Disorders 1. *Radiographics*. 2007;27:477-95.
- 38) Fuks D, Mouly C, Robert B, Hajji H, Yzet T, Regimbeau J-M. Acute cholecystitis: preoperative CT can help the surgeon consider conversion from laparoscopic to open cholecystectomy. *Radiology*. 2012;263:128-38.
- 39) Oh K, Gilfeather M, Kennedy A, Glastonbury C, Green D, Brant W, et al. Limited abdominal MRI in the evaluation of acute right upper quadrant pain. *Abdominal imaging*. 2003;28:643-51.
- 40) Altun E, Semelka RC, Elias Jr J, Braga L, Voultzinos V, Patel J, et al. Acute cholecystitis: MR findings and differentiation from chronic cholecystitis 1. *Radiology*. 2007;244:174-83.
- 41) Kaura SH, Haghighi M, Matza BW, Hajdu CH, Rosenkrantz AB. Comparison of CT and MRI findings in the differentiation of acute from chronic cholecystitis. *Clin Imaging*. 2013;37:687-91.
- 42) Kimura Y, Takada T, Strasberg SM, Pitt HA, Gouma DJ, Garden OJ, Büchler MW, et al. TG13 current terminology, etiology, and epidemiology of acute cholangitis and cholecystitis. *J Hepatobiliary Pancreat Sci*. 2013 Jan;20:8-23. doi: 10.1007/s00534-012-0564-0.
- 43) Lee SW, Yang SS, Chang CS, Yeh HJ. Impact of the Tokyo guidelines on the management of patients with acute calculous cholecystitis. *J Gastroenterol Hepatol*. 2009 Dec;24:1857-61. doi: 10.1111/j.1440-1746.2009.05923.x.
- 44) Cheng WC, Chiu YC, Chuang CH, Chen CY. Assessing clinical outcomes of patients with acute calculous cholecystitis in addition to the Tokyo grading: a retrospective study. *Kaohsiung J Med Sci*. 2014 Sep;30:459-65. doi: 10.1016/j.kjms.2014.05.005. Epub 2014 Jun 27.
- 45) Asai K, Watanabe M, Kusachi S, Matsukiyo H, Saito T, Kodama H, et al. Risk factors for conversion of laparoscopic cholecystectomy to open surgery associated with the severity characteristics according to the Tokyo guidelines. *Surg Today*. 2014 Dec;44:2300-4. doi: 10.1007/s00595-014-0838-z. Epub 2014 Jan 29.
- 46) Bouassida M, Charrada H, Feidi B, Chtourou MF, Sassi S, Mighri MM, et al. Could the Tokyo

guidelines on the management of acute cholecystitis be adopted in developing countries? Experience of one center. *Surg Today*. 2016 May;46:557-60. doi: 10.1007/s00595-015-1207-2. Epub 2015 Jun 21.

- 47) Törnqvist B, Waage A, Zheng Z, Ye W, Nilsson M. Severity of Acute Cholecystitis and Risk of Iatrogenic Bile Duct Injury During Cholecystectomy, a Population-Based Case-Control Study. *World J Surg*. 2016 May;40:1060-7. doi: 10.1007/s00268-015-3365-1.
- 48) Ambe PC, Papadakis M, Zirngibl H. A proposal for a preoperative clinical scoring system for acute cholecystitis. *J Surg Res*. 2016 Feb;200(2):473-9. doi: 10.1016/j.jss.2015.09.010. Epub 2015 Sep 9.
- 49) Borzellino G, Steccanella F, Mantovani W, Genna M. Predictive factors for the diagnosis of severe acute cholecystitis in an emergency setting. *Surg Endosc*. 2013 Sep;27:3388-95. doi: 10.1007/s00464-013-2921-8. Epub 2013 Apr 3.
- 50) Patel NB, Oto A, Thomas S. Multidetector CT of emergent biliary pathologic conditions. *Radiographics*. 2013;33:1867-88.
- 51) Wu CH, Chen CC, Wang CJ, Wong YC, Wang LJ, Huang CC, et al. Discrimination of gangrenous from uncomplicated acute cholecystitis: accuracy of CT findings. *Abdom Imaging*. 2011;36:174-8.
- 52) Stoker J, van Randen A, Laméris W, Boermeester MA. Imaging Patients with Acute Abdominal Pain 1. *Radiology*. 2009;253:31-46.
- 53) Koenig T, Tamm EP, Kawashima A. Magnetic resonance imaging findings in emphysematous cholecystitis. *Clin Radiol*. 2004;59:455-8.

Figure legend

Fig. 1 Forest plot. Paired forest plot of summary estimates for sensitivity and specificity. The overall summary estimates of sensitivity and specificity for cholescintigraphy, US, and MR imaging are plotted in pairs. Error bars = calculated 95% Cis. (Source: Reference 33)

Fig. 2 Typical ultrasound images of acute cholecystitis.

a: Pericholecystic fluid. Pericholecystic fluid is demonstrated to the left side of the gallbladder. Gallstones and debris are also seen in the gallbladder.

b: An intraluminal flap seen in a gangrenous cholecystitis. A linear echogenic line representing the intraluminal flap is demonstrated.

Fig. 3 Typical ultrasound images of acute cholecystitis

a: Color Doppler images of acute cholecystitis. Increased intraluminal blood flow is demonstrated. However it is not always easy to estimate the intraluminal flow since the sensitivity of color Doppler imaging is influenced by several factors such as the settings of the filter, velocity range, frequency of the ultrasound beam, the patients' constitutions, and the limitations of the equipment.

b: Superb Microvascular Imaging of acute cholecystitis. Superb Microvascular imaging, which is more sensitive than the conventional color Doppler in the detection of blood flow, shows the increased intraluminal flow of the gallbladder in a patient with acute cholecystitis. Still, the same problem as described in the figure legend of Fig. 3a remains so it is difficult to make use of these Doppler imagings as an objective method for the diagnosis of acute cholecystitis.

Fig. 4 Typical MR images of acute cholecystitis comparing contrast-enhanced CT. Man in 40s with acute cholecystitis due to gallstones. Dynamic contrast enhanced MRI and CT are shown. Early phase (a) and portal venous phase (b) of contrast-enhanced MRI

Early phase (c) and portal venous phase (d) of contrast-enhanced CT. Numerous signal voids are visible in the gallbladder (a, arrowhead which indicates the gallstones). Clear contrast enhancement of the gallbladder wall is evident (b, arrows). This contrast enhancement of the wall is more clearly visualized on MRI compared with contrast-enhanced CT, and gallstone visualization is also better on MRI than on CT. To identify gallstone, T2 weighted MRI is also helpful (image is not shown).

Fig. 5 Typical MR images and MRCP of acute cholecystitis. Man in 70s with acute cholecystitis due to gallstones. MR T2 weighted image (ssfse: single shot fast spin echo) (a), diffusion weighted image (b), and MRCP (c). On T2 weighted image of MRI (a), a hypointense gallstone (a, arrowhead) is visible in the gallbladder. The gallbladder is enlarged, with thickening of the wall (a, arrow). On diffusion weighted image of MRI (b), thickening of the gallbladder wall (b, arrows) is clearly evident. The deposition of debris is visualized as a hyperintensity (b, *) at the neck of the gallbladder. On 2D MRCP image (40mm slice thickness) (c), the aberrant posterior hepatic duct (c, arrow) is clearly visualize. The asterisk indicates the neck of the gallbladder.

Fig. 6 Typical CT images of gangrenous cholecystitis. Woman in her 70s with gangrenous cholecystitis (acute acalculous cholecystitis). Dynamic contrast enhanced CT (a, plain; b, early phase; c, equilibrium phase). Enlargement of the gallbladder, thickening of the gallbladder wall, and edematous lesions beneath the gallbladder serosa are evident on plain CT (arrows). On contrast enhanced CT (b,c), irregularity of the gallbladder wall and the partial lack of contrast enhancement can be seen (arrows) as the characteristic appearance of gangrenous cholecystitis. Transient early-phase staining of the hepatic parenchyma (b) and edematous changes to the hepatoduodenal ligament (c, arrowhead) are also apparent, suggesting the spread of inflammation.

Fig. 7 Typical CT, US, and MRI findings of gangrenous cholecystitis. Man in his 80s with emphysematous cholecystitis. Chest X-ray (a, inset picture is a magnification of the squared area), plain CT (b), dynamic contrast enhanced CT: early phase (c), equilibrium phase (d). On chest X-ray, abnormal gas is apparent in the right upper abdomen. Gas is present both within the gallbladder lumen (a, *) and the gallbladder wall (a, arrows). On plain CT, gas is evident both within the gallbladder wall and the gallbladder lumen. Contrast enhancement is apparent in the wall at the neck of the gallbladder (arrowhead). Inflammation has spread beneath the duodenal mucosa, and an abscess is also present (*).

Fig. 8 Public hearing final voting outcome

***Supporting Information**

Additional Supporting Information may be found in the online version of this article at the publisher's web-site:

Supplement Movie 1: Acute cholecystitis.

Gallbladder swelling, wall thickening with pericholecystic fluid, massive debris and stone impaction are demonstrated.

Supplement Movie 2: Gangrenous cholecystitis.

Gallbladder swelling, wall thickening, hypoechoic layer and massive debris are demonstrated. However, it is difficult to diagnose acute gangrenous cholecystitis or not for this case by only these US findings.

Supplement Movie 3: Gangrenous cholecystitis.

Gallbladder enlargement, massive debris and stone impaction are demonstrated. However, it is difficult to diagnose acute gangrenous cholecystitis or not for this case by only these US findings.

Table 1 TG18/TG13 Diagnostic criteria for acute cholecystitis**A. Local signs of inflammation etc.:**

(1) Murphy's sign, (2) RUQ mass/pain/tenderness

B. Systemic signs of inflammation etc.:

(1) Fever, (2) elevated CRP, (3) elevated WBC count

C. Imaging findings:

Imaging findings characteristic of acute cholecystitis

Suspected diagnosis: One item in A + one item in B**Definite diagnosis:** One item in A + one item in B + C

Cited from Ref.[5]

Notes: acute hepatitis, other acute abdominal diseases, and chronic cholecystitis should be excluded. *RUQ* right upper abdominal quadrant, *CRP* C-reactive protein, *WBC* white blood cell. The TG13 diagnostic criteria of acute cholecystitis was judged from numerous validation studies as useful indicators in clinical practice and adopted as TG18 diagnostic criteria without any modification.

Table 2 Relationship between severity and 30-days overall mortality*

	Severity grading			p value
	Grade I n= 1339	Grade II n= 1702	Grade III n= 680	
30days mortality	15 (1.1%)	13 (0.8%)	37 (5.4%)	< 0.001

*Data from Yokoe et al.⁸**Table 3** Length of hospital stay

References	Year	n	Grade I	Grade II	Grade III	
Cheng [44]	2014	103	7.3±3.5	9.2±3.9	15.2±8.5	p<0.05
Kamalapurkar* [11]	2014	84		5(4-8)	12(8-16)	p<0.001
Wright* [10]	2015	445	3(1-16)	4(1-33)	7(1-60)	p<0.001
Ambe [§] [13]	2015	138	6.0±2.7	7.8±3.3	10.4±6.1	p=0.02
Amirthalingam** [12]	2016	149	4.46(2-14)	6.24(1-41)	9.31(3-21)	p<0.001
Hayasaki [17]	2016	171	4.3±2.5	11.0±11.6	20.8±13.5	p<0.001

Data are presented as mean days±SD, *:median(range), **:median(interquartile range), §:postoperative length of hospital stay

Table 4 Conversion rate from laparoscopic cholecystectomy to open surgery

References	Year	n	Grade I	Grade II	Grade III	
Asai [45]	2014	225	7/105 (6.7%)	22/119 (18.5%)	0/1 (0%)	p=0.0279
Kamalapurkar [11]	2014	84		1/60 (1.7%)	4/24 (16.7%)	p=0.006
Wright [10]	2015	445	7/92 (7.0%)	31/121 (25.6%)	9/26 (34.6%)	p=0.001
Ambe [13]	2015	138	5/79 (6.3%)	5/33 (15.2%)	9/26 (34.6%)	p=0.001
Amirthalingam [12]	2016	149	2/84 (2.4%)	6/49 (12.2%)	0/16 (0%)	p=0.03

Table 5 Complications (Morbidities)

References	Year	N	Grade I	Grade II	Grade III	
Cheng [44]	2014	103	3/31 (9.7%)	7/25 (28.0%)	9/20 (45.0%)	p<0.05
Wright [10]	2015	445	4/137 (2.9%)	6/191 (3.1%)	13/117 (11.1%)	p=0.003
Ambe [13]	2015	138	7/79 (8.9%)	5/33 (15.2%)	12/26 (46.2%)	p=0.01

Table 6 Survival analysis of 30-day mortality in patients with Grade III AC**

		Survivor (n=591)	Non-survivor (n=20)	Univariate p-value	Multivariate p-value	odds ratio	95%CI
Charlson Comorbidity Index							
	0 0~5	304	7	0.148	0.380		
	1 6≤	287	13				
Jaundice	0 -	477	9	<0.01	<0.01	6.470 (2.446 - 17.110)	
	1 +	114	11				
Neurological	0 -	518	12	<0.01	<0.01	4.346 (1.640 - 11.515)	
	1 +	73	8				
Respiratory	0 -	528	13	<0.01	<0.01	5.843(2.052 – 16.635)	
	1 +	63	7				

** Data from Endo et al.¹⁴

Table 7 TG18/TG13 Severity assessment criteria for acute cholecystitis**Grade III (Severe) acute cholecystitis**

“Grade III” acute cholecystitis is associated with dysfunction of any one of the following organs/systems

1. Cardiovascular dysfunction (hypotension requiring treatment with dopamine $\geq 5\mu\text{g}/\text{kg}$ per min, or any dose of Norepinephrine)
2. Neurological dysfunction decreased level of consciousness
3. Respiratory dysfunction $\text{PaO}_2/\text{FiO}_2$ ratio < 300
4. Renal dysfunction Oliguria, creatinine $> 2.0\text{mg}/\text{dl}$
5. Hepatic dysfunction $\text{PT-INR} > 1.5$
6. Hematological dysfunction Platelet count $< 100,000/\text{mm}^3$

Grade II (Moderate) acute cholecystitis

“Grade II” acute cholecystitis is associated with any one of the following conditions.

1. Elevated WBC count ($> 18000/\text{mm}^3$)
2. Palpable tender mass in the right upper abdominal quadrant
3. Duration of complaints $> 72\text{h}^{\text{a}}$
4. Marked local inflammation (gangrenous cholecystitis, pericholecystic abscess, hepatic abscess, biliary peritonitis, emphysematous cholecystitis)

(a: Laparoscopic surgery should be performed within 96h of the onset of acute cholecystitis)

Grade I (Mild) acute cholecystitis

“Grade I” acute cholecystitis does not meet the criteria of “Grade III” or “Grade II” acute cholecystitis. It can also be defined as acute cholecystitis in a healthy patient with no organ dysfunction and mild inflammatory changes in the gallbladder, making cholecystectomy a safe and low-risk operative procedure.

Cited from Ref. [5]

The TG13 severity assessment criteria of acute cholecystitis was judged from numerous validation studies as useful indicators in clinical practice and adopted as TG18 severity assessment criteria without any modification.

Fig. 1 Forest plot

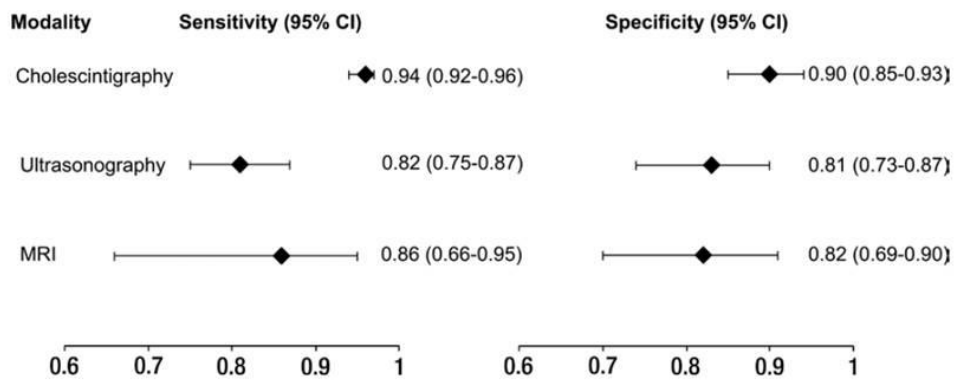


Fig. 2 Typical ultrasound images of acute cholecystitis

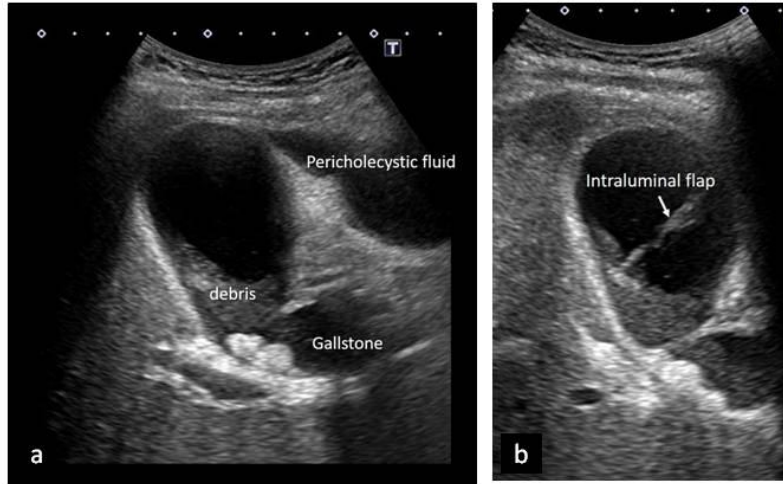


Fig. 3 Typical ultrasound images of acute cholecystitis

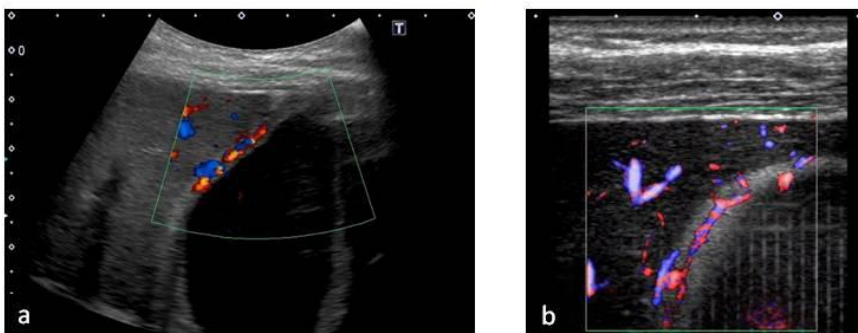


Fig. 4 Typical MR images of acute cholecystitis comparing contrast-enhanced CT

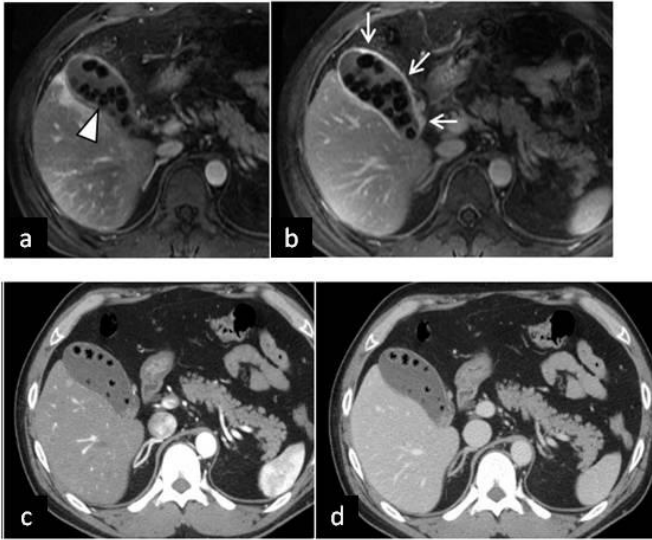


Fig. 5 Typical MR images and MRCP of acute cholecystitis

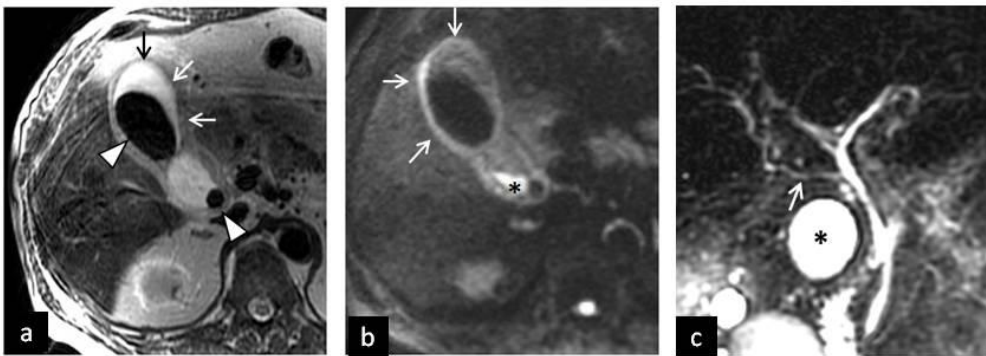


Fig. 6 Typical CT images of gangrenous cholecystitis

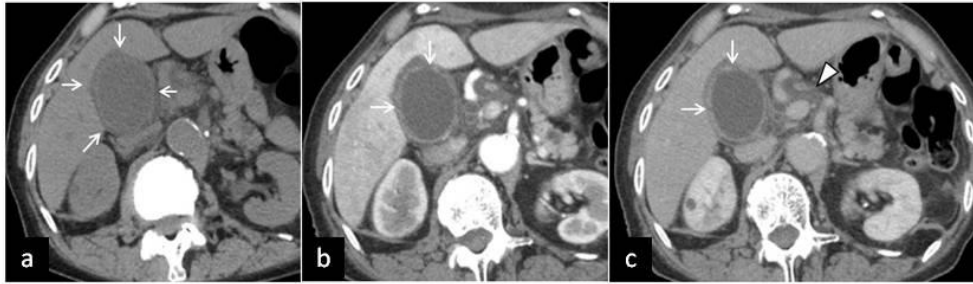


Fig. 7 Typical CT, US, and MRI findings of gangrenous cholecystitis

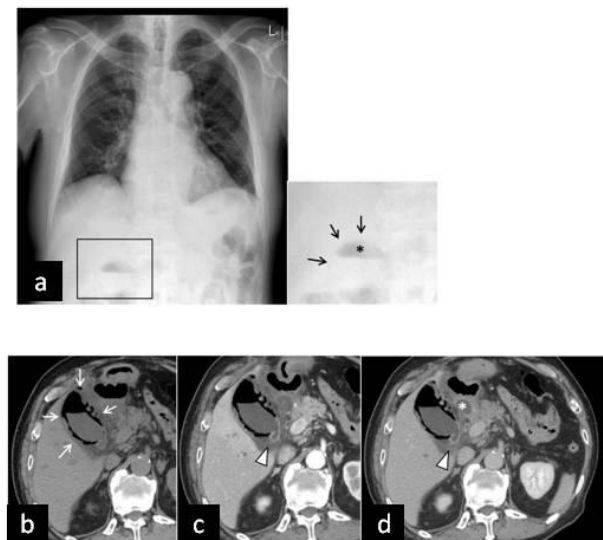


Fig. 8 Public hearing final voting outcome

