



An Abnormal Cerebellar Network in Children with Autistic Spectrum Disorder: A Morphometric Study

Edoardo Pappaianni¹, Roma Siugzdaitė² and Alessandro Grecucci¹

¹Department of Psychology and Cognitive Sciences, University of Trento, Trento, Italy

²Experimental Psychology Department, Faculty of Psychology and Pedagogical Sciences, Ghent University, Ghent, Belgium

*Corresponding author: Pappaianni E, Department of Psychology and Cognitive Sciences, University of Trento, Trento, Italy, Tel: +39-3475956454; E-mail: edoardo.pappaianni@studenti.unitn.it

Received date: 04 May 2016; Accepted date: 30 May 2016; Published date: 06 June, 2016

Copyright: © 2016 Pappaianni E, et al. This is an open-access article distributed under the terms of the Creative Commons Attribution License, which permits unrestricted use, distribution, and reproduction in any medium, provided the original author and source are credited.

Abstract

Autism is a neurodevelopmental disorder characterized by poor social abilities, communication deficiency and restricted behavioural patterns. Recently, scholars started to consider the possibility of detecting biological markers for better and faster diagnosing autism. This problem has been approached from different perspectives considering biochemical, neurophysiological, and neuroanatomical markers. Following this perspective, our intent was to investigate whether a structural brain signature of autism can be detected in children by using a whole brain morphological analysis. To this aim, we selected 43 male children with autistic spectrum disorder and 46 male controls, matched for age. Structural brain images (T1 image), intelligence scores (Full IQ, Verbal IQ, Performance IQ), and Autism Diagnostic Observation Schedule (ADOS) scores were considered for analyses. Source-Based Morphometry, a multivariate method based on Independent Component Analysis to detect maximally independent cortical networks of gray matter differences was applied to autistic and control brains. Results showed a statistically different network between ASD children and controls, including several cerebellar regions (Inferior Semi-lunar lobule, Tuber, Uvula, Pyramis, Declive, Cerebellar Tonsil) and the Fusiform Gyrus, confirming, but, also expanding previous results. In addition, separate temporal, frontal, and parietal networks were found to be significantly correlated with the Stereotyped Behaviour ADOS scores. These morphologic differences may be particularly useful in paving the way for future objective methods to diagnose autism.

Keywords: Autism; Structural differences; Source based morphometry; Biological markers

Introduction

Kanner defined autism as a disease characterized by three main deficits: poverty of social relations, communication deficiency and behavioural stereotypy with restricted interests. Recently, the Diagnostic and Statistical Manual of Mental Disorders, Fifth Edition (DSM 5, 2013), included the diagnosis of autism spectrum disorder (ASD) inside the neurodevelopmental disorders, building on the fact that this pathology seems to have a neurobiological substrate. Indeed, scientific research provided growing evidence that autism may be associated with specific neurological and biological markers. One day such biomarkers could help clinicians making earlier and more objective diagnosis. In fact, autism is characterized by a large heterogeneity of symptomatic and phenotypical manifestations that make a diagnosis based on observable signs very difficult [1-3]. Moreover, very often these signs appear at a late stage. The timing of the diagnosis of autism is fundamental. According to Lord and colleagues, autism could be diagnosed from about 18 months of age [4,5]. However, in the vast majority of cases such diagnosis is not done before of an age of 5-6 years, and this is probably due to the lack of objective markers. Earlier detection of autism can lead to better responses to interventions [5,6]. Recently there is a growing interest among clinicians and scholars to find the possibility of isolating objective biological markers for autism [6,7]. The problem has been approached from different perspectives: behavioral, biochemical, neuroanatomical, neurophysiological, immunological, and even

hormonal. While some biochemical biomarkers have been clearly identified, research is now focused on the possibility of finding genetic, metabolic and neurological markers [8]. About the neurological markers, some encouraging data is emerging. For example, Bosl et al. [9], showed abnormal EEG patterns in babies between 6 and 24 months with histories of autism in family. Authors suggest these patterns may point out a functional endophenotype related to ASD risk. In another study, researchers investigated plasticity in motor cortex under a low-intensity repetitive transcranial magnetic stimulation (rTMS) in young ASD. The results showed a greater reduction in the amplitude of motor evoked potentials in the diseased group compared to those of typical controls 20 min after stimulation [10]. This result may indicate a marker of cortical plasticity to be used in the diagnosis of autism [10]. Functional and structural magnetic resonance imaging (MRI) studies, described a series of abnormalities in the autistic brain. Among others, differences were found in the cerebellum (abnormal grey matter thickness compared to typical subjects), in the amygdala (abnormal constant activation in the first years), larger right volume of amygdala associated with difficulties and criticality in social and communication [2,8,11,12]. More recently, Hyde et al. [11] found several brain regions differences in grey matter between autistic and control individuals: the Inferior Frontal Cortex, Superior Temporal Sulcus, Cingulate Gyrus, Middle Occipital Gyrus, Fusiform Gyrus, and Inferior Parietal Lobule.

One problem with these results was that no whole brain analyses were carried out, thus resulting in partial and puzzling findings. Only recently, Grecucci and colleagues (in prep) used a novel approach to structural MRI data analysis called Source-Based Morphometry (SBM), that is a multivariate method to detect activation patterns of

gray matter distributed over several large and independent cortical components [13,14]. With this methodology, Grecucci found abnormalities in large temporal, frontal and cerebellar networks in adult autistics (age 18-39) as compared with controls [13].

Building from Grecucci's work, our intent was to extend the previous results to younger autistic individuals using the same whole brain approach. The relevance of the present study stems from the fact that if these markers are visible at a younger age, they may be used in the near future by clinicians to diagnose autism at an earlier stage.

Methods

43 male subjects with autistic spectrum disorder (mean age=9.84; SD=1.24) and 46 male controls (mean age=10.03; SD=1.38), were selected from Autism Brain Imaging Data Exchange (ABIDE) database. Since our interest in the present study was on children, the age of the samples ranged between 6 and 12 years old. We considered

only subjects with no artifactual MRI images and complete cognitive tests scores. Beside structural magnetic resonance images (T1 image), intelligence scores (Full IQ, Verbal IQ, Performance IQ) derived from the Wechsler Abbreviated Scale of Intelligence (WASI), the Differential Ability Scales (DAS), and the Wechsler Intelligence Scale for Children (WISC) were considered. In addition, we considered the Autism Diagnostic Observation Schedule (ADOS) scoring for autistic sample (specifically Social, Communication and Repetitive Behavior scores) only for the ASD group. All demographic informations are presented in Table 1. Data were chosen from four different research centers, including NYU Langone Medical Center, University of California in Los Angeles, Yale Child Study Center, School of Medicine in University of Pittsburg. The scanners were used from the same manufacturer (e.g. 3T Siemens TrioTim, Siemens Allegra). All information is available on ABIDE database website (http://fcon_1000.projects.nitrc.org/indi/abide/).

	ASD	CONTROLS	p value
Subjects	43	46	
Age	9.84 (1.25)	10.03 (1.39)	0.3353
Full IQ	108.14 (16.40)	111.06 (13.74)	0.4101
Verbal IQ	103.74 (14.18)	111.34 (12.9)	0.0123*
Performance IQ	111.72 (18.50)	108.13 (14.05)	0.2801
ADOS Communication	3.37 (1.52)		
ADOS Social	7.74 (2.72)		
ADOS Stereotyped behaviour	2.55 (1.51)		
ADOS Total	11.16 (3.84)		

Table 1: Demographic information.

Source Based Morphometry Analysis

SBM, a multivariate approach useful to identify automatic voxels composition or activation pattern in the brain, was applied to structural images. Although often used with functional data, an independent component analysis approach applied to structural data can be very useful in identifying grey matter patterns in a whole brain network perspective [14]. SPM12 software (<http://www.fil.ion.ucl.ac.uk/spm/software>) and dedicated toolboxes were used. After the initial check of data quality (in order to avoid critical artefacts as head-motion effect, ghosting, stripes that could potentially affect the results), images were segmented in grey matter, white matter and cerebrospinal fluid. Following Ashburner and Friston [15], alignment and normalization to MNI space with smoothing (full-width at half maximum of Gaussian smoothing kernel [8, 8, 8]) was then applied. After pre-processing, images were ready to be analyzed with SBM. In order to implement SBM, Independent Component Analysis (ICA) was applied. ICA breaks up the mixed signal coming from images of both groups together, recognizing maximally spatially independent sources revealing patterns of variation that occur in

structural MRI images automatically. GIFT software (<http://mialab.mrn.org/software/gift>) was used to compute ICA applying Infomax algorithm with ICASSO method [16,17]. We then performed two sample t-test on loading scores to identify sMRI differences between the two groups for every component. Moreover, we looked for correlations between components and cognitive tests' scores (in addition to ADOS scores for autistic children).

Results

No differences were found in age ($t(88)=1.98$, $p=0.335$), Full IQ ($t(88)=1.98$, $p=0.410$), or Performance IQ ($t(88)=1.99$, $p=0.280$) between groups. Only Verbal IQ resulted significantly different between groups ($t(88)=1.98$, $p=0.012$). Verbal and language difficulties characterizing autistic spectrum legitimize this diversity in the two samples. ICA returned 16 Independent Components (Figure 1). Notably the number of components to look for was suggested by the GIFT toolbox based the well-known Akaike's information criterion and not selected based on a priori knowledge.

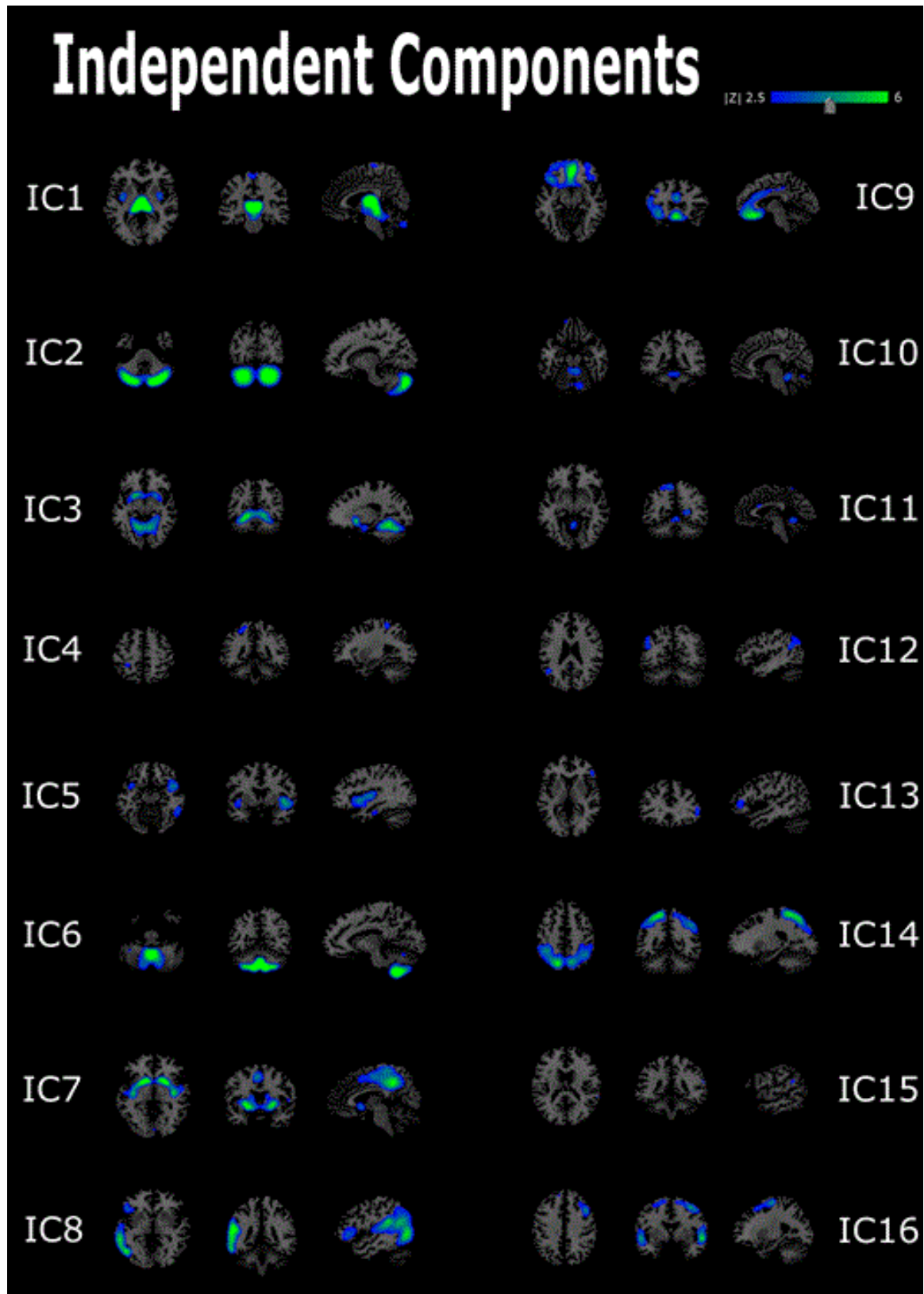


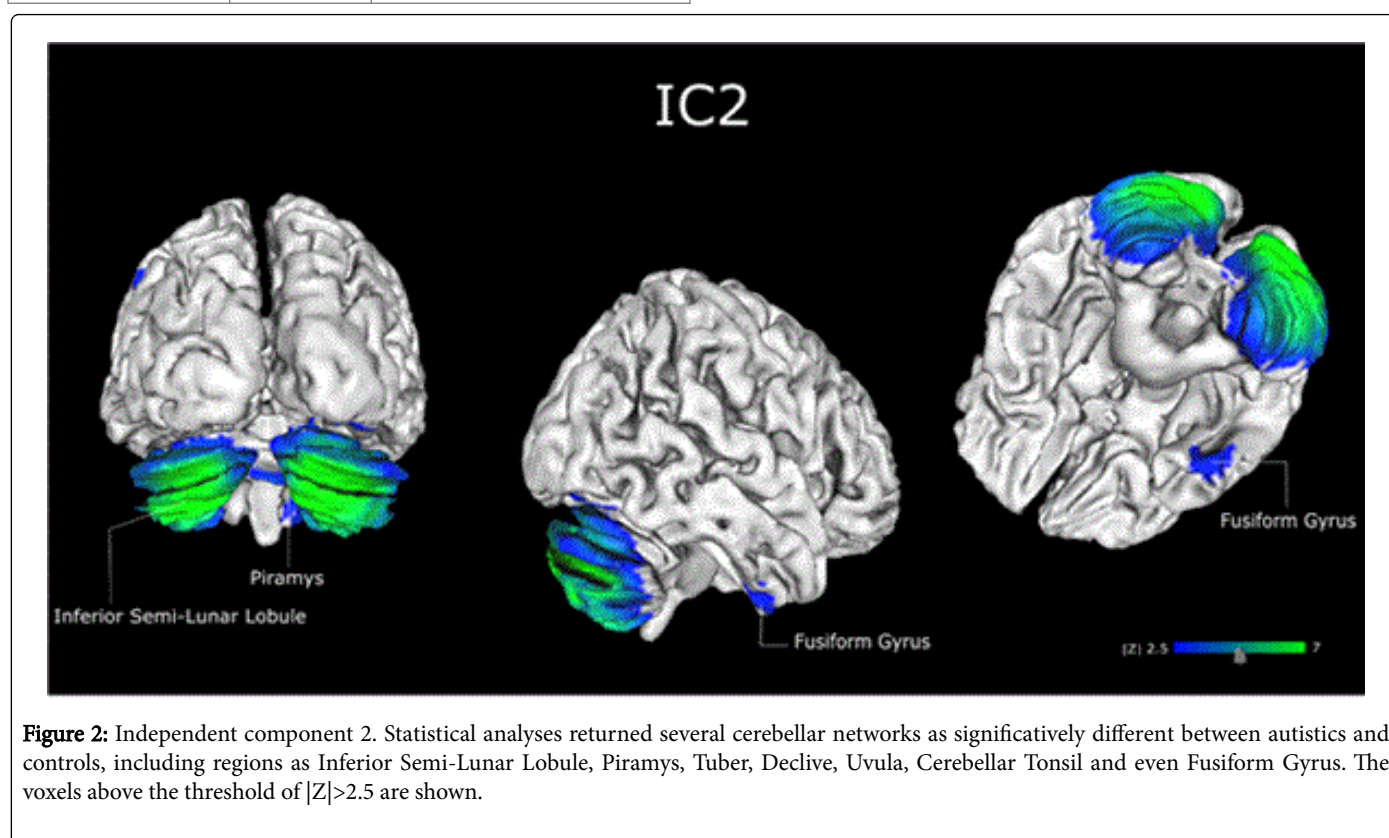
Figure 1: Source-based morphometry results. Sources resulted by SBM. The voxels above the threshold of $|Z| > 2.5$ are shown. Morphometrical analysis showed 16 Independent Components for both groups taking together.

Only IC2 resulted to be significantly differed between groups ($p=0.0493^*$). This network included several cerebellar regions: Tuber, Pyramis, Inferior Semi-Lunar Lobule showed the widest extension at the cortical level, but also a small portion of the right Fusiform Gyrus. Although essentially bilateral, these activations resulted a bit more intense on the right hemisphere (Figure 2). Specific details about IC2's composition are available in Table 2.

Area	L/R volume (cc)	Max Value MNI (x, y, z) L/R
Tuber	3.1/3.3	7.5 (-24, -79, -28)/8.7 (24, -79, -28)
Uvula	2.4/3.3	7.2 (-28, -77, -26)/8.6 (19, -80, -26)
Pyramis	3.5/3.8	7.3 (-19, -80, -28)/8.2 (25, -76, -30)

Declive	2.4/4.2	6.2 (-22, -80, -21)/7.4 (19, -80, -21)
Inferior Semi-Lunar Lobule	4.2/4.8	6.8 (-30, -75, -35)/6.8 (30, -73, -35)
Cerebellar Tonsil	1.6/2.4	5.6 (-39, -64, -32)/5.9 (36, -64, -32)
Fusiform Gyrus	0.0/0.1	- /3.5 (28, -85, -18)

Table 2: Talairach labels for regions statistically different in autistic children compared with controls. Talairach coordinates for the left and right hemisphere are shown. Volume of each area is presented in cubic centimeters (cc). Finally, MNI coordinates for each area are shown.



ICA returned other interesting components that showed mild statistical trends between groups. In particular, IC6 ($p=0.0794$) showed differences again in cerebellar regions such as: Inferior-Semi Lunar Lobule and Cerebellar Tonsil, bilaterally. This confirms the role of Cerebellum as a crucial region for autism, confirming previous results with older ASD individuals [13]. IC8 ($p=0.0781$), showed differences in the left Middle Temporal Gyrus, Superior Temporal Gyrus, Insula and Inferior Temporal Gyrus. Figure 1 for graphical details of these components.

We also checked for correlations with IQ and ADOS scores. We found a positive correlation ($r=0.3820$; $p=0.0115$) between IC5 (that includes Insula, Superior Temporal Gyrus, Inferior Frontal Gyrus, Extra-Nuclear, Inferior Temporal Gyrus, Middle Temporal Gyrus, Sub-Gyral, Fusiform Gyrus), and Stereotyped Behavior ADOS score.

Discussion

In this study, we used Source-Based Morphometry to investigate the presence of abnormal neural circuits in children with autistic spectrum disorder (age 6-12) compared with typical development peers. T1 MRI images of 89 male subjects (43 diseased and 46 control subjects) from ABIDE online database were considered [18]. SBM, a multivariate approach was used to study grey matter differences between samples [14]. This method is based on the detection and decomposition of mixed signal coming from structural images by the Independent Components Analysis (ICA). Because of that, SBM is a powerful tool to detect dissimilarities in gray matter between subjects not in terms of regions of interest (as in other type of analysis like Voxel-Based Morphometry), but in terms of different networks. This data-driven approach allows us to make a wide-ranging reasoning not being anchored to regions of interest pre-selected before the analysis. Indeed, ICA works autonomously on the entire brain. There is no theory that

guides the analysis, rather, theory follows the analysis. This is a great advantage as compared to standard analyses (such as Voxel-based Morphometry) used in previous studies. In this way, a data-driven method is able to provide a way to gather signal information from different voxels so as to identify unpredictable patterns [14]. Results showed a significantly different independent component (IC2) between groups. IC2 included a large network in the cerebellum, bilaterally. The involvement of the cerebellum as a neural region involved in autism is not new. As already mentioned, Amaral et al. considered cerebellum as compromised in autism: in post-mortem studies, the 79% of examined autistics' cerebellums showed a lower density of Purkinje cells [19-22]. In their review paper, authors pointed out that cerebellum may be generally larger in autistic than healthy people, although this difference can be justified by the stated increase in brain volume typical for this disorder [23,24]. There is evidence on the involvement of cerebellum in many cognitive functions, as it is widely interconnected with the thalamus and with several cortical regions [25-27]. Nowadays, cerebellum is strongly considered engaged in an umbrella of cognitive functions such as language, auditory processing, visuospatial perception, verbal memory, sequencing and executive functions [25,27,28]. In light of these evidences, we may hypothesize that cerebellar network found in our autistic sample could be directly involved in the phenotypic and symptomatic manifestations of this disorder. Although we did not find any correlation between IC2 and IQ nor ADOS scores, a recent study showed that cerebellar deficits correlated with social and communication deficits and stereotyped behaviour [29]. In the same study, grey matter volume in Right Crus I/II of cerebellar regions resulted to be smaller than in controls, and predicted the impaired performance in ADOS test. Authors found also differences between groups in several cerebellar parts as right Crus 1/2, Vermis VIIIA, Vermis VIIIB, Vermis VIII B, Vermis IV and others [29]. We also found a second cerebellar network (IC6), including the Inferior Semi-Lunar Lobule and the Cerebellar Tonsil, that showed a trend toward significance further confirming the role of cerebellar regions in autism. IC8, that included wide left temporal circuit with additional small areas in frontal, occipital and parietal lobes showed again a trend. Notably, a similar temporal-frontal circuit was found by Grecucci et al. [13] (in prep) with older ASD individuals, thus confirming the role of wide cortical networks in ASD pathophysiology, and the importance of a distributed whole brain approach when studying autism. Finally, we found an interesting correlation between a fronto-temporal network (IC5, including the right Insula, Superior Temporal Gyrus, Inferior Frontal Gyrus, Extra-Nuclear, Inferior Temporal Gyrus, Middle Temporal Gyrus, Sub-Gyral, Fusiform Gyrus), and ADOS Stereotype Behaviour scores [13]. This large network may integrate emotional aspects (limbic areas as insula in temporal lobe) with planning and organizational ones (frontal regions), deficient in individuals suffering from ASD. One hypothesis is that large networks of areas contribute to social and behavioral deficits displayed by ASD individuals and the need for a more global approach when studying this pathology.

Although these results can be considered as preliminary, they clearly stress the importance of the cerebellum as a key region for understanding ASD. We expanded previous results by showing that abnormalities in this region appear earlier than showed in previous studies with older ASD individuals [13]. Future studies will explore the functional aspects of this region and how it is specifically associated with the deficits presented by autistics. Moreover, we provided evidence of the usefulness of a whole brain approach such as SBM as compared to previous region specific approaches.

Acknowledgement

Alessandro Grecucci has been supported by a grant awarded by the The Neuropsychanalysis Foundation, New York, USA.

References

1. Hyde KL, Samson F, Evans AC, Mottron L (2010) Neuroanatomical differences in brain areas implicated in perceptual and other core features of autism revealed by cortical thickness analysis and voxel-based morphometry. *Human Brain Mapping* 31: 556-566.
2. Amaral DG, Schumann CM, Nordahl CW (2008) Neuroanatomy of autism. *Trends Neurosci* 31: 137-145.
3. Stanfield AC, McIntosh AM, Spencer MD, Philip R, Gaur S, et al. (2008) Towards a neuroanatomy of autism: a systematic review and meta-analysis of structural magnetic resonance imaging studies. *Eur Psychiatry* 23: 289-299.
4. Lord C, Risi S, DiLavore PS, Shulman C, Thurm A, et al. (2006) Autism from 2 to 9 years of age. *Arch Gen Psychiatry*. 63: 694-701.
5. Dawson G, Jones EJ, Merkle K, Venema K, Lowy R, et al. (2012) Early behavioral intervention is associated with normalized brain activity in young children with autism. *J Am Acad Child Adolesc Psychiatry* 51: 1150-1159.
6. Small DM, Pelphrey K (2015) Autism spectrum disorder: Sniffing out a new biomarker. *Current Biology*. 25: R674-R676.
7. Wang A, Liang S, Wang M, Gao J, Sun C, et al. (2015) Potential serum biomarkers from a metabolomics study of autism. *J Psychiatry Neurosci* 22: 140009.
8. Ruggeri B, Sarkans U, Schumann G, Persico AM (2014) Biomarkers in autism spectrum disorder: The old and the new. *Psychopharmacology (Berl)* 231: 1201-1216.
9. Bolduc ME, Du Plessis AJ, Sullivan N, Khwaja OS, Zhang X, et al. (2011) Spectrum of neurodevelopmental disabilities in children with cerebellar malformations. *Dev Med Child Neurol* 53: 409-416.
10. Pedapati EV, Gilbert DL, Erickson CA, Horn PS, Shaffer RC, et al. (2016) Abnormal cortical plasticity in youth with autism spectrum disorder: A transcranial magnetic stimulation case-control pilot study. *J Child Adolesc Psychopharmacol*.
11. Sparks BF, Friedman SD, Shaw DW, Aylward EH, Echelard D, et al. (2002) Brain structural abnormalities in young children with autism spectrum disorder. *Neurology* 59: 184-192.
12. Mundon J, Dawson G, Abbott R, Faja S, Webb SJ, et al. (2006) Amygdalar volume and behavioral development in autism. *Arch Gen Psychiatry* 63: 686-693.
13. Grecucci A, Rubicondo D, Siugzdaite R, Job R (2016) Uncovering the social deficits in the autistic brain. A Source-Based Morphometric study.
14. Xu L, Groth KM, Pearson G, Schretlen DJ, Calhoun VD (2009) Source-based morphometry: The use of independent component analysis to identify gray matter differences with application to schizophrenia. *Human Brain Mapping* 30: 711-724.
15. Ashburner A, Friston KJ (2000) Voxel-based morphometry-The methods. *Neuroimage* 11: 805-821.
16. Bell AJ, Sejnowski TJ (1995) An information-maximization approach to blind separation and blind deconvolution. *Neural Comput* 7: 1129-1159.
17. Lee TW, Girolami M, Sejnowski TJ (1999) Independent component analysis using an extended infomax algorithm for mixed subgaussian and supergaussian sources. *Neural Comput* 11: 417-441.
18. Di Martino A, Yan CG, Li Q, Denio E, Castellanos FX, et al. (2014) The autism brain imaging data exchange: towards a large-scale evaluation of the intrinsic brain architecture in autism. *Mol Psychiatry* 19: 659-667.
19. Bailey A, Luthert P, Dean A, Harding B, Janota I, et al. (1998) A clinicopathological study of autism. *Brain* 121 : 889-905.
20. Kemper TL, Bauman ML (1993) The contribution of neuropathologic studies to the understanding of autism. *Neurol Clin* 11: 175-187.

-
21. Ritvo ER, Freeman BJ, Scheibel AB, Duong T, Robinson H, et al. (1986) Lower purkinje cell counts in the cerebella of four autistic subjects: Initial findings of the UCLA-NSAC Autopsy Research Report. *Am J Psychiatry* 143: 862-866.
 22. Yip J, Soghomonian JJ, Blatt GJ (2007) Decreased GAD67 mRNA levels in cerebellar Purkinje cells in autism: Pathophysiological implications. *Acta Neuropathol* 113: 559-568.
 23. Minshew NJ, Sweeney JA, Bauman ML, Webb SJ (2005) Neurologic aspects of autism. In *Handbook of Autism and Pervasive Developmental Disorders*. John Wiley & Sons.
 24. Hardan AY, Minshew NJ, Harenski K, Keshavan MS (2001) Posterior fossa magnetic resonance imaging in autism. *J Am Acad Child Adolesc Psychiatry* 40: 666-672.
 25. Hampson DR, Blatt GJ (2015) Autism spectrum disorders and neuropathology of the cerebellum. *Front Neurosci* 9: 420.
 26. Fatemi SH, Aldinger KA, Ashwood P, Bauman ML, Blaha CD, et al. (2012) Consensus paper: pathological role of the cerebellum in autism. *Cerebellum* 11: 777-807.
 27. Broussard DM (2014) *The cerebellum: Learning movement, language, and social skills*. John Wiley & Sons, Chichester.
 28. Bolduc ME, De Plessis AJ, Sullivan N, Guizard N, Zhang X, et al. (2012) Regional cerebellar volumes predict functional outcome in children with cerebellar malformations. *Cerebellum* 11: 531-542.
 29. D'Mello AM, Crocetti D, Mostofsky SH, Stoodley CJ (2015) Cerebellar gray matter and lobular volumes correlate with core autism symptoms. *Neuroimage Clin* 7: 631-639.