



Cyber-shot, a handy digital camera for maxillofacial surgery

著者名	SASAKI Ryo, WATANABE Yorikatsu, MATSUMINE Hajime, OKAMOTO Toshihiro, ANDO Tomohiro
journal or publication title	Plastic and reconstructive surgery. Global open
volume	2
number	8
page range	e191
year	2014
URL	http://hdl.handle.net/10470/00032164

doi: 10.1097/GOX.000000000000102(<https://doi.org/10.1097/GOX.000000000000102>)

Cyber-shot, a Handy Digital Camera for Maxillofacial Surgery

Ryo Sasaki, DDS, PhD

Department of Oral and Maxillofacial Surgery
Tokyo Women's Medical University,
School of Medicine
Shinjuku-ku
Tokyo, Japan
Institute of Advanced Biomedical
Engineering and Science
Tokyo Women's Medical University
Shinjuku-ku
Tokyo, Japan

Yorikatsu Watanabe, MD, PhD

Department of Plastic and Reconstructive Surgery
Tokyo Metropolitan Police Hospital
Nakano-ku
Tokyo, Japan
Institute of Advanced Biomedical
Engineering and Science
Tokyo Women's Medical University
Shinjuku-ku
Tokyo, Japan

Hajime Matsumine, MD, PhD

Department of Plastic Surgery
Tokyo Women's Medical University School of Medicine
Shinjuku-ku
Tokyo, Japan
Institute of Advanced Biomedical
Engineering and Science
Tokyo Women's Medical University
Shinjuku-ku
Tokyo, Japan

Toshihiro Okamoto, DDS, PhD

Tomohiro Ando, DDS, PhD

Department of Oral and Maxillofacial Surgery
Tokyo Women's Medical University,
School of Medicine
Shinjuku-ku
Tokyo, Japan

Sir:

Clinical and surgical photographs are valuable for maxillofacial surgeons. Photographs can help

Copyright © 2014 The Authors. Published by Lippincott Williams & Wilkins on behalf of The American Society of Plastic Surgeons. PRS Global Open is a publication of the American Society of Plastic Surgeons. This is an open-access article distributed under the terms of the Creative Commons Attribution-NonCommercial-NoDerivatives 3.0 License, where it is permissible to download and share the work provided it is properly cited. The work cannot be changed in any way or used commercially.

Plast Reconstr Surg Glob Open 2014;2:e191; doi:10.1097/GOX.000000000000102; Published online 4 August 2014.

surgeons to review novel procedures performed and can be used to teach students and residents and prepare manuscripts. Taking photographs of the oral cavity requires specialized techniques, because the oral cavity is a narrow, deep, dark space. A conventional single-lens reflex camera with a ring flash can be used to take these photographs, but such cameras are large, heavy, and expensive. A conventional compact digital camera is light and affordable but does not have a suitable focusing distance for taking photographs of the oral cavity. We started using compact digital cameras from the Cyber-shot DSC-T30 and TX series (Sony, Tokyo, Japan) to take clinical, surgical, and experimental photographs in 2008.¹⁻⁵ We currently use the Cyber-shot DSC-TX30 (96.4×59.3×15.4 mm, 140 g, 18.2 megapixels, price approximately USD250; Sony) (Fig. 1). This camera is waterproof and shockproof and has passed a drop test from a height of 1.5 m. The camera is used with an exposure value of +0.7 and fill-in flash, and the operating lights turned off. To take photographs during surgical procedures, the surgeon holds the camera in one hand, which is covered by an extra sterile glove over the surgical glove and exposes the operative field with the other hand using a retractor (Fig. 2). The camera automatically focuses on the surgical site. The Cyber-shot DSC-TX30 includes an LED ring flash, which is not useful for taking photographs of the oral cavity, but it is useful for taking photographs of surgical specimens from as little as 10 mm away, without causing shadows. No other settings are



Fig. 1. The Cyber-shot DSC-TX30 camera. The surgeon holds the camera in one hand, which is covered by an extra sterile glove over the surgical glove.

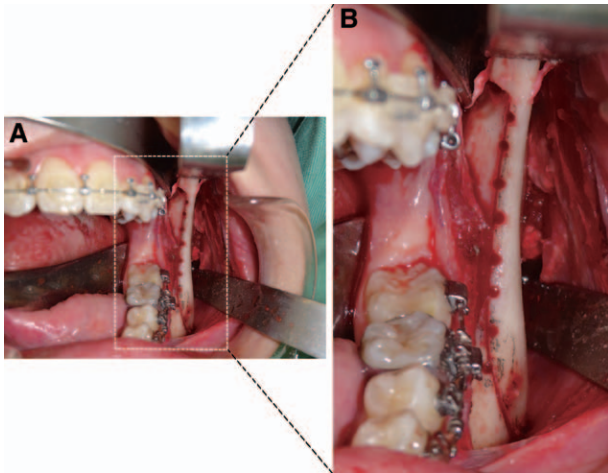


Fig. 2. A, Surgical photograph of a sagittal split ramus osteotomy, taken with the Cyber-shot DSC-TX30 digital camera (programmed settings: exposure value, +0.7; spot metering; fill-in flash; ISO, 80; white balance, auto). B, Magnified view of the area indicated by the rectangle.

necessary for taking photographs. This camera can also record approximately 30 minutes of full high-definition video (1920 × 1080 pixels, video format: AVCHD). Surgeons can record a clear surgical video using only one hand, because the camera includes an image stabilization system.

We were able to take clear surgical photographs of the face and neck, mandible,¹ maxilla,² zygoma, orbit, hard palate, tongue, buccal mucosa,³ floor of the mouth, nasal septum, hypoglossal nerve, and facial nerve using the Cyber-shot camera. Use of this camera may reduce interruptions during surgery compared with use of a conventional single-lens reflex camera with a ring flash. We believe that clear photographs are best taken by the surgeon rather than by observers or residents.

Correspondence to Dr. Sasaki

Department of Oral and Maxillofacial Surgery
Tokyo Women's Medical University,
School of Medicine
8-1 Kawada-cho
Shinjuku-ku, Tokyo 162-8666
Japan
sasaki@oms.twmu.ac.jp

ACKNOWLEDGMENTS

We thank Dr. Kaori Agawa (Tokyo Metropolitan Police Hospital) for giving the first author (R.S.) the Cyber-shot DSC-T30 that she previously used, which took good surgical photographs, and Dr. Norio Ueno for his editorial assistance in preparing this manuscript.

DISCLOSURE:

The authors have no financial interest to declare in relation to the content of this article. The Article Processing Charge was paid for by the Department of Oral and Maxillofacial Surgery, Tokyo Women's Medical University, School of Medicine, Tokyo, Japan.

REFERENCES

1. Sasaki R, Watanabe Y, Ando T, et al. Two stage enucleation and deflation of a large unicystic ameloblastoma with mural invasion in mandible. *Craniomaxillofac Trauma Reconstr.* 2013; In press.
2. Sasaki R, Takanashi N, Chigono T. Transplantation of a tooth involved in dentigerous cyst. *Eur J Paediatr Dent.* 2012;13:342-344.
3. Sasaki R, Yamato M, Takagi R, et al. Punch and spindle-shaped biopsies for collecting oral mucosal tissue for the fabrication of transplantable autologous epithelial cell sheets. *J Biomed Mater Res A.* 2012;100:2849-2854.
4. Sasaki R, Matsumine H, Watanabe Y, et al. Surgical anatomy of the hypoglossal nerve for facial nerve reconstruction research in swine. *J Reconstr Microsurg.* 2013; In press.
5. Sasaki R, Matsumine H, Watanabe Y, et al. Anesthesia for reconstructive surgical research in rat face. *J Reconstr Microsurg.* 2013;29:209-210.