

From Old to New Cardiovascular Complications in Ankylosing Spondylitis

Fabiola Atzeni MD PhD¹, Marco Corda MD², Piercarlo Sarzi-Puttini MD³, Francesco Caso MD PhD⁴ and Maurizio Turiel MD⁵

¹IRCCS Galeazzi Orthopedic Institute, Milan, Italy

²Cardiology Unit, Brotzu Hospital, Cagliari, Italy

³Rheumatology Unit, Sacco University Hospital, Milan, Italy

⁴Rheumatology Unit, Department of Clinical Medicine and Surgery, University Federico II, Naples, Italy

⁵Cardiology Unit, IRCCS Galeazzi Orthopedic Institute, Milan, Italy

KEY WORDS: cardiovascular risk, heart, spondyloarthritis (SpA), ankylosing spondylitis (AS)

IMAJ 2017; 19: 506–509

The clinical course of ankylosing spondylitis (AS) is complicated by several extra-articular spondyloarthritis (SpA)-related manifestations (such as acute anterior uveitis, inflammatory bowel disease and psoriasis) and non-SpA-related manifestations (such as lung and cardiovascular). Cardiovascular involvement in AS is highly heterogeneous and may affect the pericardium, endocardium, cardiac muscle and valves, conduction system, coronary arteries, or large or small vessels of the systemic circulation, which may increase the risk of premature ischemic heart disease and stroke. The level and expression of cardiovascular involvement varies widely from the activity of the disease and the drugs used to treat the disease, which can aggravate or protect against cardiovascular disorders. The progress in imaging techniques makes it possible to identify atherosclerosis-related changes at their earliest stages. Cardiologists and rheumatologists should be fully aware of the increased cardiovascular risks of these patients in order to treat and prevent them.

Ankylosing spondylitis (AS) is a chronic inflammatory disease predominantly

This work was presented at the 5th Israel-Italy Meeting on Advances in Rheumatology and Autoimmunity, 15 December 2016 in Haifa, Israel, published in our previous issue, July 2017

involving the axial skeleton and is included in the family of inflammatory spondyloarthropathies (SpAs). The clinical course of the disease is complicated by several extra-articular manifestations subdivided into those that are SpA-related, such as acute anterior uveitis, inflammatory bowel disease and psoriasis, and those that are non-SpA-related, such as lung and cardiovascular involvement [1].

Several studies reported an increased overall mortality in AS as much as 1.6–1.9 times that of the general population, in addition to a higher mortality rate of 20–40% for circulatory or cardiovascular diseases [2]. A large population-based study, which included 21,473 AS patients and 86,606 controls living in Ontario, Canada, showed that vascular mortality was significantly higher in AS patients compared to the general population. Moreover, there was a 36% higher risk for vascular mortality when adjusted for baseline cardiovascular risk factors, hazard ratio (HR) 1.36, 95% confidence interval (CI) 1.13–1.65 [3]. When stratified according to gender, this risk was particularly significant among male subjects (HR 1.46, 95%CI 1.13–1.87). Compared to controls, patients with AS had a 60% higher risk of cerebrovascular mortality (HR 1.60, 95%CI 1.17–2.20) and a 35% higher risk for cardiovascular mortality (HR 1.35, 95%CI 1.07–1.70) [3]. The data confirm an increased risk of cardiovascular morbidity and mortality, which can only partially be explained by the high prevalence of traditional cardiovascular risk factors among patients with AS, and are mainly due to the immuno-mediated inflammatory pattern of

the diseases themselves and the potentially unfavorable cardiovascular and metabolic effects caused by the corticosteroidal and non-corticosteroidal anti-inflammatory drugs used to treat them. In a meta-analysis, no differences were found in terms of blood pressure, glucose levels and atherogenic index (the ratio of total cholesterol/HDL cholesterol) between AS patients and a control group [4], although an increased relative risk of metabolic syndrome (cluster of metabolic abnormalities including obesity, insulin resistance, glucose intolerance, hypertension, and dyslipidemia) was found in AS patients, relative risk (RR) 2.13, 95%CI 1.48–3.06 [4].

Non-steroidal anti-inflammatory drugs (NSAIDs) are the first choice of therapy in treating AS [5]. Although NSAIDs lead to cardiovascular risks, data from AS studies suggest a favorable cardiovascular risk profile of long-term NSAID use in addition to reducing pain and improving mobility. Clearly individual risk assessments including age and consideration of co-morbidities is required before making a decision on long-term NSAID use. Corticosteroid therapy is not recommended for treating AS patients [6], but data from other studies and registries showed that these patients (particularly those with the peripheral form) are treated with these drugs despite their adverse effects [7].

WELL-KNOWN CARDIOVASCULAR COMPLICATIONS

Aortitis and insufficiency of the aortic valve are among the most important and earli-

est defined cardiovascular manifestations of AS. AS can affect various segments of the aorta, particularly the ascending aorta [8]. Histologically, aortitis is defined by the presence of inflammatory infiltrates in the medial and/or intimal layers of the tissue. Inflammation may cause dilatation and reduced arterial elasticity. Dilatation of the proximal aorta along with the thickened cusps may cause valvular regurgitation in up to 20% of the patients [8]. Before the advent of echocardiography the estimated prevalence of aortic valve was approximately 1–10% [9]. Later studies using echocardiography provided a prevalence around 18–20% [10,11]. The explanation for aortitis is that the inflammation caused by AS is often located in the entheses, which are the attachments of tendons, ligaments, or joint capsules to bone or cartilage [1]. Enteses are regions of “wear and tear” where micro damage frequently occurs, followed by inflammation and new bone formation as a reparative. The attachment of the aortic cusps in the heart, with their central tendon-like fibrous core, shows some resemblance to entheses [1]. Like tendon insertions, the attachment points of the aortic cusps are also regions that are subject to mechanical stress followed by inflammation and repetitive mechanisms.

In general, many of the cases are sub-clinical but some of the patients may require surgical intervention. Longer disease duration and aging are likely to increase the aortic lesions. Combination of several factors, including higher disease activity, human

leukocyte antigen B27 (HLA-B27) positivity, and extra-spinal features such as peripheral arthritis, may predispose certain patients who are susceptible to aortic disease [10,11].

One of the well-known cardiac complications of AS is conduction system abnormalities. Chronic inflammation originating from the proximal aorta may extend into the membranous part of the interventricular septum and atrioventricular nodal area inducing several forms of arrhythmias and conduction blocks. When compared with the general population the most prevalent form of conduction blocks is atrioventricular, which is predominantly localized in the suprahisian region [12]. However, the sinoatrial node dysfunction, Wolff–Parkinson–White (WPW) syndrome, tachycardia, bradycardia, or interventricular conduction abnormalities have also been described [13]. The observed abnormalities seem to be more frequent among males, and HLA-B27 patients seem to be more susceptible, but these abnormalities are also found in women and HLA-B27 patients who are negative for AS [14]. Clinical manifestations may range from asymptomatic to severe, requiring a pacemaker.

With the use of echocardiography an increase of myocardial disease was found in AS. In particular, results showed that AS patients without cardiorespiratory symptoms, or known cardiac abnormalities, had diastolic left ventricular dysfunction, which is a precursor to heart failure. A possible explanation is that a systemic inflammation gradually damages the cardiomyocytes and

causes increased collagen deposition in the heart. Clinical significance of asymptomatic left ventricular diastolic dysfunction in AS is not yet entirely clear, but it has been reported in 10–50% of AS patients according to different studies [15]. Recently, Atzeni and colleagues [16] showed, using two-dimensional speckle tracking echocardiography (2D-STE) to assess end-systolic left ventricular longitudinal strain (ϵ), that AS patients with still negative traditional echocardiography parameters had impaired STE-measured myocardial, thus suggesting a myocardial alteration [16].

Finally, considering that the increased prevalence, although still unknown, of this complication that can lead to heart failure, we suggest developing prevention and treatment strategies for these patients.

RECENT CARDIOVASCULAR COMPLICATIONS

Recently, imaging techniques have made it possible to identify atherosclerosis-related changes at their earliest stages [17] [Figure 1, Figure 2]. Several invasive and non-invasive techniques are used to identify early arterial wall alterations. Intima-media thickness (IMT) of common carotid arteries (CCA) and assessment of flow-mediated dilatation (FMD) by ultrasound are the most widely used non-invasive methods. IMT of CCA is a reproducible marker of generalized atherosclerosis that allows for the evaluation of the earliest structural changes in the arterial wall. FMD is used to detect endothelial

Figure 1. Chronic total occlusion of left anterior descending artery

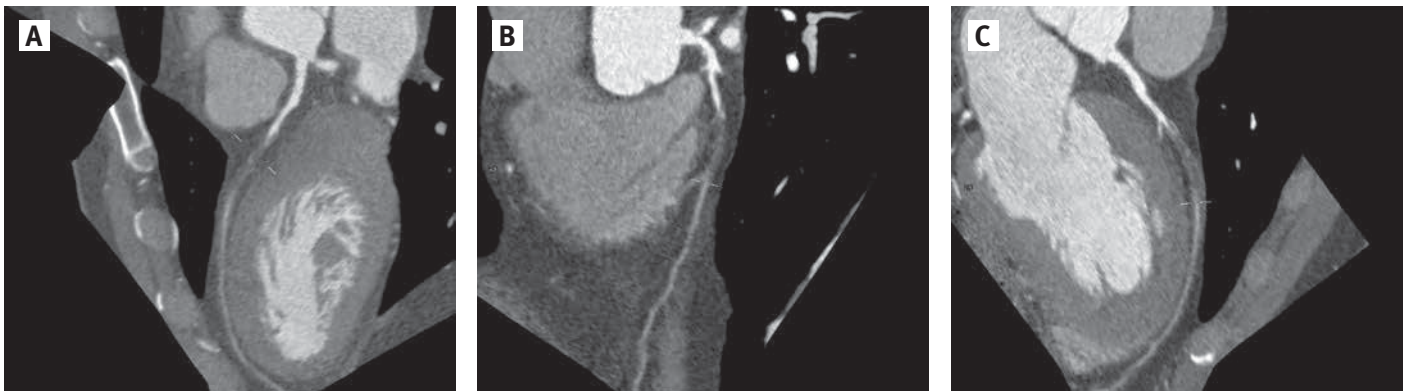
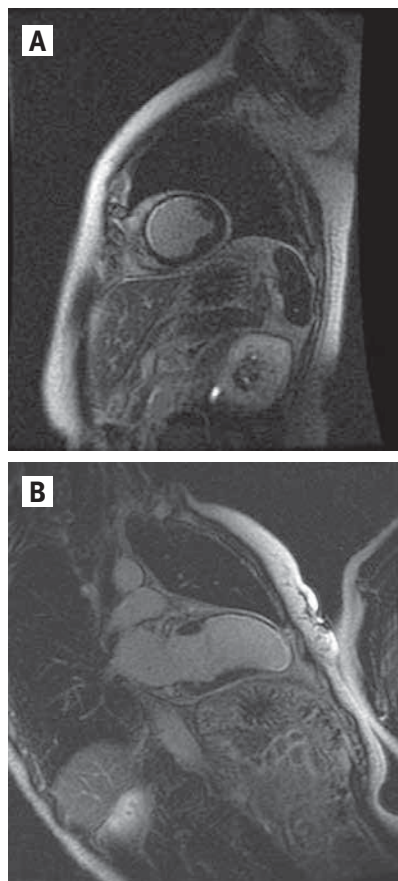


Figure 2. Previous anterior acute myocardial infarct



dysfunction, which precedes morphological changes and is believed to be the initial step in the development of atherosclerosis. Impaired endothelial function has been reported in various studies in AS. In one meta-analysis Mathieu et al. [4] analyzed six studies and reported an increased IMT in the AS group. Arida and co-authors [17] showed that carotid IMT, but not plaque burden, was significantly increased in AS compared to controls. AS without clinically evident cardiovascular disease has a high prevalence of subclinical vascular involvement. It is still not clear what physiopathological mechanisms underlie the relationship between systemic inflammation and increased cardiovascular risk as none of the many hypotheses that have been proposed has yet been fully confirmed.

From the point of view of everyday clinical practice, there is still uncertainty con-

cerning the need for screening asymptomatic patients for sub-clinical atherosclerosis or which target plasma lipid levels can be considered satisfactory in patients with AS. Furthermore, although it is already known that corticosteroids have undesirable effects on cardiovascular risk factors, the effects of methotrexate and sulphasalazine are favorable. Further evidence is needed concerning the impact of other drugs (particularly biological drugs) on the onset of cardiovascular co-morbidities. Although there is some research that shows a positive impact on vascular function, available data do not support a direct beneficial effect of anti-tumor necrosis factor (TNF) treatments on cardiovascular disease [16,18]. Based on the known role of inflammation in the pathogenesis of the atherosclerotic process, it can be extrapolated that systemic inflammatory disease has many and various effects on overall cardiovascular risk. A more atherogenous lipid profile, forced reduction in physical activity, activation and expression of cytokines and other molecules involved in plaque formation, coronary vasculitis, and cardiovascular and metabolic effects of the most widely prescribed medications can all synergistically worsen the risk of cardiovascular diseases. It is therefore possible that controlling inflammation medically can be cardioprotective, and early rehabilitation, optimally by controlling patient lipid levels, blood pressure and metabolic profiles, can reduce the effects of inflammation on the cardiovascular system. In addition, making use of effective and directed screening procedures can detect cardiovascular manifestations earlier.

The increasingly clearer association between AS and cardiovascular risk has been further highlighted by the recently published guidelines of the European Society of Cardiology, which has a specific section dedicated to preventing cardiovascular disease in patients with systemic autoimmune inflammatory diseases [19]. However, some important aspects of the clinical management of cardiovascular risk in patients with AS are still uncertain and not considered in the guidelines, including the screening of asymptomatic patients

for sub-clinical atherosclerosis and target plasma lipid levels. A recent post hoc analysis of two statin trials has found that the reduction to cardiovascular risk in patients with autoimmune diseases is comparable to that observed in patients with other conditions [20], but these findings need to be validated by controlled clinical trials to demonstrate unequivocally whether aggressively treating cardiovascular risk factors with the same targets as those recommended for patients with conditions of equivalent risk is also capable of reducing the number of events in patients with chronic inflammatory diseases.

CONCLUSIONS

In conclusion, it is particularly important that cardiologists and rheumatologists are fully aware of the increased cardiovascular risk of patients with AS, the precocity of the onset of cardiac involvement, the need for aggressive treatment of traditional risk factors, and the favorable or unfavorable role of the medications used to treat systemic inflammatory diseases.

Finally, considering the increased cardiovascular disease risk, we suggest developing prevention and treatment strategies for AS patients as well as guidelines and a standardized approach for cardiovascular examination and laboratory workup in routine clinical care of AS patients.

Correspondence

Dr. F. Atzeni

Rheumatology Unit, Sacco University Hospital, Via G. B. Grassi 74, 20157 Milan, Italy

Phone: (39-02) 3904-2489

Fax: (39-02) 3904-3454

email: atzenifabiola@hotmail.com

References

1. Gensler LS. Axial spondyloarthritis: the heart of the matter. *Clin Rheumatol* 2015; 34 (6): 995-8.
2. Nurmohamed MT, van der Horst-Bruinsma I, Maksymowych WP. Cardiovascular and cerebrovascular diseases in ankylosing spondylitis: current insights. *Curr Rheumatol Rep* 2012; 14: 415-21.
3. Haroon NN, Paterson JM, Li P, Inman RD, Haroon N. Patients with ankylosing spondylitis have increased cardiovascular and cerebrovascular mortality: a population-based study. *Ann Intern Med* 2015; 163: 409-16.
4. Mathieu S, Gossec L, Dougados M, et al. Cardiovascular profile in ankylosing spondylitis: a systematic review and meta-analysis. *Arthritis Care Res (Hoboken)* 2011; 63: 557-63.

5. Sari I, Ozturk MA, Akkoc N. Treatment of ankylosing spondylitis. *Turk J Med Sci* 2015; 45: 416-30.
6. Ward MM, Deodhar A, Akl EA, et al. American College of Rheumatology/Spondylitis Association of America/Spondyloarthritis Research and Treatment Network 2015 recommendations for the treatment of ankylosing spondylitis and nonradiographic axial spondyloarthritis. *Arthritis Rheumatol* 2016; 68: 282-98.
7. Siu S, Haraoui B, Bissonnette R, et al. Meta-analysis of tumor necrosis factor inhibitors and glucocorticoids on bone density in rheumatoid arthritis and ankylosing spondylitis trials. *Arthritis Care Res (Hoboken)* 2015; 67: 754-64.
8. Stone JR, Bruneval P, Angelini A, et al. Consensus statement on surgical pathology of the aorta from the Society for Cardiovascular Pathology and the Association for European Cardiovascular Pathology: I. Inflammatory diseases. *Cardiovasc Pathol* 2015; 24: 267-78.
9. Kinsella TD, Johnson LG, Ian R. Cardiovascular manifestations of ankylosing spondylitis. *Can Med Assoc J* 1974; 11: 1309-11.
10. Klingberg E, Svealv BG, M. S. Tang, et al. Aortic regurgitation is common in ankylosing spondylitis: time for routine echocardiography evaluation? *Am J Med* 2015; 128, 1244-50.
11. Johnsen K, Mahonen M, Lunde P. Prevalence estimation and follow-up of aortic regurgitation subjects in a Norwegian Sami population. *Scand Cardiovasc J* 2009; 43: 176-80.
12. Bergfeldt L, Vallin H, Edhag O. Complete heart block in HLA B27 associated disease. Electrophysiological and clinical characteristics. *Br Heart J* 1984; 51: 184-8.
13. Palazzi CD, D'Angelo S, Lubrano E, Olivieri I. Aortic involvement in ankylosing spondylitis. *Clin Exp Rheumatol* 2008; 26: S131-4.
14. Bergfeldt L. HLA-B27-associated cardiac disease. *Ann Intern Med* 1997; 127: 621-9.
15. Sari I, Haroon N. Cardiovascular Involvement in ankylosing spondylitis. In Atzeni F, Doria A, Nurmohamed M, Pauletto P, eds. Heart in Autoimmune diseases. Book in press 2017 Elsevier.
16. Atzeni F, Gianturco L, Bongiovanni S, et al. Non-invasive imaging methods of evaluating cardiovascular parameters in patients with ankylosing spondylitis before and after 12-month treatment with anti-TNF drugs. *J Biol Regul Homeost Agents* in press 2017
17. Arida A, Proterogerou AD, Konstantonis G, et al. Subclinical atherosclerosis is not accelerated in patients with ankylosing spondylitis with low disease activity: new data and metaanalysis of published studies. *J Rheumatol* 2015; 42: 2098-105.
18. Mathieu S, Pereira B, Couderc M, et al. No significant changes in arterial stiffness in patients with ankylosing spondylitis after tumour necrosis factor alpha blockade treatment for 6 and 12 months. *Rheumatology (Oxford)* 2013; 52: 204-9.
19. Piepoli MF, Hoes AW, Agewall S, Authors/Task Force Members. 2016 European Guidelines on cardiovascular disease prevention in clinical practice: The Sixth Joint Task Force of the European Society of Cardiology and Other Societies on Cardiovascular Disease Prevention in Clinical Practice (constituted by representatives of 10 societies and by invited experts) developed with the special contribution of the European Association for Cardiovascular Prevention & Rehabilitation (EACPR). *Eur Heart J*. 2016; 1; 37: 2315-81.
20. Semb AG, Kvien TK, DeMicco DA, et al. Effect of intensive lipid-lowering therapy on cardiovascular outcome in patients with and those without inflammatory joint disease. *Arthritis Rheum* 2012; 64: 2836-46.

Capsule

Why antioxidants do not prevent preeclampsia

Preeclampsia impairs fetal growth and can damage maternal organs. Reactive oxygen species (ROS) have been proposed to increase the risk of preeclampsia by blocking blood vessel formation (angiogenesis) in the placenta. However, using a mouse model of preeclampsia, Nezu et al. found that decreasing ROS levels led to reduced placental angiogenesis, fetal growth, and maternal survival. In contrast, increased

ROS levels resulted in greater placental angiogenesis and improved fetal and maternal outcomes. These results help to explain why antioxidants have been ineffective at preventing preeclampsia in clinical trials.

Sci Signal 2017; 10: eaam5711

Eitan Israeli

Capsule

Search and capture in space and time

How immunological T cells scan target cells for ligands is poorly understood. Cai and co-authors examined microvillar dynamics in living T cells in three dimensions and in real time. The T cells palpated all spots on a surface within about 1 minute through rapid movements of their microvilli. The time it took to scan the surface matched the movement rate of cells through tissues. These contacts took place in the absence of T cell receptor recognition and were stabilized

independently of signaling or the cytoskeleton. Instead, stabilization depended on ligand affinity. The findings explain why many of the previously described components of the immunological synapse and T cell receptor signaling reside on three-dimensional microvillar-derived projections.

Science 2017; 356: 598

Eitan Israeli

“From things that have happened and from things as they exist and from all things that you know and all those you cannot know, you make something through your invention that is not a representation but a whole new thing truer than anything true and alive, and you make it alive, and if you make it well enough, you give it immortality”

Ernest Hemingway (1899–1961) American novelist, short story writer, and journalist