



Afr J Paediatr Surg. 2018 Jan-Mar; 15(1): 10–15.

PMCID: PMC6419541

doi: [10.4103/ajps.AJPS_84_16](https://doi.org/10.4103/ajps.AJPS_84_16)

PMID: [30829302](https://pubmed.ncbi.nlm.nih.gov/30829302/)

Congenital Pouch Colon Associated with Anorectal Malformation: A Rare Anomaly of Asian Region – Experience of Kurdish Centre

[Rossella Angotti](#), [Qadir Qadir Mohamed Salih](#),¹ [Francesco Molinaro](#), [Francesco Ferrara](#), [Marina Sica](#), [Edoardo Bindj](#), and [Mario Messina](#)

Department of Medical, Surgical and Neurological Sciences, Division of Pediatric Surgery, University of Siena, Siena, Italy

¹Department of Pediatric Surgery, Hevi Pediatric Teaching Hospital, Duhok, Iraq

Address for correspondence: Dr. Rossella Angotti, Department of Medical, Surgical and Neurological Sciences, Division of Paediatric Surgery, University of Siena, Viale Bracci 53100, Siena, Italy. E-mail:

rossellaangotti@me.com

Copyright : © 2019 African Journal of Paediatric Surgery

This is an open access journal, and articles are distributed under the terms of the Creative Commons Attribution-NonCommercial-ShareAlike 4.0 License, which allows others to remix, tweak, and build upon the work non-commercially, as long as appropriate credit is given and the new creations are licensed under the identical terms.

Abstract

Background:

Congenital pouch colon (CPC) is an unusual malformation associated with anorectal malformations (ARMs) that are seen especially in Asia. The aim of this study was to analyse our series of CPC associated with ARM in our centre and report our experience based on the rarity of pathology.

Materials and Methods:

This is a retrospective study conducted at the Department of Paediatric Surgery in North Iraq. We identified patients from a prospectively kept database, including all patients managed between 1997 and 2014.

Results:

In total, 17 patients (3 females and 14 males) were included; all had CPC and high ARM; male:female ratio was 5.6:1. Two females had colo-vestibular fistula, 1 had a colo-cloacal fistula, all males had imperforate anus with colovesical fistula. Pre-operative diagnosis of CPC was made in eight patients (47%). Four patients (23.5%) had an incomplete pouch colon (Type III and IV), and 13 (76%) had complete pouch colon (Type I and II). All patients were managed with staged surgery. Mortality rate was 17.6% (3/17).

Conclusions:

CPC associated with ARM can be defined as 'Asian' complex malformation. Few cases are reported in Literature from Europe and USA. However, it is known that it is ever more frequent the collaboration between Asian and European surgeons (as in our study), so the suspicion should be considered in all patient high ARM who come from Asian region. We reviewed literature and report our experience of 15 years, after a retrospectively analysis, to share it and add our data to their reported.

Keywords: Anorectal malformation, child, congenital colon pouch

INTRODUCTION

Congenital pouch colon (CPC) is a term used to define an unusual condition associated with anorectal malformations (ARMs), even if some authors consider it as a form of ARM.[1,2,3] It is rare worldwide but common in Asian regions, predominantly from the Northern Provinces.[4] It is described as an anomaly in which all or part of the colon is substituted by a pouch-like dilatation, which is connected distally with the urogenital tract through a big fistula.[1,2,3,4] Based on rarity of disease, we reviewed literature and decided to report our experience after a retrospectively analysis of our series and a comparison with data reported. The main aim was to share our experience with scientific community and add our data to those existent.

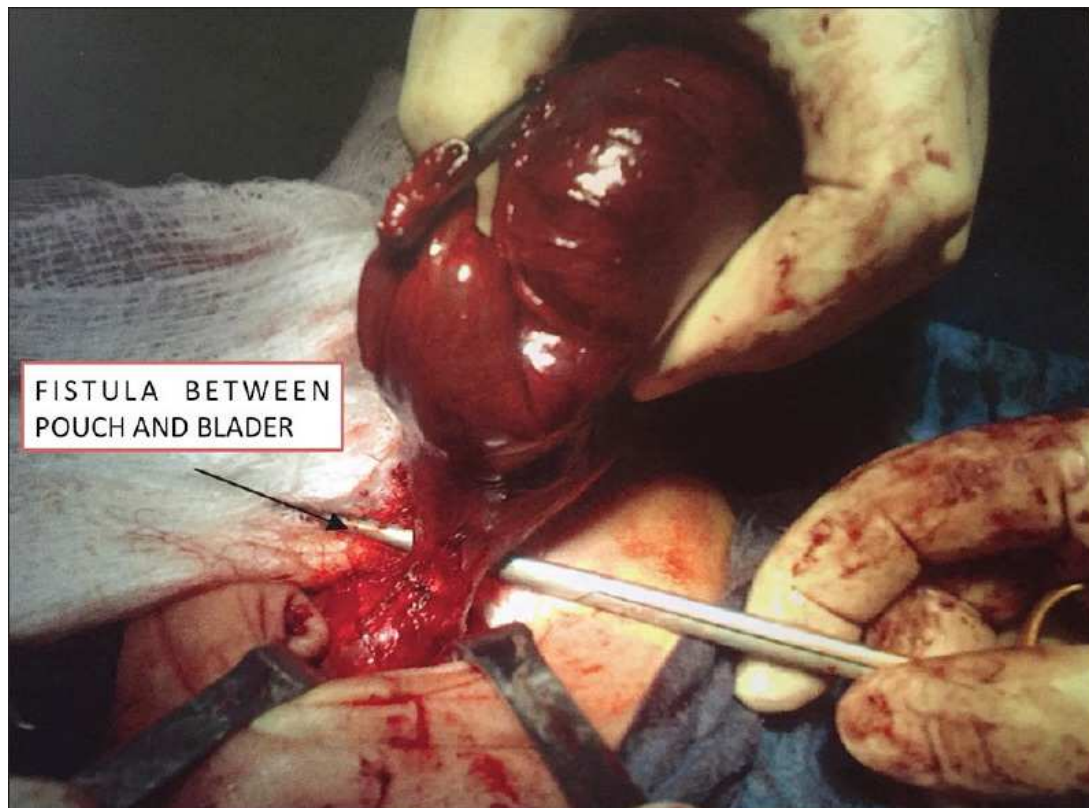
MATERIALS AND METHODS

This is a retrospective study conducted at the Department of Paediatric Surgery in Duhok, Mosul and Erbil (North Iraq). We identified patients from a prospectively kept database. All patients with high ARM seen between 1997 and 2014 were included in this study. We selected only patients with associated CPC. In the last 7 years, we managed these patients with Italian surgeons (Siena) during their Kurdish mission. Clinical presentation and management of all patients were analysed. All patients underwent pre-operative investigations that involved abdominal X-ray, blood exams, abdominal ultrasound, echocardiogram and invertogram. All were managed with staged surgery. One year ago, we called all patients for evaluation in outpatients' clinic with the aim to collect data about the quality of life.

RESULTS

A total of 320 patients with high ARM were identified and 17 of them (5.3%) were included in our study because they had associated a CPC. Fourteen were male (82%), and 3 were female (18%). Male:female ratio was 5.6:1. Four patients (23.5%) had incomplete pouch colon: Type III-5.9% (1) and Type IV-17.6% (3). Thirteen patients (76.5%) had a complete CPC: Type I-47% (8) and Type II-29.5% (5).

Two females had colo-vestibular fistula, 1 had a colo-cloacal fistula, all males had imperforate anus with colovesical fistula [Figure 1]. Thirteen patients (76.5%) had associated malformations including renal diseases (vesicoureteral reflux, hydronephrosis, kidney ectopia and agenesis, megacystis), genital malformations (undescendis testis, hypospadias), gastrointestinal anomalies (appendix agenesis and duodenal atresia), cardiac diseases and vertebral anomalies.



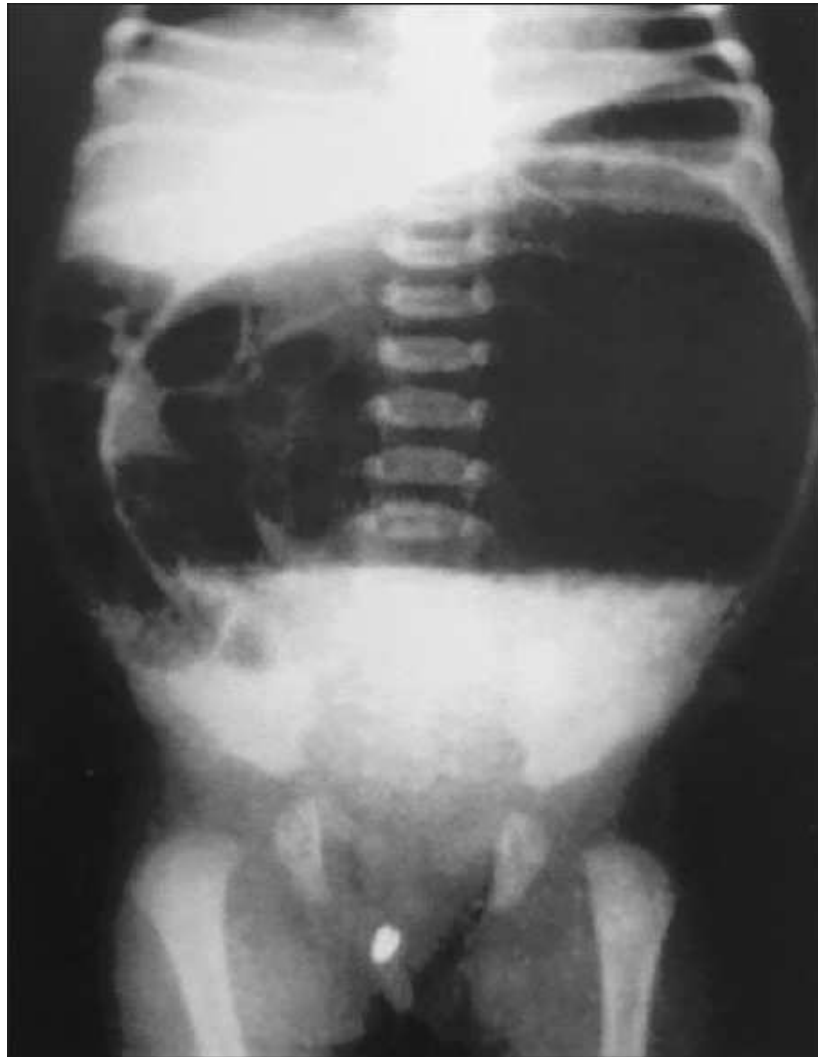[Figure 1](#)

Intraoperative report of congenital pouch colon with vesical fistula in male

The age of presentation was between 1 day-1 year; 16 patients came to our attention in the 1st week of life (mean 3.25 days) and only one female at 1 year. Five males (29%) came to the hospital with acute abdomen and poor general conditions: Abdominal distension and bilious vomiting. One of them had a bowel perforation that it was confirmed charge to pouch during surgery. Other 9 males (53%) had fecaluria. All of them presented an absence of opening anus.

One female (6%) came with symptoms of classical cloaca: Meconium from abdominal opening; other two females (12%) presented meconium from vestibular fistula. All patients underwent abdominal X-ray and invertogram. Only in 8 (47%) of them, it was a suspicion of CPC [[Figure 2](#)]. Abdominal ultrasound and ecocardiogram were performed to rule out or confirm associated malformations. All children were managed with staged surgery. First step provided these surgical procedures: Window colostomy without ligation of fistula in four patients (3-I type, 1-II type); trasverse colostomy and division of the fistula in two (1-IV type, 1-III type); end colostomy after division of the fistula and excision of the pouch in 2 patients (2-IV type); ileostomy and excision of pouch in 9 patients (5-I type, 4-II type) [[Figure 3](#)]. Second step, definitive surgery, was done in 14 cases (82%) because 3 of 17 died (1 for cardiac malformations and 2 for sepsis). The age of definitive surgery ranged between 5 and 16 months (mean 7 months). In 10/14 patients, we performed an ileoanal anostomosis (CPC I-II), 9 of them had an ileostomy and 1 had a window colostomy, indeed he underwent pouch excision. 4/14 underwent coloanal anastomosis previous pouch excision in patients with transverse colostomy. In these 2 patients, we left colostomy and closed it 7 weeks later. All patients with ileoanal anastomosis had more than 8 defecations per day for 3 months. These bowel movements decreased after 6 months

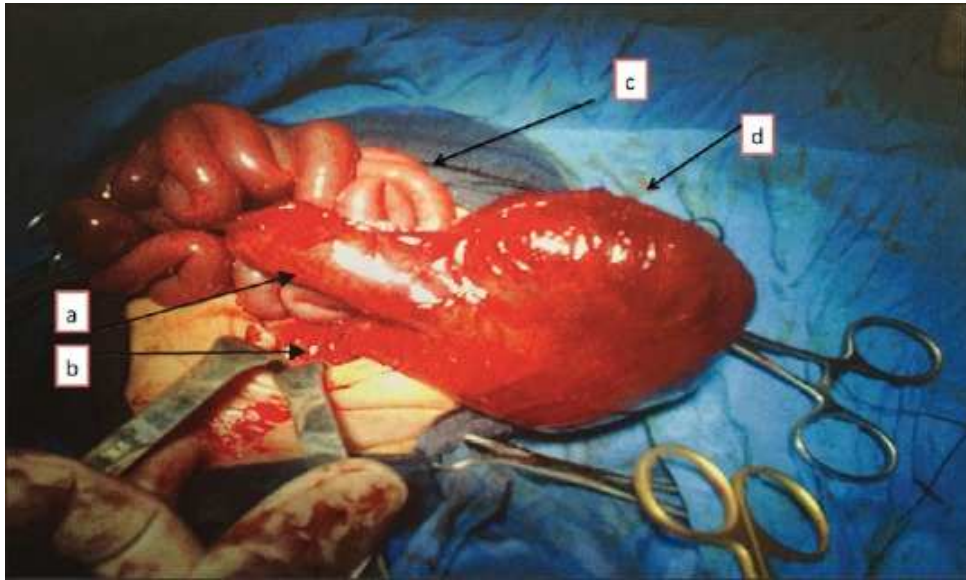
at least. All patients were managed with antibiotic therapy for 2 postoperatively weeks. All were discharged in mean after 18 days (range: 16–20 days), and we set a prophylactic therapy with amoxicillina-clavulanic (20 mg/kg/day) and loperamide (3 mg/kg/die) therapy for 6 months. We had 29% of complications (5/17) after 1th operation: 2 colostomy's prolapse, 1 retraction of ileostomy and 2 recurrent urinary tract infection (r-UTI) in patients with windows colostomy. Five complications there were after definitive surgery (36%): 2 faecal incontinence, 1 anal stenosis, 1 r-UTI and 1 failure to thrive. Mortality was 17.6% equal to 3/17 children: All patients died after firts surgery (1 for cardiac malformations and 2 for sepsis). The mean follow-up is 10.1 years (1–18 years). We have not at now a protocol for long-term follow-up because all of these patients were managed at their local hospital. Last year, we convened all fourteen patients, but only 11 (9 males and 2 females) responded and came to the outpatient clinic. Two patients (11 years and 16 years) with ileoanal anastomosis have faecal incontinence, and they are managed with peristeen with middle results. One female (1 years-ex cloaca) has r-UTI, and she is on prophylactic antibiotics. We delayed the genitourinary reconstruction because she has cardiac malformation, so we are planning the final surgery when she will be stable. One male (3 years) has anal stenosis that we are managing with periodic dilatation under anesthesia. Three patients have keloid scars at the site of ileostomy. [Table 1](#) shows main details of our patients.



[Open in a separate window](#)

Figure 2

Abdomen X-ray in male with high anorectal malformation who came in the 2 days of life for abdominal distention and bilious vomiting in absence of normal opening anus. Plain shows a large loop of bowel with a single air-fluid level that occupies most of the abdominal cavity and causes a shift of small bowel to on the right side. The main suspicion was of congenital pouch colon associated with anorectal malformation



[Figure 3](#)

Intraoperative image of complete pouch. a: Transient zone between pouch and ileum; b: colovesical fistula; c: ileum; d: colon pouch

Table 1

Summary of all our patients

Patient number	Sex	Age of presentation	Diagnosis (pre-operative/intraoperative)	Type of fistula/type of CPC	Stage 1-surgical procedure	Complications after 1 step	Stage 2-def surgery
1	Male	2	Pre-operative	CPC II and colovesical fistula	Ileostomy and pouch excision		Abdc pull through ileo- ϵ anast
2	Male	1	Intraoperative	CPC I and colovesical fistula	Ileostomy and pouch excision	Retraction of ileostomy	Abdc pull through ileo- ϵ anast
3	Male	7	Pre-operative	CPC II and colovesical fistula	Ileostomy and pouch excision		Abdc pull through ileo- ϵ anast
4	Male	2	Pre-operative	CPC I and colovesical fistula	Ileostomy and pouch excision		Abdc pull through ileo- ϵ anast
5	Male	3	Pre-operative	CPC II and colovesical fistula	Ileostomy and pouch excision		Abdc pull through ileo- ϵ anast
6	Male	2	Intraoperative	CPC I and colovesical fistula	Ileostomy and pouch excision		Abdc pull through ileo- ϵ anast
7	Male	2	Pre-operative	CPC I and colovesical fistula	Ileostomy and pouch excision		Abdc pull through ileo- ϵ anast
8	Male	1	Intraoperative	CPC IV and colovesical fistula	Transverse colostomy	1 prolapse of colostomy	Abdc pull through coloa anast

Patient number	Sex	Age of presentation	Diagnosis (pre-operative/intraoperative)	Type of fistula/type of CPC	Stage 1-surgical procedure	Complications after 1 step	Stage 2-def surgery
9	Male	2	Intraoperative	CPC IV and colovesical fistula	End colostomy		Abdc pull through coloa anast
10	Male	4	Pre-operative	CPC I and colovesical fistula	Window colostomy	r-UTI/died	
11	Male	3	Pre-operative	CPC I and colovesical fistula	Window colostomy	Died	
12	Male	1	Intraoperative	CPC I and colovesical fistula	Window colostomy	1 prolapse of colostomy/died	
13	Male	2	Pre-operative	CPC II and colovesical fistula	Ileostomy and pouch excision		Abdc pull through ileo-Ꝁ anast
14	Male	2	Intraoperative	CPC I and colovesical fistula	Ileostomy and pouch excision		Abdc pull through ileo-Ꝁ anast
15	Female	5	Intraoperative	CPC IV and colo-vestibular	End colostomy		Abdc pull through coloa anast
16	Female	365	Intraoperative	CPC III and colo-	Transverse colostomy		Abdc pull

[Open in a separate window](#)

We report in this from Table : summary of patients

DISCUSSION

CPC is known as an anomaly in which all or part of the colon is substituted by a pouch-like dilatation, which is connected distally with the urogenital tract through a fistula.[1,2] The exact embryogenesis of

CPC is not known. The first anatomic description of this malformation was done in 1977 by Singh *et al.*[5,6] The name 'CPC syndrome' was introduced by Narsimha Rao *et al.* in 1984[1,7] and his classification has been widely accepted and it is used till today. In most of largest series, Type I and II are more common.[8,9,10,11] We confirm it in our series because we report the 76.5% of CPC I/II. The exact incidence of CPC associated with ARM is not known even if it is certain that it is rare worldwide. It is much more common in India than in the rest of world,[1,4] indeed majority cases reported in literature are from there. The reason of this unique geographical distribution has not yet been ascertained. We report an CPC's incidence of 5.3% of all ARM in North Iraq that it is lower in comparison to other studies from North India.[1] In our series, there was no regional variations, while in India most of studies report difference between North and Sud regions. It is reported that CPC is more common in males.[1,4] Also in our series, there is a significantly higher incidence in males than in females (5.6:1). According to scientific community, CPC, to be defined as such, must have some specific anatomical hallmarks. An ARM must be present. The total length of the colon must be shorter than normal because all or part of it is replaced by the pouch. Length and size of this colonic pouch are variable, generally, the diameter is between 5 and 15 cm. Colon pouch does not have taenia coli and haustrations, appendices epiploicae that typify a normal colonic tract. The mesentery of pouch is poorly developed. The blood supply is abnormal, and it is different based on type of CPC. In general, it is charged to the superior mesenteric artery in CPC I/II and inferior mesenteric artery in CPC III/IV. In most of cases, hystopathology is characterised by a thinning of muscle layers, outer as well as inner and a disorganised muscle layers with normal ganglionosis; however, it is recognised that in few cases it can be seen an hypoganglionosis, aganglionosis, neuronal hypoplasia or presence of heterotopic. The terminal fistula of the colonic pouch opens at variable levels of genitourinary system. In male, it can open into the urethra or bladder (at different sites); in female, it opens in the vestibule, in the vagina, uterus, in perineum or a persistent cloaca.[1,2] The fistula is large, muscular and long. Finally, there is no transit zone between the pouch and the normal bowel as it is present in Hirschprung disease.[1] All of our patients had anatomic and histologic features as described in literature. Clinical presentation varies based on anatomical situation, and it is the same of ARM with fistula. There is no normal opening anus in the perineum of baby, and there is an unusual passage of meconium from abnormal opening (urethra in male, vagina, vestibulo or cloaca in female).[1,3] Commonly, patients present abdominal distention with/without bilious vomiting. Five of our patient had this onset; 9 males had fecaluria, 2 females had meconium pass from vestibulo and 1 had cloaca. The worst clinical presentation is due to the perforation of the pouch, that is, no rare event based on its thinness of wall, resulting in the acute abdomen, poor general conditions and sometimes life-threatening. We report only 1 case with this clinical picture. Most onsets are neonatal; rarely the presentation may be late when the fistula is large and permits the passage of gas and meconium (this is typical of colo-cloacal fistula). In our series, 15 patients came in the 1st week of life, with a mean age of 3, 25 days (range 1–7 days) and 1 female with big rectovestibular fistula came at 1 year.

Many associated anomalies with CPC are reported in literature.[1] Genitourinary and gastrointestinal systems are most commonly involved.[1,2] We report associated anomalies in 13 patients (76.5%) that is similar to the percentage reported in literature.[1] The diagnosis of CPC is it not always clear, and it usually is done during surgery. Sometimes, it can be missed as in the presence of incomplete pouch or in cases of perforation, where the pneumoperitoneum masks the real anatomical situation. In one of our patient, we had this situation, and the correlation between perforation and pouch was clear only during surgery. However, it is important to know that an early perforation in a patient with high ARM and who comes from geographic area where CPC is commonly seen is suggestive of pouch colon. Other times, instead, it can be made a false diagnosis, when other organs are so dilated that mimic a CPC, for example, in case of big dilatation of sigmoid colon or uterus.[8,11] In a classical case, the diagnosis is

made with an abdomen X-ray (anteroposterior and lateral views) and an invertogram. The radiographic hallmark is a large loop of bowel with a single air-fluid level that occupies most of the abdominal cavity and causes a shift of small bowel to on the side (usually right). In the invertogram, the image of pouch is at the level is at the level of pubococcygeal line.[1] In our series, pre-operative diagnosis was made in 47% of patients (8 patients). This percentage is lower than that reported in literature.[11] The management of CPC has three main goals: (1) to preserve a length of peristaltic colon (15 cm) enough to ensure a good absorption and faecal storage capacity; (2) to ensure an anal continence; (3) to preserve ileocecal valve. All of these purposes can be ensured with a single surgery o staged surgeries, based on clinical situation of patient and type of CPC. The general consensus is to a correction by staged surgery. We are agree with this leanings, indeed we report all staged surgeries. The prognosis of CPC is related to general conditions of child, in term of clinical onset, associated anomalies, weight at birth and type of CPC. As it is clear, it is better in case of incomplete CPC. In the last year, Gupta and Sharma[1] reported a mortality of 8.8% in the neonatal period; our mortality is higher (17.6%) but after the neonatal period and it was related to the initial period of this study. It has now come down as a result of the growing awareness of this condition and improvements in surgical management and neonatal care.

A review of literature, as it known, shows majority of cases from India; however, there are few cases from European countries and USA: 7 cases from Canada,[12] 6 from Turkey,[13] some cases from China,[14] Japan[15] and Iran,[16] and few reports from Europea[17,18,19] countries and the USA.[20,21]

CONCLUSIONS

We reported our experience and added 17 cases from Iraq to those presented in literature. The retrospective analysis of this study permitted us to evaluate our management and our approach to these patients. We are agree that it was an improvement in term of management that it is shown by decreasing of mortality and by a better quality of life of patients who underwent surgery in the last 10 years. The key message of this study, so, is to consider CPC in all patients with high ARM especially if they come from the Asian region. It is known indeed that many European and American Centers manage patients who come from these places. The knowledge of disease permits an early diagnosis and an appropriate surgical approach to ensure a survival and good quality of life to these children.

Financial support and sponsorship

Nil.

Conflicts of interest

There are no conflicts of interest.

REFERENCES

1. Gupta DK, Sharma S. Congenital pouch colon – Then and now. J Indian Assoc Pediatr Surg. 2007;12:5–12. [[Google Scholar](#)]
2. Sangkhathat S, Patrapinyokul S, Chiengkriwate P. Functional and manometric outcomes after a congenital pouch colon reconstruction: Report of a case. J Med Assoc Thai. 2012;95:270–4. [[PubMed](#)] [[Google Scholar](#)]
3. Sharma S, Gupta DK. Management options of congenital pouch colon – A rare variant of anorectal malformation. Pediatr Surg Int. 2015;31:753–8. [[PubMed](#)] [[Google Scholar](#)]

4. Pavai A, Pillai SD, Shanthakumari S, Sam CJ, Shylaja M, Sabarivinoth R. Congenital pouch colon: Increasing association with low anorectal anomalies. *J Indian Assoc Pediatr Surg.* 2009;14:218–20. [[PMC free article](#)] [[PubMed](#)] [[Google Scholar](#)]
5. Singh A, Singh R, Singh A. Short colon malformation with imperforate anus. *Acta Paediatr Scand.* 1977;66:589–94. [[PubMed](#)] [[Google Scholar](#)]
6. Wakhlu AK, Tandon RK, Kalra R. Short colon with anorectal malformation. *Indian J Surg.* 1982;44:621–9. [[Google Scholar](#)]
7. Narsimha Rao KL, Yadav K, Mitra SK, Pathak IG. Congenital short colon with imperforate anus (CPC syndrome) *Ann Pediatr Surg.* 1984;1:159. [[Google Scholar](#)]
8. Budhiraja S, Pandit SK, Rattan KN. A report of 27 cases of congenital short colon with an imperforate anus so called “CPC syndrome” *Trop Doct.* 1977;27:217–20. [[PubMed](#)] [[Google Scholar](#)]
9. Narasimharao KL, Yadav K, Mitra SK, Pathak IC. Congenital short colon with imperforate anus (pouch colon syndrome) *Ann Pediatr Surg.* 1984;1:159–67. [[Google Scholar](#)]
10. Wardhan H, Gangopadhyay AN, Singhal GD, Gopal SC. Imperforate anus with congenital short colon (pouch colon syndrome): Review of 18 cases. *Pediatr Surg Int.* 1990;5:124–6. [[Google Scholar](#)]
11. Chadha R, Bagga D, Mahajan JK, Gupta S. Congenital CPC revisited. *J Pediatr Surg.* 1988;33:1510–5. [[PubMed](#)] [[Google Scholar](#)]
12. Trusler GA, Mestel AL, Stephens CA. Colon malformation with imperforate anus. *Surgery.* 1959;45:328–34. [[PubMed](#)] [[Google Scholar](#)]
13. Baskin D, Pektas O, Burut M. Association of Anorectal Malformations with Congenital Pouch Colon: A Report of 6 Case. Paper Presented at XVI Annual Congress of The Turkish Association of Pediatric Surgeons; 14-17 October. 1998; Antalya (Turkey). [[Google Scholar](#)]
14. Wu YJ, Du R, Zhang GE, Bi ZG. Association of imperforate anus with short colon: A report of eight cases. *J Pediatr Surg.* 1990;25:282–4. [[PubMed](#)] [[Google Scholar](#)]
15. Chiba T, Kasai M, Asakura Y. Two cases of coloplasty for congenital short colon. *Nihon Geka Hokan.* 1976;45:40–4. [[PubMed](#)] [[Google Scholar](#)]
16. Vaezzadeh K, Gerami S, Kalani P, Sieber WK. Congenital short colon with imperforate anus: A definitive surgical cure. *J Pediatr Surg.* 1982;17:198–200. [[PubMed](#)] [[Google Scholar](#)]
17. Dénes J, Ziszi K, Bognár M, Schläffer E, Tóth J. Congenital short colon associated with imperforate anus (Zachary-Morgan syndrome) *Acta Paediatr Hung.* 1984;25:377–83. [[PubMed](#)] [[Google Scholar](#)]
18. el Shafie M. Congenital short intestine and cystic dilatation of the colon associated with ectopic anus. *J Pediatr Surg.* 1971;6:76. [[PubMed](#)] [[Google Scholar](#)]
19. Luzzatto C, Zanardo V, Guglielmi M. Imperforate anus with congenital short colon: Combined abdominal and posterior sagittal approach. *Pediatr Surg Int.* 1990;5:375–6. [[Google Scholar](#)]
20. Dickinson SJ. Agenesis of the descending colon with imperforate anus. Correlation with modern concepts of the origin of intestinal atresia. *Am J Surg.* 1967;113:279–81. [[PubMed](#)] [[Google Scholar](#)]
21. Herman TE, Coplen D, Skinner M. Congenital short colon with imperforate anus (pouch colon). Report of a case. *Pediatr Radiol.* 2000;30:243–6. [[PubMed](#)] [[Google Scholar](#)]

Articles from African Journal of Paediatric Surgery: AJPS are provided here courtesy of **Wolters Kluwer --
Medknow Publications**