



African Journal of Paediatric Surgery

| Volume 14 | Issue 2 | April-June 2017 |



In this issue....

- Factors Associated with the Risk of Persistent Gastrostomy Site Infection Following Laparoscopic or Open Nissen Fundoplication
- Retroperitoneoscopic Varicocelectomy in Adolescents: Long-term Follow-up in Two Italian Centres
- One or Two Stages Procedure for Repair of Rectovestibular Fistula: Which is Safer? (A Single Institution Experience)
- Unusual Ileal Anomalies Associated with Omphalomesenteric Duct Remnants

Official Journal of:
Association of Paediatric Surgeons of Nigeria [APSON]
Pan-African Paediatric Surgical Association [PAPSA]

www.afrijpaedsurg.org

Retroperitoneoscopic Varicocelectomy in Adolescents: Long-term Follow-up in Two Italian Centres

Molinaro Francesco, Cobellis Giovanni¹, Cerchia Elisa, Ferrara Francesco¹, Tallarico Rosella¹, Sica Marina, Noviello Carmine¹, Martino Ascanio¹, Angotti Rossella, Messina Mario

Department of Medical, Surgical and Neurological Science, Pediatric Surgery Unit, University of Siena, 53100 Siena, ¹Department of Pediatric Surgery, Pediatric Surgery Unit, Salesi Children Hospital Ospedali Riuniti, 60123 Ancona, Italy

Abstract

Background: The varicocele is the most commonly diagnosed pre-pubertal andrological condition with an incidence of 10%–15% between adolescents. The aim of this study was to evaluate the efficacy of retroperitoneoscopic varicocelectomy (RV) in two Italian centres with particular attention to post-operative testicular volume and semen analysis after 18 years of life. **Materials and Methods:** From 1999 to 2010, 286 adolescents underwent retroperitoneoscopic left varicocelectomy. Of these patients, 67 were evaluated by clinical examination, ultrasound and semen analysis, allowing an adequate long-term follow-up. **Results:** Surgery was performed at a mean age of 13 years (range 10–17) without intraoperative complications. There were two recurrences (3%), two left testis hypotrophy (3%) and four hydroceles (6%), not yet undergone surgery because asymptomatic or without tension. Currently, 44 patients accepted to perform semen analysis which showed a reduction in sperm motility in 12 cases, with associated morphological alterations in 3 and reducing number of spermatozoa in one case. **Conclusions:** In consideration of morphological and biomolecular spermatogenic alterations reported in adolescent varicocele that could interfere with cellular migration, differentiation and nutrition, it is fundamental to consider the correction of varicocele, not only for the classical indications, but also as a choice for arresting the progressive damage that inevitably acts for several years on the adolescent testis. The RV in adolescents is a safe and feasible procedure for experienced paediatric laparoscopic surgeons with early good clinical outcomes, but more studies occur to understand the real impact of adolescent varicocelectomy on testicular function.

Keywords: Adolescents, infertility, retroperitoneoscopy, varicocele

INTRODUCTION

Varicocele is the most common correctable aetiology found in adult men with infertility. Because evidence from animal and human studies have shown that varicocele is associated with a time-dependent decline in testicular function,^[1] the surgical management of asymptomatic varicocele in adolescents has been advised with the main goal of preventing testicular injury and maintaining a good testicular function at younger age.^[2] In literature, the optimal treatment is still a matter of debate and controversy. Many procedures are described; all of them have advantages and disadvantages. The aim of this study was to evaluate the efficacy of retroperitoneoscopic varicocelectomy in two Italian centres with particular attention to post-operative testicular volume and semen analysis after 18 years of life.

MATERIALS AND METHODS

Between January 1999 and September 2010, the retroperitoneoscopic approach was performed on 286 patients with left-sided varicocele in two Departments of Paediatric Surgery. The indications for surgical treatment were a third-degree varicocele according to Horner's classification and in case of second-degree, the presence of pain, scrotal discomfort or the identification of testicular asymmetry with hypotrophy of the affected side. Of these 286 patients, only 67 cases, with age superior to 18 years, were included in our

Address for correspondence: Dr. Angotti Rossella, Department of Medical, Surgical and Neurological Science, Paediatric Surgery Unit, University of Siena, Viale Bracci 16, 53100 Siena, Italy. E-mail: rossellaangotti@me.com

This is an open access article distributed under the terms of the Creative Commons Attribution-NonCommercial-ShareAlike 3.0 License, which allows others to remix, tweak, and build upon the work non-commercially, as long as the author is credited and the new creations are licensed under the identical terms.

For reprints contact: reprints@medknow.com

How to cite this article: Francesco M, Giovanni C, Elisa C, Francesco F, Rosella T, Marina S, *et al.* Retroperitoneoscopic Varicocelectomy in Adolescents: Long-term Follow-up in Two Italian Centres. Afr J Paediatr Surg 2017;14:24-6.

Access this article online

Quick Response Code:



Website:
www.afjpaedsurg.org

DOI:
10.4103/ajps.AJPS_58_16

study of long-term follow-up. All patients were evaluated by clinical examination, ultrasonographic testicular volume assessment and semen analysis.

Surgical technique

All patients were submitted to the same surgical procedure of one trocar retroperitoneoscopic Palomo's varicocelectomy under general anaesthesia. A standard surgical position of the right lateral decubitus was adopted for all patients, and a transverse incision of 1.5 cm was made below the apex of the 12th rib for the introduction of a 10 mm, 0° operative telescope. The trocar, which is balloon tripped to prevent dislodgement, was introduced in the retroperitoneal space after open approach [Figure 1]. Carbon dioxide pneumoretroperitoneum was induced to a pressure of 12–15 mmHg. The retroperitoneal working space was created by a blunt-tipped dissector under visual control. After visualisation of psoas muscle and the lumbar ureter, the spermatic vessels (artery and vein) were carefully identified at the cross with the ureter (ureterovenous angle). These vessels were stuck to the posterior part of the peritoneum. The artery and one or two veins were dissected off from the peritoneum, coagulated by a bipolar electrocautery and finally divided [Figure 2].

We did not require ethics approval because this is a descriptive study. We obtained and collected data during a normal diagnostic and therapeutic route that patients with varicocele make in our centres.

RESULTS

The retroperitoneoscopic procedure was performed at a mean

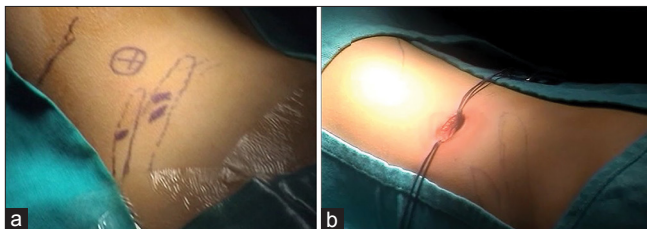


Figure 1: (a and b) Standard surgical position on the right lateral decubitus and the site of port

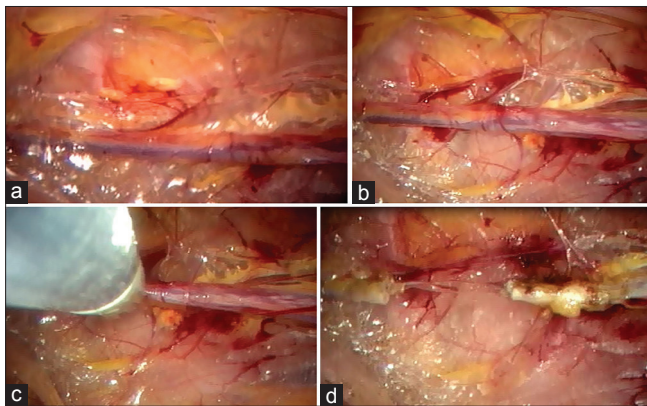


Figure 2: (a-d) Surgical steps of retroperitoneoscopic varicocelectomy: (a and b) visualization of the spermatic vessels after performing a working space, (c and d) the vessels are dissected off from the peritoneum, then they are coagulated by a bipolar electrocautery and finally divided

age of 13 years (range 10–17 years) without intraoperative complications and completed without required conversion in all cases. Median operating time was 30 min (range 15–45 min), and median hospital stay was 2 days (range 1–3 days). At a mean clinical and ultrasound follow-up of 25 months (range 6–46 months), there were two recurrences (3%), two left testis hypotrophy (3%) and four hydroceles (6%), not yet undergone surgery because asymptomatic or without tension. Currently, 44 patients (66%) accepted to perform semen analysis which showed a reduction in sperm motility in 12 cases (27%), with associated morphological alterations in 3 (7%) and reducing number of spermatozoa in 1 (2%). In 4 (9%) patients, only morphological sperm alterations were founded, and only one patient referred to have a child.

DISCUSSION

The varicocele is the most commonly diagnosed pre-pubertal andrological condition with an incidence of 10%–15% between adolescents.^[3] Its clinical presentation can be widely variable and often asymptomatic or silent. As early as 1970s, paediatric and adolescent varicocele were thought to be an unimportant clinical entity. Its importance was recognised when several studies showed its relation with male infertility and that it was the most common correctable cause of sterility. Many studies have been done to explain the pathophysiology of testicular dysfunction occurring with varicocele, but the exact mechanism of infertility remains misunderstood. The most accepted theory is that germinal cell dysfunction is secondary to hypoxia due to the obstruction of small vessels and venous stasis.^[4] The deteriorating of testicular function has been documented clearly in individuals with varicocele.^[5] The effect of varicocele is manifested by low sperm count, decreased sperm motility and low percentage of normal sperm morphology presenting in different combinations. In our series, we reported a reduction in sperm motility in 12 cases (27%), with associated morphological alterations in 3 (7%) and reducing number of spermatozoa in 1 (2%). In literature, it is well documented that there is an increase in both ipsilateral and contralateral testicular growth in children and adolescents who have undergone varicocele treatment compared with those who had not. Surgical repair of varicocele should be suggested to prevent testicular injury and improve the potential for future fertility.^[6,7] Nowadays, the diagnosis and management of varicocele have not been standardised, and the debate is opened regarding many points: What cut-off must be used for candidate patients to surgical treatment and the choice of a surgical technique with low complications rate.

What criteria must be considered to candidate patients to treatment? We consider that the European Association of Urology and European Society of Paediatric Urology guidelines are more detailed^[8] in term of diagnosis and indications for treatment.

What is the best surgery for varicocele in adolescent patients?

Literature purposes many different data. The most popular surgical procedure remains the high retroperitoneal ligation of the internal spermatic vein and artery (Palomo's technique),

resulting in decrease of recurrences compared with artery sparing techniques.^[9] Minimally invasive methods such as percutaneous retrograde sclerotherapy and laparoscopy have also been applied to paediatric population in the last years.^[10] We do not perform percutaneous retrograde sclerotherapy as the first choice but we limited in cases of recurrence, so we will not include this technique in our report. A recent meta-analysis and literature review performed on eleven studies published between 2000 and 2009, with a population of 1443 children and adolescents treated, have compared the two most popular approaches in the paediatric age group reported in the literature: The laparoscopic and the open techniques.^[11] Varicocele recurrence in adolescents who underwent laparoscopic versus open techniques showed no statistical difference (4.7% vs. 8.6%). Similarly, no statistical difference could be demonstrated in terms of post-operative hydrocele formation: 9.5% for the laparoscopic technique versus 6.7% for the open techniques.

In our opinion, retroperitoneoscopy seems more rational and less invasive to approach the spermatic vessels.^[12-15] The one incision decreases the injury to the abdominal wall and allows a more direct access to the spermatic vessels even if there is a technical difficulty to create a good working space. In term of complications, we report a higher rate of hydrocele (6%) that seems related to ligation of lymphatic vessels. For this reason, we started to use lymphatic sparing technique in the last 2 years, but we have only preliminary results. We have no cases of atrophy and only two patients (3%) with testicular hypotrophy.

Fertility and paternity are the most important topics that patients and parents of adolescent with varicocele consider, regardless of surgical technique.^[16] Many studies report data about these points. We tried to create a long-term follow-up with the aim of studying the evolution of fertility in our patients after 18 years of age of life. Unfortunately, only 44 of 286 (15%) patients were submitted to semen analysis. However, the preliminary results show the presence of abnormal semen in 27% of patients as evidence of the importance of early treatment. We are aware that a longer follow-up is needed to demonstrate any improvement in spermatogenesis after early surgical management.

CONCLUSIONS

Based on the knowledge of morphological and biomolecular spermatic alterations in adolescent varicocele that could interfere with spermatogenesis, it is important to consider the surgical correction in paediatric age. However, more studies must be done to understand the real impact of adolescent

varicocelectomy on testicular function. All surgical techniques have advantages and disadvantages, and each surgeon prefers one of them. Our group treats the varicocele through retroperitoneoscopic approach because we believe that it is a safe and feasible procedure with good clinical outcomes.

Financial support and sponsorship

Nil.

Conflicts of interest

There are no conflicts of interest.

REFERENCES

1. Kass EJ, Freitas JE, Bour JB. Adolescent varicocele: Objective indications for treatment. *J Urol* 1989;142(2 Pt 2):579-82.
2. Haans LC, Laven JS, Mali WP, te Velde ER, Wensing CJ. Testis volumes, semen quality, and hormonal patterns in adolescents with and without a varicocele. *Fertil Steril* 1991;56:731-6.
3. Valla JS. Retroperitoneoscopic surgery in children. *Semin Pediatr Surg* 2007;16:270-7.
4. Ficarra V, Crestani A, Novara G, Mirone V. Varicocele repair for infertility: What is the evidence? *Curr Opin Urol* 2012;22:489-94.
5. Chehval MJ, Purcell MH. Deterioration of semen parameters over time in men with untreated varicocele: Evidence of progressive testicular damage. *Fertil Steril* 1992;57:174-7.
6. Kass EJ, Belman AB. Reversal of testicular growth failure by varicocele ligation. *J Urol* 1987;137:475-6.
7. Messina M, Zagordo L, Di Maggio G, Molinaro F, Abate V, Nardi N. Testicular hypotrophy in varicocele: Pre and postoperative echographic follow-up in the pediatric age. *Minerva Urol Nefrol* 2006;58:151-5.
8. Roque M, Esteves SC. A systematic review of clinical practice guidelines and best practice statements for the diagnosis and management of varicocele in children and adolescents. *Asian J Androl* 2016;18:262-8.
9. Zampieri N, Brugnoli M, Caldarulo E, Corciulo A, D'Amato M, Nino F *et al.* Multicenter Italian survey for varicocele treatment in pediatric age. *JEMIS Journal of Endoscopic and Minimally Invasive Surgery*, 2013, n. 1.
10. Pajovic B, Radojevic N. Prospective follow up of fertility after adolescent laparoscopic varicocelectomy. *Eur Rev Med Pharmacol Sci* 2013;17:1060-3.
11. Borruto FA, Impellizzeri P, Antonuccio P, Finocchiaro A, Scalfari G, Arena F, *et al.* Laparoscopic vs. open varicocelectomy in children and adolescents: Review of the recent literature and meta-analysis. *J Pediatr Surg* 2010;45:2464-9.
12. Mancini S, Bulotta AL, Molinaro F, Ferrara F, Tommasino G, Messina M. Surgical retroperitoneoscopic and transperitoneoscopic access in varicocelectomy: Duplex scan results in pediatric population. *J Pediatr Urol* 2014;10:1037-42.
13. Messina M, Zagordo L, Garzi A, Cerigioni E, Di Maggio G, Roggi A, *et al.* Treatment of varicocele in pediatric age with retroperitoneoscopic "one trocar" technique. Long term follow-up. *Minerva Urol Nefrol* 2006;58:81-6.
14. Cobellis G, Mastroianni L, Cruccetti A, Amici G, Martino A. Retroperitoneoscopic varicocelectomy in children and adolescents. *J Pediatr Surg* 2005;40:846-9.
15. Gaur DD, Agarwal DK, Purohit KC. Retroperitoneal laparoscopic varicocelectomy. *J Urol* 1994;151:895-7.
16. Podkamenev VV, Stalmakhovich VN, Urkov PS, Solovjev AA, Iljin VP. Laparoscopic surgery for pediatric varicoceles: Randomized controlled trial. *J Pediatr Surg* 2002;37:727-9.