



Multiseptate gallbladder in a child

Mirko Bertozzi^a, Ilaria Bizzarri^b, Rossella Angotti^c, Giulia Fusi^c, Stefania Ceppi^b, Giuseppe Di Cara^b, Susanna Esposito^b, Mario Messina^c, Francesco Molinaro^{c,*}

^a S.C. di Clinica Chirurgica Pediatrica, Azienda Ospedaliera di Perugia, Italy

^b S.C. di Clinica Pediatrica, Università degli Studi di Perugia - Azienda Ospedaliera di Perugia, Italy

^c Department of Medical Sciences, Surgery and Neuroscience, Section of Paediatric Surgery, University of Siena, Siena, Italy



ARTICLE INFO

Keywords:

Multiseptate gallbladder
Laparoscopic surgery
Children

ABSTRACT

Multiseptate gallbladder (MSG) is a rare congenital anomaly. MSG may be accompanied with other abnormalities of the biliary tree. MSG can be asymptomatic and most cases are detected incidentally. Nevertheless, some patients present with biliary pain or colicky abdominal pain due to biliary stasis and calculi. We report a case of MSG in a girl who presented with recurrent abdominal pain and normal laboratory work-up recovered after laparoscopic cholecystectomy. A pediatric literature review of this rare anomaly is also performed.

1. Introduction

Multiseptate gallbladder (MSG) is a rare congenital anomaly, whose clinical and pathological findings of MSG were firstly reported in 1963 [1]. It is likely secondary to an incomplete vacuolization of the gallbladder bud [2]; the septa may be complete, involving the entire lumen, or incomplete [2–4]. Clinically, MSG can be asymptomatic but most patients present with biliary pain or colicky abdominal pain, usually localized in the epigastrium or right upper quadrant, sometimes irradiated in the back near the right scapula [5]. This clinical findings are likely due to a transient inability of thick bile to pass through the small holes between the septa, causing biliary stasis and calculi [2,4]. It occurs particularly because of the lack of muscle fiber inside the septa [6]. Most cases are detected incidentally at imaging [1], and can be accompanied with other duct abnormalities.

Furthermore literature report a female preponderance of this anomaly [7–9].

We report a patient with a MSG who presented with recurrent abdominal pain and normal laboratory work-up and recovered after surgical treatment.

2. Case report

A 7-year-old girl with recurrent abdominal pain of about 2 years of duration was admitted to our hospital. The pain was colicky in nature and not associated with nausea, vomiting, diarrhea, fever or any other symptoms. Infectious disease and blood disorders, such as sickle cell

disease, were excluded. Familiar history was negative for any relevant disease. Physical examination and laboratory findings, included CBC, liver function tests, and electrolytes, ESR, CPR, were normal. Ultrasound (US) examination, performed during the first episode, was not diriment because of the lack of fasting.

The second sonographic exam demonstrate a MSG with a honeycomb appearance (Fig. 1).

At first a pharmacological approach with ursodeoxycholic acid was administered with no clinical benefit. Therefore, girl underwent laparoscopic surgery and a perioperative magnetic resonance cholangiopancreatography (MRCP) study was performed (Fig. 2) confirming MSG. After surgical treatment by laparoscopic cholecystectomy (Fig. 3 – Fig. 4) she completely recovered.

3. Discussion

From a review of literature, 20 pediatric cases of MSG are described, including our case. Most of them were female (11 of 20) and eighteen of them reported clinical symptoms. The diagnosis was made with US in almost every cases and with MRCP in three cases. The median age at diagnosis was 8.7 years. Nine of them underwent to surgical treatment with resolution of symptoms. Some of authors did not mentioned the type of therapy whether pharmacologic ones or surgical ones (Table 1).

For what concerns adult data, 29 cases were described and, as for pediatric population, a female prevalence was evident (M/F: 9/20) and 24 were symptomatic. Even in most of adult patient US allow to diagnose MSG with a median age at diagnosis of 35.5 years. In eighteen

* Corresponding author. Department of Medical Sciences, Surgery and Neuroscience, Section of Pediatric Surgery, University of Siena, Policlinico Le Scotte, Viale Bracci 14, 53100, Siena, Italy.

E-mail address: fmolidoc@me.com (F. Molinaro).

<https://doi.org/10.1016/j.epsc.2019.101212>

Received 26 February 2019; Received in revised form 5 April 2019; Accepted 8 April 2019

Available online 09 April 2019

2213-5766/ © 2019 The Authors. Published by Elsevier Inc. This is an open access article under the CC BY-NC-ND license (<http://creativecommons.org/licenses/by-nc-nd/4.0/>).

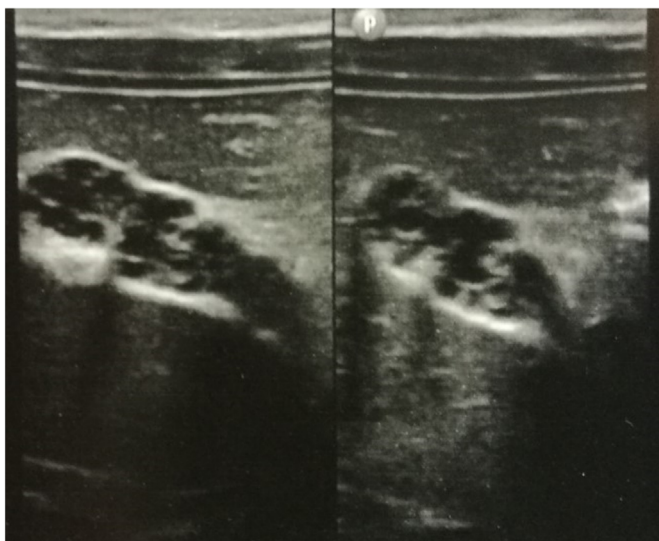


Fig. 1. US appearance: “Stretched morphology of gallbladder, almost completely contracted, with thickened and irregular walls. Lumen appears cranny. A dilatation of the common liver duct coexist. Multiple linear echoes, consistent with septa, are seen within the gallbladder, some of which crossed the lumen and connected to the opposing walls mimicking a honey-comb pattern. There were no gallstones or dilatation of the bile ducts, and the wall thickness of the gallbladder was normal.

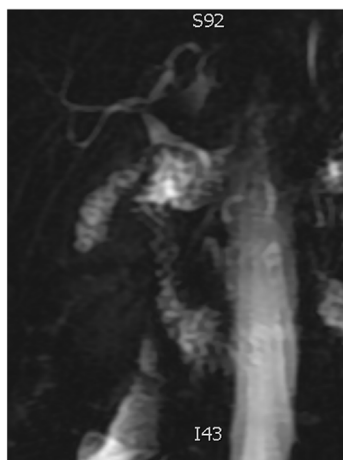


Fig. 2. MRCP: “contracted gallbladder with a cranny lumen and internally multiple septa. A dilatation of common liver duct is confirmed”.

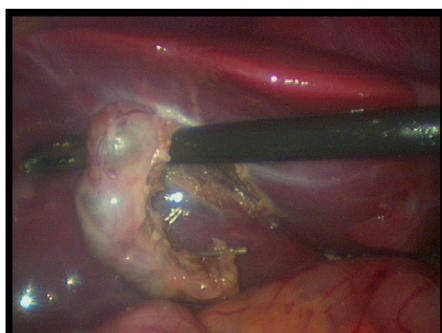


Fig. 3. Intra-operative view of laparoscopic cholecystectomy.

patients cholecystectomy was performed with recover [10–13].

Altogether, pediatric and adult cases showed a median age at diagnosis of 24.5 years.

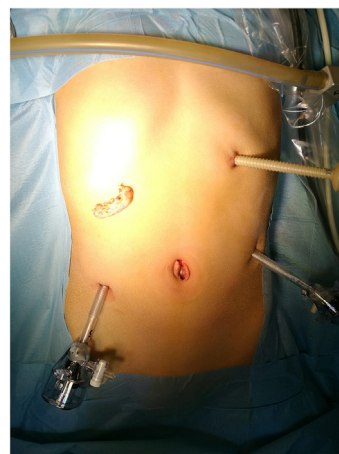

Fig. 4. Image of the removed MSG.

MSG is a rare congenital anomaly characterized by the presence of multiple septa lined by columnar epithelium dividing in many compartments of different sizes the lumen of gallbladder. The septa present small holes that allow communication between the above-mentioned compartments [27]. The septa may be complete, involving the entire lumen, or incomplete [2–4]. Multiple compartments confer a honey-combs appearance to the gallbladder [11]. Associated anomalies of the biliary ducts, such as ectopic gallbladder, choledochal cysts and anomalous junction of pancreatic and biliary ducts have been reported [28]. MSG has been reported even in association with hypoplasia of gallbladder, cholelithiasis, Phrygian cap, cholecystitis, and pancreaticobiliary ductal union [9,11,15,28–31].

The pathogenesis that underlies the development of MSG is not completely clear. It may be attributable to an incomplete cavitation of the embryonic gallbladder tissue that may result in MSG or development of stenosis. Another hypothesis affirm that the irregular wrinkling appearance of the gallbladder bud interferes with the properly formation of the lumen. The last hypothesis suggest a faster development of gallbladder than the surrounding structure leading to lack of space with consequent wrinklins and kinkings of the gallbladder [13,14,29].

Clinically, multiseptate gallbladder can be asymptomatic but most of patient present with biliary pain or colicky abdominal pain, usually localized in the epigastrium or right upper quadrant, sometimes irradiated in the back near the right scapula. Authors report symptomatic cases complicated by the presence of biliary sludge, stones and also cholecystitis [2,5,11,27,32]. The absence of these complication lead to delay in diagnosis and surgical treatment [13].

A delayed diagnosis of MSG often occur because recurrent abdominal pain in childhood is in most of cases due to intestinal or genitourinary etiologies. Indeed both cholelithiasis and cholecystitis are infrequent in pre-puberal age and generally related to bacterial and parasitic infections, hemolytic conditions or chronic gastrointestinal diseases [32].

Ultrasound (US) evaluation in patients with multiseptate gallbladder demonstrates a honeycomb appearance due to septa crossing the lumen of the gallbladder or multiple linear, fine echogenic bands without acoustic shadowing [2]. These sonographic findings help clinicians in differentiating desquamated gallbladder mucosa and hyperplastic cholecystoses than MSG. Indeed desquamated gallbladder mucosa is characterized by multiple linear echoes in the lumen which do not arise from the wall of the gallbladder and it is associated to clinical setting of acute cholecystitis [33].

MSG should also be considered in the differential diagnosis of polypoid cholesterosis and adenomyomatosis but in these cases there is bridging of the gallbladder lumen by the cyst-like Rokitsky-Aschoff sinuses or polypoid bulbous echoes. A further differential diagnosis is

Table 1
Pediatric cases of MSG.

Author	Year	Age	Sex	Symptoms	Associated anomalies	Diagnosis	Therapy
Haslam [14]	1966	15	F	+	–	NA ^a	Cholecistectomy
Pery [15]	1985	8	F	+	Choledochal cyst	US	Cholecistectomy
Fremont [16]	1989	13	F	+	–	US, cholecistography	Cholecistectomy
Adear [17]	1990	12	F	–	–	US	NA
Tan [18]	1993	14	F	+	Choledochal cyst	US, ERCP	Cholecistectomy
Strauss [5]	1993	3	M	–	–	US	NA
Strauss [5]	1993	9	F	+	–	US, CT	NA
Strauss [5]	1993	16	M	+	–	US	NA
Choulot [19]	1996	9	F	+	–	US	NA
Saddik [20]	1997	10	M	+	–	US, X-Ray	None
Kocakoc [21]	2003	9	M	+	–	US, RMCP	Cholecistectomy
Erdogmus [3]	2004	10	F	+	–	US	Cholecistectomy
Erdogmus [3]	2004	12	M	+	–	US	Cholecistectomy
Bahadır [22]	2006	15 days	M	+	Ectopic pancreas, choledochal cyst	US	Total excision of cyst and gallbladder
Demirpolat [6]	2010	5	F	+	–	US	None
Wanaguru [23]	2011	9 months	F	+	–	US, RMCP	None
Herliczek [24]	2011	11	M	+	–	US	None
Geremia [25]	2012	10	M	+	–	US, RMCP	None
Bordallo Vazquez [26]	2016	15 months	M	+	–	US, RMCP	None
Our case	2017	7	F	+	–	US, MRCP	Cholecistectomy

^a NA: not available.

with hydatid cyst: this one presents communication with the cystic duct and postprandial contraction of the gallbladder [6].

Ultrasound evaluation of the gallbladder is usually sufficient to diagnose MSG although even computed tomography, magnetic resonance cholangiopancreatography (MRCP) and endoscopic retrograde cholangiography (ERCP) can help to establish the diagnosis. The combination of US and MRCP is the most useful and the least invasive methods to diagnose multiseptate gallbladder [12].

Particularly, MRCP can show a grapelike cluster of the entire gallbladder interpreted as multiseptate gallbladder. Other authors report as MR imaging a multiple hypointense (compared to bile) septations in gallbladder consistent with MSG and a ‘honeycomb’ appearance of the gallbladder [34].

Moreover, we agree with previous authors that MR cholangiography, being a noninvasive method with no risk of ionizing radiation, may be used as an alternative method to endoscopic retrograde cholangiography to confirm or rule out multiseptate gallbladder, as in our case.

If MSG is symptomatic, the gold standard therapy is cholecystectomy. When choledochal cyst coexist, hepaticojejunostomy may be performed [35–37]. Indeed, cholecystectomy seems to relieve the symptoms and to avoid chronic infection and stone formation [37].

Patient consent

Consent to publish the case report was not obtained. This report does not contain any personal information that could lead to the identification of the patient.

Authorship

All authors attest that they meet the current ICMJE criteria for Authorship.

Conflict of interest

The following authors have no financial disclosures: MB, IB, GF, RA, SC, GDC, SE, MM, FM.

Funding

No funding or grant support.

References

- [1] Simon M, Tandon BN. Multiseptate gallbladder. A case report. *Radiology* 1963;80(1):84–6. <https://doi.org/10.1148/80.1.84>.
- [2] Lev-Toaff AS, Friedman AC, Rindsberg SN, Caroline DF, Maurer AH, Radecki PD. Multiseptate gallbladder: incidental diagnosis on sonography. *AJR Am J Roentgenol* 1987;148(6):1119–20. <https://doi.org/10.2214/ajr.148.6.1119>.
- [3] Erdogmus B, Yazici B, Ozdere BA, Akcan Y. Clinical and ultrasonographical findings in patients with multiseptate gallbladder. *Tohoku J Exp Med* 2004;204(3):215–9. <https://doi.org/10.1620/tjem.204.215>.
- [4] Meilstrup JW, Hopper KD, Thieme GA. Imaging of gallbladder variants. *Am J Roentgenol* 1991;157(6):1205–8. <https://doi.org/10.2214/ajr.157.6.1950867>.
- [5] Strauss S, Starinsky R, Alon Z. Partial multiseptate gallbladder. 1993. p. 201–3.
- [6] Demirpolat G, Duygulu G, Tamsel S. Multiseptate gallbladder in a child with recurrent abdominal pain. *Diagn Interv Radiol* 2010;16(4):306–7. <https://doi.org/10.4261/1305-3825.DIR.1926-08.0>.
- [7] Paciorek ML, Lackner D, Daly C, Sekas G. A unique presentation of multiseptate gallbladder. *Dig Dis Sci* 1997;42(12):2519–23. <http://www.ncbi.nlm.nih.gov/pubmed/9440630>, Accessed date: 13 February 2018.
- [8] Hahm KB, Yim DS, Kang JK, Park IS. Cholangiographic appearance of multiseptate gallbladder: case report and a review of the literature. *J Gastroenterol* 1994;29(5):665–8. <http://www.ncbi.nlm.nih.gov/pubmed/8000519>, Accessed date: 13 February 2018.
- [9] Tan CEL, Howard ER, Driver M. Non-communicating multiseptate gall bladder and choledochal cyst: a case report and review of publications. *Jpn J Gastroenterol* 1993;85:3–6.
- [10] Miwa W, Toyama K, Kitamura Y, Murakami K, Kamata K, Takada T, Tanabe HKM. Multiseptate gallbladder with cholelithiasis diagnosed incidentally in an elderly patient. *Int Med* 2000;39(12):1054–9.
- [11] Erdogmus B, Yazici B, Ozdere BA, Akcan Y. Clinical and ultrasonographical findings in patients with multiseptate gallbladder. *Tohoku J Exp Med* 2004;204(3):215–9. <http://www.ncbi.nlm.nih.gov/pubmed/15502421>, Accessed date: 12 February 2018.
- [12] Karaca T, Yoldas O, Bilgin BC, Bilgin S, Evcik E, Ozen S. Diagnosis and treatment of multiseptate gallbladder with recurrent abdominal pain. *Case Rep Med* 2011;2011:3–4. <https://doi.org/10.1155/2011/162853>.
- [13] Rivera-Troche EY, Hartwig MG, Vaslef SN. Multiseptate gallbladder. *J Gastrointest Surg* 2009;13(9):1741–3. <https://doi.org/10.1007/s11605-009-0880-0>.
- [14] Haslam RH, Gayler BWEP. Multiseptate gallbladder. A cause of recurrent abdominal pain in childhood. *Am J Dis Child* 1966;112(6):600–3.
- [15] Pery M, Kaftori JK, Marvan H, Sweed Y, Kerner H. Ultrasonographic appearance of multiseptate gallbladder: report a case with coexisting choledochal cyst. *J Clin Ultrasound* 1985;13(8):570–3. <http://www.ncbi.nlm.nih.gov/pubmed/3934221>, Accessed date: 13 February 2018.
- [16] Fremont B, Stasik C, Jouan H, Marcourelles P, Chapuis M, Treguiet CBJ. The multiseptate gallbladder. A rare malformation of the biliary tract. *Chir Pediatr* 1989;30(6):292–4.
- [17] Adear HB. Multiseptate gallbladder in a child: incidental diagnosis on sonography. *Pediatr Radiol* 1990;20(3):192.
- [18] Tan CE, Howard ER, Driver M, Murray-Lyon IM. Non-communicating multiseptate gall bladder and choledochal cyst: a case report and review of publications. *Gut* 1993;34(6):853–6. <http://www.ncbi.nlm.nih.gov/pubmed/8314522>, Accessed date: 13 February 2018.
- [19] Choulot JJ, Strainchamps P, Parent P, Saint-Martin JMA. Cas radiologique du mois. *Arch Pediatr* 1996(3):505–6.

- [20] Saddik D. *Ultrasound* 1998;374–6. May 1997.
- [21] Kocakoc E, Kiris A, Bozgeyik Z. Multiseptate gallbladder: MR and MR cholangiographic findings. *Abdom Imag* 2005;30(4):501. <https://doi.org/10.1007/s00261-005-0332-6>.
- [22] Bahadır B, Ozdamar SO, Gun BD, Bektas S, Numanoglu KV, Kuzey GM. Ectopic pancreas associated with choledochal cyst and multiseptate gallbladder. *Pediatr Dev Pathol* 2006;9(4):312–5. <https://doi.org/10.2350/10-05-0125.1>.
- [23] Wanaguru D, Jiwane A, Day AS, Adams S. Multiseptate gallbladder in an asymptomatic child. *Case Rep Gastrointest Med* 2011;2011:470658 <https://doi.org/10.1155/2011/470658>.
- [24] Herliczecz TW. Multiseptate gallbladder. *Indian J Gastroenterol* 2011;30(6):286. Nov-Dic.
- [25] Geremia P, Tomà P, Martinoli C, Camerini G, Derchi LE. Multiseptate gallbladder: clinical and ultrasonographic follow-up for 12 years. *J Pediatr Surg* 2013;48(2):e25–8. <https://doi.org/10.1016/j.jpedsurg.2012.11.053>.
- [26] Bordallo Vázquez M, Encinas Goenechea A, Gallego Mellado N, González Piñera J. Vesícula biliar multiseptada como hallazgo casual, ¿qué hacer? *An Pediatr* 2017;86(6):357–8. <https://doi.org/10.1016/j.anpedi.2015.12.009>.
- [27] Nakazawa T, Ohara H, Sano H, et al. Multiseptate gallbladder: diagnostic value of MR cholangiography and ultrasonography. *Abdom Imag* 2004;29(6):691–3. <https://doi.org/10.1007/s00261-004-0184-5>.
- [28] Türkvatan A, Erden A, Çelik M, Ölçer T. Ectopic hypoplastic and multiseptate gallbladder with coexisting choledochal cyst: evaluation with sonography and magnetic resonance cholangiopancreatography. *J Clin Ultrasound* 2006;34(2):88–91. <https://doi.org/10.1002/jcu.20207>.
- [29] Bhagavan BS, Amin PB, Land AS, Weinberg T. Multiseptate gallbladder. Embryogenetic hypotheses. *Arch Pathol* 1970;89(4):382–5 <http://www.ncbi.nlm.nih.gov/pubmed/5435679>. Accessed date: 13 February 2018.
- [30] Jena PK, Hardie RA, Hobsley M. Multiseptate hypoplastic gallbladder. *Br J Surg* 1977;64(3):192–3 <http://www.ncbi.nlm.nih.gov/pubmed/890264>. Accessed date: 13 February 2018.
- [31] Yamamoto T, Matsumoto J, Hashiguchi S, Yamaguchi A, Sakoda K, Taki C. Multiseptate gallbladder with anomalous pancreaticobiliary ductal union: a case report. *World J Gastroenterol* 2005;11(38):6066–8 <http://www.ncbi.nlm.nih.gov/pubmed/16273627>. Accessed date: 13 February 2018.
- [32] Esper E, Kaufman DB, Crary GS, Snover DC, Leonard AS. Septate gallbladder with cholelithiasis: a cause of chronic abdominal pain in a 6-year-old child. *J Pediatr Surg* 1992;27(12):1560–2 <http://www.ncbi.nlm.nih.gov/pubmed/1469574>. Accessed date: 13 February 2018.
- [33] Wales L. Desquamated gallbladder mucosa: unusual sign of cholecystitis. *Am J Roentgenol* 1982;139(4):810–1. <https://doi.org/10.2214/ajr.139.4.810>.
- [34] Kocakoca E, Kirisa A, Alkanb A, Bozgeyika Z, Senc HO Y. Multiseptate gallbladder in a child with chronic abdominal pain: ultrasonography, magnetic resonance imaging and magnetic resonance cholangiography findings. *Eur J Radiol Extra* 2003;47(1):22–5.
- [35] Toombs BD, Foucar E, Rowlands BJ, Strax R. Multiseptate gallbladder. *South Med J* 1982;75(5):610–2 <http://www.ncbi.nlm.nih.gov/pubmed/7079823>. Accessed date: 18 February 2018.
- [36] Spech HJ, Hümmer N, Braun H. [Septate gallbladder (author's transl)]. *Med Klin* 1975;70(21):941–6 <http://www.ncbi.nlm.nih.gov/pubmed/1152800>. Accessed date: 18 February 2018.
- [37] Oliva Oliva I, Rodriguez Moran M, Lozano Sanchez F, Gomez Alonso A. Multiseptate gallbladder. *Int Surg*. 70(1):83-84. <http://www.ncbi.nlm.nih.gov/pubmed/4019093>. Accessed February 18, 2018.