



Title	Validation of the 8th edition of the AJCC/UICC TNM staging system for tongue squamous cell carcinoma
Author(s)	Kano, Satoshi; Sakashita, Tomohiro; Tsushima, Nayuta; Mizumachi, Takatsugu; Nakazono, Akira; Suzuki, Takayoshi; Yasukawa, Shinichiro; Homma, Akihiro
Citation	International journal of clinical oncology, 23(5), 844-850 <a href="https://doi.org/10.1007/s10147-018-1276-5">https://doi.org/10.1007/s10147-018-1276-5</a>
Issue Date	2018-10
Doc URL	<a href="http://hdl.handle.net/2115/73689">http://hdl.handle.net/2115/73689</a>
Rights	This is a post-peer-review, pre-copyedit version of an article published in International Journal of Clinical Oncology. The final authenticated version is available online at: <a href="http://dx.doi.org/10.1007/s10147-018-1276-5">http://dx.doi.org/10.1007/s10147-018-1276-5</a>
Type	article (author version)
File Information	IJCO23_844.pdf



[Instructions for use](#)

# **Validation of the 8<sup>th</sup> edition of the AJCC/UICC TNM staging system for tongue squamous cell carcinoma**

Satoshi Kano, M.D., Ph.D.<sup>1</sup>, Tomohiro Sakashita, M.D., Ph.D.<sup>1</sup>, Nayuta Tsushima, M.D., Takatsugu Mizumachi, M.D., Ph.D.<sup>1</sup>, Akira Nakazono, M.D.<sup>1</sup>, Takayoshi Suzuki, M.D.<sup>1</sup>, Shinichiro Yasukawa, M.D.<sup>1</sup>, Akihiro Homma, M.D., Ph.D.<sup>1</sup>

<sup>1</sup> Department of Otolaryngology-Head and Neck Surgery, Faculty of Medicine and Graduate School of Medicine, Hokkaido University, Sapporo, Japan.

**Corresponding author:** Satoshi Kano, Department of Otolaryngology-Head and Neck Surgery, Faculty of Medicine and Graduate School of Medicine, Hokkaido University, Kita 15, Nishi 7, Kita-ku, Sapporo 060-8638, Japan,  
Tel: +81-11-706-5958, Fax: +81-11-717-7566  
E-mail: skano@med.hokudai.ac.jp

## **Abstract**

**Background.** The revised 8<sup>th</sup> edition of the AJCC/UICC staging system was released in January 2017, and depth of invasion (DOI) was added to the new criteria for T classification in oral cavity cancer. In this study, we evaluated whether the 8<sup>th</sup> edition presents the prognosis and risk of nodal metastasis in patients with squamous cell carcinoma of tongue more accurately than did the 7<sup>th</sup> edition.

**Methods.** The data for 112 patients were obtained and reclassified based on the criteria presented in the 8<sup>th</sup> edition.

**Results.** Seven patients previously staged as T1 based on the criteria in the 7<sup>th</sup> edition were reclassified as T2 based on the 8<sup>th</sup> edition, while 19 T2 patients were reclassified as T3, and 9 T4a patients were reclassified as T3. T3 in the 8<sup>th</sup> edition represents a homogenous population showing the same prognosis, while T2 in the 8<sup>th</sup> edition represents a heterogenous population. Nodal metastasis was significantly correlated with T classification in both editions and DOI. However, neither the T classification in the 7<sup>th</sup> or 8<sup>th</sup> edition, nor DOI could predict the probability of potential nodal metastasis in patients with cN0 disease.

**Conclusions.** The classification on T3 in the 8<sup>th</sup> edition can be seen as reasonable with regard to prognosis. Nodal metastasis was significantly correlated with T classification

and DOI; however, the probability of subsequent nodal metastasis in patients with T2N0 was almost same for the criteria in the 7<sup>th</sup> and 8<sup>th</sup> editions, therefore the same careful management as before is required for patients with N0 disease.

**Keywords:** the 8<sup>th</sup> edition of the AJCC/UICC TNM staging system, tongue cancer, depth of invasion

## **Introduction**

Tongue squamous cell carcinoma (SCC) is the most common malignancy of the oral cavity. [1,2] The presence of cervical lymph node metastasis is the most important prognostic factor for survival, [3] and tumor thickness or depth of invasion (DOI) of the primary lesion has been reported to be associated with an increased risk of lymph node metastasis. [4,5] Therefore, the need for prophylactic neck dissection in patients with cN0 tongue cancer is often based on the radiographic assessment of DOI in addition to tumor size. Evaluation of DOI is generally performed with the use of magnetic resonance imaging (MRI), and several studies have shown that there are strong correlations between pathological and radiographic measurements of DOI or tumor thickness. [6-11] However, DOI has not been reflected in the T classification of oral cavity cancer up to the 7<sup>th</sup> edition of the AJCC/UICC TNM staging system.

The revised 8<sup>th</sup> edition of the AJCC/UICC staging system was released in January 2017, and DOI was added to the new criteria for T classification in oral cavity cancer (Table 1). The DOI is now one of the staging criteria for T1, T2 and T3. On the other hand, extrinsic muscle infiltration is no longer a staging criterion for T4a disease as it has been superseded by DOI and extrinsic muscle invasion is difficult to assess clinically and radiographically.

In this study, we evaluated whether the 8<sup>th</sup> edition of the AJCC/UICC TNM staging system represents the prognosis and risk of cervical lymph node metastasis in patients with SCC of tongue more accurately than did the 7<sup>th</sup> edition.

## **MATERIALS AND METHODS**

### **Patients**

This is a retrospective study using the medical records of patients with head and neck cancers treated at Hokkaido University Hospital between January 2005 and December 2014. The inclusion criteria for this study were as follows: (1) previously untreated tongue cancer, (2) histologically proven SCC, and (3) treatment with curative intent.

The exclusion criteria for this study were as follows: (1) unavailable pretreatment MRI or CT, (2) unevaluable images due to artifacts, and (3) histologically diagnosed carcinoma in situ. A total of 136 patients satisfied the inclusion criteria, among which 24 patients were later excluded from this study, so that the data for 112 patients were obtained and analyzed in this study. Of the 112 patients, 72 were male and 40 were female. The median patient age was 63 years (range 21-95 years). The median follow-up period for the survivors was 5.2 years (range 0.3-11.7 years). The present study was approved by the Institutional Ethics Review Board of the ethics committee of

our institution.

### **Treatment**

One hundred and seven patients received surgical treatment and 5 patients received non-surgical treatment consisting of brachytherapy (n=2) or concurrent chemoradiotherapy by intra-arterial administration of cisplatin (n=3). Of the 107 patients treated with surgery, ND was performed in 53 patients and post-operative radiotherapy was performed in 21 patients.

### **Image analysis**

T classification of the tongue tumors was evaluated by clinical examination and enhanced MRI. Plain MRI or computed tomography (CT) scans were acceptable for patients who could not tolerate enhanced MRI. DOI on the MRI or CT scan was measured as follows. The reference line was determined as a horizontal line connecting the mucosal junctions of the tumor, and the length of the line perpendicular to this line and running towards the deepest point of tumor infiltration was measured (Figure 1). If the tumor was ulcerative, the reference line was determined in the same way in consideration of the presumed original surface level, exophytic lesions were ignored and length measurement was simplified to represent invasion ability. When the tongue tumor could not be identified despite the absence of artifacts, the DOI was judged to be

5 mm or less.

The lymph node metastasis was diagnosed by comprehensive judgment using the ultrasonography, CT and positron emission tomography.

### **Statistical analysis**

The disease-specific survival (DSS) curve and probability of nodal metastasis were calculated using the Kaplan-Meier method and differences were assessed by the log-rank test. All tests were two-sided, and P values <0.05 were considered to be statistically significant. Statistical analyses were performed using BellCurve for Excel (Social Survey Research Information Co., Ltd.).

## **RESULTS**

### **The shift in T classification among patients with tongue squamous cell carcinoma based on the change from the 7<sup>th</sup> to the 8<sup>th</sup> edition of the AJCC/UICC TNM staging system**

The distribution of the T classifications based on the 7<sup>th</sup> edition of the AJCC/UICC TNM stage is shown in Figure 2. Of the 112 patients, 27 (24%), 54 (48%), 20 (18%), 10 (9%), and 1 (1%) were diagnosed with T1, 2, 3, 4a and 4b disease, respectively. After reclassification based on the 8th edition, 7 patients previously staged as T1 based on the



criteria in the 7<sup>th</sup> edition were reclassified as T2 based on the 8<sup>th</sup> edition, while 19 T2 patients were reclassified as T3, and 9 T4a patients were reclassified as T3. According to this reclassification, 20 cases (18%), 42 (37%), 48 (43%), 1 (1%), and 1 (1%) were finally diagnosed with T1, 2, 3, 4a and 4b disease based on the in the 8<sup>th</sup> edition, respectively. As for nodal metastasis, 76 cases (68%) were diagnosed with N0, 11 (10%) with N1, 18 (16%) with N2b, 5 (4%) with N2c and 2 (2%) with N3 disease using the N classification based on the 7<sup>th</sup> edition. After reclassification using the 8<sup>th</sup> edition, 2 cases classified as N2b and 2 cases classified as N3 based on the 7<sup>th</sup> edition were reclassified as N3b. Of 76 patients staged as N0 at the first visit, 11 patients were diagnosed as pathologically lymph node metastasis by the prophylactic ND, and 13 patients developed subsequent lymph node metastasis.

### **Survival outcomes**

Figure 3A and 3B show the DSS curves stratified according to T classification based on the 7<sup>th</sup> and 8<sup>th</sup> editions of the AJCC/UICC TNM stage, respectively. Progression of the primary disease was significantly correlated with DSS based on both the 7<sup>th</sup> and 8<sup>th</sup> editions (log-rank test:  $P < 0.01$ ). A comparison of the survival rates by T classification based on the 7<sup>th</sup> and 8<sup>th</sup> editions revealed that the 5-year DSS for T2 disease improved from 76.5% to 85.2%; however, there were no changes observed for T1 or T3 disease.

When the survival analysis was limited to patients with T2 disease as classified by the 8<sup>th</sup> edition, the DSS curves for T1 and T2 based on the 7<sup>th</sup> edition were observed to diverge, although there was no significant differences (Figure 3C, log-rank test:  $P = 0.24$ ). On the other hand, for patients with T3 disease as classified by the 8<sup>th</sup> edition, the DSS curves for T2, T3 and T4a based on the 7<sup>th</sup> edition were almost overlapping (Figure 3D, log-rank test:  $P = 0.64$ ). Furthermore, when the survival analysis was limited to patients with T1 disease as classified by the 7<sup>th</sup> edition, the DSS curves of T1 and T2 based on the 8<sup>th</sup> edition showed an almost similar trend (Figure 3E, log-rank test:  $P = 0.55$ ). However, in patients with T2 disease as classified by the 7<sup>th</sup> edition, the DSS curves for T2 and T3 based on the 8<sup>th</sup> edition were observed to diverge, although there was no significant differences (Figure 3F, log-rank test:  $P = 0.10$ ).

To further investigate the correlation between the DOI of the primary tumor and survival rate, the DSS curves stratified according to the DOI were drawn (Figure 4A and 4B). As a result, no significant differences were observed between the groups separated by a DOI of 5 mm (log-rank test:  $P = 0.30$ ), but significant differences were observed between the groups separated by a DOI of 10 mm (log-rank test:  $P < 0.01$ ).

### **Lymph nodal metastasis**

Patients with radiologically or pathologically assessed lymph node metastasis during the

observation period were regarded as having lymph node metastasis, although this study excluded patients whose lymph nodes were radiologically positive but pathologically negative. Three patients were diagnosed as lymph node metastasis only by the radiological assessment. Figure 5A and 5B show the number of node metastasis-positive cases according to T classification based on the criteria in the 7<sup>th</sup> and 8<sup>th</sup> edition. Lymph node metastasis was significantly increased with progression in T classification for both editions (log-rank test:  $P < 0.01$ ); however, there was little difference between the two editions. Furthermore, analysis of the correlation between the DOI of primary tumor and nodal metastasis revealed that the DOI was significantly correlated with nodal metastasis (Figure 5C, log-rank test:  $P < 0.01$ ).

In addition, analysis of the probability of nodal metastasis was performed in patients staged as cN0 at the first visit. In consideration of the influence on the neck, the patients who received radiotherapy to the neck and systemic chemotherapy before the occurrence of nodal metastasis were excluded from this analysis. A comparison of the probability of nodal metastasis in patients with cN0 stratified according to T classification based on the 7<sup>th</sup> and 8<sup>th</sup> editions showed that early lymph node recurrence decreased in patients with T1 disease as classified in the 8<sup>th</sup> edition. There was little difference in the probability of nodal metastasis for T2 disease between the 7<sup>th</sup> and 8<sup>th</sup>

editions, while that for T3, as classified in the 8<sup>th</sup> edition, increased (Figure 6A and 6B).

A comparison of the probability of nodal metastasis and the DOI revealed that there was no significant difference between the groups separated by a DOI of 5 or 10 mm (Figure 7A and 7B, log-rank test: P = 0.39 and 0.91).

## **DISCUSSION**

DOI was added to the new criteria for T classification in oral cavity cancer in the 8<sup>th</sup> edition of the AJCC/UICC staging system, and was defined as distinct from tumor thickness. However, there is no clear definition for the method of measurement of the DOI. In this study, following the measurement method used in previous reports, the reference line was determined as a horizontal line connecting the mucosal junctions of the tumor, and the length of the line perpendicular to this line and running towards the deepest point of tumor infiltration was measured (Figure 1). [6-8] The radiological DOI of preoperative tumors was clearly correlated with the pathological DOI of resected tumors in every report; therefore, this measurement method was considered to be useful for evaluating the DOI of preoperative tumors. However, the more a primary tumor develops, the more the reference line, which represents the hypothetical basement membrane, diverges from the actual line of the basement membrane. Although no

patients corresponding to this condition were included in this study, it is necessary to improve the measurement method for large tumors of the tongue.

We examined whether the new system of classification more correctly reflects the prognosis than the old one. Based on the results shown in figure 3C and D, T3 in the 8<sup>th</sup> edition represents a homogenous population showing the same prognosis, while T2 in the 8<sup>th</sup> edition represents a heterogenous population. Additionally, T1 in the 7<sup>th</sup> edition represented a homogenous population showing the same prognosis, while T2 in the 7<sup>th</sup> edition represented a heterogenous population (Figure 3E and F). These results suggested that T3 as classified in the 8<sup>th</sup> edition is regarded as reasonable with regard to prognosis, and T1 as classified in the 7<sup>th</sup> edition is regarded as more reasonable than T2 in the 8<sup>th</sup> edition. The reason for this is that patients with a DOI of 5 mm or more, reclassified from T1 in the 7<sup>th</sup> edition to T2 in the 8<sup>th</sup> edition, had a similarly good prognosis to those with T1 disease in the 8<sup>th</sup> edition (Figure 3E). Actually, a significant difference was observed between the groups separated by a DOI of 10 mm; however, there were no significant differences between the groups separated by a DOI of 5 mm (Figure 4A). One of the reasons could be that it is difficult to measure a DOI of 5 mm accurately using the MRI or CT. The cut-off values for tumor thickness and DOI have been controversial in previous reports. O'Brien et al. reported that differences in the

survival rate were observable for a tumor thickness of 4 mm, [12] whereas Jung et al. reported that the survival rate showed significant differences with a cut-off value for DOI of 9mm. [8] Regarding prognosis, analysis of data from a greater number of patients is required to better clarify the cut-off value for the DOI and the validity of T2 criteria as presented in the 8<sup>th</sup> edition.

This study showed that lymph node metastasis was significantly correlated with T classification in both editions (Figure 5A and 5B). The DOI was also significantly correlated with lymph node metastasis (Figure 5C), with similar results reported by several authors. [7,8,10] However, neither the T classification in the 7<sup>th</sup> or 8<sup>th</sup> edition, nor the DOI could predict the probability of nodal metastasis in patients with cN0 disease at the first visit (Figure 6 and 7). According to the results shown in figure 6B, no early lymph node metastasis was observed in patients classified as T1N0 based on the 8<sup>th</sup> edition; therefore, prophylactic neck dissection could be avoided in these patients. However, prophylactic neck dissection cannot be neglected for all patients with a DOI  $\leq$  5 mm tumor. Figure 7A shows that early lymph node metastasis is not necessarily rare in patients with a tumor DOI  $\leq$  5 mm. Regarding patients with T2N0, the probability of nodal metastasis was almost same for the criteria in the 7<sup>th</sup> and 8<sup>th</sup> editions (Figure 6A and 6B). Although T2N0 has been the most controversial clinically

with regard to the performance of prophylactic neck dissection, the new classification system could not solve this important problem. Furthermore, figure 7B shows that some of patients with a DOI > 10 mm were followed without lymph nodal metastasis after only resection of the primary tumor. There is no doubt that the DOI is correlated with nodal metastasis; however, these results suggested the existence of other factors associated with nodal metastasis regardless of DOI. Therefore, careful management is still required for patients with N0 disease, regardless of T classification or DOI.

In conclusion, stage T3 as classified in the 8<sup>th</sup> edition was regarded as a reasonable in terms of prognosis, while T2, as classified in the 8<sup>th</sup> edition, represents a heterogenous population. Lymph nodal metastasis was significantly correlated with T classification and DOI in both editions; however, the same careful management as before is required for patients with N0 disease, regardless of T classification or DOI.

## **Conflict of Interest**

No authors has any conflict of interest.



## REFERENCES

1. Johnson NW, Jayasekara P, Amarasinghe AA (2011) Squamous cell carcinoma and precursor lesions of the oral cavity: epidemiology and aetiology. *Periodontol* 2000 57:19-37
2. Patel SC, Carpenter WR, Tyree S, et al. (2011) Increasing incidence of oral tongue squamous cell carcinoma in young white women, age 18 to 44 years. *J Clin Oncol* 29:1488-1494
3. Taniguchi Y, Okura M (2003) Prognostic significance of perioperative blood transfusion in oral cavity squamous cell carcinoma. *Head Neck* 25:931-936
4. Fukano H, Matsuura H, Hasegawa Y, et al. (1997) Depth of invasion as a predictive factor for cervical lymph node metastasis in tongue carcinoma. *Head Neck* 19:205-210
5. Layland MK, Sessions DG, Lenox J (2005) The influence of lymph node metastasis in the treatment of squamous cell carcinoma of the oral cavity, oropharynx, larynx, and hypopharynx: N0 versus N+. *Laryngoscope* 115:629-639
6. Alsaffar HA, Goldstein DP, King EV, et al. (2016) Correlation between clinical and MRI assessment of depth of invasion in oral tongue squamous cell carcinoma. *J Otolaryngol Head Neck Surg* 45:61. doi:10.1186/s40463-016-0172-0

7. Goel V, Parihar PS, Parihar A, et al. (2016) Accuracy of MRI in Prediction of Tumour Thickness and Nodal Stage in Oral Tongue and Gingivobuccal Cancer With Clinical Correlation and Staging. *J Clin Diagn Res* 10:TC01-05. doi:10.7860/JCDR/2016/17411.7905
8. Jung J, Cho NH, Kim J, et al. (2009) Significant invasion depth of early oral tongue cancer originated from the lateral border to predict regional metastases and prognosis. *Int J Oral Maxillofac Surg* 38:653-660
9. Lwin CT, Hanlon R, Lowe D, et al. (2012) Accuracy of MRI in prediction of tumour thickness and nodal stage in oral squamous cell carcinoma. *Oral Oncol* 48:149-154
10. Park JO, Jung SL, Joo YH, et al. (2011) Diagnostic accuracy of magnetic resonance imaging (MRI) in the assessment of tumor invasion depth in oral/oropharyngeal cancer. *Oral Oncol* 47:381-386
11. Tsushima N, Sakashita T, Homma A, et al. (2016) The role of prophylactic neck dissection and tumor thickness evaluation for patients with cN0 tongue squamous cell carcinoma. *Eur Arch Otorhinolaryngol* 273:3987-3992
12. O'Brien CJ, Lauer CS, Fredricks S, et al. (2003) Tumor thickness influences prognosis of T1 and T2 oral cavity cancer--but what thickness? *Head Neck*

25:937-945

## **FIGURE LEGENDS**

### **Figure1. Depth of invasion (DOI) on magnetic resonance (MR) images.**

DOI on MR images (A: axial view, B: coronal view) was measured from point of deepest tumor invasion (double-headed arrow) to the presumed original surface level (straight line) ignoring exophytic growth.

### **Figure 2. Shift in T classification among patients with tongue squamous cell carcinoma from the 7<sup>th</sup> to the 8<sup>th</sup> edition of the AJCC/UICC TNM staging system.**

Seven patients previously staged as T1 based on the criteria in the 7<sup>th</sup> edition were reclassified as T2 based on the 8<sup>th</sup> edition, while 19 T2 patients were reclassified as T3, and 9 T4a patients were reclassified as T3.

### **Figure 3. Kaplan-Meier curves for disease-specific survival (DSS) stratified by T classification.**

(A) DSS curves stratified by T classification based on the 7<sup>th</sup> edition of the AJCC/UICC TNM stage (the 5-year DSS for T1 94.7%, T2 76.5%, T3 68.4%, T4 42.4%). (B) DSS curves stratified by T classification based on the 8<sup>th</sup> edition (the 5-year DSS for T1 92.9%, T2 85.2%, T3 63.2%). (C) DSS curves stratified by T1 and T2 based on the 7<sup>th</sup> edition in patients with T2 disease as classified by the 8<sup>th</sup> edition (the 5-year DSS for T1

in the 7<sup>th</sup> edition 100%, T2 in the 7<sup>th</sup> edition 82.1%). (D) DSS curves stratified by T2, T3 and T4a based on the 7<sup>th</sup> edition in patients with T3 disease as classified by the 8<sup>th</sup> edition (the 5-year DSS for T2 in the 7<sup>th</sup> edition 66.9%, T3 in the 7<sup>th</sup> edition 68.4%, T4a in the 7<sup>th</sup> edition 44.4%). (E) DSS curves stratified by T1 and T2 based on the 8<sup>th</sup> edition in patients with T1 disease as classified by the 7<sup>th</sup> edition (the 5-year DSS for T1 in the 8<sup>th</sup> edition 92.9%, T2 in the 8<sup>th</sup> edition 100%). (F) DSS curves stratified by T2 and T3 based on the 8<sup>th</sup> edition in patients with T2 disease as classified by the 7<sup>th</sup> edition (the 5-year DSS for T2 in the 8<sup>th</sup> edition 82.1%, T3 in the 8<sup>th</sup> edition 66.9%).

**Figure 4. Kaplan-Meier curves for disease-specific survival (DSS) stratified by depth of invasion (DOI).**

(A) DSS curves for tumors with a DOI of 5 mm or less and a DOI of more than 5 mm (the 5-year DSS for DOI  $\leq$  5 mm 81.2%, DOI  $>$  5 mm 74.3%). (B) DSS curves for tumors with a DOI of 10 mm or less and a DOI of more than 10 mm (the 5-year DSS for DOI  $\leq$  10 mm 86.0%, DOI  $>$  10 mm 62.9%).

**Figure 5. The probabilities of nodal metastasis stratified by T classification and DOI.**

(A) The probabilities of nodal metastasis stratified by T classification based on the 7<sup>th</sup> edition of the AJCC/UICC TNM stage (the probability for T1 23.1%, T2 52.3%, T3

70.0%, T4 81.8%). (B) The probabilities of nodal metastasis stratified by T classification based on the 8<sup>th</sup> edition (the probability for T1 20.6%, T2 45.7%, T3 66.7%, T4 100%). (C) The probabilities of nodal metastasis stratified by DOI (DOI  $\leq$  5 mm 32.5%, 5 mm < DOI  $\leq$  10 mm 46.9%, DOI > 10 mm 66.7%).

**Figure 6. The probabilities of nodal metastasis in patients with cN0 stratified by T classification.**

(A) The probabilities of nodal metastasis stratified by T classification based on the 7<sup>th</sup> edition of the AJCC/UICC TNM stage (the probability for T1 16.9%, T2 43.7%, T3 0%).

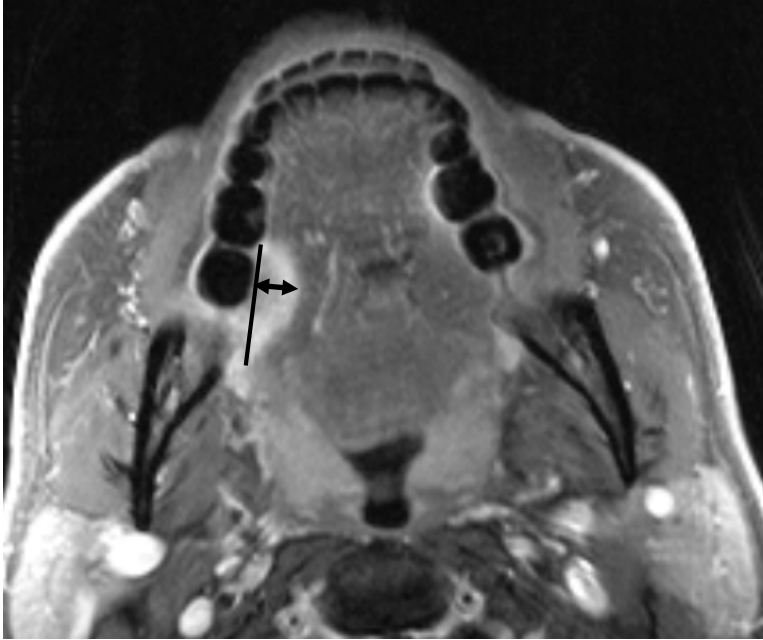
(B) The probabilities of nodal metastasis stratified by T classification based on the 8<sup>th</sup> edition (the probability for T1 11.8%, T2 42.2%, T3 25.0%).

**Figure 7. The probabilities of nodal metastasis in patients with cN0 stratified by depth of invasion.**

(A) The probabilities of nodal metastasis for tumors with a DOI of 5 mm or less and a DOI of more than 5 mm DOI (the probability for DOI  $\leq$  5 mm 28.3%, DOI > 5 mm 35.3%). (B) The probabilities for nodal metastasis for tumors with a DOI of 10 mm or less and a DOI of more than 10 mm (the probabilities for DOI  $\leq$  10 mm 32.4%, DOI > 10 mm 30.8%).

Figure 1

A



B

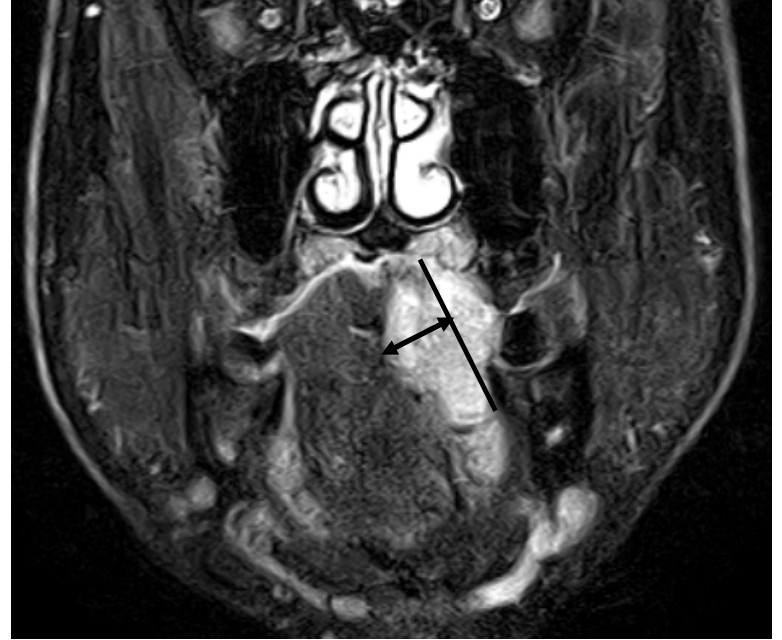

Figure 2

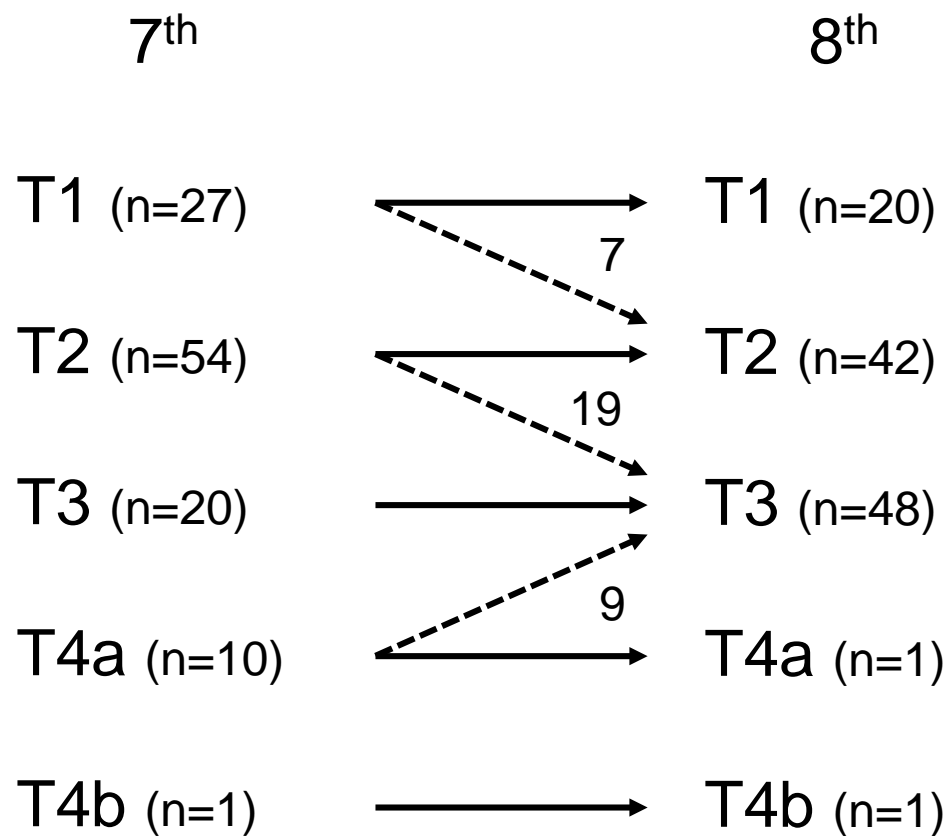




Figure 3

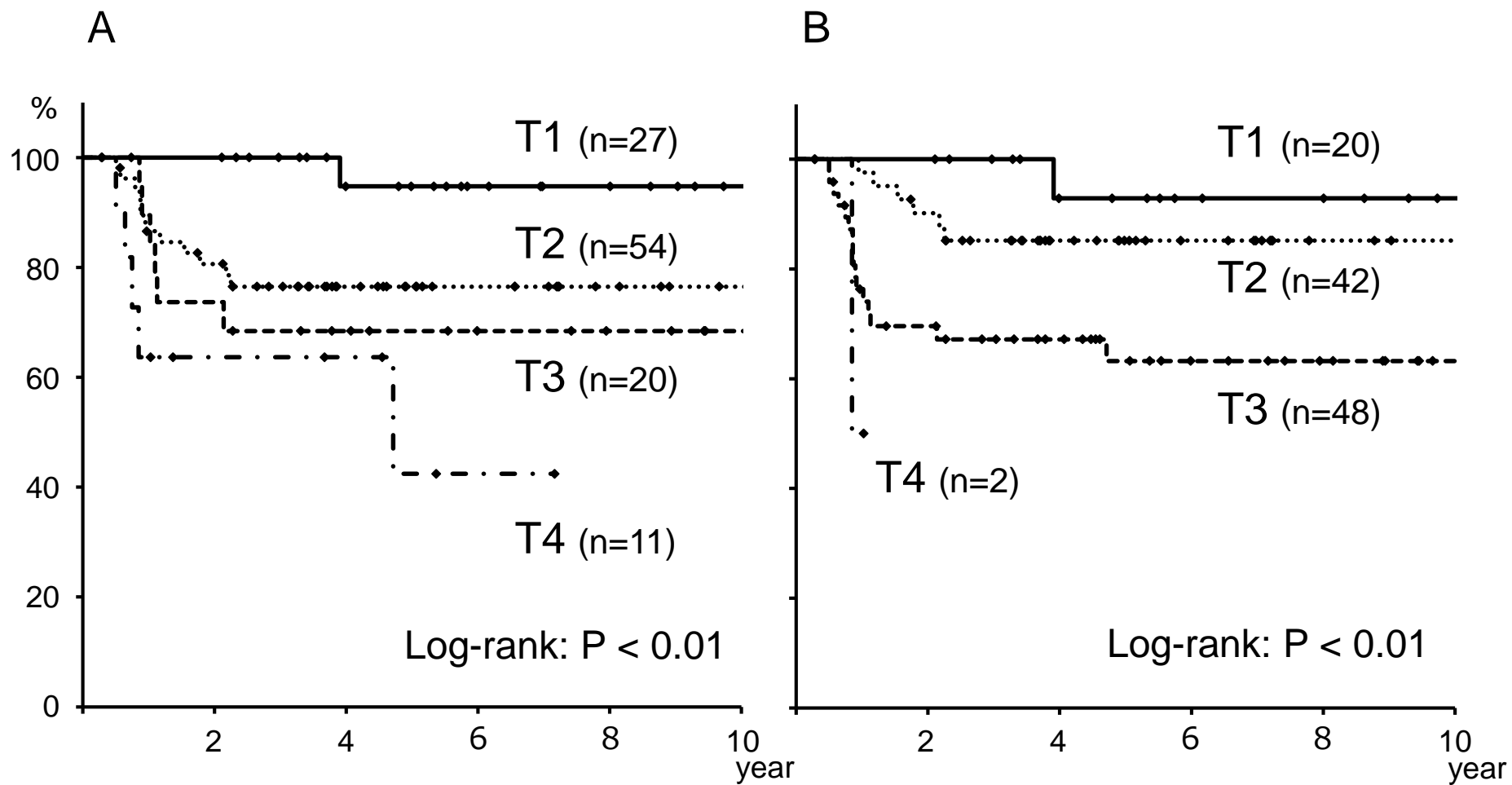


Figure 3

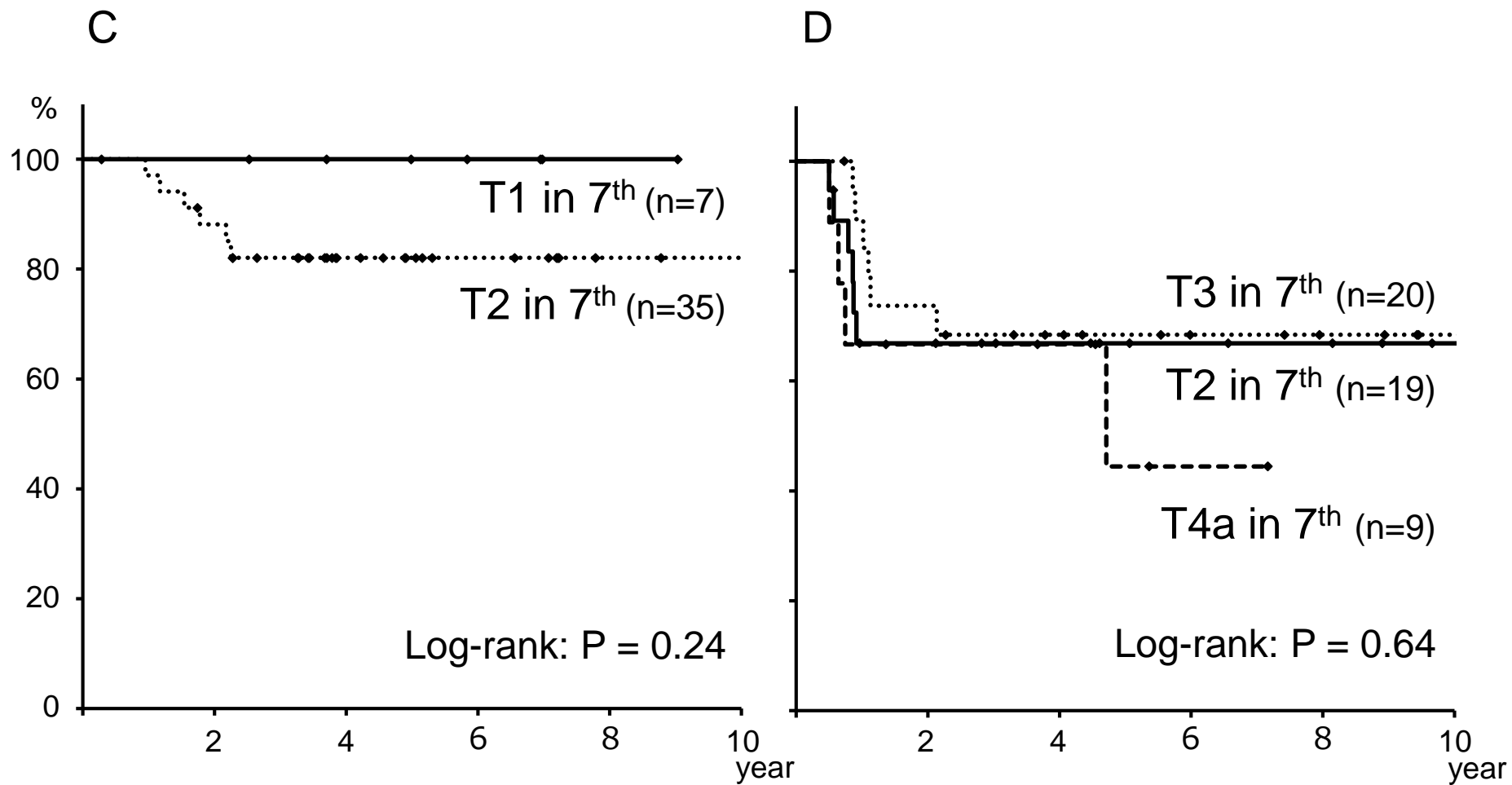


Figure 3

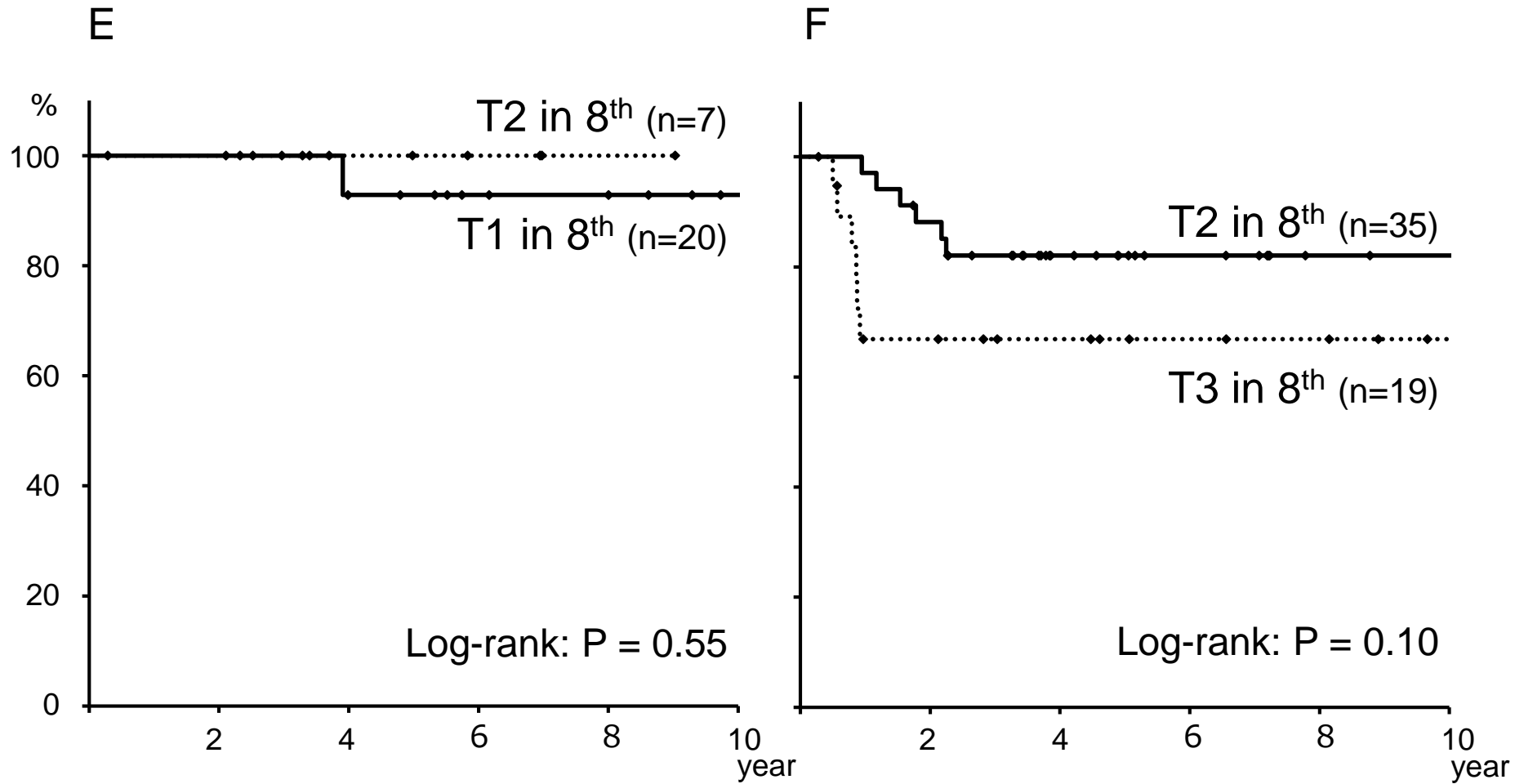


Figure 4

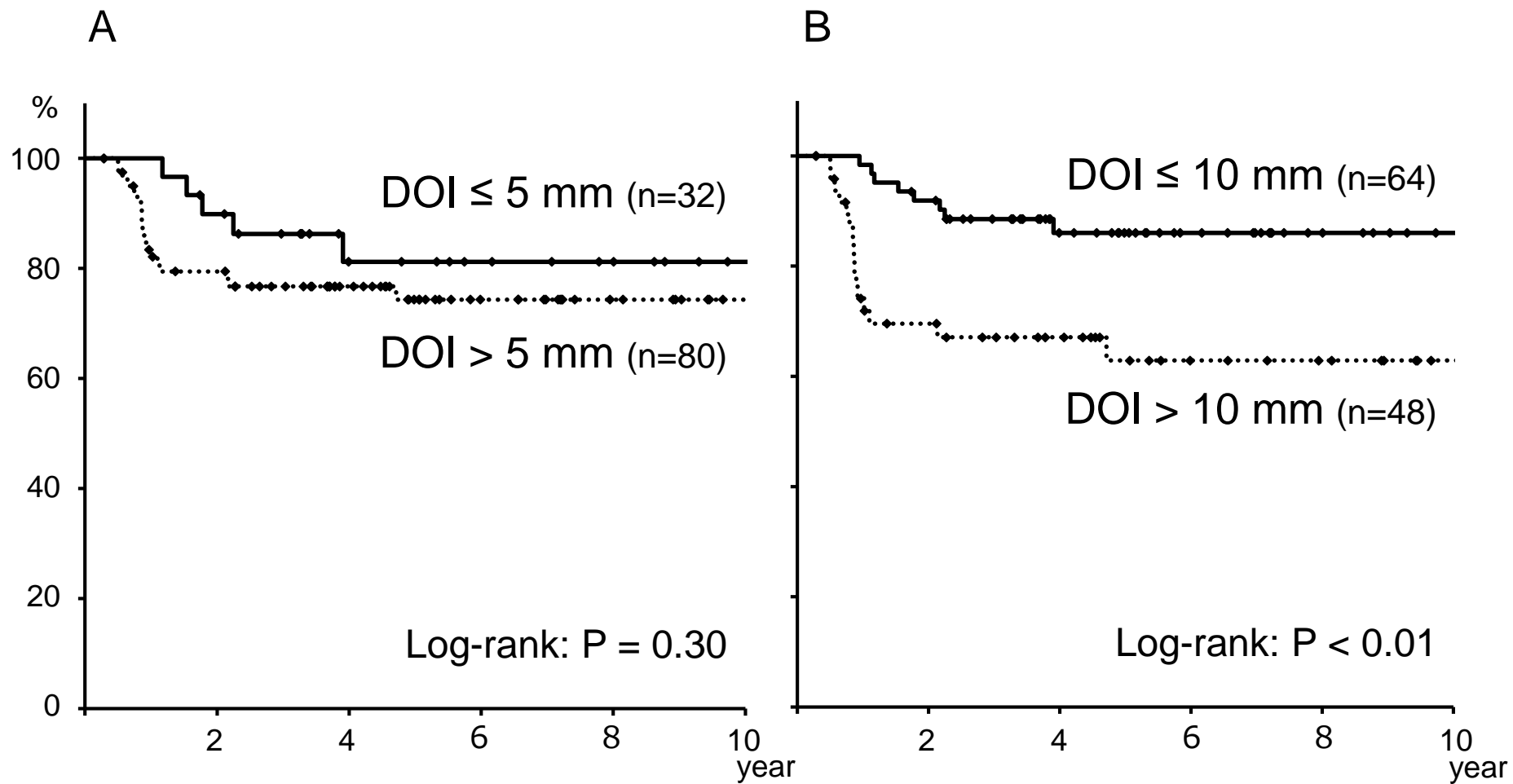


Figure 5

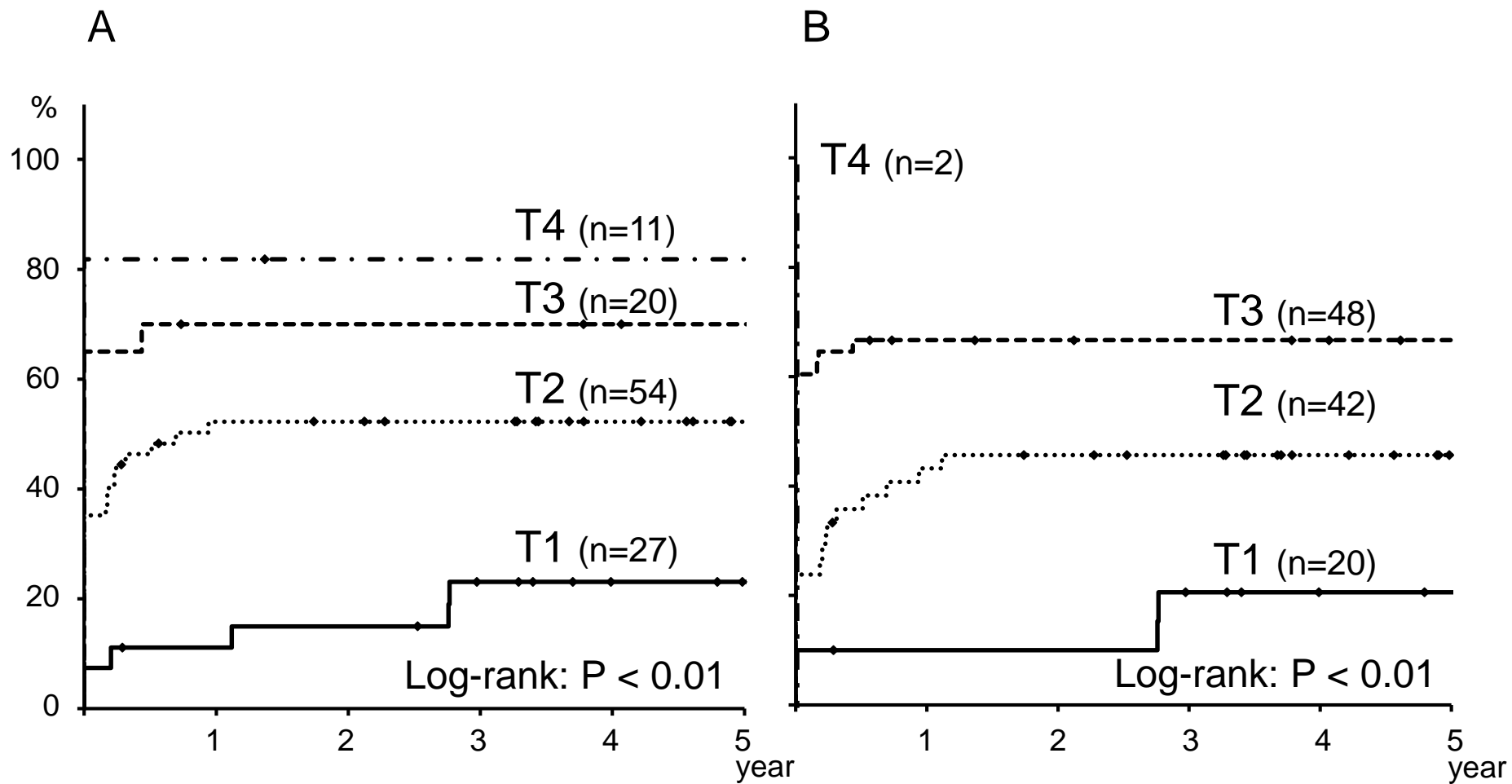


Figure 5

C

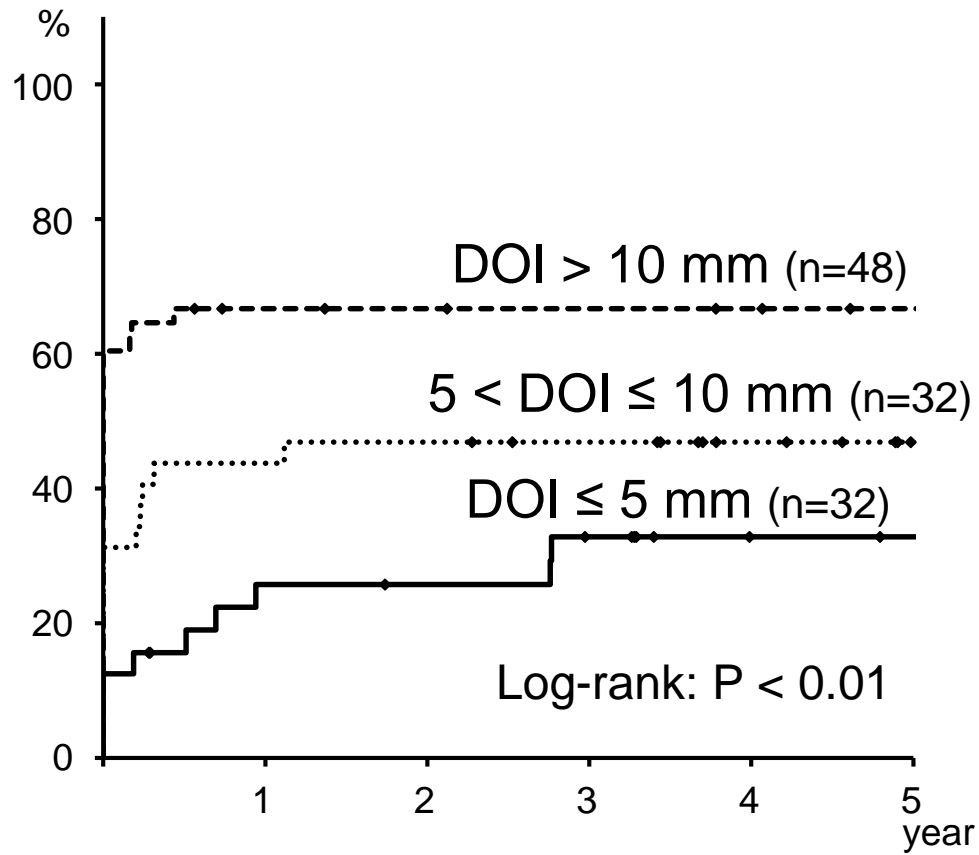


Figure 6

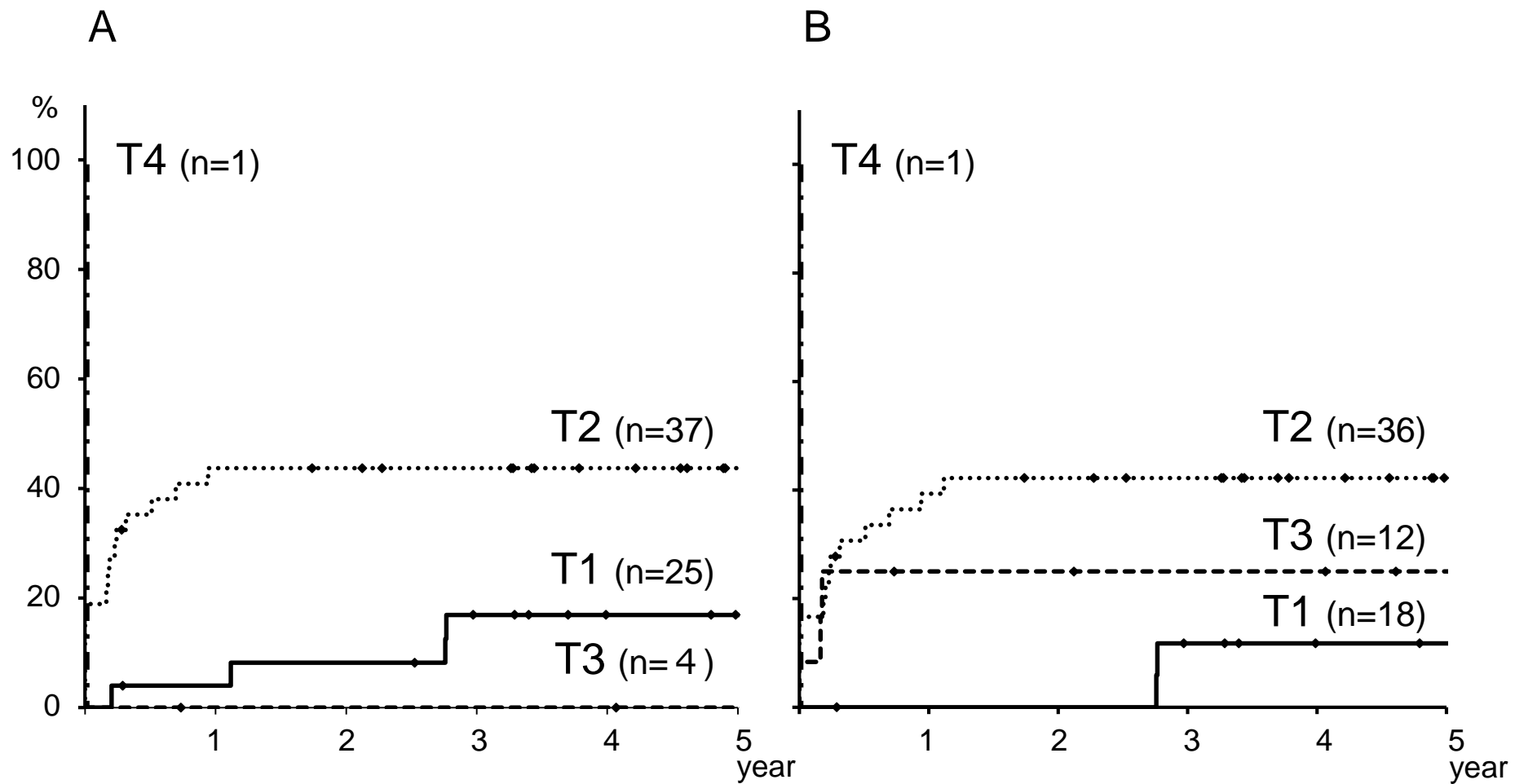
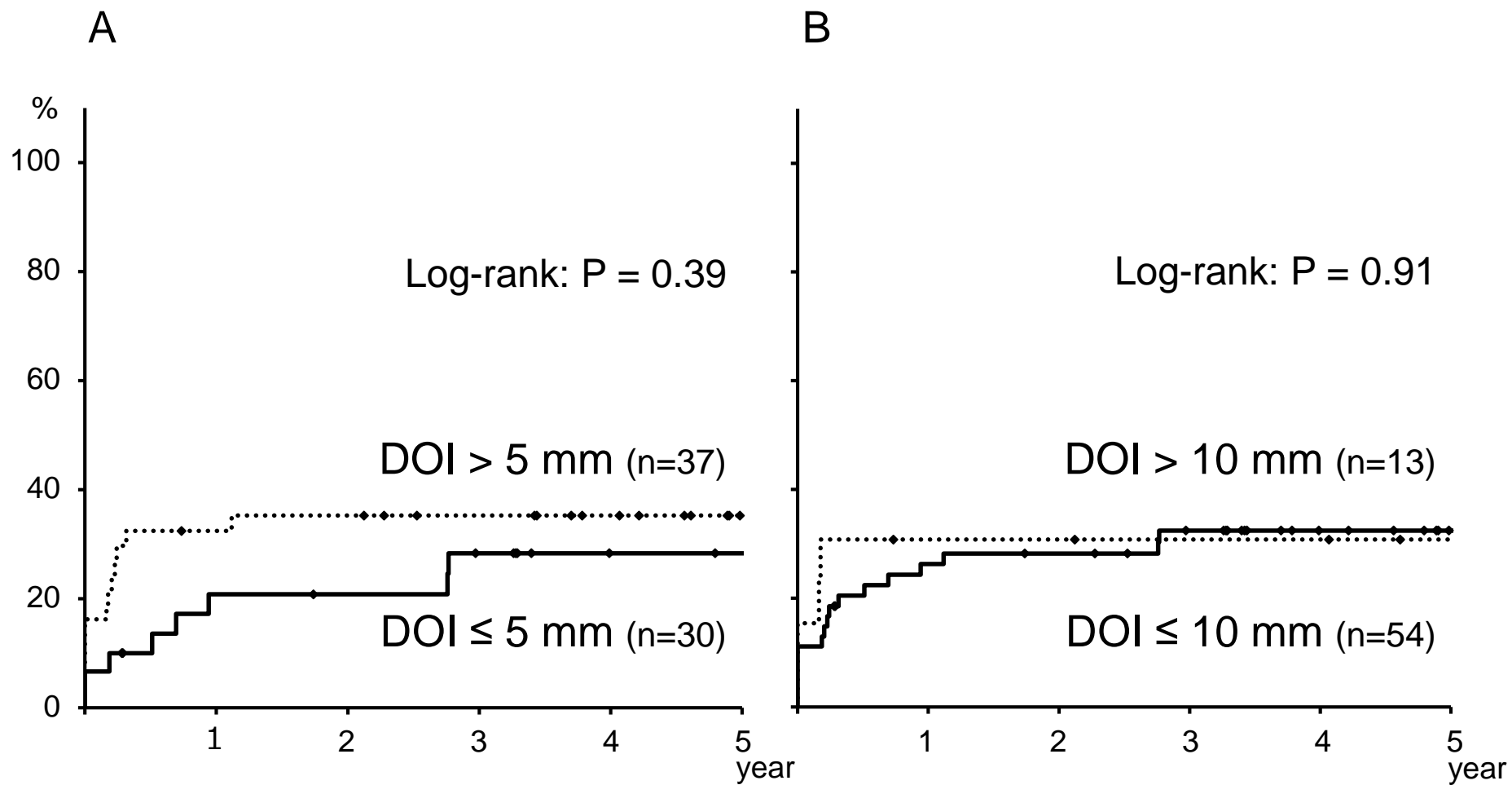


Figure 7





**Table 1. Definition of primary tumor of oral cavity in the 8<sup>th</sup> edition of the AJCC/UICC TNM staging system**

T classification	Criteria
T1	Tumor 2 cm or less in greatest dimension and 5 mm or less depth of invasion
T2	Tumor 2 cm or less in greatest dimension and more than 5 mm but no more than 10 mm depth of invasion or Tumor more than 2 cm but not more than 4cm in greatest dimension and depth of invasion no more than 10 mm
T3	Tumor more than 4 cm in greatest dimension or more than 10 mm depth of invasion
T4a	Tumor invades through cortical bone of the mandible or maxillary sinus, or invades the skin of the face
T4b	Tumor invades masticator space, pterygoid plates, or skull base, or encases internal carotid artery