




Open Archive Toulouse Archive Ouverte (OATAO)

OATAO is an open access repository that collects the work of some Toulouse researchers and makes it freely available over the web where possible.

This is an author's version published in: <https://oatao.univ-toulouse.fr/23113>

Official URL : <https://doi.org/10.1016/j.jse.2018.02.057>

To cite this version :

Krukenberg, Anna and McBirnie, Julie and Bartsch, Stefan and Böhler, Nikolaus and Wiedemann, Ernst and Jost, Bernhard and Mansat, Pierre  and Bellon-Champel, Pierre and Angeloni, Renzo and Scheibel, Markus *Sidus Stem-Free Shoulder System for primary osteoarthritis: short-term results of a multicenter study.* (2018) *Journal of Shoulder and Elbow Surgery*, 27 (8). 1483-1490. ISSN 1058-2746

Any correspondence concerning this service should be sent to the repository administrator:

tech-oatao@listes-diff.inp-toulouse.fr

Sidus Stem-Free Shoulder System for primary osteoarthritis: short-term results of a multicenter study

Anna Krukenberg^a, Julie McBirnie, MD^b, Stefan Bartsch, MD^c, Nikolaus Böhler, MD^d, Ernst Wiedemann, MD^e, Bernhard Jost, MD^f, Pierre Mansat, MD, PhD^g, Pierre Bellon-Champel, MD^h, Renzo Angeloni, MDⁱ, Markus Scheibel, MD^{a,*}

^aDepartment of Shoulder and Elbow Surgery, Charité–Universitätsmedizin Berlin, Berlin, Germany

^bDepartment of Orthopaedics, New Royal Infirmary of Edinburgh, Edinburgh, UK

^cPraxis am Wall Rinteln, Rinteln, Germany

^dAllgemeines Krankenhaus der Stadt Linz, Kepler Universitätsmedizin, Linz, Austria

^eOrthopedic Surgery Center Munich (OCM), München, Germany

^fDepartment of Orthopaedics and Traumatology, Kantonsspital St Gallen, St. Gallen, Switzerland

^gCentre Hospitalier Universitaire Toulouse–Hôpital Purpan, Toulouse, France

^hGroupe Chirurgical Thiers, Grenoble, France

ⁱUniversitaria Careggi–Centro Traumatologico Ortopedico, Florence, Italy

Background: The aim of this prospective multicenter study was to evaluate clinical and radiologic results of a new metaphyseal anchored system. This system features a different anchor geometry that potentially leads to better bony integration and less loosening.

Methods: From November 2012 until December 2015, 148 patients (151 shoulders) were treated with the Sidus Stem-Free Shoulder System at 9 centers in Europe. The main indication was primary osteoarthritis (80.1%). This analysis only includes patients diagnosed with primary osteoarthritis (n = 121). A clinical evaluation was performed using the Constant-Murley score, Subjective Shoulder Value, American Shoulder and Elbow Surgeons Standardized Shoulder Assessment Form, and range of motion. Radiologic assessment was based on the occurrence of radiolucent lines and signs of implant migration, osteolysis, loosening, and heterotopic ossification.

This study was approved by the ethics committee of each institution:

- Ethikkommission, Ethikausschuss 4, Charité–Universitätsmedizin Berlin, Berlin, Germany (No. EA4/021/13)
- Ethikkommission des Landes Oberösterreich, Linz, Austria (No. B-38-12)
- Ministère de L'Enseignement Supérieur et de la Recherche, Paris, France (No. 12.513)
- Freiburger Ethikkommission International, Freiburg, Germany (No. CME2012-01E)
- Kanton St Gallen Ethikkommission, St Gallen, Switzerland (No. 12/128/1B)
- South East Scotland Research Ethics Committee 02, Edinburgh, UK (No. 12/SS/0154)
- Segreteria Comitato Etico Sperimentazione Clinica, Firenze, Italy (No. CME2012-01E)

*Reprint requests: Markus Scheibel, MD, Department of Shoulder and Elbow Surgery, Charité–Universitätsmedizin Berlin, Augustenburger Platz 1, D-13353 Berlin, Germany.

E-mail address: markus.scheibel@charite.de (M. Scheibel).

Results: We evaluated 105 patients after a follow-up period of 2 years. There were 53 women and 52 men. The average age was 64 years. Total shoulder arthroplasty was performed in 73 cases and hemiarthroplasty in 32. The Constant-Murley score improved from 26 points preoperatively to 70 points at 2 years' follow-up ($P < .001$). The Subjective Shoulder Value increased from 34% to 84% ($P < .001$), and the American Shoulder and Elbow Surgeons Standardized Shoulder Assessment Form increased from 34 points to 86 points ($P < .001$). Radiologically, neither migration nor loosening was found. However, radiolucent lines of 2 mm or greater could be detected around the glenoid in 2 cases, but none of them have had clinical relevance yet. The overall complication rate was 6.7%, and the revision rate was 0%.

Conclusion: Patients with the Sidus Stem-Free Shoulder System achieve good clinical and radiologic short-term results that are comparable with the results of other stem-free shoulder implants.

Level of evidence: Level IV; Case Series; Treatment Study

Keywords: Total shoulder arthroplasty; hemiarthroplasty; osteoarthritis; glenohumeral joint replacement; Sidus; stem-free

For decades, the use of stemmed prostheses has been the state of the art when replacing the glenohumeral joint. Although the first total shoulder arthroplasty (TSA) was performed in 1893 by Jules Emile Péan in a patient with chronic tuberculosis in the proximal part of the humerus, it was Charles S. Neer who laid out the main concepts of shoulder arthroplasty in 1953.¹⁵ His so-called monoblock prosthesis was originally for the treatment of proximal humeral fractures.¹⁸

During the next 40 years, this first generation of prostheses underwent many changes, leading to a more anatomic reconstruction of the joint with excellent clinical results. Hence, this allowed not only the treatment of proximal humeral fractures but also the treatment of other conditions, such as osteoarthritis, post-traumatic arthritis, and rheumatoid arthritis.

However, stem-related complications are still reported and include intraoperative humeral fracture, postoperative periprosthetic humeral fracture, proximal humeral bone loss due to stress shielding, humeral stem loosening, osteolysis, and difficulty in explanting a well-fixed stem in the case of revision.^{1,5,7,17,19-21} To minimize stem-related problems, short-stem prostheses were developed, which led to the development of stemless shoulder arthroplasty, first introduced in 2004. Over the past 12 years, a total of 8 stemless prostheses were designed, one of them being the Sidus Stem-Free Shoulder System (Zimmer Biomet, Warsaw, IN, USA) in 2012. So far, no clinical or radiologic results have been published on this device.

The aim of this prospective, nonrandomized, multicenter cohort study was to evaluate the Sidus Stem-Free Shoulder System clinically and radiologically in patients with primary osteoarthritis.

Materials and methods

Between November 2012 and December 2015, the Sidus prosthesis was implanted in a total of 148 patients (151 shoulders) at 9 centers in Europe. All patients met the inclusion criteria (Table I) and signed the consent sheet. The exclusion criteria are defined in Table II. In this analysis, only patients who were treated because of primary osteoarthritis were included ($n = 121$). Before patients

Table I Inclusion criteria

The patient is aged 18-80 yr.
The patient is skeletally mature.
The patient has severe shoulder pain and disability requiring unilateral or bilateral HA or TSA based on physical examination findings and medical history.
Conservative treatment has failed.
The patient meets the following indication: osteoarthritis.
The patient is willing and able to cooperate with the required postoperative therapy.
The patient is willing and able to complete scheduled follow-up evaluations as described during the informed consent process.
The patient has participated in the informed consent process and signed the ethics committee-approved "informed consent" form.

HA, hemiarthroplasty; TSA, total shoulder arthroplasty.

were enrolled, a power analysis was performed; this showed 90% power for 115 patients.

Patients were evaluated preoperatively; intraoperatively; and at 3 months, 6 months, 1 year, and 2 years after the operation. The data were collected on case report forms and uploaded to an online platform (Oracle Remote Data Capture, Oracle PartnerNetwork; Oracle, Redwood Shores, CA, USA).

Clinically, the patients were evaluated with the Constant-Murley score (CS), American Shoulder and Elbow Surgeons Standardized Shoulder Assessment Form (ASES), and Subjective Shoulder Value (SSV) and by testing of active and passive range of motion preoperatively and postoperatively.^{8,11,16}

The preoperative radiologic assessment was performed using standardized radiographs in 3 planes (true anteroposterior [AP], axillary, and Y views). Computed tomography was performed to evaluate humeral or glenoid defects, bone quality, and glenoid morphology according to Walch et al²³ and to estimate the fatty infiltration of the rotator cuff; a magnetic resonance tomography scan was obtained only in cases with an unclear status of the rotator cuff.

The postoperative radiologic evaluation was performed with radiographs in 2 planes (true AP and axillary views) measuring osteolysis; radiolucent lines (RLs) in millimeters; and according to Franklin et al,⁹ migration or heterotopic ossification. Therefore, the

Table II Exclusion criteria

The patient is unwilling or unable to give consent or to comply with the follow-up program.
The patient has any condition that would, in the judgment of the investigator, place the patient at undue risk or interfere with the study. Any patient who is institutionalized, is known to abuse drugs, is known to have alcoholism, or cannot understand what is required of him or her is excluded.
The patient is known to be pregnant or breastfeeding.
The patient meets 1 of the following contraindications: <ul style="list-style-type: none">Soft or inadequate humeral bone (including osteoporosis and extensive avascular necrosis or rheumatoid arthritis) leading to poor implant fixationMetaphyseal bony defect (including large cysts)Post-traumatic tuberosity nonunionSigns of infectionIrreparable cuff tearRevision from failed stemmed prosthesisCharcot shoulder (neuroarthropathy)

implant-bone interface of the humeral component was divided into 5 different zones in AP and axillary views (Fig. 1). The glenoid component was divided into 3 zones in AP view according to Lazarus et al.¹⁴

Implant description

The Sidus Stem-Free Shoulder System is a 2-component system consisting of a metaphyseal implanted anchor and the humeral head. The cross-shaped anchor creates a “press fit” when it is forced into the slightly undersized bed prepared in the metaphyseal bone, ensuring the primary stability of the implant. The anchor is made from a rough-blasted, forged titanium alloy (Protasul, 64WF; Zimmer Biomet) and has 4 fins to ensure good bony integration and to secure against rotation (Fig. 2). It is available in 3 diameters (small, medium, and large) and is not convertible to a reverse prosthesis. The humeral head is concentric and consists of a cobalt-chrome alloy (Protasul, 21WF; Zimmer Biomet). It is available in different diameters (38–52 mm) and heights (Fig. 3). The head and anchor are connected by a Morse taper connection. The Sidus system can be combined with 2 different and already known glenoid systems: Anatomical Shoulder Glenoid (cemented keel and pegged; Zimmer Biomet) and Bigliani/Flatow System (cemented keel or pegged; Zimmer Biomet).

Surgical technique

All surgical procedures were performed with patients under general anesthesia combined with an additional interscalene block or catheter for adequate intraoperative and postoperative pain relief. A deltopectoral approach was used in all patients. The subscapularis was released by a tenotomy or lesser tuberosity osteotomy according to Gerber et al¹⁰ per surgeon preference. The long head of the biceps underwent either tenotomy or tenodesis. After dislocation of the humeral head, a guide was positioned at the medial border of the insertion of the supraspinatus tendon and marked with a K-wire. The K-wire should exit at the posterior edge of the cartilage medial to the bare area. Afterward, the guide was removed, and a resec-

tion guide was placed with another 2 K-wires along the anatomic neck (Fig. 4, a). By use of this resection guide, the inclination angle and retroversion can be determined even in severe cases of osteoarthritis. Then, the humeral head was resected along the anatomic neck (Fig. 4, b). In the case of TSA, a metallic bone protector was placed on the resection plane while the glenoid was prepared. First, the capsule was released all around the glenoid. Then, the glenoid was prepared in a standard manner. After the glenoid was replaced, the correct size of the humeral head was determined by using a trial head (Fig. 5, a). Via this model, a central wire was placed in the humerus and the metaphysis was prepared using a drill and an impaction instrument (Figs. 5, b, and 6, b). Then, the anchor was positioned in the metaphysis, and the humeral head was placed on top of the anchor (Fig. 7). Finally, subscapularis repair and wound closure were performed.

Postoperative rehabilitation

All patients were immobilized in a sling in internal rotation for 4 to 6 weeks. Simultaneously, physiotherapy was performed, but active motion and passive external rotation were not allowed for the first 6 weeks; only passive abduction, flexion, and internal rotation exercises were permitted during this time. After 6 weeks, gradual progression of active motion was allowed. After full range of motion was achieved, strength exercises were allowed.

Statistical analysis

Statistical analysis was performed using the Wilcoxon rank sum test with a significance level of less than .05 and a confidence level of 0.95.

Results

Demographic data

In total, 151 Sidus systems were implanted in 148 patients. The main indication for joint replacement was primary osteoarthritis (n = 121, 80.1%), other indications were post-traumatic arthritis (7.3%), focal avascular necrosis (3.3%), rheumatoid arthritis (2.6%), and instability arthropathy (1.3%).

Of the 121 patients who underwent surgery for primary osteoarthritis, 105 (86.8%) were available for a 2-year follow-up evaluation, whereas 4 did not want to continue with this study and 12 were lost to follow-up. In the cohort of 105 patients, there were 53 women (50.5%) and 52 men (49.5%), and the average age was 64 years (range, 40–79 years). TSA was performed in 73 cases, whereas hemiarthroplasty (HA) was performed in 32. Table III shows the distribution of glenoid morphology according to Walch et al.²³

Clinical results

The average CS increased from 26 points (SD, 13 points) preoperatively to 70 points (SD, 18.9 points) at 2 years' follow-up ($P < .001$); the average ASES score, from 34 points (SD, 17.9 points) to 86 points (SD, 21.4 points) ($P < .001$); and the SSV, from 34% (SD, 17.2%) to 84% (SD, 17.5%)

Radiographic Zones Evaluation guide

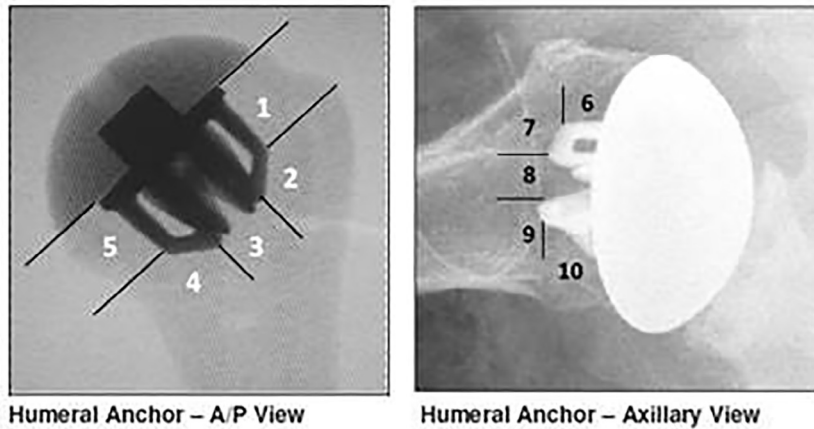


Figure 1 Radiologic classification in true anteroposterior (A/P) and axillary views (humeral classification by Zimmer Biomet).




Figure 2 Sidus anchor. *D*, diameter; *H*, height.

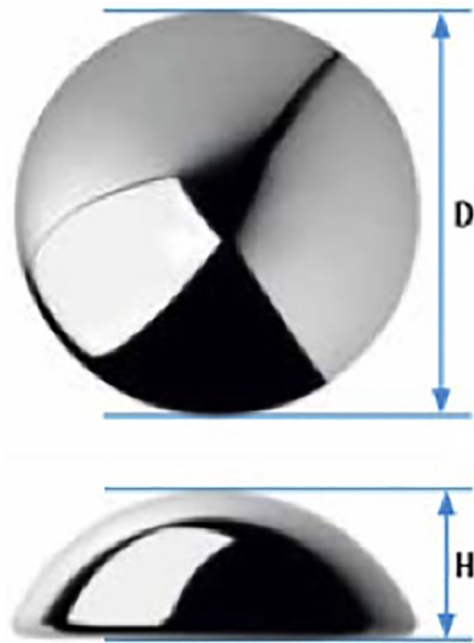


Figure 3 Sidus humeral head. *D*, diameter; *H*, height.

($P < .001$). Active forward elevation improved from 86° (SD, 29°) preoperatively to 144° (SD, 30.7°) at final follow-up, and active external rotation with the arm at the side improved from 13° (SD, 17.9°) to 41° (SD, 23.3°) ($P < .001$).

In this 2-year cohort, patients with TSA reached significantly higher scores than patients with HA (Table IV). In patients with TSA, the CS improved from 25 points preoperatively to 70 points at 1-year follow-up and reached 75 points at final follow-up ($P < .001$). In patients with HA, the CS

improved from 27 points preoperatively to 59 points at 1-year and final follow-up ($P < .001$). The ASES score increased from 32 points preoperatively to 91 points at final follow-up in patients with TSA and from 34 points to 86 points in patients with HA ($P < .001$). The SSV improved from 32% preoperatively to 87% in patients with TSA and from 38% to 75% in patients with HA ($P < .001$). Active range of motion differed between TSA and HA: Flexion increased from 85° preoperatively to 150° postoperatively ($P < .001$) and external rotation with the arm at the side increased from 12° to 45° ($P < .001$) in patients with TSA, whereas in patients with HA, flexion improved from 89° to 129° ($P < .001$) and external rotation from 15° to 34° ($P < .006$). Finally, 90.4% of

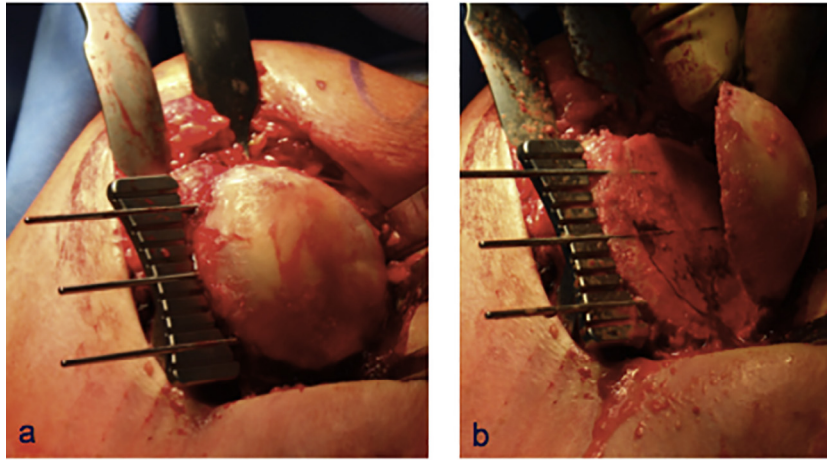


Figure 4 Implantation of Sidus Stem-Free Shoulder System: resection of humeral head.

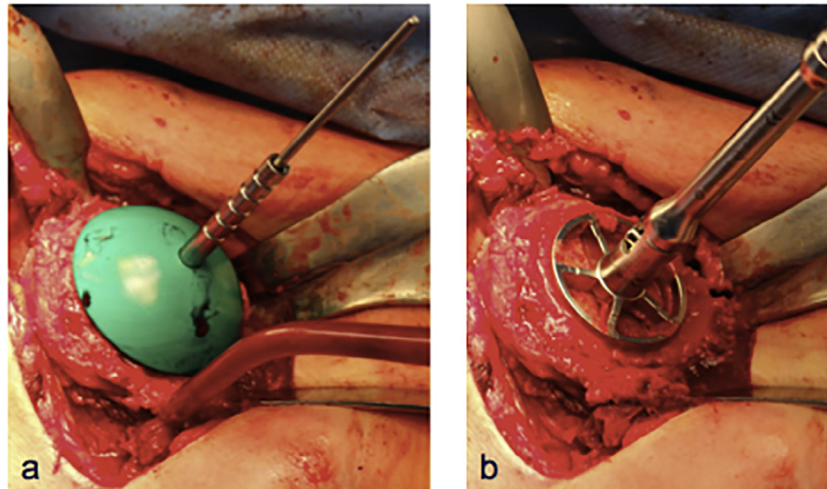


Figure 5 Implantation of Sidus Stem-Free Shoulder System: head sampling (a) and preparation for anchor (b).

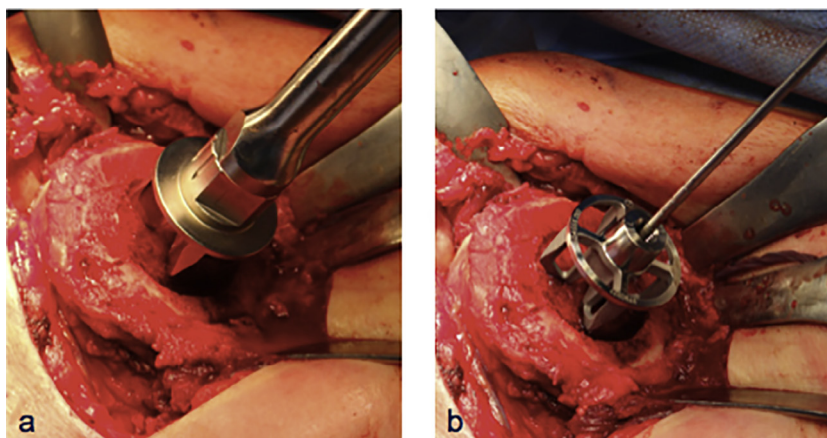


Figure 6 Implantation of Sidus Stem-Free Shoulder System: preparation for anchor (a) and impaction of anchor (b).

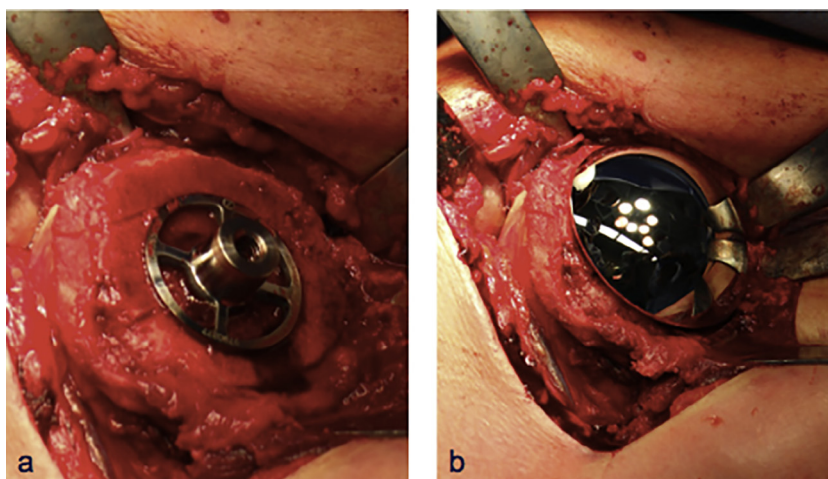


Figure 7 Implantation of Sidus Stem-Free Shoulder System: impacted anchor (a) and humeral head (b).

Table III Glenoid morphology according to Walch et al²³

	TSA (n = 73)	HA (n = 32)
Type A1	18 (24.7%)	13 (40.6%)
Type A2	19 (26%)	7 (21.9%)
Type B1	8 (11%)	1 (3.1%)
Type B2	26 (35.6%)	6 (18.8%)
Type C	2 (2.7%)	5 (15.6%)

TSA, total shoulder arthroplasty; HA, hemiarthroplasty.

Table IV Comparison of TSA versus HA at 2 years' follow-up

	TSA	HA	P value
ASES score, points	90.6	74.6	<.001
CS, points	74.7	59	<.001
SSV, %	87.1	75.2	.0018

TSA, total shoulder arthroplasty; HA, hemiarthroplasty; ASES, American Shoulder and Elbow Surgeons Standardized Shoulder Assessment Form; CS, Constant-Murley score; SSV, Subjective Shoulder Value.

the patients with TSA and 53.1% of the patients with HA were very satisfied with the postoperative result.

Radiographic results

No cases of osteolysis, anchor migration, or implant loosening have been reported so far in this cohort. Around the humeral component, incomplete RLs of 1 mm each could be documented in 1 patient, in zones 2 and 6. Around the glenoid component, there were incomplete RLs of 1 mm each in 10 patients and complete RLs of 1 mm each in 6 patients. In 2 patients there were incomplete RLs of 2 mm each in zone 2. None of them have had clinical relevance yet.

Lower bone density or atrophy around the humeral component could be noted in 4 patients, occurring in zone 1 (n = 3), zone 4 (n = 1), zone 5 (n = 1), zone 6 (n = 1), zone 7 (n = 1), zone 8 (n = 1), zone 9 (n = 2), and zone 10 (n = 4). There was

no atrophy around the glenoid component. One patient had heterotopic ossification and inferior osteophytes (3-7 mm).

Adverse events

Within the study cohort of patients being treated for primary osteoarthritis, the complication rate was 6.7% and the revision rate was 0%. One intraoperative fracture occurred at the greater tuberosity during anchor placement. Because there was no dislocation of the tuberosity and the anchor was well fixed, no further treatment was initiated. Postoperatively, temporary axillary nerve palsy was found in 1 patient, and temporary irritation of the plexus brachialis was found in 2 other patients. In 1 patient, insufficiency of the pectoralis major developed, without further treatment. One patient had deep vein thrombosis postoperatively.

Discussion

The short-term results of this study showed that patients treated with the Sidus Stem-Free Shoulder System for primary osteoarthritis achieved good clinical results after 2 years. Incomplete RLs of 1 mm each were noted in 0.95% of patients on the humeral side and in 9.5% on the glenoid side. Incomplete RLs of 2 mm each were just found around the glenoid component in 1.9%. There were complete RLs of 1 mm each around the glenoid component in 5.7%. Atrophy or lower bone density was noted in 3.8%. Nevertheless, there were no signs of migration or loosening of the humeral or glenoid component. The complication rate was 6.7%, and no revisions have been performed.

To date, few articles have been published on stemless shoulder arthroplasty. Studies of only 4 stemless prostheses have reported results at a minimum of 2 years' follow-up.

The TESS prosthesis (Zimmer Biomet) was the first canal-sparing prosthesis and was introduced in 2004. The TESS group first published 3-year follow-up results of this prosthesis

in 2010.¹³ Between March 2004 and June 2005, 70 patients (72 shoulders) were treated with the TESS prosthesis for primary or post-traumatic arthritis or osteonecrosis. In 61 patients (63 shoulders), a 3-year follow-up evaluation was performed. The mean CS improved from 30 points preoperatively to 75 points at 3 years postoperatively; active flexion, from 96° to 145°; and active external rotation, from 20° to 40°. Ninety percent of the patients were satisfied or very satisfied. Huguet et al¹³ could not find any signs of radiolucency, osteolysis, or stress shielding around the implant. In 5 patients a small crack in the lateral cortex was noted, which healed within 2 months. Two patients needed revision because of a large hematoma and stiffness. The total revision rate was 11%. Berth and Pap³ were able to confirm the results of the TESS group in 2013. They compared the TESS prosthesis with a stemmed prosthesis (Affinis; Mathys, Bettlach, Switzerland) in patients who were treated for primary osteoarthritis. In total, 82 patients were included, 41 in each group, with a minimum follow-up period of 2 years. The mean CS in patients with the TESS prosthesis improved from 30 points preoperatively to 55 points postoperatively; anteversion, from 81° to 116°; and external rotation, from 39° to 54°. Neither RLs around the humeral implant nor osteolysis was found, but there were RLs around the glenoid in 9 patients without any loosening or migration. There was 1 fissure of the glenoid, which healed without any additional therapy, and 1 temporary plexus neuropathy. The total revision rate was 0%. The results for the stemmed prosthesis group did not differ significantly.

The Eclipse Stemless Prosthesis (Arthrex, Naples, Florida, USA) was introduced in 2005. Habermeyer et al¹² were the first authors to publish the midterm results of a stemless prosthesis. Between May 2005 and September 2008, 96 patients were treated with the Eclipse prosthesis, and 78 patients were available for a 5-year follow-up evaluation. The main indications were primary osteoarthritis and post-traumatic arthritis. The mean CS improved from 46 points preoperatively to 65 points postoperatively; flexion, from 114° to 141°; and external rotation, from 25° to 44°. In 1 patient an incomplete RL around the humeral component was seen, and in 3 patients partial osteolysis without loosening was observed. Partial RLs were seen in 8.3% of TSA patients around the metal-backed glenoid and in 53.3% of patients with a cemented all-polyethylene glenoid. In 8.3%, loosening of the cementless glenoid component was observed. The overall revision rate was 9%. Similar results were described by Brunner et al⁴ and Uschok et al.²²

The Affinis Short Stemless Shoulder (Mathys) was introduced in 2009. An Australian study group published early results in 2014.² A total of 97 patients were treated with this implant. In this study, only 12 patients had undergone their 2-year follow-up visits at the time of publication. The mean CS improved from 25 points preoperatively to 86 points postoperatively; the ASES score, from 46 points to 96 points; and flexion of the arm, from 93° to 160°. Neither loosening nor implant migration was found. One patient needed revision surgery for rotator cuff failure.

The Simpliciti Canal-Sparing Shoulder Arthroplasty System (Wright Medical, Memphis, Tennessee, USA) was introduced in 2010. Churchill et al⁶ published 2-year follow-up results. In their study, 157 patients were treated with the Simpliciti system at 14 study sites between July 2011 and November 2012. Of these patients, 149 were available for the 2-year follow-up evaluation. In 96% primary osteoarthritis was the reason for shoulder arthroplasty, while post-traumatic osteoarthritis was observed in 4%. The mean CS increased from 44 points preoperatively to 81 points at 2 years postoperatively, reaching the highest scores compared with the other stemless systems. The mean ASES score improved from 38 points to 92 points; active flexion, from 103° to 147°; and external rotation, from 31° to 56°. No RLs, migration, subsidence, osteolysis, or loosening of the humeral component was found at 2 years' follow-up. Five patients needed revision, including conversion to a stemmed prosthesis because of poor bone quality (n = 1), change of the nucleus to a larger one (n = 1), conversion to reverse shoulder arthroplasty (n = 1), change of the humeral head because of infection (n = 1), and change of the glenoid because of loosening (n = 1). The overall revision rate was 2%.

The results of the Sidus Stem-Free Shoulder System in terms of clinical outcome and revision rate are comparable with those of other stemless prostheses. Nevertheless, there were more RLs than in other studies. However, it should be noted that those were mainly RLs of 1 mm each. In fact, there were just 2 cases with RLs of 2 mm. For now, there have been no signs of migration or loosening. However, further follow-up evaluation is required. In addition, lower bone density was seen in 3.8% of patients. The significance of this in terms of earlier loosening is not known yet and requires further follow-up evaluation.

This study has some limitations. The reported results are only short-term results, and further follow-up evaluation is needed. Furthermore, the evaluation was performed at 9 different centers and by at least 9 different investigators, creating possible bias in evaluation. Furthermore, there was not an independent reviewer who checked the results of the radiographic evaluation. Hence, there was no validation process to confirm that the data were correct other than each surgeon's expertise. In the end, there are still questions unacknowledged in terms of further radiographic evaluation, such as re-creation of the glenohumeral anatomy. This should be part of further follow-up evaluation.

Conclusion

At 2 years postoperatively, the Sidus Stem-Free Shoulder System shows clinical scores comparable with other marketed stemless systems. There have been no instances of loosening or other major device-related complications. However, midterm and long-term results including a larger sample size are needed to confirm these short-term results.

Disclaimer

This study was financially supported by Zimmer Biomet (Warsaw, IN). Each author or institution received a payment for radiologic and clinical assessments per patient according to fair market value.

References

1. Athwal GS, Sperling JW, Rispoli DM, Cofield RH. Periprosthetic humeral fractures during shoulder arthroplasty. *J Bone Joint Surg Am* 2009;91:594. <http://dx.doi.org/10.2106/JBJS.H.00439>
2. Bell SN, Coghlan J. Short stem shoulder replacement. *Int J Shoulder Surg* 2014;8:72-5. <http://dx.doi.org/10.4103/0973-6042.140113>
3. Berth A, Pap G. Stemless shoulder prosthesis versus conventional anatomic shoulder prosthesis in patients with osteoarthritis: a comparison of the functional outcome after a minimum of two years follow-up. *J Orthop Traumatol* 2013;14:31-7. <http://dx.doi.org/10.1007/s10195-012-0216-9>
4. Brunner UH, Fruth M, Rückl K, Magosch P, Tauber M, Resch H, et al. Die schaftfreie Eclipse-Prothese—Indikation und mittelfristige Ergebnisse: eine prospektive Multicenterstudie. *Obere Extrem* 2012;7:22-8 [in German]. <http://dx.doi.org/10.1007/s11678-011-0152-y>
5. Campbell JT, Richard SM, Williams GR, Joseph P, Norris TR, Francisco CS. Periprosthetic humeral fractures: mechanisms of fracture and treatment options. *J Shoulder Elbow Surg* 1998;7:406-13.
6. Churchill RS, Chuinard C, Wiater JM, Friedman R, Freehill M, Jacobsen S, et al. Clinical and radiographic outcomes of the Simpliciti canal-sparing shoulder arthroplasty system: a prospective two-year multicenter study. *J Bone Joint Surg Am* 2016;98:552-60. <http://dx.doi.org/10.2106/JBJS.15.00181>
7. Cil A, Veillette CJH, Sanchez-Sotelo J, Sperling JW, Schleck CD, Cofield RH. Survivorship of the humeral component in shoulder arthroplasty. *J Shoulder Elbow Surg* 2010;19:143-50. <http://dx.doi.org/10.1016/j.jse.2009.04.011>
8. Constant CR, Murley AH. A clinical method of functional assessment of the shoulder. *Clin Orthop Relat Res* 1987;(214):160-4.
9. Franklin JL, Barrett WP, Jackins SE, Matsen FA. Glenoid loosening in total shoulder arthroplasty. *J Arthroplasty* 1988;3:39-46.
10. Gerber C, Pennington SD, Yian EH, Pfirrmann CA, Werner CM, Zumstein MA. Lesser tuberosity osteotomy for total shoulder arthroplasty. Surgical technique. *J Bone Joint Surg Am* 2006;88(Suppl 1):170-7. <http://dx.doi.org/10.2106/JBJS.F.00407>
11. Gilbert MK, Gerber C. Comparison of the subjective shoulder value and the Constant score. *J Shoulder Elbow Surg* 2007;16:717-21. <http://dx.doi.org/10.1016/j.jse.2007.02.123>
12. Habermeyer P, Lichtenberg S, Tauber M, Magosch P. Midterm results of stemless shoulder arthroplasty: a prospective study. *J Shoulder Elbow Surg* 2015;24:1463-72. <http://dx.doi.org/10.1016/j.jse.2015.02.023>
13. Huguet D, DeClercq G, Rio B, Teissier J, Zipoli B. Results of a new stemless shoulder prosthesis: radiologic proof of maintained fixation and stability after a minimum of three years' follow-up. *J Shoulder Elbow Surg* 2010;19:847-52. <http://dx.doi.org/10.1016/j.jse.2009.12.009>
14. Lazarus MD, Jensen KL, Southworth C, Matsen FA III. The radiographic evaluation of keeled and pegged glenoid component insertion. *J Bone Joint Surg Am* 2002;84:1174-82.
15. Lugli T. Artificial shoulder joint by Péan (1893): the facts of an exceptional intervention and the prosthetic method. *Clin Orthop Relat Res* 1978;(133):215-8.
16. Michener LA, McClure PW, Sennett BJ. American Shoulder and Elbow Surgeons Standardized Shoulder Assessment Form, patient self-report section: reliability, validity, and responsiveness. *J Shoulder Elbow Surg* 2002;11:587-94. <http://dx.doi.org/10.1067/mse.2002.127096>
17. Nagels J, Stokdijk M, Rozing PM. Stress shielding and bone resorption in shoulder arthroplasty. *J Shoulder Elbow Surg* 2003;12:35-9. <http://dx.doi.org/10.1067/mse.2003.22>
18. Neer CS, Brown TH, McLaughlin HL. Fracture of the neck of the humerus with dislocation of the head fragment. *Am J Surg* 1953;85:252-8.
19. Phipatanakul WP, Bowen JM, Jobe CM. Removal of well-fixed flanged humeral prostheses may require humeral expansion. *J Shoulder Elbow Surg* 2009;18:724-7. <http://dx.doi.org/10.1016/j.jse.2008.11.021>
20. Raiss P, Edwards TB, Deutsch A, Shah A, Bruckner T, Loew M, et al. Radiographic changes around humeral components in shoulder arthroplasty. *J Bone Joint Surg Am* 2014;96:e54. <http://dx.doi.org/10.2106/JBJS.M.00378>
21. Seybold D, Geßmann J, Königshausen M, Schildhauer TA. Glenoidale und humerale revision nach schulterendoprothese. *Obere Extrem* 2016;11:210-7 [in German]. <http://dx.doi.org/10.1007/s11678-016-0381-1>
22. Uschok S, Magosch P, Moe M, Lichtenberg S, Habermeyer P. Is the stemless humeral head replacement clinically and radiographically a secure equivalent to standard stem humeral head replacement in the long-term follow-up? A prospective randomized trial. *J Shoulder Elbow Surg* 2017;26:225-32. <http://dx.doi.org/10.1016/j.jse.2016.09.001>
23. Walch G, Badet R, Boulahia A, Khoury A. Morphologic study of the glenoid in primary glenohumeral osteoarthritis. *J Arthroplasty* 1999;14:756-60.