



THE UNIVERSITY *of* EDINBURGH

Edinburgh Research Explorer

Complete spermatogenesis in intratesticular testis tissue xenotransplants from immature non-human primate

Citation for published version:

Ntemou, E, Kadam, P, Van Saen, D, Wistuba, J, Mitchell, RT, Schlatt, S & Goossens, E 2019, 'Complete spermatogenesis in intratesticular testis tissue xenotransplants from immature non-human primate', *Human Reproduction*, vol. 34, no. 3, pp. 403-413. <https://doi.org/10.1093/humrep/dey373>

Digital Object Identifier (DOI):

[10.1093/humrep/dey373](https://doi.org/10.1093/humrep/dey373)

Link:

[Link to publication record in Edinburgh Research Explorer](#)

Document Version:

Publisher's PDF, also known as Version of record

Published In:

Human Reproduction

General rights

Copyright for the publications made accessible via the Edinburgh Research Explorer is retained by the author(s) and / or other copyright owners and it is a condition of accessing these publications that users recognise and abide by the legal requirements associated with these rights.

Take down policy

The University of Edinburgh has made every reasonable effort to ensure that Edinburgh Research Explorer content complies with UK legislation. If you believe that the public display of this file breaches copyright please contact openaccess@ed.ac.uk providing details, and we will remove access to the work immediately and investigate your claim.



Complete spermatogenesis in intratesticular testis tissue xenotransplants from immature non-human primate

E. Ntemou^{1,*}, P. Kadam¹, D. Van Saen¹, J. Wistuba², R.T. Mitchell^{3,4}, S. Schlatt², and E. Goossens¹

¹Biology of the Testis Lab, Department of Reproduction, Genetics and Regenerative Medicine, Vrije Universiteit Brussel (VUB), Brussels 1090, Belgium ²Centre of Reproductive Medicine and Andrology (CeRA), University of Münster, Münster 48149, Germany ³MRC Centre for Reproductive Health, The University of Edinburgh, The Queen's Medical Research Institute, Edinburgh EH16 4TJ, Scotland, UK ⁴Edinburgh Royal Hospital for Sick Children, Edinburgh EH9 1LF, Scotland, UK

*Correspondence address. Biology of the Testis Lab, Department of Reproduction, Genetics and Regenerative Medicine, Vrije Universiteit Brussel (VUB), Laarbeeklaan 103, 1090 Brussels, Belgium. Tel: +32-02-477-4644; E-mail: elissavet.ntemou@vub.be

Submitted on July 24, 2018; resubmitted on November 20, 2018; accepted on November 30, 2018

STUDY QUESTION: Can full spermatogenesis be achieved after xenotransplantation of prepubertal primate testis tissue to the mouse, in testis or subcutaneously?

SUMMARY ANSWER: Intratesticular xenotransplantation supported the differentiation of immature germ cells from marmoset (*Callithrix jacchus*) into spermatids and spermatozoa at 4 and 9 months post-transplantation, while in subcutaneous transplants, spermatogenic arrest was observed at 4 months and none of the transplants survived at 9 months.

WHAT IS KNOWN ALREADY: Auto-transplantation of cryopreserved immature testis tissue (ITT) could be a potential fertility restoration strategy for patients with complete loss of germ cells due to chemo- and/or radiotherapy at a young age. Before ITT transplantation can be used for clinical application, it is a prerequisite to demonstrate the feasibility of the technique and identify the conditions required for establishing spermatogenesis in primate ITT transplants. Although xenotransplantation of ITT from several species has resulted in complete spermatogenesis, in human and marmoset, ITT has not been successful.

STUDY DESIGN, SIZE, DURATION: In this study, we used marmoset as a pre-clinical animal model. ITT was obtained from two 6-month-old co-twin marmosets. A total of 147 testis tissue pieces (~0.8–1.0 mm³ each) were transplanted into the testicular parenchyma (intratesticular; $n = 40$) or under the dorsal skin (ectopic; $n = 107$) of 4-week-old immunodeficient Swiss Nu/Nu mice ($n = 20$). Each mouse received one single marmoset testis tissue piece in each testis and 4–6 pieces subcutaneously. Xenotransplants were retrieved at 4 and 9 months post-transplantation and evaluations were performed with regards to transplant survival, spermatogonial quantity and germ cell differentiation.

PARTICIPANTS/MATERIALS, SETTING, METHODS: Transplant survival was histologically evaluated by haematoxylin-periodic acid Schiff (H/PAS) staining. Spermatogonia were identified by MAGE-A4 via immunohistochemistry. Germ cell differentiation was assessed by morphological identification of different germ cell types on H/PAS stained sections. Meiotically active germ cells were identified by BOLL expression. CREM immunohistochemistry was performed to confirm the presence of post-meiotic germ cells and ACROSIN was used to determine the presence of round, elongating and elongated spermatids.

MAIN RESULTS AND THE ROLE OF CHANCE: Four months post-transplantation, 50% of the intratesticular transplants and 21% of the ectopic transplants were recovered ($P = 0.019$). The number of spermatogonia per tubule did not show any variation. In 33% of the recovered intratesticular transplants, complete spermatogenesis was established. Overall, 78% of the intratesticular transplants showed post-meiotic differentiation (round spermatids, elongating/elongated spermatids and spermatozoa). However, during the same period, spermatozoa (early meiotic germ cells) were the most advanced germ cell type present in the ectopic transplants. Nine months post-transplantation,

50% of the intratesticular transplants survived, whilst none of the ectopic transplants was recovered ($P < 0.0001$). Transplants contained more spermatogonia per tubule ($P = 0.018$) than at 4 months. Complete spermatogenesis was observed in all recovered transplants (100%), indicating a progressive spermatogenic development in intratesticular transplants between the two time-points. Nine months post-transplantation, transplants contained more seminiferous tubules with post-meiotic germ cells (37 vs. 5%; $P < 0.001$) and fewer tubules without germ cells (2 vs. 8%; $P = 0.014$) compared to 4 months post-transplantation.

LARGE SCALE DATA: N/A.

LIMITATIONS, REASONS FOR CAUTION: Although xenotransplantation of marmoset ITT was successful, it does not fully reflect all aspects of a future clinical setting. Furthermore, due to ethical restrictions, we were not able to prove the functionality of the spermatozoa produced in the marmoset transplants.

WIDER IMPLICATIONS OF THE FINDINGS: In this pre-clinical study, we demonstrated that testicular parenchyma provides the required microenvironment for germ cell differentiation and long-term survival of immature marmoset testis tissue, likely due to the favourable temperature regulation, growth factors and hormonal support. These results encourage the design of new experiments on human ITT xenotransplantation and show that intratesticular transplantation is likely to be superior to ectopic transplantation for fertility restoration following gonadotoxic treatment in childhood.

STUDY FUNDING/COMPETING INTEREST(S): This project was funded by the ITN Marie Curie Programme 'Growsperm' (EU-FP7-PEOPLE-2013-ITN 603568) and the scientific Fund Willy Gepts from the UZ Brussel (ADSI677). D.V.S. is a post-doctoral fellow of the Fonds Wetenschappelijk Onderzoek (FWO; 12M2815N). No conflict of interest is declared.

Key words: spermatogenesis / immature testis tissue / intratesticular transplantation / primates / fertility preservation

Introduction

Young boys receiving chemo- or radiotherapy to eradicate cancer or as preconditioning treatment for hematopoietic stem cell transplantation face the possibility of being infertile when they reach adulthood due to the gonadotoxicity of the regimens used (Jahnukainen et al., 2011). It is estimated that almost half of adult male survivors of paediatric cancer will face fertility problems (Green et al., 2010; Wasilewski-Masker et al., 2014). Sperm banking cannot be offered to prepubertal patients to safeguard their fertility as mature spermatozoa are not present. The only potential fertility preservation strategy currently offered to these patients involves the cryopreservation of immature testis tissue (ITT) containing spermatogonial stem cells (SSCs) (Picton et al., 2015). To date, the methods proposed for fertility restoration using cryopreserved ITT remain experimental and primarily involve testis tissue transplantation (TTT), SSC transplantation or *in vitro* culture of single cells or tissue fragments (Giudice et al., 2017). Among these approaches, TTT has the advantage that it retains SSCs within their niche and ensures germ cell and supporting cell interactions, providing an optimal microenvironment for cell proliferation, maturation and differentiation (Goossens et al., 2013). However, since TTT carries a potential risk of reintroducing cancerous cells back to the patient and causing malignant relapse (Jahnukainen et al., 2001), it should only be considered for patients diagnosed with non-systemic cancer and/or non-malignant hematopoietic disorders (Picton et al., 2015). For patients for whom the ITT could potentially be contaminated by neoplastic cells, the organotypic culture aiming at *in vitro* maturation might be a good alternative (de Michele et al., 2017).

Complete spermatogenesis following auto-transplantation of ITT was first demonstrated in mice (Honaramooz et al., 2002; Schlatt et al., 2002; Shinohara et al., 2002) and numerous reports on successful xenotransplantation of ITT from other species followed (hamster:

Schlatt et al., 2002; rabbit: Shinohara et al., 2002; bovine: Oatley et al., 2004; rhesus monkey: Honaramooz et al., 2004; horse: Rathi et al., 2006; cat: Kim et al., 2007; dog: Abrishami et al., 2010; buffalo: Reddy et al., 2012). Preservation of the reproductive potential of sperm generated in xenotransplants has been confirmed either by oocyte activation (ectopic; pig and goat: Honaramooz et al., 2002), embryo generation by ICSI (ectopic; rhesus monkey: Honaramooz et al., 2004) or the birth of live offspring (intratesticular; rabbit: Shinohara et al., 2002).

Prior to a pilot clinical trial and clinical implementation of ITT transplantation, the feasibility of the technique and the optimal conditions for establishing spermatogenesis using ITT transplants, including the transplantation site, need to be investigated in a human-relevant pre-clinical model. Recently, a study from Liu et al. (2016) reported for the first time the generation of non-human primate (*Macaca fascicularis*) offspring using sperm derived from juvenile monkey testis xenotransplants (ectopic). However, in human, xenotransplantation of ITT containing spermatogonia as the most advanced germ cell type did not result in complete spermatogenesis and production of spermatozoa. The presence of pachytene spermatocytes and spermatid-like cells were reported in human ITT xenotransplants placed into the scrotum of castrated immunodeficient mice (Wyns et al., 2008; Poels et al., 2013), while early spermatocytes were detected in xenotransplants under the dorsal skin (Sato et al., 2010). Studies from Van Saen et al. (2011, 2013) on intratesticular xenotransplantation of human ITT also reported the differentiation of immature germ cells up to the stage of pachytene spermatocytes. We hypothesised that the reason for not achieving full spermatogenesis in human xenotransplants was the relatively short time that human fragments could be maintained in mice. Therefore, we designed a study to conduct intratesticular transplantation using ITT from primates in which testicular tissue matures much faster (in the marmoset, puberty starts around the age of 11 months,

but in the human, it starts around the age of 12 years). Similarities between the common marmoset (*Callithrix jacchus*) and the human (including reproductive hormonal activity, germ cell differentiation and proliferation, and the efficiency of spermatogenesis) render the marmoset as the most accepted pre-clinical animal model for human testicular development (Sharpe *et al.*, 2000; Mitchell *et al.*, 2008). Previously, in marmoset, spermatogonia and spermatocytes were observed by Schlatt *et al.* (2002) while pre-meiotic arrest was reported by Wistuba *et al.* (2004) in ITT xenografts under the dorsal skin.

In this study, we compared two potential transplantation sites and report for the first time complete spermatogenesis with generation of spermatozoa in marmoset transplants following intratesticular xenotransplantation of ITT.

Materials and Methods

Ethical approval

All experimental procedures were performed in compliance with the European legislation of animal experimentation, the German Federal Law on the Care and Use of Laboratory Animals (LANUV NRW 84-02.04.2015.A281) and were approved by the Animal Care and Use Committee of the Vrije Universiteit Brussel (16-216-1).

Testis tissue donors

Two prepubertal co-twin marmosets aged 6 months (*Callithrix jacchus*) were used for this study (Fig. 1A). The marmosets were maintained under standardised conditions in the University of Münster primate facility (Münster, Germany). They were kept in families under a 12-h to 12-h light/dark cycle and fed with food pellets (Altromin; Lage, Germany) together with beef or chicken meat and a daily supplement of fresh fruits and vegetables. They had unlimited access to tap water. Housing and exercise conditions were identical for both animals.

For the surgical removal of the testes, marmosets were anaesthetised by a single intravenous injection of pentobarbital-sodium (Narcoren; Merial-Boehringer, Ingelheim, Germany; 0.1 ml/kg body weight, 10% solution). Castration was performed through a scrotal incision, and following

removal of the testes, the scrotal skin was stitched. The testes were dissected into small fragments (0.8–1 mm³) and kept in cold Dulbecco's Modified Eagle Medium (DMEM; Invitrogen GmbH, Karlsruhe, Germany) at 4°C. The fragments were transported to the Vrije Universiteit Brussel (Brussels, Belgium) and stored overnight at the same conditions. The next morning, the fragments were transplanted.

Transplantation

In total, 147 fragments of marmoset ITT were transplanted either ectopically ($n = 107$) or intratesticularly ($n = 40$) into 4-week-old Swiss Nu/Nu mice ($n = 20$) (Charles River Laboratories, Saint-Germain-Nuelles, France). Prior to transplantation, mice were anaesthetised by a single intraperitoneal injection (7.5 µl/kg body weight) of a mixture of medetomidine hydrochloride (0.1 mg/ml) and ketamine hydrochloride (0.75 mg/ml).

For intratesticular transplantation, a mid-abdominal incision was made, and the testis was exteriorised. Following a fine incision in the tunica albuginea, the transplant was placed under the tunica and the incision was closed using non-absorbable suture (U7003, 10-0; Ethicon, Instruvet, Beringen-Paal, Belgium). A single testis tissue fragment from one marmoset was placed in the testicular parenchyma of one testis of the recipient, while a single fragment from the other marmoset was placed in the contralateral testis (Van Saen *et al.* 2011, 2013). Ectopic transplantation was performed simultaneously on the same recipient.

For ectopic transplantation, two or three fragments of testis tissue from each marmoset (Schlatt *et al.*, 2002; Wistuba *et al.*, 2004; Liu *et al.*, 2016) were placed under the dorsal skin of each recipient mouse using an implant G13 needle (Popper Precision Instruments, NY, USA). Testis tissue fragments from one marmoset were transplanted on one side of the dorsal midline while fragments from the other marmoset were transplanted on the contralateral side. The position of the transplanted tissue was recorded to determine the identity of the donor.

Transplanted mice were randomly allocated into two study groups: one for evaluation after a 4-month post-transplantation period ($n = 10$) and the other one for evaluation after a 9-month post-transplantation period ($n = 10$). Two mice, one from each time point, died before the time of the analysis, and were not included in the study.

After transplantation, mice were housed in the central animal facility of the Vrije Universiteit Brussel (Jette, Belgium) in individually ventilated cages under a controlled environment of 14-h to 10-h light/dark cycle with access to sterilised diet and water.

Transplant recovery

Mice were sacrificed by cervical dislocation at 4 and 9 months post-transplantation. For the recovery of the ectopic transplants, the back skin of the mouse was removed, and the transplants were dissected from the skin. The marmoset testis tissue was fixed in formalin-based fixative (AFA0060AF59001; VWR International, Leuven, Belgium) and embedded in paraffin. For the recovery of the intratesticular transplants, the mouse testes were collected and placed in pre-warmed (34°C) DMEM/F12 (Life Technologies, Thermo Fischer Scientific, Gent, Belgium). After removing the tunica albuginea, the testes were fixed and embedded in paraffin. To localise the marmoset testis tissue within the mouse testis, the paraffin-embedded samples were sectioned at 5-µm thickness and immunostaining for human/marmoset specific VIMENTIN (mouse monoclonal anti-VIMENTIN; dilution 1:100; M072501; Dako, Heverlee, Belgium) was performed for every 10th section. The sections between the VIMENTIN-positive sections (sections containing marmoset tissue) were kept for further analysis, whilst the sections between the VIMENTIN-negative sections (sections containing only mouse tissue) were discarded.

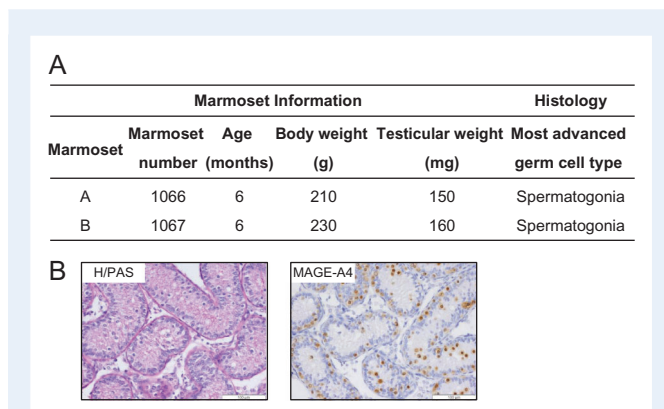


Figure 1 Marmoset testis tissue donor information. (A) Basic parameters of the testis tissue donors. (B) Representative sections of immature marmoset testis tissue prior to xenotransplantation. Histological identification of spermatogonia as the most advanced germ cell type by H/PAS and immunohistochemical confirmation by MAGE-A4.

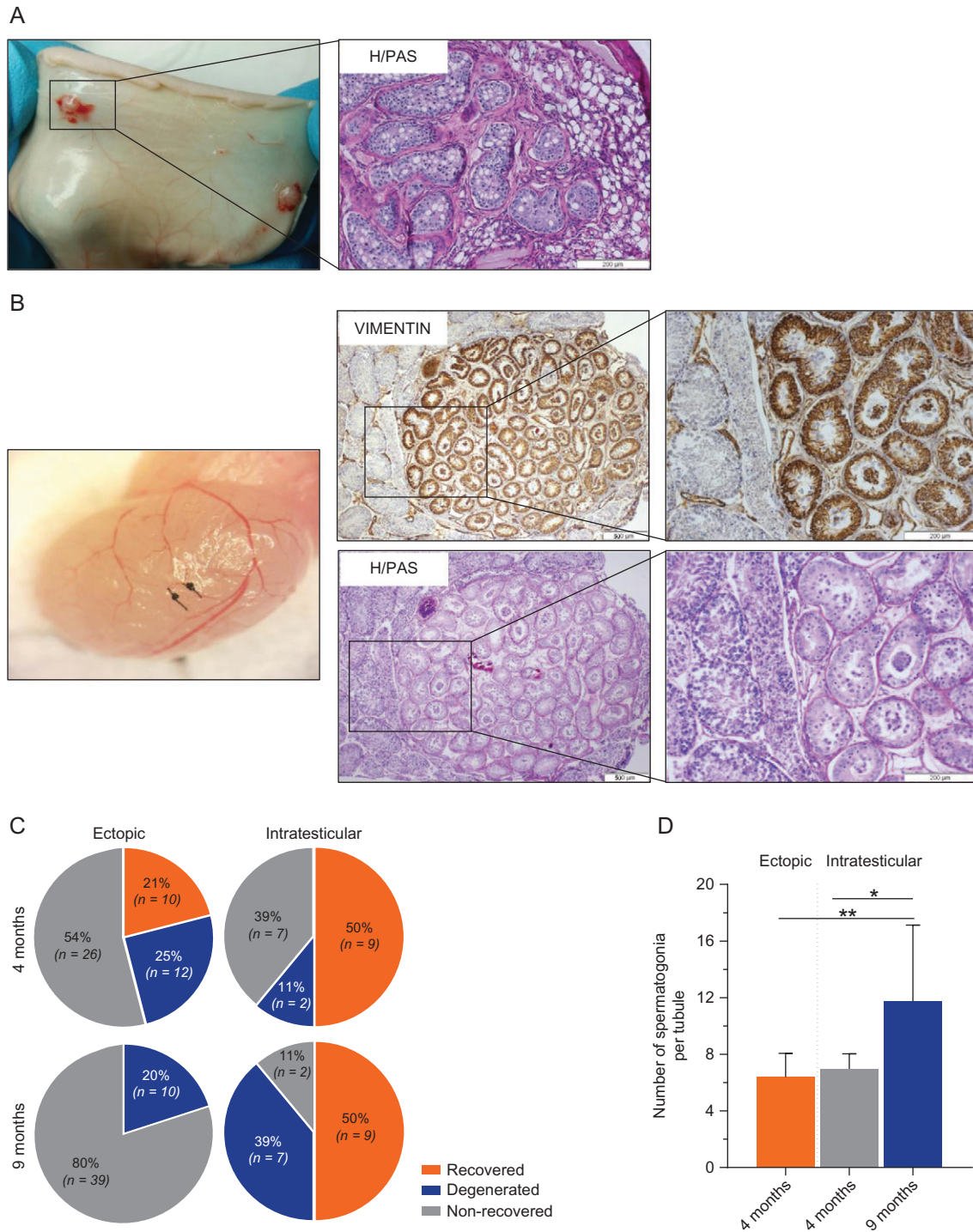


Figure 2 Recovery of marmoset testis xenotransplants and spermatogonial quantity. (A) Recovery of ectopic marmoset testis xenotransplants in immunodeficient mouse. Transplant contains seminiferous tubules with germ cells as histologically observed by H/PAS. (B) Recovery of intratesticular xenotransplants. Localisation of the transplant within the mouse testicular parenchyma by immunostaining for VIMENTIN (brown) and the histology of marmoset testis tissue on the subsequent H/PAS stained section. (C) Increased survival rates for the intratesticular marmoset testis tissue xenotransplants compared to the ectopic xenotransplants at 4 ($P < 0.05$) and 9 months ($P < 0.0001$) post-transplantation. (D) Mean number of spermatozoa per tubule in the xenotransplants. * $P < 0.05$; ** $P < 0.01$.

Histology

Dewaxed sections were stained with haematoxylin/periodic acid-Schiff (H/PAS). Following rehydration in a graded alcohol series (100, 90 and 70% alcohol) and washing in distilled water, sections were oxidised in periodic acid solution (VWR International) for 5 min. After another washing step, sections were placed in Schiff reagent (VWR International) for 15 min. Next, testis tissue sections were washed and counterstained with haematoxylin for 3 min.

Immunohistochemistry

For immunohistochemical staining, dewaxed and rehydrated sections were washed with phosphate-buffered saline (PBS; Life-technologies, Gent, Belgium) and non-specific peroxidase was blocked with 0.3% (v/v) hydrogen peroxide in methanol for 30 min. Antigen retrieval was performed by heating the tissue sections in citrate buffer (0.01 M, pH 6.0) in a water bath (95°C) for 75 min. Following another washing step, non-specific adhesion sites were blocked with 4% normal goat serum (Tebu-bio, Boechout, Belgium) diluted in PBS or with Cas-block (Life Technologies) (only for CREM-I antibody) for 30 min. Next, primary antibodies against VIMENTIN (marmoset specific), MAGE-A4 (mouse monoclonal anti-melanoma-associated antigen 4; dilution 1:200; gift from Dr Spagnoli; marker for spermatogonia and primary spermatocytes, marmoset specific), BOLL (mouse monoclonal anti-BOLL; dilution 1:400; H00066037-M03; R&D system, Abingdon, UK; marker for spermatocytes (meiotic cells)), CREM-I (rabbit polyclonal anti-CREM-I; dilution 1:400; sc-440; Santa-Cruz Biotechnology, Heidelberg, Germany; marker for round spermatids (post-meiotic cells)) and ACROSIN (rabbit polyclonal anti-ACROSIN; dilution 1:500; sc-67151; Santa-Cruz; marker for acrosome visualisation in round, elongating and elongated spermatids (post-meiotic cells), marmoset specific), were applied to the sections and incubated in a humidified chamber overnight at 4°C. After washing, sections were incubated with a peroxidase-labelled secondary antibody (Dako Real Envision Detection System; Dako) for 1 h. Staining was visualised with 3,3'-diaminobenzidine (Dako Real™ Envision™ Envision system; Dako) as the chromogen and haematoxylin as the counterstain. Testis tissue sections from adult marmoset were used as positive control and sections where the primary antibody was omitted served as negative control (Supplementary Fig. S1).

Transplant survival

At both time points, the survival of the transplants was evaluated by light microscopic observation of H/PAS stained sections. Transplants were recorded as 'recovered' if they consisted of well-defined seminiferous tubules containing Sertoli cells and/or germ cells and as 'degenerated' if only interstitial cells and fibrosis were observed. Transplants were recorded as 'non-recovered' if transplants were not detectable by VIMENTIN staining (intratesticular) or if transplants were no longer visible under the dorsal skin (ectopic).

Spermatogonial quantity

The number of spermatogonia in the testis tissue transplants was evaluated on MAGE-A4 stained sections. MAGE-A4 is a germ cell marker expressed mainly by spermatogonia (strong expression), but also by primary spermatocytes (Takahashi *et al.*, 1995). Therefore, only MAGE-A4 positive cells located at the basement membrane of seminiferous tubules were counted. Analysis was performed on one cross-section from four different depths of each transplant. Only the round intact tubules were included in the evaluation. The results were expressed as the mean number of MAGE-A4 positive cells per round tubule.

Germ cell differentiation and spermatogenic progress

The level of germ cell differentiation in the testis tissue transplants was assessed by morphological identification of different germ cell types on H/PAS stained sections. The presence of spermatogonia and primary spermatocytes was confirmed by immunostaining for MAGE-A4, and meiotic activity was confirmed by staining for BOLL protein. Transplants with elongating or elongated spermatids or spermatozoa were identified as transplants with complete spermatogenesis. The presence of post-meiotic cells was confirmed by immunostaining for the post-meiotic marker CREM-I (Behr and Weinbauer, 2001). Staining for ACROSIN confirmed the presence of round, elongating and elongated spermatids (Muciaccia *et al.*, 2013).

To evaluate the spermatogenic progress in the intratesticular transplants, the percentage of seminiferous tubules with the most advanced germ cell type present was assessed per transplant for both time points. Tubular cross-sections were recorded: as 'no germ cells' if germ cells were lacking; as 'pre-meiotic' if spermatogonia were the most advanced germ cell type; as 'meiotic' if tubules contained spermatocytes as the most advanced germ cell type; and as 'post-meiotic' if spermatids or spermatozoa were observed. All seminiferous tubules in every 10th section were counted for each transplant.

Statistical analysis

Statistical analysis was performed using GraphPad Prism 6 (La Jolla, CA, USA). The chi-squared test was applied to compare the percentages of transplant survival between different transplantation sites. Statistical differences between subcutaneous transplants and intratesticular transplants were determined using the Mann-Whitney *U* test. Data on the intratesticular transplants between the two time points were analysed by applying paired *t*-test. $P < 0.05$ was considered significant. Data are expressed as mean \pm SD.

Results

Transplant survival

Marmoset testis tissue xenotransplants were recovered at 4 and 9 months post-transplantation (Fig. 2). For ectopic transplants, 4 months post-transplantation, 21% (10/48) were recovered, 25% (12/48) were degenerated and 54% (26/48) could not be recovered. For intratesticular transplants, 50% (9/18) were recovered, 11% (2/18) were degenerated and 39% (7/18) could not be recovered. Overall, the survival rate of the intratesticular transplants was higher compared to the ectopic transplants ($P = 0.019$). Nine months post-transplantation, 20% (10/49) of the ectopic transplants were degenerated and 80% (39/49) could not be recovered. On the contrary, the survival rate was significantly higher ($P < 0.0001$) for the intratesticular transplants as 50% (9/18) of the transplants were recovered, while 39% (7/18) were degenerated and 11% (2/18) could not be recovered. No difference was detected in the transplant survival between the two donor marmosets at any time point (Supplementary Table S1).

Spermatogonial quantity

For each ectopic transplant, 54.1 ± 15.8 well-preserved round seminiferous tubules were analysed (541 tubules in total, 131 for marmoset A and 410 for marmoset B) at 4 months post-transplantation. For

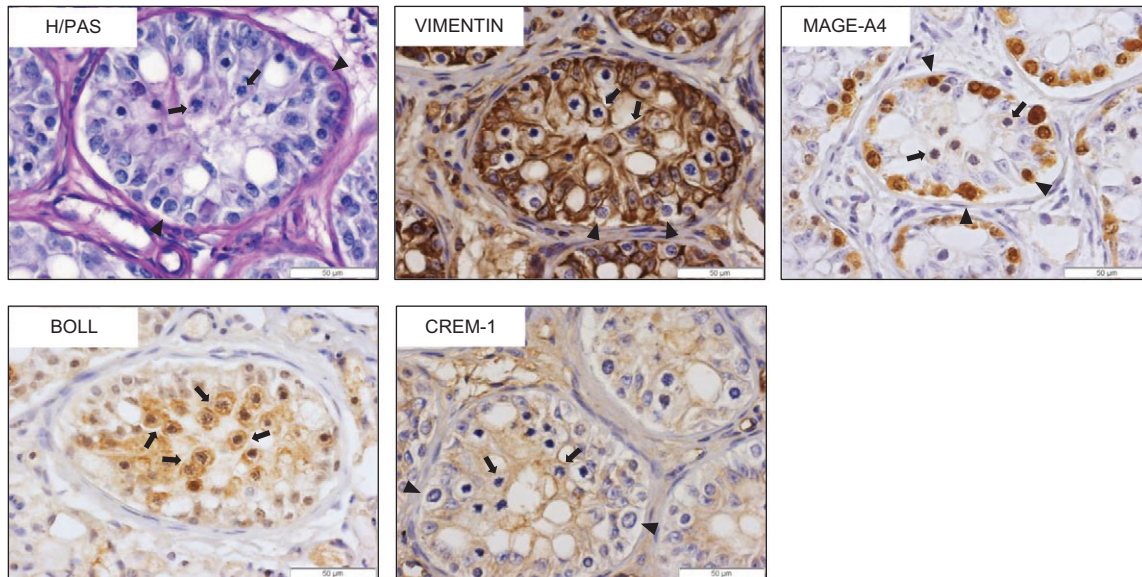


Figure 3 Germ cell differentiation in ectopic marmoset testis tissue xenotransplants at 4 months post-transplantation. Morphological identification of spermatogonia and spermatocytes by H/PAS and VIMENTIN, and confirmation by immunostaining for MAGE-A4 and BOLL expression. Transplants were negative for the post-meiotic marker CREM-1. Arrows indicate spermatocytes in the lumen of marmoset seminiferous tubules; arrowheads indicate spermatogonia at the basal membrane.

each intratesticular transplant, 47.11 ± 15.3 well-preserved round seminiferous tubules were analysed (424 tubules in total, 154 for marmoset A and 270 for marmoset B) at 4 months post-transplantation, and 44.4 ± 18.7 well-preserved round seminiferous tubules were analysed (400 tubules in total, 197 for marmoset A and 203 for marmoset B) at 9 months post-transplantation. No difference was observed in the number of spermatogonia per tubule between ectopic and intratesticular transplants at 4 months post-transplantation (6.4 ± 1.6 vs. 7.0 ± 1.0). The number of spermatogonia in the intratesticular transplants was significantly higher at 9 months post-transplantation compared to 4 months post-transplantation (11.7 ± 5.1 vs. 7.0 ± 1.0 ; $P = 0.018$).

Germ cell differentiation

Histological analysis revealed that spermatogonia were the most advanced germ cells in marmoset ITT at the time of transplantation (Fig. 1B). Spermatogenesis in all (10/10) recovered ectopic transplants was ongoing but did not progress beyond the spermatocyte stage during the first 4 months post-transplantation (Fig. 3). On the contrary, at 4 months post-transplantation, 78% (7/9) of the recovered intratesticular transplants showed post-meiotic differentiation confirmed by the presence of round, elongating and elongated spermatids and 33% (3/9) showed complete spermatogenesis. Complete spermatogenesis and spermatozoa were observed in all recovered (9/9) intratesticular transplants at 9 months post-transplantation (Fig. 4).

Spermatogenic progress

For intratesticular transplants, 233.9 ± 113.7 seminiferous tubules were analysed (2105 seminiferous tubules in total, 859 for marmoset A and 1246 for marmoset B) at 4 months post-transplantation, and

283.0 ± 202.3 seminiferous tubules (2547 seminiferous tubules in total, 1228 for marmoset A and 1319 for marmoset B) at 9 months post-transplantation. Intratesticular transplants contained a significantly higher percentage of seminiferous tubules with post-meiotic cells at 9 months compared to 4 months post-transplantation (37 vs. 5%; $P < 0.001$). In addition, there were fewer tubules without germ cells at 9 months compared to 4 months post-transplantation (2 vs. 8% respectively; $P = 0.014$). The percentage of seminiferous tubules with meiotic cells as the most advanced germ cell type was lower at 9 months compared to 4 months post-transplantation (38 vs. 54%; $P = 0.004$), while the percentage of tubules containing pre-meiotic cells was similar (23 vs. 33%; $P = 0.067$) at both time-points (Fig. 5).

Discussion

To our knowledge, this is the first study to demonstrate the production of spermatozoa following intratesticular transplantation of immature non-human primate testis tissue. Transplantation of marmoset testis fragments into the testicular parenchyma of immunodeficient mice supported the initiation and establishment of complete spermatogenesis and enabled the long-term survival of the transplants. On the contrary, subcutaneous transplantation was inadequately supported over the longer period, with none of the transplants surviving at 9 months post-transplantation. Moreover, only spermatogonia and spermatocytes were observed at 4 months post-transplantation.

The present study has compared ITT survival following ectopic and intratesticular xenotransplantation over an extended period. Previous studies conducting subcutaneous TTT from neonatal and prepubertal marmosets reported the recovery of xenotransplants, containing spermatogonia or spermatocytes as the most advanced germ cell type

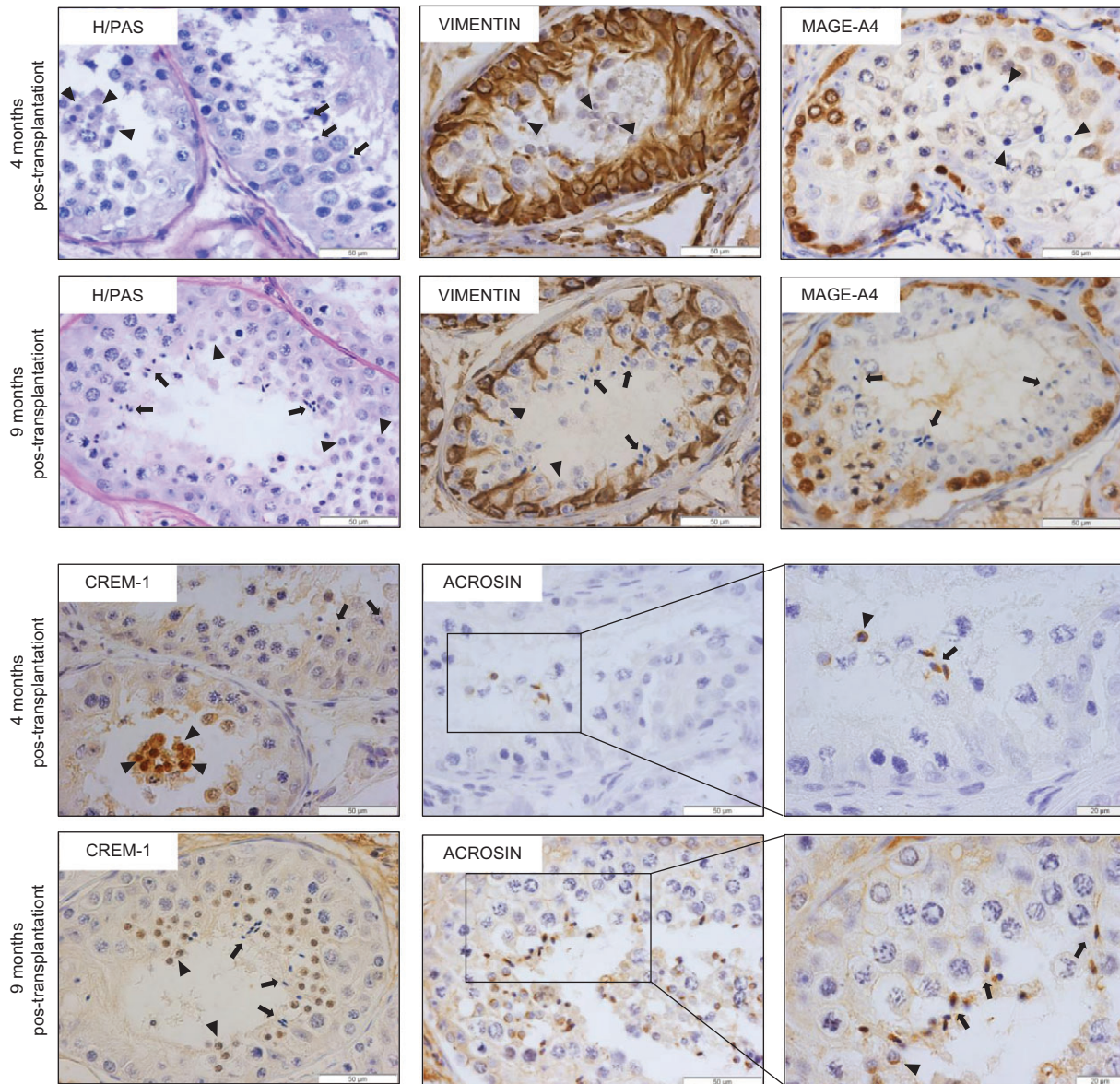


Figure 4 Germ cell differentiation in intratesticular marmoset testis tissue xenotransplants. Morphological identification of post-meiotic germ cells by H/PAS, and on VIMENTIN and MAGE-A4 stained sections and immunohistochemical confirmation by CREM-1 expression and acrosome visualisation by immunostaining for ACROSIN. Arrowheads indicate round spermatids; arrows indicate elongating/elongated spermatids.

up to 4 and a half months post-transplantation (Schlatt *et al.*, 2002; Wistuba *et al.*, 2004). The survival of transplants without microvascular anastomosis depends on neovascularisation and establishment of a circulatory connection with the recipient to secure a sufficient oxygen and nutrient supply. Prolonged warm ischemia time is associated with transplant failure (Tennankore *et al.*, 2016) and may depend on the transplantation site, due to differences in vascularisation between sites (Jahnukainen *et al.*, 2012). The testis is a well vascularised organ, similar to muscle and kidney capsules (Soleimani *et al.*, 2010), which is not the case for the subcutaneous site (Vériter *et al.*, 2013). Therefore, the testicular parenchyma can provide fast and efficient transplant revascularisation and consequently minimise the period of post-transplantation hypoxia. In a clinical setting, it is possible that normal

vascularisation may be disturbed in some patients due to the gonadotoxic treatment but strategies to improve the vascularisation of the transplants using angiogenic factors, such as vascular endothelial growth factor (VEGF) have been reported. A positive effect of VEGF on transplant neovascularisation has been observed in mouse ITT transplants following hydrogel delivery (Poels *et al.*, 2016) and in human ITT transplants by *in vitro* pre-treatment of the tissue prior to xenotransplantation (Ntemou *et al.*, 2017). In our study, the combination of a limited vascularisation with the increased metabolic needs and high demand for oxygen of the growing subcutaneous marmoset transplants could have resulted in their gradual degeneration. This hypothesis has also been proposed to explain the failure of adult testis tissue xenotransplantation (Geens *et al.*, 2006; Schlatt *et al.*, 2006).

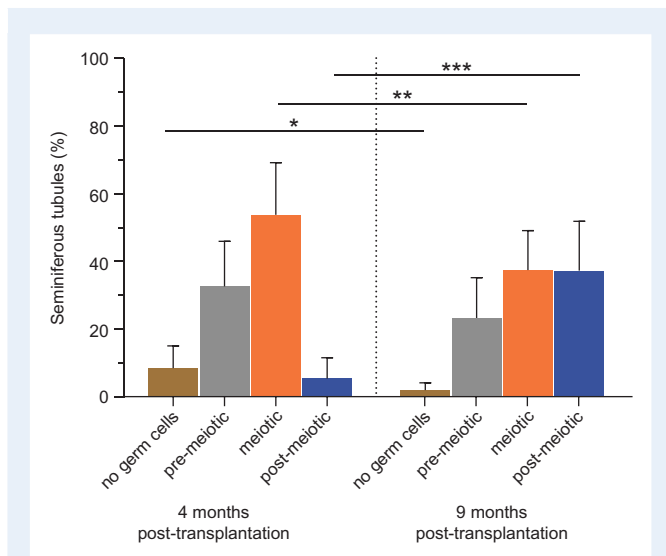


Figure 5 Spermatogenic progress in intratesticular marmoset testis tissue xenotransplants. Percentages of seminiferous tubules containing no germ cells, pre-meiotic (spermatogonia), meiotic (spermatocytes) and post-meiotic (spermatids and spermatozoa) germ cells in the recovered marmoset transplants at 4 and 9 months post-transplantation. * $P < 0.05$; ** $P < 0.01$; *** $P < 0.001$.

Indeed, subcutaneous transplants appeared to be smaller compared to the intratesticular transplants at the same time point. The limited vascularisation and hypoxic conditions might have caused the observed degeneration of tubules and fibrosis in both peripheral and central regions of the transplants. Less fibrosis was observed in the intratesticular transplants. In general, the recovery rate of the transplants, both intratesticular and subcutaneous, appears to be lower than the rates reported in other xenotransplantation studies, although it is difficult to make an accurate comparison due to the different species used, the size of the fragments and the length of the xenotransplantation period. However, it is worth mentioning that in our study, we classified the transplants into three categories: 'recovered', 'degenerated' and 'non-recovered' while the other studies distinguish only between 'recovered' and 'non-recovered' transplants. Therefore, it is possible that the 'degenerated' transplants (transplants that were recovered but contained no well-defined tubules) were also included in the 'recovered' group, resulting in ostensibly higher survival rates. Despite the lower survival rate of the subcutaneous xenotransplants, both transplantation sites supported spermatogonial survival with the number of spermatogonia per tubule being similar between subcutaneous and intratesticular transplants at 4 months post-transplantation, while at 9 months intratesticular transplants contained more spermatogonia which reflects the growth of the transplants and the effective establishment of the spermatogenic process.

Intratesticular xenotransplantation of marmoset ITT enabled the differentiation of spermatogonia into meiotic cells and ultimately spermatozoa. The 9-month transplants showed fewer tubules without germ cells and more tubules containing post-meiotic cells, indicating progressive and sustained spermatogenesis. The proportion of tubules containing pre-meiotic cells remained similar. Tubules containing no germ cells at 4 months were repopulated by spermatogonia, while in

the tubules containing meiotic cells at 4 months, germ cells further differentiated into spermatids and spermatozoa.

In other non-human primates, complete spermatogenesis has been reported previously and the sperm obtained from subcutaneous xenotransplants has been used to generate embryos by ICSI up to the blastocyst stage (rhesus monkey; Honaramooz et al., 2004) and live offspring (cynomolgus monkey; Liu et al., 2016). In the latter study, mature sperm was observed in fresh and frozen-thawed fragments from two juvenile monkeys transplanted subcutaneously in nude mice at 10 months post-transplantation. Acceleration of testicular maturation has been reported by 1–2 years while most of the transplants survived and grew well, with some even up to 17 months post-transplantation, but no data on the actual survival rates were provided. These and most of the other studies were performed using castrated recipients to mimic the hormonal milieu just before puberty with high levels of pituitary gonadotrophins, due to the removal of the negative feedback by testosterone and inhibin. The increased level of FSH in the castrated recipients stimulated Sertoli cell proliferation while LH triggered testosterone production in (primate) ectopic ITT transplants (Honaramooz et al., 2002, 2004). In other studies, additional manipulation of the endocrine environment of the castrated recipient by exogenous administration of gonadotrophins was necessary to achieve spermatogenesis (Rathi et al., 2006, 2008). Lack of complete spermatogenesis in ectopic marmoset ITT xenotransplants was initially attributed to their unique LH receptor, resulting in unresponsiveness to mouse LH and arrest of germ cell differentiation (Gromoll et al., 2003). Nonetheless, co-transplantation with hamster testis tissue, for local testosterone support, or with exogenous administration of human chorionic gonadotrophin, failed to establish spermatogenesis (Wistuba et al., 2004). However, autologous transplantation of ITT into the scrotum of immature castrated marmosets led to complete spermatogenesis, with 32% of the seminiferous tubules of the transplants containing post-meiotic germ cell after 14 months, although ectopic transplants showed spermatogenic arrest, confirming the need for a lower temperature environment to induce germ cell differentiation (Wistuba et al., 2006; Luetjens et al., 2008). In this study, we showed that the testicular parenchyma is a superior site for transplanting ITT, likely because of its optimal temperature regulation and the unique hormonal environment essential for germ cell maturation, without the necessity for castration or gonadotrophin stimulation.

Even though intratesticular xenotransplantation of marmoset ITT led to post-meiotic differentiation of germ cells, previous studies utilising ITT from prepubertal boys have not been successful. Transplantation of human ITT into the testicular parenchyma of recipient mice resulted in germ cell differentiation up to the spermatocyte stage at 9 months post-transplantation (Van Saen et al., 2011), despite exogenous FSH administration (Van Saen et al., 2013). Germ cell differentiation and transformation into spermatozoa requires the maturation of the testicular microenvironment, including the Sertoli cells, which are critical for the support of spermatogenesis (Sharpe, 1994). Indeed, the previous studies confirmed the functionality of Sertoli cells in the human transplants, but not their fully matured status, as indicated by the expression of anti-Mullerian hormone, a marker for Sertoli cell immaturity, at 9 months post-transplantation. The results of this study are significant for future studies on human ITT xenotransplantation. Initially, it was suggested that species-specific characteristics in the organisation of spermatogenesis was the cause for failure to

obtain haploid germ cells following xenotransplantation (e.g. multiple stages of spermatogenesis in one tubule in marmoset and human, while in rodents and rhesus monkey, only one stage of spermatogenesis is found per tubule (Luetjens *et al.*, 2005; Vistuba *et al.*, 2006)). However, here, we showed that complete spermatogenesis in marmoset ITT xenotransplants is achievable when transplanted into the testicular parenchyma. These results support our hypothesis that the generation of sperm in human ITT xenotransplants may require a prolonged (more than 9 months) transplantation period. Humans have a long prepubertal period and such xenotransplantation studies could be limited by the short lifespan of the mouse recipient. Future studies focusing on the increase of the xenotransplantation period either by the re-transplantation of the already transplanted testis tissue into a younger recipient or by using other species as recipients, e.g. non-human primates, are necessary to identify the possible cause(s) of failure in the human xenotransplants.

The main limitation of our study is that it has not been possible to test the functionality of the spermatozoa in the transplants due to ethical restrictions, but previous studies have confirmed the fertilisation competence of sperm derived from subcutaneous ITT xenotransplants from non-human primates. (Honaramooz *et al.*, 2004; Liu *et al.*, 2016). However, the use of sperm produced in xenotransplants of immature human testis tissue is unlikely to be a viable clinical option for fertility restoration due to the risk of zoonoses. To extrapolate our results into a clinical setting, autologous transplantation of cryopreserved ITT into the testis of the infertile patient would enable the testicular extraction of viable spermatozoa and the generation of embryos by ICSI. However, auto-transplantation of ITT cannot be considered for patients suffering from systemic cancers due to the risk of reintroducing the disease. In a future study, a comparison between the transplantation of non-human ITT in the testicular parenchyma and in the scrotum, two potential transplantation sites with the same temperature, will contribute to determine the factors and mechanisms regulating spermatogenesis in ITT transplants. Additionally, since high levels of gonadotropins are often reported in patients who become azoospermic following gonadotoxic treatment, the effect of exogenous administration of FSH or human chorionic gonadotropin on transplant survival and germ cell differentiation should be investigated. Moreover, a study on autologous transplantation of ITT in the testicular parenchyma of non-human primates following gonadotoxic treatment as well as analysing the epigenetic normality of the spermatozoa produced, is warranted.

To conclude, intratesticular xenotransplantation of non-human primate ITT resulted in long-term survival of the transplants and complete differentiation of immature germ cells into spermatozoa. These results encourage the design of new experiments on human xenotransplantation and the further development of intratesticular tissue transplantation as a future clinical strategy for fertility restoration in patients having undergone gonadotoxic treatments.

Supplementary data

Supplementary data are available at *Human Reproduction* online.

Acknowledgements

The authors would like to thank Fabian Van Haelst and Pierre Hilven for their technical assistance with the immunohistochemistry

procedure. They are also thankful to Dr Sharma for the support during the preparation of the fresh marmoset tissue and Dr Mincheva for the technical assistance during the preparation of sections from the paraffinised testis tissue and H/PAS staining. The authors are also grateful to Dr Spagnoli for providing the MAGE-A4 antibody and Dr W. Cools for the statistical advice.

Authors' roles

E.N. was involved in conception and design of the study, performing experiments, acquisition of data, analysis and interpretation of data, drafting of the article and critical approval of the final article. P.K. was involved in the transplantation of the tissue, critical revision of the article and final approval of the article. D.V.S. was involved in the analysis and interpretation of data, critical revision of the article and final approval of the article. J.W. was involved in the analysis and interpretation of data, critical revision of the article and final approval of the article. R.T.M. was involved in the analysis and interpretation of data, critical revision of the article and final approval of the article. S.S. was involved in the conception and design of the study, analysis and interpretation of data, critical revision of the article and final approval of the article. E.G. was involved in the conception and design of the study, analysis and interpretation of data, critical revision of the article and final approval of the article.

Funding

This project was funded by the ITN Marie Curie Programme 'Growsperm' (EU-FP7-PEOPLE-2013-ITN 603568) and the scientific Fund Willy Gepts from the UZ Brussel (ADSI677). D.V.S. is a post-doctoral fellow of the Fonds Wetenschappelijk Onderzoek (FWO; 12M2815N).

Conflict of interest

No conflict of interest is declared.

References

- Abrishami M, Abbasi S, Honaramooz A. The effect of donor age on progression of spermatogenesis in canine testicular tissue after xenografting into immunodeficient mice. *Theriogenology* 2010;**73**:512–522.
- Behr R, Weinbauer GF. cAMP response element modulator (CREM): an essential factor for spermatogenesis in primates? *Int J Androl* 2001;**24**: 126–135.
- de Michele F, Poels J, Weerens L, Petit C, Evrard Z, Ambroise J, Gruson D, Wyns C. Preserved seminiferous tubule integrity with spermatogonial survival and induction of Sertoli and Leydig cell maturation after long-term organotypic culture of prepubertal human testicular tissue. *Hum Reprod* 2017;**32**:32–45.
- Geens M, de Block G, Goossens E, Frederickx V, van Steirteghem A, Tournaye H. Spermatogonial survival after grafting human testicular tissue to immunodeficient mice. *Hum Reprod* 2006;**21**:390–396.
- Giudice MG, de Michele F, Poels J, Vermeulen M, Wyns C. Update on fertility restoration from prepubertal spermatogonial stem cells: how far are we from clinical practice? *Stem Cell Res* 2017;**21**:171–177.

- Goossens E, Van Saen D, Tournaye H. Spermatogonial stem cell preservation and transplantation: from research to clinic. *Hum Reprod* 2013;**28**: 897–907.
- Green DM, Kawashima T, Stovall M, Leisenring W, Sklar CA, Mertens AC, Donaldson SS, Byrne J, Robison LL. Fertility of male of childhood cancer: a report from the Childhood Cancer Survivor Study. *J Clin Oncol* 2010; **28**:332–339.
- Gromoll J, Wistuba J, Terwort N, Godmann M, Müller T, Simoni M. A new subclass of the Luteinizing Hormone/Chorionic Gonadotropin receptor lacking exon 10 messenger RNA in the New World Monkey (Platyrrhini) lineage. *Biol Reprod* 2003;**69**:75–80.
- Honaramooz A, Li MW, Penedo MC, Meyers S, Dobrinski I. Accelerated maturation of primate testis by xenografting into mice. *Biol Reprod* 2004; **70**:1500–1503.
- Honaramooz A, Snedaker A, Boiani M, Schöler H, Dobrinski I, Schlatt S. Sperm from neonatal mammalian testes grafted in mice. *Nature* 2002; **418**:778–781.
- Jahnukainen K, Ehmcke J, Hou M, Schlatt S. Testicular function and fertility preservation in male cancer patients. *Best Pract Res Clin Endocrinol Metab* 2011;**25**:287–302.
- Jahnukainen K, Ehmcke J, Nurmio M, Schlatt S. Autologous ectopic grafting of cryopreserved testicular tissue preserves the fertility of prepubescent monkeys that receive sterilizing cytotoxic therapy. *Cancer Res* 2012;**72**: 5174–5178.
- Jahnukainen K, Hou M, Petersen C, Setchell B, Söder O. Intratesticular transplantation of testicular cells from leukemic rats causes transmission of leukemia. *Cancer Res* 2001;**61**:706–710.
- Kim Y, Selvaraj V, Pukazhenthil B, Travis AJ. Effect of donor age on success of spermatogenesis in feline testis xenografts. *Reprod Fertil Dev* 2007;**19**: 869–876.
- Liu Z, Nie YH, Zhang CC, Cai YJ, Wang Y, Lu HP, Li YZ, Cheng C, Qiu ZL, Sun Q. Generation of macaques with sperm derived from juvenile monkey testicular xenografts. *Cell Res* 2016;**26**:139–142.
- Luetjens CM, Stukenborg JB, Nieschlag E, Simoni M, Wistuba J. Complete spermatogenesis in orthotopic but not in ectopic transplants of autologously grafted marmoset testicular tissue. *Endocrinology* 2008;**149**:1736–1747.
- Luetjens CM, Weinbauer GF, Wistuba J. Primate spermatogenesis: new insights into comparative testicular organization, spermatogenic efficiency and endocrine control. *Biol Rev Camb Philos Soc* 2005;**80**:475–488.
- Mitchell RT, Cowan G, Morris KD, Anderson RA, Fraser HM, McKenzie KJ, Wallace WH, Kelnar CJ, Saunders PT, Sharpe RM. Germ cell differentiation in the marmoset (*Callithrix jacchus*) during fetal and neonatal life closely parallels that in the human. *Hum Reprod* 2008;**23**:2755–2765.
- Muciaccia B, Boitani C, Berloco BP, Nudo F, Spadetta G, Stefanini M, de Rooij DG, Vicini E. Novel stage classification of human spermatogenesis based on acrosome development. *Biol Reprod* 2013;**89**:1–10.
- Ntemou E, Kadam P, Van Saen D, Vicini E, Goossens E. Effect of human recombinant vascular endothelial growth factor (VEGF-165) on testicular tissue xenografts from prepubertal boys [abstract]. *Hum Reprod* 2017;**32**:368. Abstract number P-509.
- Oatley JM, de Avila DM, Reeves JJ, McLean DJ. Spermatogenesis and germ cell transgene expression in xenografted bovine testicular tissue. *Biol Reprod* 2004;**71**:494–501.
- Picton H, Wyns C, Anderson RA, Goossens E, Jahnukainen K, Kliesch S, Mitchell RT, Pennings G, Rives N, Tournaye H et al. On behalf of the ESHRE Task Force On Fertility Preservation In Severe Diseases. A European perspective on testicular tissue cryopreservation for fertility preservation in prepubertal and adolescent boys. *Hum Reprod* 2015;**30**: 2463–2475.
- Poels J, Abou-Ghannam G, Decamps A, Leyman M, Des Rieux A, Wyns C. Transplantation of testicular tissue in alginate hydrogel loaded with VEGF nanoparticles improves spermatogonial recovery. *J Control Release* 2016;**234**:79–89.
- Poels J, Van Langendonck A, Many MC, Wese FX, Wyns C. Vitrification preserves proliferation capacity in human spermatogonia. *Hum Reprod* 2013;**28**:578–589.
- Rathi R, Honaramooz A, Zeng W, Turner R, Dobrinski I. Germ cell development in equine testis tissue xenografted into mice. *Reproduction* 2006; **131**:1091–1098.
- Rathi R, Zeng W, Megee S, Conley A, Meyers S, Dobrinski I. Maturation of testicular tissue from infant monkeys after xenografting into mice. *Endocrinology* 2008;**149**:5288–5296.
- Reddy N, Mahla RS, Thathi R, Suman SK, Jose J, Goel S. Gonadal status of male recipient mice influences germ cell development in immature buffalo testis tissue xenograft. *Reproduction* 2012;**143**:59–69.
- Sato Y, Nozawa S, Yoshiike M, Arai M, Sasaki C, Iwamoto T. Xenografting of testicular tissue from an infant human donor results in accelerated testicular maturation. *Hum Reprod* 2010;**25**:1113–1122.
- Schlatt S, Honaramooz A, Ehmcke J, Goebell PJ, Rübber H, Dhir R, Dobrinski I, Patrizio P. Limited survival of adult human testicular tissue as ectopic xenograft. *Hum Reprod* 2006;**21**:384–389.
- Schlatt S, Kim SS, Gosden R. Spermatogenesis and steroidogenesis in mouse, hamster and monkey testicular tissue after cryopreservation and heterotopic grafting to castrated hosts. *Reproduction* 2002;**124**:339–346.
- Sharpe RM. Regulation of spermatogenesis. In: Knobil E, Neill JD (eds). *The Physiology of Reproduction*, Vol. 1. New York: Raven Press, 1994, 1363–1434.
- Sharpe RM, Walker M, Millar MR, Atanassova N, Morris K, McKinnell C, Saunders PT, Fraser HM. Effect of neonatal gonadotropin-releasing hormone antagonist administration on Sertoli cell number and testicular development in the marmoset: comparison with the rat. *Biol Reprod* 2000;**62**:1685–1693.
- Shinohara T, Inoue K, Ogonuki N, Kanatsu-Shinohara M, Miki H, Nakata K, Kurome M, Nagashima H, Toyokuni S, Kogishi K et al. Birth of offspring following transplantation of cryopreserved immature testicular pieces and in-vitro microinsemination. *Hum Reprod* 2002;**17**:3039–3045.
- Soleimani R, Heytens E, van den Broecke R, Rottiers IS, Dhont MA, Cuvelier CA, De Sutter P. Xenotransplantation of cryopreserved human ovarian tissue into murine back muscle. *Hum Reprod* 2010;**25**:1458–1470.
- Takahashi K, Shichijo S, Noguchi M, Hirohata M, Itoh K. Identification of MAGE-1 and MAGE-4 proteins in spermatogonia and primary spermatocytes of testis. *Cancer Res* 1995;**55**:3478–3482.
- Tennankore KK, Kim SJ, Alwayn IP, Kiberd BA. Prolonged warm ischemia time is associated with graft failure and mortality after kidney transplantation. *Kidney Int* 2016;**89**:648–658.
- Van Saen D, Goossens E, Bourgain C, Ferster A, Tournaye H. Meiotic activity in orthotopic xenografts derived from human postpubertal testicular tissue. *Hum Reprod* 2011;**26**:282–293.
- Van Saen D, Goossens E, Haentjens P, Baert Y, Tournaye H. Exogenous administration of recombinant human FSH does not improve germ cell survival in human prepubertal xenografts. *Reprod Biomed Online* 2013; **26**:286–298.
- Vériter S, Gianello P, Dufrane D. Bioengineered sites for islet cell transplantation. *Curr Diab Rep* 2013;**13**:745–755.
- Wasilewski-Masker K, Seidel KD, Leisenring W, Mertens AC, Shnorhavorian M, Ritenour CW, Stovall M, Green DM, Sklar CA, Armstrong GT et al. Male infertility in long-term survivors of pediatric cancer: a report from the Childhood Cancer Survivor Study. *J Cancer Surviv* 2014;**8**:437–447.

- Wistuba J, Luetjens CM, Wesselmann R, Nieschlag E, Simoni M, Schlatt S. :
Meiosis in autologous ectopic transplants of immature testicular tissue :
grafted to *Callithrix jacchus*. *Biol Reprod* 2006;**74**:706–713. :
Wistuba J, Mundry M, Luetjens CM, Schlatt S. Cografting of hamster :
(*Phodopus sungorus*) and marmoset (*Callithrix jacchus*) testicular tissues :
into nude mice does not overcome blockade of early spermatogenic dif- :
ferentiation in primate grafts. *Biol Reprod* 2004;**71**:2087–2091. :
Wyns C, Van Langendonck A, Wese FH, Donnez J, Curaba M. Long-term :
spermatogonial survival in cryopreserved and xenografted immature :
human testicular tissue. *Hum Reprod* 2008;**23**:2402–2414. :