



Hypercalcaemia in pseudohypoparathyroidism type 1A and type 1B

Maria P Yavropoulou¹, Efstathios Chronopoulos², George Trovas³, Emmanouil Avramidis², Francesca Marta Elli⁴, Giovanna Mantovani⁴, Pantelis Zebekakis⁵ and John G Yovos⁵

¹1st Propaedeutic Department of Internal Medicine, LAIKO General Hospital of Athens, ²2nd Orthopaedic Department, Konstantopouleio General Hospital, ³Laboratory for Research of the Musculoskeletal System, Th Garofalidis, National and Kapodistrian University of Athens, Athens, Greece, ⁴Endocrinology Unit, Department of Clinical Sciences and Community Health, Fondazione IRCCS Ca' Granda Ospedale Maggiore Policlinico, University of Milan, Milan, Italy, and ⁵1st Department of Internal Medicine, AHEPA University Hospital, Thessaloniki, Greece

Correspondence should be addressed to M P Yavropoulou
Email
maria.yavropoulou.my@gmail.com

Summary

Pseudohypoparathyroidism (PHP) is a heterogeneous group of rare endocrine disorders characterised by normal renal function and renal resistance to the action of the parathyroid hormone. Type 1A (PHP1A), which is the most common variant, also include developmental and skeletal defects named as Albright hereditary osteodystrophy (AHO). We present two cases, a 54- and a 33-year-old male diagnosed with PHP who were referred to us for persistently high levels of serum calcitonin. AHO and multinodular goitre were present in the 54-year-old male, while the second patient was free of skeletal deformities and his thyroid gland was of normal size and without nodular appearance. We performed GNAS molecular analysis (methylation status and copy number analysis by MS-MLPA) in genomic DNA samples for both patients. The analysis revealed a novel missense variant c.131T>G p.(Leu44Pro) affecting GNAS exon 1, in the patient with the clinical diagnosis of PHP1A. This amino acid change appears to be in accordance with the clinical diagnosis of the patient. The genomic DNA analysis of the second patient revealed the presence of the recurrent 3-kb deletion affecting the imprinting control region localised in the STX16 region associated with the loss of methylation (LOM) at the GNAS A/B differentially methylated region and consistent with the diagnosis of an autosomal dominant form of PHP type 1B (PHP1B). In conclusion, hypercalcaemia may be encountered in PHP1A and PHP1B even in the absence of thyroid pathology.

Learning points:

- We describe a novel missense variant c.131T>G p.(Leu44Pro) affecting *GNAS* exon 1 as the cause of PHP1A.
- Hypercalcaemia in PHP1A is considered an associated resistance to calcitonin, as suggested by the generalised impairment of $Gs\alpha$ -mediated hormone signalling. *GNAS* methylation defects, as in type PHP1B, without thyroid pathology can also present with hypercalcaemia.

Background

Pseudohypoparathyroidism (PHP) is a heterogeneous group of rare endocrine disorders characterised by normal renal function and resistance to the renal action of parathyroid hormone. Inactivating PTH/PTHrP signalling disorders (iPPSD) has been recently suggested, although

not widely accepted, as a term encompassing all disorders related to this pathway (1).

The genetic background of the disease includes mutations and/or epigenetic changes at the complex *GNAS* gene on chromosome 20q13.3 that undergoes





parent-specific methylation changes at several sites. *GNAS* gene encodes alpha subunit of the stimulatory guanine nucleotide ($G_s\alpha$) part of the signalling pathway of G-proteins-coupled receptors (GPCRs) and splice variants as well as an antisense transcript. Because of the much reduced paternal $G_s\alpha$ expression in certain tissues, such as the proximal renal tubules, thyroid and pituitary, there is little or no $G_s\alpha$ protein in the presence of maternal *GNAS* mutations. Furthermore, since a wide variety of hormonal peptides such as GHRH, TSH, FSH, LH or calcitonin (CT) act through GPCRs in different tissues, it is clear that patients with PHP may present with additional hormone dysfunctions.

Heterozygous maternal deletions within the *STX16* gene, which are associated with loss of mutation (LOM) at exon A/B also reduce $G_s\alpha$ expression, thus leading to hormonal resistance. Other genes that may be involved in this group of diseases are *PRKAR1A* and *PDE4D* (2).

As there is considerable variability in tissue responsiveness to $G_s\alpha$ protein deficiency, mainly due to differences in the quantity of cAMP that is necessary to activate the physiological responses in each tissue or absence of imprinting in target tissues, other hormones such as ACTH and vasopressin that also stimulate $G_s\alpha$ protein are not usually impaired (3), although ACTH resistance has been described before in PHP type 1 (4).

There are several variants of PHP, including type 1A (PHPIA), type 1B (PHP1B), type 1C (PHP1C), type 2 (PHP2) and pseudopseudohypoparathyroidism (PPHP). The phenotype of PHPIA, which is the most commonly found variant (5), and PHP1C include multiple hormone resistance and skeletal defects such as short stature, obesity, round face, subcutaneous ossifications and brachydactyly, collectively named as Albright's hereditary osteodystrophy (AHO) (6). PHP1B is pathogenetically linked to imprinting methylation defects at the *GNAS* locus resulting in lack of expression of the maternal allele almost exclusively in the renal tissue (7) and usually lack AHO, but may present with additional hormone dysfunctions, most frequently TSH resistance (8).

Pseudopseudohypoparathyroidism, on the other hand, is a clinical entity characterised by AHO phenotype without hormone resistance and is linked to *GNAS* mutations in the paternally inherited allele (7).

Hypercalcaemia has been sporadically described in patients with PHPIA and IB (9, 10, 11), but the exact pathogenetic mechanism and its relation to the future development of medullary thyroid carcinoma (MTC) remain unknown. We present two cases of PHP with distinct phenotypes that were referred to our outpatient

endocrine clinic for further investigation of their persistently high levels of serum calcitonin.

Case presentation

Case 1 was a 54-year-old male complaining of weakness, fatigue and periodic headache. His general practitioner asked for consultancy from an endocrinologist seeking for further investigation of his hypercalcaemia on the ground of multinodular goitre (calcitonin >100 pg/mL in repeated measurements). The physical examination revealed an obese person (BMI: 39.7) with short stature (height: 165 cm) (Table 1), round face, stocky appearance with notable facial puffiness and brachydactyly of hands and feet. There was no report of his physical appearance up to the day he visited our department. An epicranial subcutaneous ossification was removed in the frontoparietal area of the head 6 years before. At that time, he was found to have asymptomatic hypocalcaemia and started treatment with active vitamin D analogues (1.0 µg of 1a-OH vitamin D) and oral calcium carbonate 2 g/day, which he continued up to the day we examined the patient. Ten years before, he was diagnosed with chronic lymphocytic thyroiditis (Hashimoto's) and multinodular goitre and he was treated since then with 225 µg of levothyroxine. His blood pressure was normal (125/82 mmHg) and the pulse rate was 78/min. The tendon reflexes were normal. The X-rays of the hands revealed shortening of the metacarpals with epiphyseal widening, conical configuration of the phalangeal heads, osteopenic appearance, as well as stenosis of the phalangeal joint space and hardening of the joint surfaces.

His laboratory workup revealed hypocalcaemia and phosphate levels slightly above normal with elevated serum PTH and calcitonin levels (Table 2). Based on the laboratory results and his clinical appearance, we diagnosed PHPIA with AHO. To confirm our diagnosis we performed the Howard–Ellsworth test with s.c. administration of recombinant 1-34 N-terminal fragment of endogenous human parathyroid hormone (INN-teriparatide, Forsteo, Pharmaserve-Lilly, Inc). Administration of 20 µg of INN-teriparatide did not change urine cAMP and PO_4 levels analysed on samples voided every 30 min for 3 h post injection (Fig. 1). Urinary cAMP is measured using an ELISA (Cayman Chemicals), according to the manufacturer's instructions. The standard curve range for this assay is 0.078–10 pmol/mL, with a sensitivity (80% B/B₀) of 0.1 pmol/mL.

Case 2 was a 33-year-old male complaining of generalised muscular weakness, pain and tetany (twitches



Table 1 Clinical presentation of cases.

	Case 1	Case 2
Age	54	33
Body weight (kg)	108	78
Height (cm)	165	177
BMI	39.7	24.9
AHO	Present	Absent
Main symptoms	Weakness, fatigue	Weakness, tetany
Medical record	Epicranial subcutaneous ossification	Gilbert syndrome, bilateral inguinal hernia, mild scoliosis
Thyroid ultrasound	Multinodular goitre	Normal morphology
Family history of pseudohypoparathyroidism	Absent	Absent
Brown tumours	Absent	Absent
History of basic ganglia calcification/seizures	Absent	Absent

of the quadriceps) while lying down and was referred to us for his persistently high levels of calcitonin in the absence of thyroid pathology (Table 1). Laboratory workup revealed severe hypocalcaemia, hyperphosphataemia, high levels of serum PTH and calcitonin (Table 2). The

patient suffered from Gilbert syndrome, bilateral inguinal hernia and mild scoliosis, but his physical appearance was otherwise normal without signs of AHO. Administration of 20µg of INN-teriparatide also did not change urine cAMP and PO₄ levels (Fig. 1).

Table 2 Laboratory workup.

Parameters	Case 1	Case 2	Normal values
Blood glucose (mg/dL)	102	89	60–100
Serum creatinine (mg/dL)	1.0	0.8	0.8–1.4
Total cholesterol (mg/dL)	120	138	<200
HDL cholesterol (mg/dL)	25	34	>40
Triglycerides (mg/dL)	113	54	<150
LDL cholesterol (mg/dL)	75	109	<100
Hct (%)	43	48.4	42–52
WBC	7.500	4300	4000–10,000
BUN (mg/dL)	29		7–22
SGOT (U/L)	40	21	<40
SGPT (U/L)	48	23	<40
Uric acid (mg/dL)	7.5*	2.8	3.0–7.0
Serum calcium (mg/dL)	7.4*	6.2*	8.7–10.3
Serum phosphorus (mg/dL)	4.7*	5.9*	2.5–4.5
Alkaline phosphatase (U/L)	60	77	35–100
Serum Na ⁺ (mEq/L)	142	142	135–145
Serum K ⁺ (mEq/L)	4.1	4.0	3.5–5.0
Albumin (g/dL)	3.5	4.6	3.5–5.0
Urine exam	Normal		
Urine calcium (mg/24 h)	31.2*	42.90	100–300
Urine creatinine (mg/24 h)	1605	1204	500–2000
TSH (µU/mL)	3.4	2.470	0.4–5.0
Anti-TG ab	30.70*		
Anti-TPO ab	>1300*		
Serum calcitonin (pg/mL)	114*	92*	<13.8
PTH (pg/mL)	133*	442.60*	11.0–54.0
FSH (IU/L)	8.57	10.3	1–12
LH (IU/L)	3.84	8.0	1.5–9.3
Total testosterone (ng/dL)	210	669	193–740
Serum cortisol (morning-fast) (µg/dL)	5.54	11.50	5.0–25
Plasma ACTH (pg/mL)	31.4	42	6.0–76.0

*Indicate abnormal values.

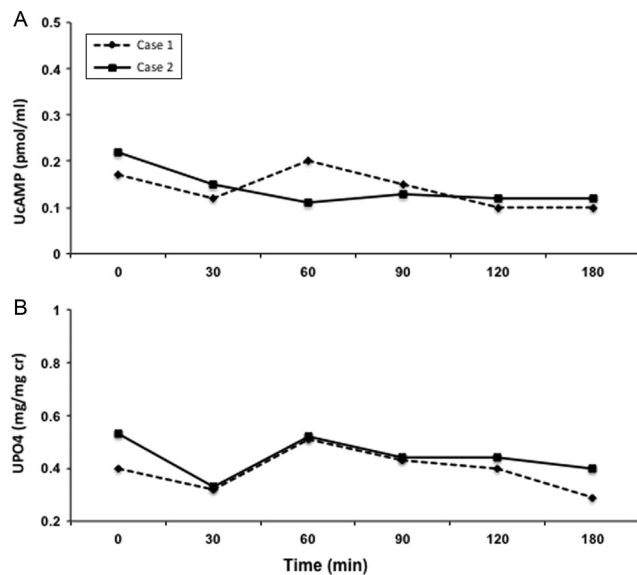


Figure 1
Results of the Howard Ellsworth test. (A) Urinary cAMP levels and (B) Urinary phosphate levels.

Investigation

We performed GNAS molecular analysis (methylation status and copy number analysis by MS-MLPA) in genomic DNA samples for both patients as previously described (12). Case 1 revealed a novel missense variant c.131T>G p.(Leu44Pro) affecting GNAS exon 1 which encodes for an altered protein and is likely responsible for the clinical phenotype presented by the patient.

Case 2 revealed the presence of the recurrent 3-kb deletion affecting the imprinting control region localised in the STX16 region associated with the LOM at the GNAS A/B differentially methylated region and consistent with the diagnosis of an autosomal dominant form of PHP1B. None of our patients had a family history of biochemical or phenotypic abnormalities consistent with the diagnosis of PHP, but we were not able to perform DNA testing for parents.

Evaluating further persistent hypercalcaemia in our patients, we performed a neck ultrasonography in both cases.

Case 1 had a thyroid gland with normal size and multiple spongiform nodules with smooth outline. The size of the larger nodule was 1.5×0.75cm with poor peripheral vasculature near isthmus. Few normal lymph nodes were also reported. Fine-needle aspiration was negative for malignant features in the larger nodule. Since it is currently unknown whether patients with PHP and hypercalcaemia are at increased risk of medullary

thyroid cancer and upon our patients' request, a total thyroidectomy was followed that showed no signs of malignancy.

Case 2 had a normal thyroid gland in terms of size and appearance, without evidence of nodules, and therefore, we did not recommend prophylactic thyroidectomy. In both of our patients, other pathological conditions known to induce hypercalcaemia such as chronic renal failure, neuroendocrine tumours originating from neural crest cells, hypergastrinaemia and use of proton pump inhibitors were excluded. In case 1, we also performed administration of pentagastrin 0.5 µg/kg before total thyroidectomy that increased further calcitonin levels despite hypocalcaemia (baseline: 114 pg/mL max at 2 min: 205 pg/mL).

There was no evidence of brown tumours in any of our patients.

Treatment

Our first patient (case 1) continued to receive active alfacalcidol 1.0 µg, oral calcium carbonate 2g/day and levothyroxine 225 µg.

Case 2 started treatment with alfacalcidol 2 µg and calcium carbonate (2g/day) with immediate alleviation of symptoms and progressive normalisation of biochemical parameters.

Outcome and follow-up

In the follow-up examination, both cases maintained serum calcium levels within the low normal reference range (case 1: 8.6 mg/dL, case 2: 8.4 mg/dL) without clinical symptomatology of hypocalcaemia. Calcitonin levels remained elevated in case 2 (102 pg/mL) and were undetectable 1 month post thyroidectomy in case 1.

Discussion

We report here two cases with PHP, PHP1A and PHP1B that developed hypercalcaemia during the course of their disease.

Hypercalcaemia is considered a sensitive marker for MTC, although it presents low specificity for this tumour. Several other physiologic and pathologic conditions have been associated with increased levels of calcitonin such as neuroendocrine tumours, renal insufficiency, papillary and follicular thyroid carcinomas, goitre, stress and pregnancy, and as in PHP, patients should



have a regular follow-up in order to avoid unnecessary thyroidectomy.

Hypercalcitoninaemia has been described before in a limited number of PHP1A cases, attributed to an associated resistance to calcitonin, as suggested by the generalised impairment of G α -mediated hormone signal transduction in this disease. We present a genetically confirmed case of PHP1A harbouring a novel mutation in GNAS gene that presented with high levels of calcitonin both at baseline and after pentagastrin stimulation. We also report high calcitonin levels in a patient with genetically confirmed PHP1B, linked with GNAS methylation defects without evidence of any other endocrinopathies and with normal thyroid ultrasound.

Since other causes of hypercalcitoninaemia such as MTC were ruled out, the exact mechanism of this manifestation and its clinical relevance with C cell dysfunction remain unanswered.

Despite the remarkable progress that has been done in the field of PTHR signalling, many of the molecular mechanisms underlying hormone resistance and imprinting defects in PHP remain incompletely understood. In future, detailed clinical and molecular characterisation will increase our knowledge about this complex gene and this unique form of the disorder.

Declaration of interest

The authors declare that there is no conflict of interest that could be perceived as prejudicing the impartiality of the research reported.

Funding

This research did not receive any specific grant from any funding agency in the public, commercial or not-for-profit sector.

Patient consent

Informed consent has been obtained from both of our patients for publication of the submitted article and accompanying images.

Author contribution statement

M P Y, E C, E A and G T collected all available information and wrote the first draft; F M A and G M performed the molecular analysis; G M, P Z and J G Y revised the final draft.

References

- Thiele S, Mantovani G, Barlier A, Boldrin V, Bordogna P, De Sanctis L, Elli FM, Freson K, Garin I, Grybek V, *et al.* From pseudohypoparathyroidism to inactivating PTH/PTHrP signalling disorder (iPPSD), a novel classification proposed by the EuroPHP network. *European Journal of Endocrinology* 2016 **175** P1–P17. (<https://doi.org/10.1530/EJE-16-0107>)
- Elli FM, Bordogna P, de Sanctis L, Giachero F, Verrua E, Segni M, Mazzanti L, Boldrin V, Toromanovic A, Spada A, *et al.* Screening of PRKAR1A and PDE4D in a large Italian series of patients clinically diagnosed with Albright hereditary osteodystrophy and/or pseudohypoparathyroidism. *Journal of Bone and Mineral Research* 2016 **31** 1215–1224. (<https://doi.org/10.1002/jbmr.2785>)
- Weinstein LS. The stimulatory G protein alpha-subunit gene: mutations and imprinting lead to complex phenotypes. *Journal of Clinical Endocrinology and Metabolism* 2001 **86** 4622–4626. (<https://doi.org/10.1210/jc.86.10.4622>)
- Chaubey SK & Sangla KS. A sporadic case of pseudohypoparathyroidism type 1 and idiopathic primary adrenal insufficiency associated with a novel mutation in the GNAS1 gene. *Endocrine Practices* 2014 **20** e202–e206. (<https://doi.org/10.4158/EP14020.CR>)
- Mantovani G, Linglart A, Garin I, Silve C, Elli FM & de Nanclares GP. Clinical utility gene card for: pseudohypoparathyroidism. *European Journal of Human Genetics* 2013 **21**. (<https://doi.org/10.1038/ejhg.2012.211>)
- Mantovani G, de Sanctis L, Barbieri AM, Elli FM, Bollati V, Vaira V, Labarile P, Bondioni S, Peverelli E, Lania AG, *et al.* Pseudohypoparathyroidism and GNAS epigenetic defects: clinical evaluation of Albright hereditary osteodystrophy and molecular analysis in 40 patients. *Journal of Clinical Endocrinology and Metabolism* 2010 **95** 651–658. (<https://doi.org/10.1210/jc.2009-0176>)
- Mantovani G & Spada A. Mutations in the Gs alpha gene causing hormone resistance. *Best Practice and Research: Clinical Endocrinology and Metabolism* 2006 **20** 501–513. (<https://doi.org/10.1016/j.beem.2006.09.001>)
- Mantovani G, Bondioni S, Linglart A, Maghnie M, Cisternino M, Corbetta S, Lania AG, Beck-Peccoz P & Spada A. Genetic analysis and evaluation of resistance to thyrotropin and growth hormone-releasing hormone in pseudohypoparathyroidism type 1b. *Journal of Clinical Endocrinology and Metabolism* 2007 **92** 3738–3742. (<https://doi.org/10.1210/jc.2007-0869>)
- Bastepe M, Lane AH & Juppner H. Paternal uniparental isodisomy of chromosome 20q – and the resulting changes in GNAS1 methylation – as a plausible cause of pseudohypoparathyroidism. *American Journal of Human Genetics* 2001 **68** 1283–1289. (<https://doi.org/10.1086/320117>)
- Zwermann O, Piepkorn B, Engelbach M, Beyer J & Kann P. Abnormal pentagastrin response in a patient with pseudohypoparathyroidism. *Experimental and Clinical Endocrinology and Diabetes* 2002 **110** 86–91. (<https://doi.org/10.1055/s-2002-23492>)
- Mantovani G, Bastepe M, Monk D, de Sanctis L, Thiele S, Usardi A, Ahmed SF, Bufo R, Choplin T, De Filippo G, *et al.* Diagnosis and management of pseudohypoparathyroidism and related disorders: first international Consensus Statement. *Nature Reviews Endocrinology* 2018 **14** 476–500. (<https://doi.org/10.1038/s41574-018-0042-0>)
- Elli FM, deSanctis L, Ceoloni B, Barbieri AM, Bordogna P, Beck-Peccoz P, Spada A & Mantovani G. Pseudohypoparathyroidism type 1a and pseudo-pseudohypoparathyroidism: the growing spectrum of GNAS inactivating mutations. *Human Mutation* 2013 **34** 411–416. (<https://doi.org/10.1002/humu.22265>)

Received in final form 20 December 2018

Accepted 9 January 2019