



Title	Portable negative-pressure wound therapy for pyoderma gangrenosum : Report of two cases
Author(s)	Yamaguchi, Yasuyuki; Yanagi, Teruki; Sato, Kazumasa; Yoshimoto, Norihiro; Hirata, Yu; Ujiie, Inkin; Nishimura, Machiko; Natsuga, Ken; Shiiya, Chihiro; Tsukinaga, Ichiro; Shimizu, Hiroshi
Citation	Journal of dermatology, 45(4), 483-486 <a href="https://doi.org/10.1111/1346-8138.14180">https://doi.org/10.1111/1346-8138.14180</a>
Issue Date	2018-04
Doc URL	<a href="http://hdl.handle.net/2115/73414">http://hdl.handle.net/2115/73414</a>
Rights	This is the peer reviewed version of the following article: Yamaguchi, Y., Yanagi, T., Sato, K., Yoshimoto, N., Hirata, Y., Ujiie, I., Nishimura, M., Natsuga, K., Shiiya, C., Tsukinaga, I. and Shimizu, H. (2018), Portable negative-pressure wound therapy for pyoderma gangrenosum: Report of two cases. J Dermatol, 45: 483-486., which has been published in final form at <a href="https://doi.org/10.1111/1346-8138.14180">https://doi.org/10.1111/1346-8138.14180</a> . This article may be used for non-commercial purposes in accordance with Wiley Terms and Conditions for Use of Self-Archived Versions.
Type	article (author version)
Additional Information	There are other files related to this item in HUSCAP. Check the above URL.
File Information	JDermatol45_483.pdf



[Instructions for use](#)

**Portable negative-pressure wound therapy for pyoderma gangrenosum: Report of two cases**

**Word count:** 1209 words, 2 figures, 1 table, 15 references, 1 supplemental video

**Authors:**

Yasuyuki YAMAGUCHI,<sup>1</sup> Teruki YANAGI,<sup>1</sup> Kazumasa SATO,<sup>1</sup> Norihiro YOSHIMOTO,<sup>1</sup> Yu HIRATA,<sup>1</sup> Inkin UJIIE,<sup>1</sup> Machiko NISHIMURA,<sup>1</sup> Ken NATSUGA,<sup>1</sup> Chihiro SHIYA,<sup>2</sup> Ichiro TSUKINAGA,<sup>2</sup> Hiroshi SHIMIZU<sup>1</sup>

<sup>1</sup>*Department of Dermatology, Hokkaido University Graduate School of Medicine, Sapporo, Japan*

<sup>2</sup>*Department of Dermatology, KKR Sapporo Medical Center, Sapporo, Japan*

**Correspondence:** Teruki Yanagi, M.D., Ph. D., Department of Dermatology, Hokkaido University Graduate School of Medicine, North 15 West 7, Kita-ku, Sapporo 060-8638, Japan. E-mail: yanagi@med.hokudai.ac.jp  
Phone: +81-11-716-7087, Fax: +81-11-706-7820

**Short running title:** Portable NPWT for PG

## **ABSTRACT**

Pyoderma gangrenosum is a chronic non-infectious neutrophilic dermatosis that causes undermining ulcers. Topical therapies for the deep ulcers of pyoderma gangrenosum have not been established. To investigate whether negative-pressure wound therapy is effective for a pyoderma gangrenosum ulcer, we used the PICO single use negative-pressure wound therapy system (Smith & Nephew plc, London) for two pyoderma gangrenosum patients. In these cases, the ulcers decreased in size and necrolytic tissue was removed notably. Moreover, there were no secondary infections nor was there Koebner phenomena. Our cases suggest that portable negative-pressure wound therapy can be a treatment option for deep, intractable ulcers caused by pyoderma gangrenosum. Since portable negative-pressure wound therapy devices afford increased mobility to patients, they can give the patient a better quality of life than standard negative-pressure wound therapy systems do.

**Key words:** negative-pressure wound therapy, PICO single use negative-pressure wound therapy system, portable negative-pressure wound therapy device, pyoderma gangrenosum, ulcer

## INTRODUCTION

Pyoderma gangrenosum (PG) is a rare non-infectious neutrophilic dermatosis that is characterized by painful, necrolytic ulceration with an undermined border.<sup>1</sup> PG is often refractory and its management is complex. The first-line therapy for severe PG is systemic prednisolone (PSL) or cyclosporine (CyA).<sup>2</sup> Even though the neutrophilic inflammation is controlled, the deep ulcers caused by PG are difficult to treat. The most common local interventions for PG ulcer are topical corticosteroids and calcineurin inhibitors,<sup>3</sup> and some reports show various topical agents to be effective: platelet-derived growth factor,<sup>4</sup> sodium cromoglycate,<sup>5</sup> nicotine<sup>6</sup> and benzoyl peroxide.<sup>7</sup> After adequate immunosuppression, surgical intervention is optional.<sup>8</sup>

Negative-pressure wound therapy (NPWT) is applied to various open wounds, and it promotes epithelialization.<sup>9</sup> To our knowledge, some PG cases have been treated with non-portable NPWT;<sup>8, 10</sup> however, information concerning the efficacy of portable NPWT has not been published. Herein we report two cases of recalcitrant PG that were improved with portable NPWT.

## CASE REPORT

Case #1.

A 48-year-old Japanese man with a 7-month history of a painful ulcer on the left lower

leg was referred to our hospital. Physical examination revealed a geographic,

erythematous-violaceous ulcer of 10 cm in size with yellow necrolytic tissue and an

undermined border surrounded by reddish erythema (Fig. 1a). The histopathology

showed patchy neutrophilic infiltrates in the dermis without features of vasculitis (Fig.

1b, c). Periodic acid–Schiff stain, Grocott stain and Ziehl–Neelsen stain were negative.

He was otherwise healthy except for a 2-year history of rheumatoid arthritis. Laboratory

tests showed high levels of inflammatory markers, such as a white blood cell count of

$9.7 \times 10^4/\mu\text{L}$  (normal:  $3.5\text{--}8.0 \times 10^4/\mu\text{L}$ ) and C-reactive protein of 3.90 mg/dL (normal:

$<0.30$  mg/dL). Anti-SS-A/B antibody, anti-Sm antibody, anti-dsDNA IgG antibody,

anti- $\beta 2$  glycoprotein I antibody, lupus anticoagulant, cryoglobulin, PR3-ANCA and

MPO-ANCA were all negative. From these findings, the diagnosis of PG was made.

The patient was initially treated with oral PSL 60 mg (1 mg/kg) and CyA 300 mg (5

mg/kg) daily for 3 weeks. After these treatments, the lesions improved gradually and the

doses of oral PSL and CyA were tapered. When we tapered oral PSL to 5 mg and CyA to 200 mg daily, the inflammatory markers were within normal ranges; however, the ulcer did not become noticeably smaller (Fig. 1b). Thus, we applied the PICO single use negative-pressure wound therapy system (Smith & Nephew plc, London) as a portable NPWT device to the ulcer. We used 15 x 15-cm pads, and the pressure was set at -80 mmHg. Over the course of 4 weeks, the ulcer gradually shrank and necrolytic tissue was notably removed (Fig. 1c). The condition of PG was controlled well, and we were able to cease the PSL.

#### Case #2.

A 51-year-old Japanese woman with a PG ulcer on the right lower leg was referred to our hospital. Physical examination revealed an oval ulcer of 15 cm in size that was completely covered with yellow necrolytic tissue (Fig. 2a). She was also diagnosed with ulcerative colitis, which was inactive. Laboratory tests were within normal ranges. The patient was initially treated with oral PSL at 50 mg (1 mg/kg) daily for 4 weeks. The ulcer improved gradually and the oral PSL was tapered by 10 mg every 2 weeks. After 1

week of oral PSL at 40 mg daily, the yellow necrolytic tissue was partially removed; however, the size of the ulcer had not changed (Fig. 2b). We applied the PICO single use negative-pressure wound therapy system to prompt epithelialization. We used 20 x 20 cm pads, and the pressure was set at -80 mmHg. Over the course of 3 weeks, the ulcer shrank remarkably (Fig. 2c). The condition of PG was controlled well, and we were able to cease the PSL. At 8 weeks after the end of NPWT, the ulcer was completely epithelialized (Fig. 2d).

## **DISCUSSION**

PG is a chronic disease that takes several months to control. For severe PG, systemic PSL and CyA are preferred, based on findings from a randomized controlled trial (RCT).<sup>2</sup> Another RCT showed the anti-TNF-alpha antibody infliximab to be effective against PG.<sup>11</sup> Surgical intervention should be undertaken only after careful consideration, since Koebner phenomenon can cause postsurgical PG without adequate immunosuppression.<sup>8</sup> Recently, a comprehensive review showed NPWT and

split-thickness skin graft to be recommended under adequate immunosuppressive therapy.<sup>8</sup>

NPWT has developed since the use of vacuum-assisted closures in the early 1990's.<sup>12</sup> The healing mechanism of NPWT is classified as follows: wound shrinkage or macrodeformation, microdeformation at the foam-wound surface interface, fluid removal and stabilization of the wound environment.<sup>9</sup> Macrodeformation refers to a kind of wound shrinkage, and microdeformation refers to the process whereby undulation is induced in the wound surface by the negative pressure of NPWT suction.<sup>9</sup> Fluid removal reduces compression of the microvasculature and increases blood flow.<sup>9</sup> NPWT removes toxins, bacteria and exudate together with fluid, which contributes to the stabilization of the wound environment.<sup>9</sup> Portable NPWT functions in the same manner as conventional NPWT.<sup>13</sup> Moreover, portable NPWT devices enable homecare NPWT and afford increased mobility to patients, which gives the patients better quality of life than standard NPWT systems do.<sup>14</sup>

In most of the previous reports on PG and NPWT, the NPWT was used to fix grafts after skin grafting.<sup>8</sup> Recently, five cases were treated with only NPWT under adequate



immunosuppression (Table 1).<sup>10, 15</sup> In these cases, non-portable NPWT devices including the VAC device (Kinetic Concepts Inc., San Antonio) and RENASYS (VISTA Blue Sky Medical/Smith & Nephew, London) were used. Our present cases show that a portable NPWT device can be efficacious against PG ulcers, just as non-portable NPWT devices have been. We used the PICO single use negative-pressure wound therapy system (Smith & Nephew plc, London) for the present cases. The pump, which is 85 x 85 x 25 mm in size and 120 g in weight, creates continuous negative pressure for seven days (Supplemental Video 1). Thus, we changed the pump every seven days. We also replaced the pads every three to five days. The negative pressure was set at -80 mmHg in both cases.

Considering that trauma provokes Koebner phenomenon in PG patients, NPWT stimulation can trigger new lesions. In our cases, we applied portable NPWT devices after the inflammatory stage had subsided with treatment of systemic PSL and/or CyA. Our cases suggest that portable NPWT can be a treatment option for PG under adequate immunosuppression.

**ACKNOWLEDGEMENTS:** None to declare.

**CONFLICTS OF INTEREST:** None to declare.

## REFERENCES

1. Binus AM, Qureshi AA, Li VW, Winterfield LS. Pyoderma gangrenosum: a retrospective review of patient characteristics, comorbidities and therapy in 103 patients. *Br J Dermatol* 2011; **165**: 1244-1250.
2. Ormerod AD, Thomas KS, Craig FE *et al.* Comparison of the two most commonly used treatments for pyoderma gangrenosum: results of the STOP GAP randomised controlled trial. *BMJ* 2015; **350**: h2958.
3. Thomas KS, Ormerod AD, Craig FE *et al.* Clinical outcomes and response of patients applying topical therapy for pyoderma gangrenosum: A prospective cohort study. *J Am Acad Dermatol* 2016; **75**: 940-949.
4. Braun-Falco M, Stock K, Ring J, Hein R. Topical platelet-derived growth factor accelerates healing of myelodysplastic syndrome-associated pyoderma gangrenosum. *Br J Dermatol* 2002; **147**: 829-831.
5. Tamir A, Landau M, Brenner S. Topical treatment with 1% sodium cromoglycate in pyoderma gangrenosum. *Dermatology* 1996; **192**: 252-254.

6. Patel GK, Rhodes JR, Evans B, Holt PJ. Successful treatment of pyoderma gangrenosum with topical 0.5% nicotine cream. *J Dermatolog Treat* 2004; **15**: 122-125.
7. Vereecken P, Wautrecht JC, De Dobbeleer G, Heenen M. A case of pyoderma gangrenosum stabilized with lymecycline, topical benzoyl peroxide and treated by autograft. *Dermatology* 1997; **195**: 50-51.
8. Pichler M, Thuile T, Gatscher B *et al.* Systematic review of surgical treatment of pyoderma gangrenosum with negative pressure wound therapy or skin grafting. *J Eur Acad Dermatol Venereol* 2017; **31**: e61-e67.
9. Huang C, Leavitt T, Bayer LR, Orgill DP. Effect of negative pressure wound therapy on wound healing. *Curr Probl Surg* 2014; **51**: 301-331.
10. Ghersi MM, Ricotti C, Nousari CH, Newman MI. Negative pressure dressing in the management of pyoderma gangrenosum ulcer. *Arch Dermatol* 2007; **143**: 1249-1251.

11. Brooklyn TN, Dunnill MG, Shetty A *et al.* Infliximab for the treatment of pyoderma gangrenosum: a randomised, double blind, placebo controlled trial. *Gut* 2006; **55**: 505-509.
12. Argenta LC, Morykwas MJ. Vacuum-assisted closure: a new method for wound control and treatment: clinical experience. *Ann Plast Surg* 1997; **38**: 563-576.
13. Malmsjö M, Huddleston E, Martin R. Biological effects of a disposable, canisterless negative pressure wound therapy system. *Eplasty* 2014; **14**: e15.
14. Brandon T. A portable, disposable system for negative-pressure wound therapy. *Br J Nurs* 2015; **24**: 98.
15. Fracalvieri M, Fierro MT, Salomone M *et al.* Gauze-based negative pressure wound therapy: a valid method to manage pyoderma gangrenosum. *Int Wound J* 2014; **11**: 164-168.

## **FIGURE LEGENDS**

### **Figure 1.** Clinical and histopathological presentations of case #1

(a) The clinical presentation at the first visit shows a geographic, erythematous-violaceous ulcer of 10 cm in size with yellow necrolytic tissue and undermined border surrounded by reddish erythema on the left lower leg. (a, inset) The histopathology of the lesion shows patchy neutrophilic infiltrates in the dermis without features of vasculitis (hematoxylin-eosin, original magnification (x200)). (b) The clinical presentation on the first day of NPWT. The ulcer has not shrunk; it is the same size as at the first visit. (c) Over the course of 4 weeks of NPWT, the ulcer gradually shrank and necrolytic tissue was notably removed.

### **Figure 2.** Clinical presentation of case #2

(a) The clinical presentation at the first visit shows an oval ulcer of 15 cm in size that is completely covered with yellow necrolytic tissue. (b) The clinical presentation at the first day of NPWT shows that yellow necrolytic tissue has been partially removed but that the ulcer size is unchanged. (c) After 3 weeks of NPWT, yellow necrolytic tissue

has been removed and the ulcer has shrunk remarkably. (d) At 8 weeks after the end of NPWT, the ulcer has completely epithelialized.

## **SUPPLEMENTAL INFORMATION LEGEND**

**Supplemental Video 1.** How to use the PICO Single Use Negative Pressure Wound Therapy System.

After the ulcer is cleansed, we apply a pad that is large enough to cover it. Then we connect the dressing to the portable pump by twisting the tubing connectors, and push an orange button to start. We confirm that the green light at the top of the pump is lit, which indicates that the pump is functioning properly.

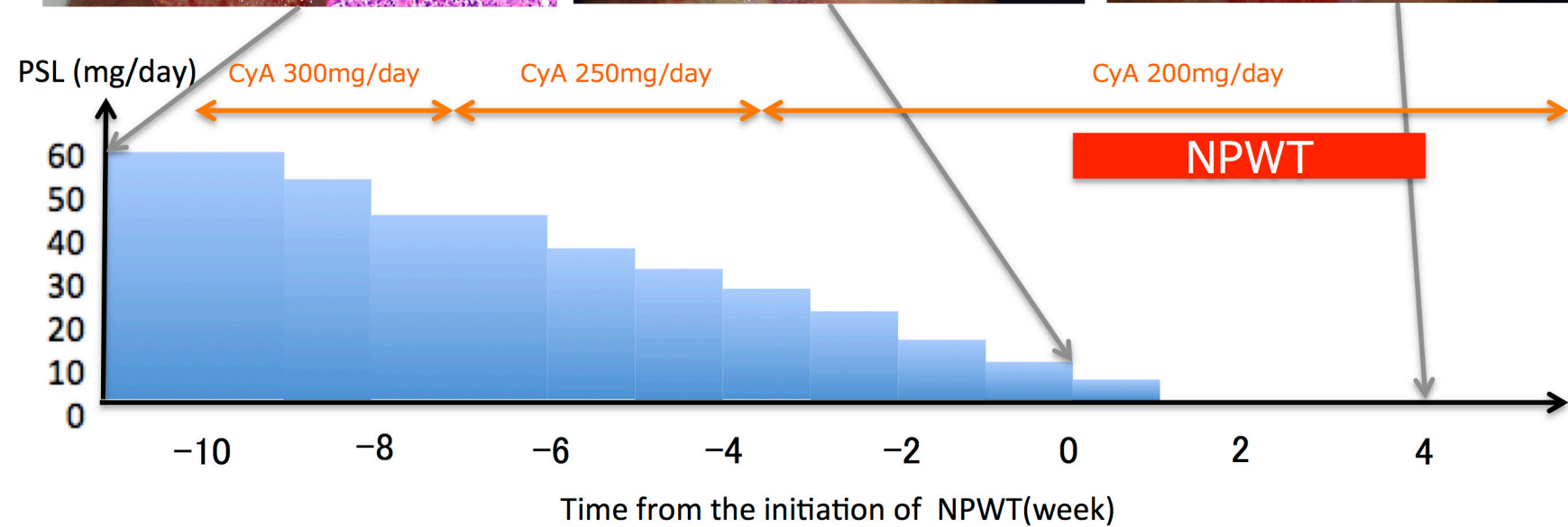
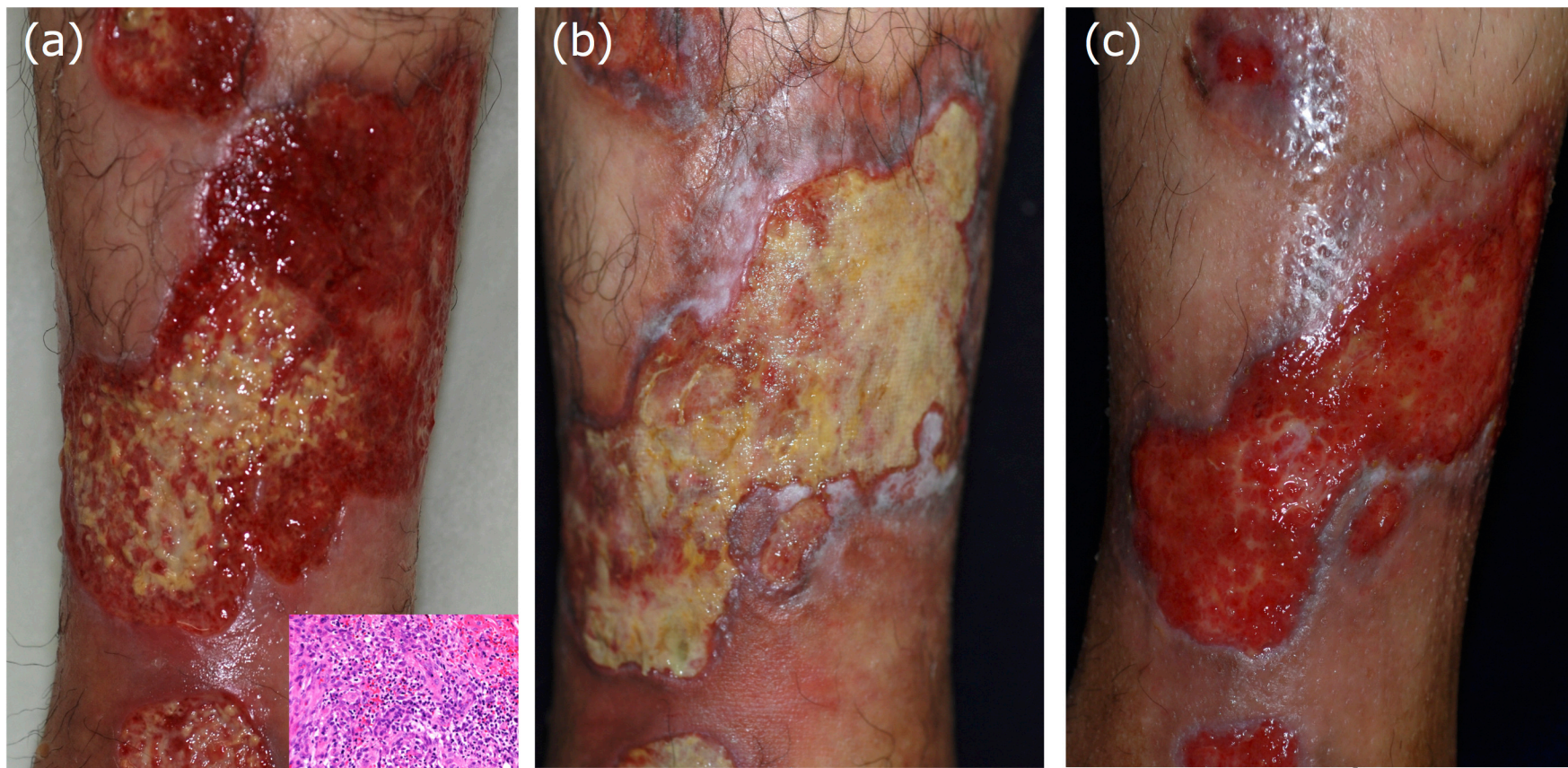


Fig. 1



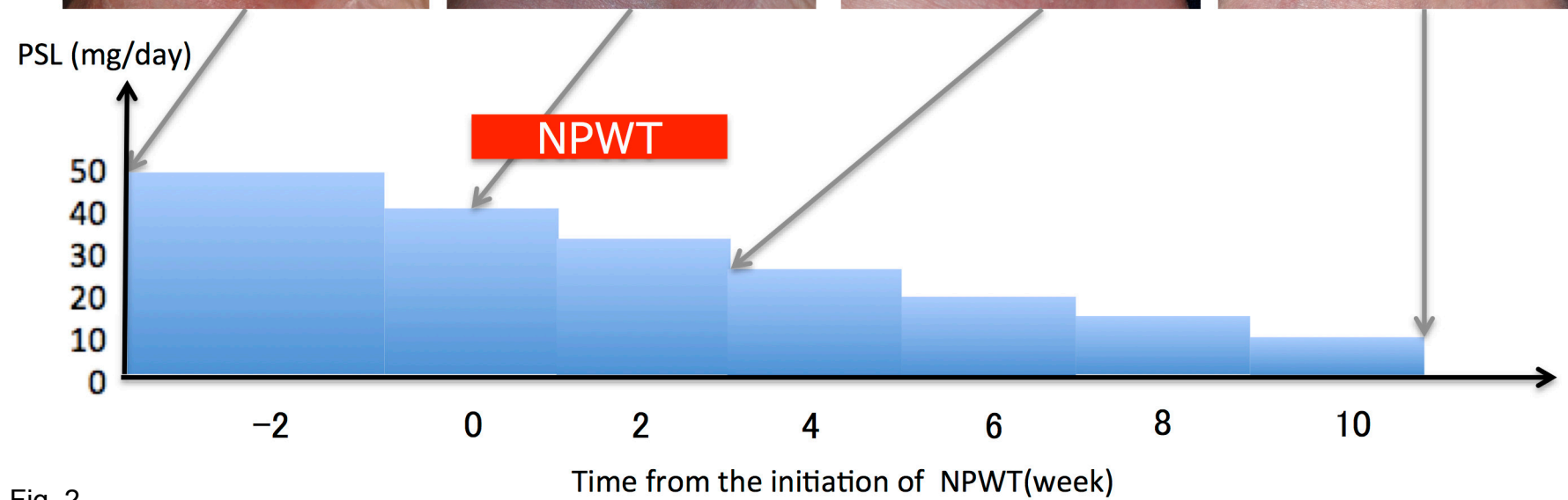
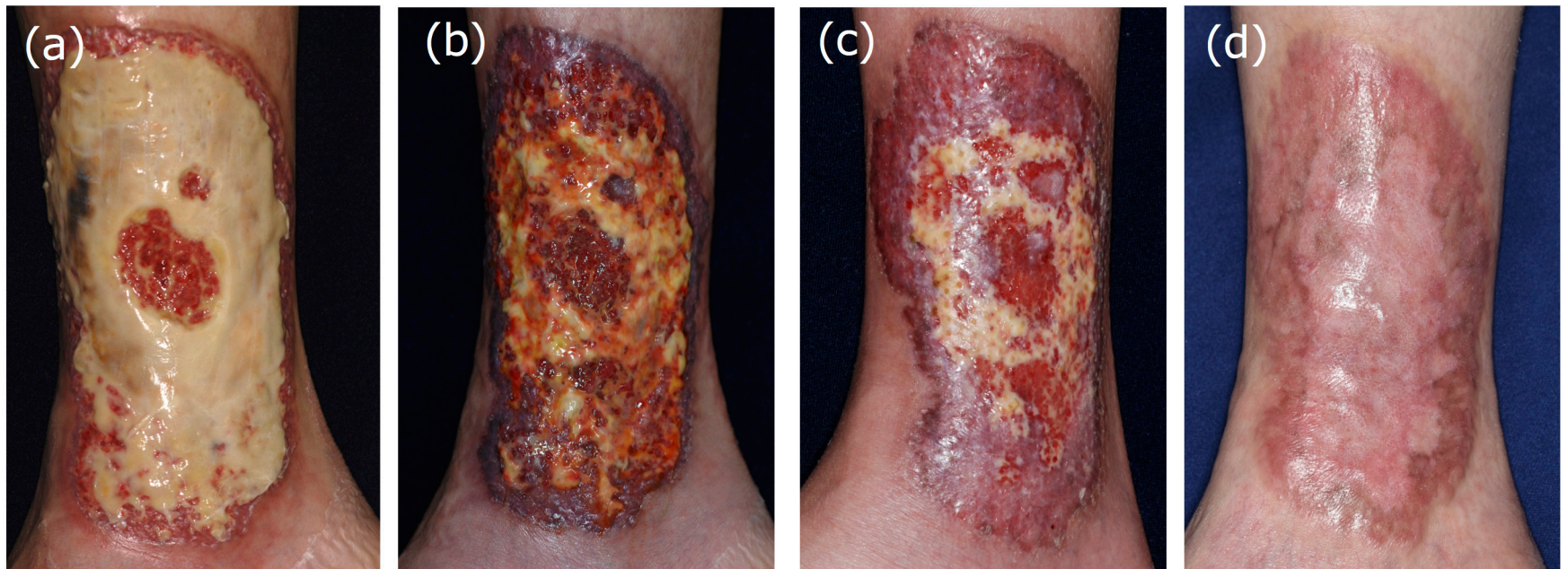

Fig. 2

## TABLES

**Table 1.** Clinical features of patients who were treated with NPWT devices

Case no.	Age/ sex	Distribution	Complication	NPWT	Systemic treatment	Outcome	Reference
1	57/F	Breast	ND	VAC	None	Epithelialization after 6 weeks	Gheri MM, et al. (10)
2	53/M	Lower leg	IBD	RENASYS	CS, CyA, DDS	Reduction of the wound and pain	Fraccalvieri M, et al. (15)
3	59/F	Breast	Breast cancer	RENASYS	CS, IVIg, CyA	Epithelialization after 12 months	Fraccalvieri M, et al. (15)
4	72/F	Lower leg	None	RENASYS	CS	Granulation formation, pain reduction	Fraccalvieri M, et al. (15)
55	45/F	Lower leg	UC, policondritis, vasculitis, polyneuritis, scleritis	RENASYS	MTX, CS, CyA, anti-TNF $\alpha$ , IVCY	Reduction of the wound and pain	Fraccalvieri M, et al. (15)
6 (Present case #1)	48/M	Lower leg	RA	PICO	CS, CyA	Reduction of the wound and pain	Present case
7 (Present case #2)	51/F	Lower leg	UC	PICO	CS	Epithelialization after 8 weeks	Present case

CS: Corticosteroid, CyA: cyclosporine, DDS: dapsone, F: female, IBD: inflammatory

bowel disease, IVCY: intravenous cyclosporine, IVIg: intravenous immunoglobulin, M:

male, MTX: methotrexate, ND: not described, RA: rheumatoid arthritis, UC: ulcerative

colitis