

# Educating renal nurses — inferior vena caval ultrasound for intravascular volume assessment

Ulrich Steinwandel, Nick Gibson, Mandy Towell-Barnard, James Rippey and Johan Rosman

Submitted: 10 January 2018, Accepted: 3 March 2018

## Abstract

**Aim:** Volume status of haemodialysis patients can be evaluated by trained doctors using ultrasound (US) of the inferior vena cava (IVC). To date, renal nurses have not been taught this skill. As part of a larger study exploring the use of US by renal nurses we developed an educational program to ensure that renal nurses received adequate US training to attain competence in IVC ultrasound (IVC-US).

**Methods:** The educational program was divided into four parts. Initially a clinical US expert delivered the necessary theoretical and then practical components of the program. After this the nurse undertook a period of self-directed US practice (100 scans). During this period three formative reviews of the recorded scan clips with feedback occurred. Specific feedback covered US technique, image optimisation and acquisition and image interpretation. Finally, as a summative assessment the nurse performed and interpreted 60 scans on 10 dialysis patients. These scans were independently assessed for quality and the nurse interpretations reviewed for accuracy, prior to deeming the candidate competent to independently perform IVC-US.

**Findings:** Ultrasound education involves knowledge and skill acquisition. Initial theoretical and practical education must be translated into competence through task repetition and targeted feedback. A staged educational program that involves these components is likely to be successful. The rate for US skill acquisition varies and a summative assessment ensuring competence prior to independent scanning is important.

**Conclusions:** This four-step program demonstrated that it is feasible to educate a renal nurse in IVC-US for intravascular volume assessment.

## Keywords

Nursing education, volume assessment, renal nurses, inferior vena cava ultrasound, nursing competency.

**Ulrich Steinwandel** MSc Nephrol, PhD (c)

Nurse for Nephrology, School of Nursing, Edith Cowan University, Joondalup, WA, Australia

Nursing Research Educator, Education Centre, Royal Perth Hospital, Perth, WA, Australia

\* **Nick Gibson**

Dr, Senior Lecturer, School of Nursing, Edith Cowan University, Joondalup, WA, Australia

\* **Mandy Towell-Barnard**

Post-Doctoral Research Fellow, School of Nursing, Edith Cowan University, Joondalup, WA, Australia

\* **James Rippey**

Professor, Emergency Physician, Expert Sonologist, Sir Charles Gairdner Hospital, Perth, WA, Australia

\* **Johan Rosman**

Professor of Medicine, School of Medicine, Faculty of Health Sciences, Curtin University, Perth, WA, Australia

**Correspondence to:** Ulrich Steinwandel, School of Nursing and Midwifery, Edith Cowan University

270 Joondalup Drive, Joondalup, WA 6027, Australia

Email [ulrich.steinwandel@health.wa.gov.au](mailto:ulrich.steinwandel@health.wa.gov.au)

\* Co-authors

## Introduction

Doctors successfully use ultrasound (US) measurements of the inferior vena cava (IVC) to determine intravascular volume status of haemodialysis (HD) patients (Muniz Pazeli *et al.*, 2014). The use of IVC ultrasound (IVC-US) is potentially beneficial for the prevention of intradialytic hypotension (IDH) (Brennan *et al.*, 2006), described as one of the most common adverse events during HD treatment with subsequent detrimental effects on the patient's health (Chao *et al.*, 2015). These detrimental effects can range from cramps, nausea and vomiting through to severe clinical events like loss of consciousness, myocardial infarct and stroke (McIntyre & Goldsmith, 2015; Chao *et al.*, 2015). Furthermore, IDH has the potential to occur completely undetected, when a patient does not display any clinical symptoms and the systolic blood pressure is lower than 100 mmHg (Bradshaw & Bennett, 2015). This asymptomatic IDH has the same potential damaging impact on a variety of organs as symptomatic IDH (Davenport, 2014).

Renal nurses are more frequently caring for an older, more frail and complex patient population (Tonelli & Riella, 2014). This patient group has been identified as being at high risk for IDH (Stefansson *et al.*, 2014). The application of IVC-US at the point of care could be a useful adjunct to the regular objective nursing assessment prior and during HD sessions which usually only consists of blood pressure and weight measurements (Steinwandel *et al.*, 2017b). Emergency department nurses without any prior experience in US, were able to measure the IVC diameter with US after a structured educational training course (De Lorenzo & Holbrook-Emmons, 2014). Obtaining knowledge of the patient's fluid status through a non-invasive device was deemed to be favourable for the patient outcomes by these authors. Nurses in a heart failure clinic, also with no prior experience in the use of US, have been successfully taught how to use IVC-US in combination with lung US and to allow for early detection of fluid imbalance in patients (Gustafsson *et al.*, 2015). A successful learning process for HD nurses using bedside US for cannulation prior to HD treatments has been also reported by Marticorena *et al.* (2015). These authors have posited that mainly through a constant repetitive process of applying the same practical technique, basic US competency is easily achievable by novices.

These previous studies demonstrate that with an adequate theoretical and practical education program nurses can acquire the necessary knowledge and skill to perform an US on focussed areas, giving the nurse more objective information to treat the patient. Routinely renal nurses assess, plan and manage a patient during HD and are expected to be able to identify and treat any IDH and to prevent the patient from

further deterioration. Pre-emptive identification of imminent IDH and subsequent intervention has been described as an essential element to improve long-term outcomes for HD patients (Bradshaw & Bennett, 2015). So, a measure like IVC-US in the skill set of renal nurses would allow them to function independently and equip them with expertise to effectively monitor the patient on HD, allowing for early identification of imminent IDH and subsequent prevention. Currently there is no formal training program for renal nurses to master the art of performing IVC-US successfully on HD patients. Therefore, there is an unmet need to develop an educational program to learn the technique of IVC-US and perform correct volume assessments.

## Creation of a structured program to upskill a renal nurse to perform IVC-US in a pilot study

Our aim was to develop and implement a structured educational program for a pilot study to enable a renal nurse to develop proficiency in the use of the IVC-US and classify the intravascular volume status of 10 renal patients requiring HD. The structured educational program was based on the theoretical framework by Benner (1984), which focusses on the dynamic learning process of a nurse gaining clinical confidence in a specific skill. In this program, the renal nurse was guided by an expert clinician sonographer, a sonologist, through the four stages of learning IVC-US skills, until finally competency was achieved (Figure 1). A sonologist is a medical doctor who performs a US scan and uses his cognitive and radiographic skills to make the diagnostic determination at the time of bedside application of focussed US (Stawicki & Bahner, 2015).

## Module 1

The first stage of the program consisted of an initial didactic session of four hours with the sonologist. The renal nurse needed to understand the purpose of the investigation and its potential benefit for an improved health outcome for the patient. Therefore, the physiological details and dynamic changes of the IVC throughout the respiratory cycle were explained in detail, including the abnormalities for hyper- or hypovolemic patients and its relationship with central venous pressure. Additionally, the nurse needed to comprehend the anatomical landmarks of the intended area of investigation, using the liver as an acoustic window, positioning of the probe, fanning into the right direction, identifying the IVC and distinguishing the IVC from the aorta. The content of this session also covered the basics of US principles, the technical handling of the US device and knowledge of potential pitfalls. This included principles of machine settings for depth, device maintenance, saving of recordings (videos or cine-loop) for further assessment and documentation. We preferred cine-

loops (CL) over static images, as CL hold the advantage of depicting the dynamics of variance of the IVC over time during the respiratory cycle. This approach simplified the post-hoc analysis process for quality and adequacy of the findings.

## Module 2

This stage of the program consisted of the practical demonstration of IVC-US to the renal nurse by the sonologist using an US device with a curvilinear (abdominal) probe (2–5 Mhz) on a patient in the clinical practice setting. During this stage, the nurse only observed the sonologist whilst the scan was performed. Learning goals during this stage were to inform the patient about the planned investigation, including obtaining consent and detailed explanation of the intended examination. Also, through full observation of the expert performing the task, the nurse was able to comprehend practical details of the examination and its desired outcome. Details of the IVC examination in this module are described as follows:

### The procedure: IVC-US

Placing the patient in a supine position allows for easy access to his upper abdomen with a slightly elevated upper body. Initially, the expert aimed to locate the IVC in the upper abdomen. After performing hand hygiene, the US probe was positioned on the upper abdomen just below the xiphoid process, perpendicular to the chest, in transverse orientation. This view, with the probe indicator located on the right reveals a cardiac view, for the initial orientation. Next, the probe was rotated 90°, so the indicator was cephalic, visualising the longitudinal view of the IVC. In this position, the probe is pointing slightly away from the heart, fanning towards the patient's right. Using the liver as an acoustic window, the probe aims to present the IVC clearly, identifying the posterior and anterior wall of the IVC in parallel appearance and focussing on an area 2 cm distal to the hepatic vein junction. Aiming the probe slightly higher is then likely to help to detect the

junction of the right atrium with the IVC exemplifying the IVC, distinct from the aorta. After visualising the junction of the right atrium with the IVC, the probe should preferably be kept in this position to follow its collapse throughout the respiratory cycle.

At this point it is essential to distinguish between the aorta and IVC. While the aorta has generally thicker vessel walls, it shows a straighter shape and does not collapse (it pulsates rather outwards). The IVC appears to have more curvature, has thinner vessel walls and most importantly, collapses during inspiration. The significant differences between the IVC and aorta are seen in Table 1.

	IVC	Aorta
Vessel wall	Thinner	Thicker (hyperechoic)
Pulsates outwards	No	Yes
Shape	Rather slightly curved	Rather straight
Enters right atrium (RA)	Yes	No
Hepatic vein visible	Yes	No
Collapses during inspiration	Yes	No
Location	Rather to the patient's right side	Rather to the patient's left side

Table 1: Anatomical differences between the IVC and aorta

During the regular breathing pattern of the patient, the upper abdomen rises and falls slightly and the visualisation of the IVC can potentially be doubtful. During this dynamic process, the observer could possibly lose track of the previously visualised IVC. It is, therefore, essential that the probe needs to follow the movements of the diaphragm during in- and expiration, while keeping the area of interest in focus. This task needs good eye–hand coordination, with the hand holding the US probe and the wrist resting partly on the abdomen to stabilise the probe, and the examiner needs to observe closely the displayed image. This manoeuvre is probably the most difficult part of the examination as the IVC needs to be constantly visible to determine its collapsibility. When the IVC is clearly

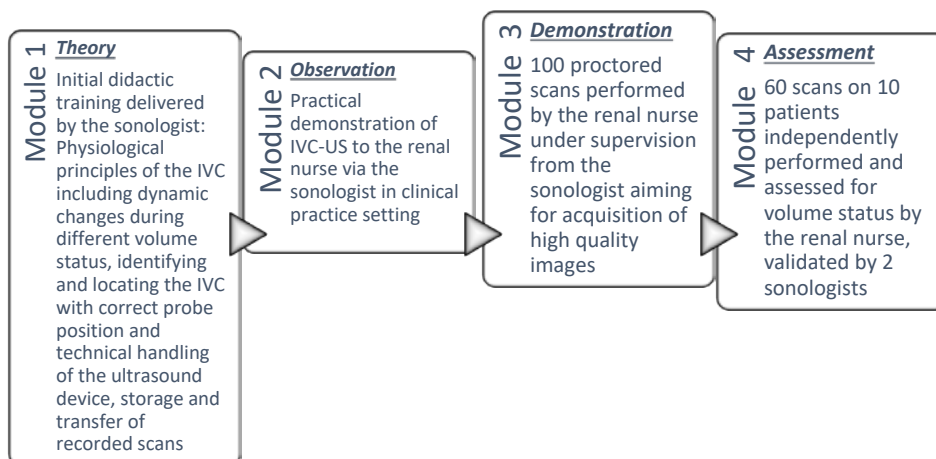


Figure 1: Modules outlining the four stages of learning IVC-US skills

identifiable, a continuous record of at least six seconds must occur, consisting of at least one full cycle of in- and expiration, creating a CL displaying the dynamic changes between the extremes of IVC minimum diameter (inspiration) and IVC maximum diameter (expiration) (Figure 2).

After recording the CL in longitudinal orientation, the probe must be turned 90° anticlockwise, so the probe indicator will face towards the patient’s right. In this position, it is intended to obtain a transverse view of the IVC. Displaying the liver now to the left, the IVC becomes visible directly at the right border of the liver. Again, it can be clearly distinguished from the aorta showing collapse during respiration (Figure 3). During this view, the probe needs to gently follow the movement of the diaphragm up and down, to keep the same area of the IVC constantly in the focus. Once the image is of good quality and clearly displays the IVC, another CL of six seconds should then be recorded. These two CL then serve as sufficient visual evidence for determining the intravascular volume status through clinical assessment.

### Assessment of the cineloops

The obtained CL were firstly assessed by the expert on adequacy and quality. If deemed to be inadequate or of low quality, they should not serve the purpose of intravascular volume assessment. It was then suggested that the investigation be repeated to refine the technique, possibly under surveillance by the expert or with his support. After multiple repeated measurements, the novice eventually gained more confidence and routine in the safe performance of the task.

After the recorded CL was found to depict the IVC adequately and with good quality, the loop was then scrolled to the biggest diameter (IVCd<sub>max</sub>) and measured, followed by the same measurement in the smallest diameter (IVCd<sub>min</sub>). These two values can be used in a specified equation, resulting in a classification of the volume status.

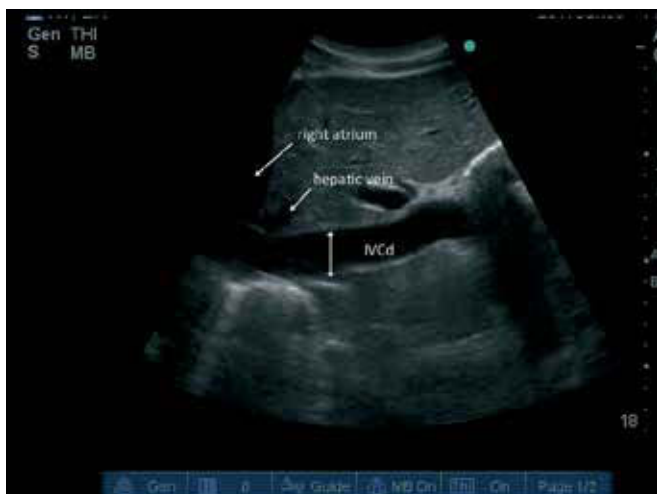

Figure 2: Inferior vena cava diameter longitudinal view (IVCd)

The formula,  $[(IVCd_{max} - IVCd_{min}) / IVCd_{max}] \times 100$ , results in the IVC collapsibility index (IVCCI) (Table 2). Muniz Pazeli *et al.* (2014) emphasised that “small millimetric differences in the measurements may change the classification” but, in our opinion, combining the values and even pairing longitudinal and transverse view will guide the assessment towards a correct conclusion. Our IVCCI cut-offs, based on the current ‘Guidelines for the Echocardiographic Assessment of the Right Heart in Adults’ (Rudski *et al.*, 2010) suggested that a diameter < 2.1 cm and collapsibility >50% represents hypovolaemia correlating with central venous pressure (Table 2).

Definition of cut-offs IVCCI:	
Hypovolaemia	(IVCCI > 50% and IVCd <sub>max</sub> < 2.1 cm)
Euvoalaemia	(IVCCI > 50% and IVCd <sub>max</sub> > 2.1 cm) or (IVCCI < 50% and IVCd <sub>max</sub> < 2.1 cm)
Hypervolaemia	(IVCCI < 50% and IVCd <sub>max</sub> > 2.1 cm)

Table 2: IVCCI cut-offs according to the ‘Guidelines for the Echocardiographic Assessment of the Right Heart in Adults’ (Rudski *et al.*, 2010)

### Assessment of the IVC diameter for intravascular volume status

The recorded CL allowed for assessment of intravascular volume status. With sufficient quality and adequacy of the CL, the recording was subsequently assessed for intravascular volume status. Several studies have confirmed that for IVC-US non-experts, nurses as well as others in the medical profession were able to adequately perform the scan and the subsequent classification for volume status after receiving appropriate training (Dalen *et al.*, 2015; Gómez Betancourt *et al.*, 2016; Muniz Pazeli *et al.*, 2014; Steinwandel *et al.*, 2017a). Yepes-Hurtado *et al.* (2016) have expressed concerns about the use of IVC-US as the single parameter for fluid status estimation, but we believe combining IVC-US-based volume classification with other traditional objective parameters has good potential to reveal a clearer picture of an individual’s volume status.

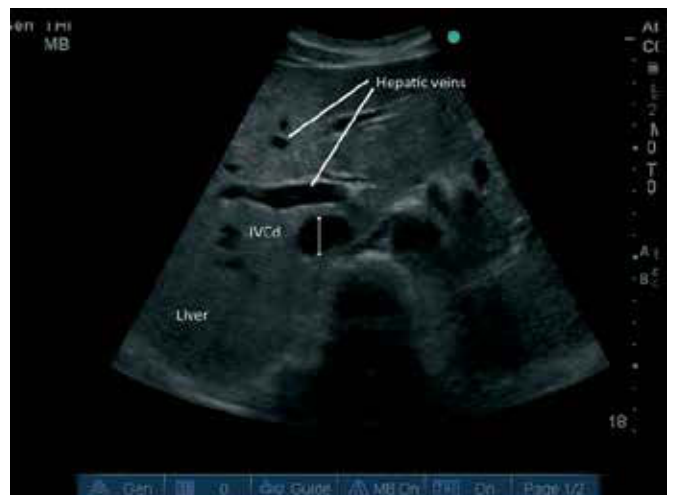

Figure 3: Inferior vena cava diameter transverse view (IVCd)

The renal nurse can then use this information in the clinical decision-making process for the determination of ultrafiltration goal and rate, ultimately aiming to avoid IDH occurrence.

### Module 3

This third stage of the program was designed to establish the number of required scans to achieve technical competency. A study by Gómez Betancourt *et al.* (2016), which evaluated the effectiveness of recommended training in US techniques, concluded that 25 procedural repetitions can be sufficient to achieve optimal image quality when novices attempt to perform US scans of the IVC. This is in accordance with the recommendation of the American College of Emergency Physicians (ACEP) recommendations (American College of Emergency, 2009). Other authors have suggested a significantly higher number of repeated scans before an ultrasound-naïve nurse can achieve a good interrater agreement with that of an expert. A study by Dalen *et al.* (2015) reported that two nurses who had previously performed more than 200 focussed US scans achieved a good interrater agreement with a cardiologist. They obtained reliable scans and could interpret them safely.

Therefore, the learning objective for this stage consisted of the renal nurse performing 100 IVC-US examinations on a broad variety of patients, firstly under the supervision of the sonologist, then independently and self-directed, allowing refinement of probe placement technique and adequate visualisation of the desired anatomical structure. Choosing different patients exposed the nurse to a broader variety of anatomical and physiological conditions with different level of difficulties in observing the IVC. The nurse-performed scans were retrospectively analysed by the expert after 15, 50 and 100 scans, providing useful feedback to the nurse. The final aims of this module were to improve acquisition of high-quality images under the guidance of the proficient expert, and perform post-examination assessment of the scans on the hydration or intravascular volume status of the patients.

### Module 4

The nurse then performed 60 scans as an independent examiner in a cohort of 10 patients without the sonologist being present. All these scans were recorded, stored and subsequently reviewed and assessed by the nurse. Based on the scans, the nurse then categorised the patients into hypo-, hyper- or euvoaemic hydration status according to the 'Guidelines for the Echocardiographic Assessment of the Right Heart in Adults' (Rudski *et al.*, 2010). Following this, two independent sonologists validated all scans again on quality and accuracy in a blinded peer-review process and found a good interrater agreement amongst all raters (Steinwandel *et al.*, 2017a). The 60 scans depicted the final milestone of

the renal nurse achieving a good level of competency and accuracy in obtaining the scans and assessing intravascular volume status when compared to the expert.

### Discussion

Specialised training guided by an expert within a structured program is likely necessary for a novice to obtain confidence in the performance of IVC-US. We suggest for an ultrasound-naïve nurse it may take an estimated 100 preliminary IVC-US scans, reviewed by an expert on quality and adequacy, to give the novice sufficient feedback before independent investigations could commence. Digital storage and post-hoc analysis of obtained CLs are certainly helpful learning opportunities as these enable independent recording without the expert present. The learning curve appeared steep initially, but with perseverance and resilience an acceptable level of competence was readily achieved.

Following our suggested approach in adopting and learning the technique of IVC-US and interpreting the results, we believe this skill is transferable to renal nurses, resulting in an enhanced skill set which could prove very useful in their everyday practice. It is important to mention that IVC-US should not be used as the sole parameter for volume assessment and should always be seen in the clinical context in combination with other objective parameters like blood pressure, weight, nutrition status and trends in the ideal body weight (IBW) of a HD patient. Therefore IVC-US in nurses' hands can be a non-invasive useful adjunct to well-known volume assessment parameters, adds another clinical dimension and may help to achieve a more comprehensive approach when assessing a HD patient for excess fluid.

### Implications for practice

Previous studies have shown that doctors can successfully perform IVC-US for volume assessment in HD patients. IVC-US has the potential to prevent HD patients from the common adverse event IDH. Repeated episodes of IDH have detrimental effects on a variety of organ systems. We found that educating a renal nurse in IVC-US is feasible and a staged educational program for renal nurses is likely to be successful. US education involves knowledge and skill acquisition and task repetition transforms theoretical and practical education into competence. Our study has also shown that a summative assessment ensuring competence prior to independent scanning is important.

### Conclusion

In preparation for a pilot study, we found a structured educational program conducted by an expert sonologist for an ultrasound-naïve renal nurse can be successful in upskilling of the nurse to perform IVC-US. When nurses use this skill on a

regular basis, it may have potential to improve health outcomes for patients, such as avoiding subsequent hospital admissions and reducing cost.

## Conflict of interest

No conflict of interest has been declared by the authors.

## Acknowledgements

This study received financial support from the Raine Medical Research Foundation, the Medical Research Foundation Fremantle Hospital and Edith Cowan University, Joondalup.

The Sonosite M Turbo was on loan from Fremantle Hospital (Fremantle, Western Australia) for the duration of the study.

## References

- American College of Emergency Physicians. (2009). Emergency ultrasound guidelines. *Annals of Emergency Medicine*, 53, 550–70.
- Benner, P. E. (1984). *From novice to expert: excellence and power in clinical nursing practice*, Menlo Park, CA.: Addison-Wesley Pub. Co., Nursing Division.
- Bradshaw, W., & Bennett, P. N. (2015). Asymptomatic Intradialytic Hypotension: The Need for Pre-Emptive Intervention. *Nephrology nursing journal: journal of the American Nephrology Nurses' Association*, 42, 479–85; quiz 486.
- Brennan, J. M., Ronan, A., Goonewardena, S., Blair, J. E., Hammes, M., Shah, D., Vasaiwala, S., Kirkpatrick, J. N., & Spencer, K. T. (2006). Handcarried ultrasound measurement of the inferior vena cava for assessment of intravascular volume status in the outpatient hemodialysis clinic. *Clinical Journal of the American Society of Nephrology: CJASN*, 1, 749–53.
- Chao, C.-T., Huang, J.-W., & Yen, C.-J. (2015). Intradialytic hypotension and cardiac remodeling: a vicious cycle. *BioMed research international*, 2015, 724147.
- Dalen, H., Gundersen, G. H., Skjetne, K., Haug, H. H., Kleinau, J. O., Norekval, T. M., & Graven, T. (2015). Feasibility and reliability of pocket-size ultrasound examinations of the pleural cavities and vena cava inferior performed by nurses in an outpatient heart failure clinic. *European Journal of Cardiovascular Nursing*, 14, 286–93.
- Davenport, A. (2014). Balancing risks: Blood pressure targets, intradialytic hypotension, and ischemic brain injury. *Seminars in Dialysis*, 27, 13–15.
- De Lorenzo, R. A., & Holbrook-Emmons, V. L. (2014). Ultrasound measurement of inferior vena cava diameters by emergency department nurses. *Advanced Emergency Nursing Journal*, 36, 271–8.
- Gómez Betancourt, M., Moreno-Montoya, J., Barragán González, A.-M., Ovalle, J. C., & Bustos Martínez, Y. F. (2016). Learning process and improvement of point-of-care ultrasound technique for subxiphoid visualization of the inferior vena cava. *Critical Ultrasound Journal*, 8, 1–5.
- Gustafsson, M., Alehagen, U., & Johansson, P. (2015). Pocket-sized ultrasound examination of fluid imbalance in patients with heart failure: a pilot and feasibility study of heart failure nurses without prior experience of ultrasonography. *European Journal of Cardiovascular Nursing*, 14, 294–302.
- Marticorena, R. M., Mills, L., Sutherland, K., McBride, N., Kumar, L., Concepcion Bachynski, J., Rivers, C., Petershofer, E. J., Hunter, J., Luscombe, R., & Donnelly, S. (2015). Development of competencies for the use of bedside ultrasound for assessment and cannulation of hemodialysis vascular access. *CANNT Journal*, 25, 28–32.
- Mcintyre, C. W., & Goldsmith, D. J. (2015). Ischemic brain injury in hemodialysis patients: which is more dangerous, hypertension or intradialytic hypotension? *Kidney International*, 87, 1109–1115.
- Muniz Pazeli, J., Fagundes Vidigal, D., Cestari Grossi, T., Silva Fernandes, N. M., Colugnati, F., Baumgratz De Paula, R., & Sanders-Pinheiro, H. (2014). Can nephrologists use ultrasound to evaluate the inferior vena cava? A cross-sectional study of the agreement between a nephrologist and a cardiologist. *Nephron Extra*, 4, 82–8.
- Rudski, L. G., Lai, W. W., Afilalo, J., Hua, L., Handschumacher, M. D., Chandrasekaran, K., Solomon, S. D., Louie, E. K., & Schiller, N. B. (2010). Guidelines for the Echocardiographic Assessment of the Right Heart in Adults: A Report from the American Society of Echocardiography. Endorsed by the European Association of Echocardiography, a registered branch of the European Society of Cardiology, and the Canadian Society of Echocardiography. *Journal of the American Society of Echocardiography*, 23, 685–713.
- Stawicki, S. P., & Bahner, D. P. (2015). Modern sonology and the bedside practitioner: evolution of ultrasound from curious novelty to essential clinical tool. *European journal of trauma and emergency surgery: official publication of the European Trauma Society*, 41, 457–60.
- Stefansson, B. V., Brunelli, S. M., Cabrera, C., Rosenbaum, D., Anum, E., Ramakrishnan, K., Jensen, D. E., & Stalhammar, N. O. (2014). Intradialytic hypotension and risk of cardiovascular disease. *Clinical Journal of the American Society of Nephrology*, 9, 2124–32.
- Steinwandel, U., Gibson, N., Towell, A., Rippey, J. J. R., & Rosman, J. (2017a). Can a renal nurse assess fluid status using ultrasound on the inferior vena cava? A cross-sectional interrater study. *Hemodialysis International*, n/a-n/a.
- Steinwandel, U., Gibson, N. P., Rippey, J. C., Towell, A., & Rosman, J. (2017b). Use of ultrasound by registered nurses—a systematic literature review. *Journal of Renal Care*, 43, 132–142.
- Tonelli, M., & Riella, M. (2014). Chronic kidney disease and the ageing population. *Journal of Renal Care*, 40, 1–5.
- Yepes-Hurtado, A., Omar, S., Monzer, K., Alalawi, R., & Nugent, K. (2016). Inferior vena cava dimensions in patients with acute kidney injury. *The Southwest Respiratory and Critical Care Chronicles*, 4, 9.