

Description of *Goussia kuehae* n. sp. (Apicomplexa: Eimeriidae) infecting the Asian seabass, *Lates calcarifer* (Bloch) (Perciformes: Latidae), cultured in Malaysian fish farms

Csaba Székely, Muhammad Hafiz Borkhanuddin, Faizah Shaharom, Mohd Shukri Adam Embong & Kálmán Molnár

Systematic Parasitology

An International Journal

ISSN 0165-5752

Volume 86

Number 3

Syst Parasitol (2013) 86:293-299

DOI 10.1007/s11230-013-9448-1



1
2
3
4
5
6
7
8
9
10
11
12
13
14
15
16
17
18
19
20
21
22
23
24
25
26
27
28
29
30
31
32
33
34
35
36
37
38
39
40
41
42
43
44
45
46
47
48
49
50
51
52
53
54
55
56
57
58
59
60
61
62
63
64
65

Description of *Goussia kuehae* n. sp. (Apicomplexa: Eimeriidae) infecting the Asian seabass, *Lates calcarifer* (Bloch) (Perciformes: Latidae), cultured in Malaysian fish farms

Csaba Székely • Muhammad Hafiz Borkhanuddin • Faizah Shaharom • Mohd Shukri
Adam Embong • Kálmán Molnár

Received: 25 July 2013 / Accepted: 16 September 2013

C. Székely (✉) • M. H. Borkhanuddin • Kálmán Molnár

Institute for Veterinary Medical Research, Centre for Agricultural Research, HAS

e-mail: szekely.csaba@agrar.mta.hu

F. Shaharom • M. S. A. Embong

Institute of Tropical Agriculture (AQUATROP), University Malaysia Terengganu, Kuala

Terengganu, Malaysia

Abstract Culturing fishes in marine cages is a rapidly developing area of marine aquaculture. The Asian seabass *Lates calcarifer* (Bloch) is a fast growing good quality fish that is readily cultured in intensive systems in the South Asian region and in Malaysia in particular. Although several papers have been published to date on viral, bacterial, parasitic and fungal organisms causing diseases in the Asian seabass, the occurrence of a coccidian infection in this species has only recently been recorded. We collected sporulated and unsporulated oöcysts of a new species of *Goussia* Labbé, 1986, from the mucus covering the epithelium of the intestine of *L. calcarifer*. This paper provides a description of *Goussia kuehae* n. sp. Sporulated oöcysts of this species are ellipsoidal, 37–40 µm in length and 28–30 µm in width. The ellipsoidal sporocysts are relatively small, 15.2–17 × 5.7–8 µm, and located loosely in the oöcyst. There are residual bodies both in the oöcysts and the sporocysts. *Goussia kuehae* n. sp. differs from all known species of *Goussia* in the large size of the oöcysts and in having two types of oöcyst residuum.

Introduction

The Asian seabass, *Lates calcarifer* (Bloch) (Perciformes: Latidae), is a favourite food fish cultured mostly in the South Asian region and Australia in intensive and semi-intensive systems. In Malaysia the culture of this species started in 1976, when the Malaysian government has embarked on the production using the wild and imported fry specimens in floating net cages in Setiu Lagoon on the east coast of Peninsular Malaysia (Norfatimah et al., 2009). Due to the high economic importance of Asian seabass culture, its diseases have been studied intensively. Among infectious diseases, viral nervous necrosis and a bacterial infection caused by *Streptococcus iniae* Pier & Madin, 1976 are the most important (Nash et al., 1987; Bromage et al., 1999; Maeno et al., 2004; Ransangan & Manin; 2010). Of the parasites infecting *L. calcarifer*, the ciliophoran parasite *Cryptocaryon irritans* Brown, 1951 plays the highest pathogenic role (Diggles & Lester, 1996) but monogeneans such as *Benedenia melleni* Meyer & Grootaert, 1990 and *Laticola* spp. are also common causative agents of diseases (Denevey et al., 2001; Yang et al., 2006). In cage cultures copepods such as *Lernanthropus latis* Yamaguti, 1954 and *Caligus* spp. (Maran et al., 2009; Chu et al., 2012; Muhd-Faizul et al., 2012) are frequent causative agents, but sanguinicolid blood flukes can also cause some latent infections (Herbert & Shaharom, 1995; Herbert et al., 1995).

Recently Gibson-Kueh et al. (2011a, b) described a coccidian infection from the intestinal epithelium of *L. calcarifer* in Vietnam and Australia, caused by an epicellularly developing *Eimeria* sp. These authors studied ethanol-fixed sporulated oöcysts, made histological and ultrastructure studies and presented data on the molecular structure of the 18S rDNA of this parasite, but due to the lack of fresh material they failed to describe it as a named new species. *Eimeria* spp. infection in Malaysia was first published by Boulard (1977) who described *Eimeria quentini* Boulard, 1977 from the marine fish *Aetobatus narinari* (Euphrasen). Some freshwater coccidians were mentioned by Molnár et al. (2003) who described three new species and recorded *Goussia trichogasteri* Székely & Molnár, 1992 found by Székely & Molnár (1992) in an aquarium cultured gouramy in Europe.

In a study on parasites of specimens of *L. calcarifer* cultured in Malaysian cage cultures we also found coccidian oöcysts in the intestine of this species which we were able to examine from fresh material. The structure of the oöcysts of this coccidium corresponded to that reported earlier by Gibson-Kueh et al. (2011a, b). Sporulated oöcysts of this species bear the typical signs

of the genus *Goussia* Labbé, 1986. Based on the morphology of the oöcysts we hereby describe this species as *Goussia kuehae* n. sp.

Materials and methods

Both the Institute for Veterinary Medical Research in Hungary and University Malaysia Terengganu received official approval for the use of fish specimens for parasitological surveys from their National Animal Experiment Committees. Fifteen Asian seabass individuals with standard length (SL) 17–32 cm were selected from cages and carried to the laboratory alive for health inspection in February, 2013. Fish were transported to the laboratory in oxygen-filled plastic bags and kept in an aquarium for 1–2 days. Following sedation with clove oil they were killed with a cervical cut and subjected to complete parasitological examination. To detect coccidian infections, fresh mucus from the intestinal tract was examined for the presence of oöcysts.

Drawings of some sporulated oöcysts were made and measurements were taken immediately after the detection of the oöcysts using a Nikon microscope (model MM-800). For further studies and for measuring more oöcysts, fresh oöcysts were photographed with a Nikon Microscope Model Eclipse 80i advanced microscope; digitised images were obtained and measurements were taken from digitised photos. All measurements are given in micrometres as the range followed by the mean and standard deviation in parentheses.

Results

Of the 15 individuals studied for coccidian infections, two specimens (standard length 19 and 23 cm) proved to be infected. In the larger individual only non-sporulated oöcysts (Fig. 1) were recovered, whereas in the smaller specimen oöcysts in advanced stage of sporulation were found, in which the sporozoites in sporocysts have already been formed but a relatively large sporocyst residuum covered them (Fig. 2). The sporulated oöcysts of the new species are described below.

Family Eimeriidae Minchin, 1903

Goussia kuehae n. sp.

Syn. *Eimeria* sp. of Gibson-Kueh et al. (2011a)

Type-host: *Lates calcarifer* (Bloch) (Perciformes: Latidae).

Type-locality: Brackish water cages at Setiu Wetland, Terengganu State, Malaysia.

Site: Mucus and epithelium of the anterior part of intestine.

Prevalence of infection: 13.3 %.

Type-material: Photo types have been deposited in the parasitological collection of the Hungarian Natural History Museum, Budapest (Coll. No. HNHM-70399).

Etymology: The *nomen triviale* derives from the name of the first author, Ms S. Gibson-Kueh of the Australian-Vietnamese research team who first studied this parasite.

Description (Figs. 1–3)

Non-sporulated oöcysts round, 14–16 in diameter or slightly elongate-oval, 18–20 × 14–16 (Fig. 1). Sporulated oöcysts (Figs. 2, 3A) (n = 50) ellipsoidal, 37–40 (37.9 ± 1.49) in length and 28–30.3 (29.3 ± 0.97) in width. Wall of the oöcyst thin, smooth, colourless. Micropyle absent. Two or 3 pale rounded oöcyst residuum-like bodies 7–8.5 (7.8 ± 0.54) in size and some round or amorphous compact oöcyst residuum-like bodies 1–3.5 in diameter present (Fig. 2). Oöcyst contains 4 ellipsoidal sporocysts (Fig. 3B), 15.2–17.0 × 5.7–8.0 (16.2 ± 0.7 × 6.7 ± 0.8), located very loosely in the oöcyst, leaving large space among them. In most cases they are arranged in different directions. Sporocyst wall thin, single-layered. The two sporocyst valves connected by an indistinct, longitudinally running suture. Stieda body or Stieda-body-like structures not seen. Sporozoites elongate, banana-shaped, located head to tail in the sporocyst, 14–15.7 × 2.3–2.7 (14.7 ± 0.71 × 2.6 ± 0.19). Sporocyst residuum rough scattered dots (0.8–1.2) arranged in the centre of the sporocyst, partially obscuring sporozoites; size of sporocyst residuum tends to permanently decrease during sporulation.

Neither oöcysts nor developing stages were found in the histological sections and in the scanning electron microscopy (SEM) preparations made from the first portion of the intestine.

Remarks

Sporulated oöcysts infecting the Asian seabass differ in their structure from all known species of *Goussia*. Their size is relatively large which is unusual among fish coccidia. The oöcysts have a loose structure in which the relatively small sporocysts are located in a large space. The oöcysts of this species have two types of oöcyst residuum-like bodies. Neither of these bodies resembles a true oöcyst residuum. True oöcyst residua are very rare in fish coccidia e.g. the oöcyst of *Goussia lomi* Molnár & Rohde, 1988, a parasite of the Murray cod, *Macullochella peelii* Mitchell, has a large oöcyst residuum which is built up from similar granules as the sporocyst residuum (Molnár & Rohde, 1988). The structure of the compact amorphous granules of the oöcyst residuum in *G. kuehae* n. sp. resembles that of the polar granules, but their large number and their varying sizes differ from the known *Goussia* species, which harbour only one or two very small amorphous polar granules. The oöcysts correspond in all respects to *Eimeria* sp. described by Gibson-Kueh et al. (2011a), but due to the lack of a Stieda body and having sporocyst walls composed of two halves, they bear the features of *Goussia* spp. This parasite has also been studied at the molecular level by Gibson-Kueh et al. (2011b).

Discussion

The majority of fishes are infected by one to five coccidian species. Of the parasites of the family Eimeriidae, members of the genera *Eimeria* Schneider, 1875 and *Goussia* are the most common in fishes. Duszynski et al. (2012), who regards *Goussia* as a synonym of *Eimeria*, listed more than 300 known species. The genus *Goussia* was described by Labbé (1896) for coccidia with delicate oöcyst and sporocyst walls, having four dizoic sporocysts composed of two valves, joined by a longitudinal suture but lacking Stieda body. The genus was for a long time regarded as a synonym of *Eimeria*, but Dyková & Lom (1981) revitalised the genus *Goussia*; later they transferred some species from the genus *Eimeria* to *Goussia* (see Dyková & Lom, 1983). Molnár (2006) in a review on fish coccidia differentiated two major groups among *Goussia* spp. parasitising fish. The first group, a disperse type *Goussia* spp. develops permanently during the year by a short developmental cycle, forms small, compact oöcysts 8–13 µm in size and infects intestinal epithelium randomly. The second group of *Goussia* spp. has loosely structured, relatively large oöcysts, which are formed only once a year in spring. Among these coccidians with oöcyst size of 15–30 µm there are three subgroups differing from each other in their

location. One type of these species develops in epicellular position (intracellular but extracytoplasmal location). Another type of *Goussia*, the nodular species, develops in the gut of the hosts in nodules in isolated places, infecting neighbouring host cells. In addition to the above types of *Goussia* there are seasonally developing species which infect inner organs such as the liver, spleen, kidney and serous membranes of the abdominal cavity of fish.

Although no developing stages were found in the histological sections and SEM preparations made from an advanced stage of development, the morphological identity of the oöcysts presented by Gibson-Kueh et al. (2011a) from fixed material and the oöcysts found by us in the fresh intestinal mucus, proves that the two cases represent a single coccidian species of the epicellular type, described here as *G. kuehae* n. sp. The stages found by Gibson-Kueh et al. (2011a) in the intestine of the Asian seabass in Vietnam, Australia and Malaysia were located epicellularly in the intestinal epithelium and thus resembled *G. pannonica* Molnár, 1989 and *G. janae* Lukeš & Dykova, 1990 (see Molnár, 1989; Lukeš & Dykova, 1990). However, *G. kuehae* differs from these two species described from cyprinids in several aspects. Thus, relatively small sporocysts are found in the unusually large oöcysts of *G. kuehae*; moreover this species has oöcyst residuum-like and polar granule-like bodies. Polar granules commonly occur in oöcysts of *Goussia* spp. of the epicellular and nodular types, but true oöcyst residuum was found only in *G. lomi* by Molnár & Rohde (1988). Although the epicellular type of *Goussia* spp. is mostly known from freshwater fishes, *G. girellae* Kent, Fournie, Snodgrass & Elston, 1988 described by Kent et al. (1988) infects a typical marine fish, *Girella nigricans* (Ayres).

The failure to detect infection in histological sections and SEM preparations can be explained by the fact that at an advanced stage of infection already no developing stages existed in the first portion of the intestine from where the samples were taken. Nevertheless, the morphological identity of the oöcysts presented by Gibson-Kueh et al. (2011a) from fixed material and the oöcysts found by us in the fresh intestinal mucus proves that oöcysts in both cases represent one species, i.e. *G. kuehae* n. sp.

Nothing is known about the seasonal occurrence of this species. The seasonal occurrence has only been studied in species infecting fishes of the temperate climate zone where (with the exception of the disperse developing coccidians) freshwater species of *Goussia* and *Eimeria* form oöcysts in spring i.e. about the season when propagation of the hosts takes place (Lukeš, 1992; Molnár, 1996). In Malaysia we found sporulated oöcysts in February, but it would be far-reaching to state that in this climate where the temperature is similar throughout the whole year, seasonal differences in oöcyst production exist. There would be a need to study the problem of seasonality both in coccidians and in other parasites of fish which show a strict seasonal cycle in Europe.

Acknowledgements The research was funded by the grants OTKA K 100132, and by the grant of the Hungarian Government, managed by the National Development Agency, and financed by the Research and Technology Innovation Fund (KTIA AIK-12), and Malaysian Scholarship to H. B. The authors are thankful to Prof. László Orbán for reading the paper and for his suggestions.

References

- Boulard, Y. (1977). Description d'*Eimeria quentini* n. sp., parasite intranucleaire du peritoine de la Raie *Aetobatis narinari* (Chondrichthyens, Myliobatidae) en Malaisie. *Protistologica*, 13, 529–533.
- Bromage, E. S., Thomas, A., & Owens, L. (1999). *Streptococcus iniae*, a bacterial infection in Asian seabass *Lates calcarifer*. *Diseases of Aquatic Organisms*, 36, 177–181.
- Chu, K. B., Rashid, N. M., & Abd Rani, N. R. (2012). Infestation of gill copepod *Lernanthropus latis* (Copepoda: Lernanthropidae) and its effect on cage-cultured Asian sea bass *Lates calcarifer*. *Tropical Biomedicine*, 29, 443–450.
- Deveney, M. R., Chisholm, L. A., & Whittington, I. D. (2001). First published record of the pathogenic monogenean parasite *Neobenedenia melleni* (Capsalidae) from Australia. *Diseases of Aquatic Organisms*, 46, 79–82.
- Diggles, B. K., & Lester, R. J. G. (1996). Influence of temperature and host species on the development of *Cryptocaryon irritans*. *Journal of Parasitology*, 82, 45–51.
- Duszynski, D. W., Upton, S. J., & Couch, L. (2013). The coccidia of the world. World Wide WEB Electronic Publication. www.k-state.edu/parasitology/worldcoccidia/.
- Dyková, I., & Lom, J. (1981). Fish coccidia. Critical notes on life cycles, classification and pathogenicity. *Journal of Fish Diseases*, 4, 487–505.
- Dyková, I., & Lom, J. (1983). Fish coccidia: an annotated list of described species. *Folia Parasitologica*, 30, 193–208.
- Gibson-Kueh, S., Yanga, R., Thuy, N. T. N., Jones, J. B., Nicholls, P. K., & Ryana, U. (2011b). The molecular characterization of an *Eimeria* and *Cryptosporidium* detected in Asian seabass (*Lates calcarifer*) cultured in Vietnam. *Veterinary Parasitology*, 181, 91–96.

- Gibson-Kueh, S., Thuy, N. T. N., Elliot, A., Jones, J. B., Nicholls, P. K., & Thompson, R. C. A. (2011a). An intestinal *Eimeria* infection in juvenile Asian seabass (*Lates calcarifer*) cultured in Vietnam – A first report. *Veterinary Parasitology*, *181*, 106–112.
- Herbert, B. W., & Shaharom, F. M. (1995). A new blood fluke, *Parasanguinicola vastispina* gen. nov, sp. nov (Trematoda, Sanguinicolidae), from sea bass *Lates calcarifer* (Centropomidae) cultured in Malaysia. *Parasitology Research*, *81*, 349–354.
- Herbert, B. W., Shaharom, F. M., & Anderson, I. G. (1995). Histopathology of cultured Sea-bass (*Lates calcarifer*) (Centropomidae) infected with *Cruoricola lates* (Trematoda, Sanguinicolidae) from Pulau-Ketam, Malaysia. *International Journal for Parasitology*, *25*, 3–13.
- Kent, M., Fournie, J. W., Snodgrass, R. E., & Elston, R. A. (1988). *Goussia girellae* n. sp. (Apicomplexa, Eimeriorina) in the opaleye, *Girella nigricans*. *Journal of Protozoology*, *35*, 287–290.
- Labbé, A. (1896). Reserches zoologiques cytologiques et biologiques sur les coccidies. *Archives de Zoologie Expérimentale et Générale* (3e série), *4*, 517–654.
- Lukeš, J. (1992). Life cycle of *Goussia pannonica* (Molnár, 1989) (Apicomplexa, Eimeriorina), an extracytoplasmic coccidium from the white bream *Blicca bjoerkna*. *Journal of Protozoology*, *39*, 484–494.
- Lukeš, J., & Dyková, I. (1990). *Goussia janae* n. sp (Apicomplexa, Eimeriorina) in dace *Leuciscus leuciscus* and chub *L. cephalus*. *Diseases of Aquatic Organisms*, *8*, 85–90.
- Maeno, Y., De La Pena, L. D., & Cruz-Lacierda, E. R. (2004). Mass mortalities associated with viral nervous necrosis in hatchery-reared sea bass *Lates calcarifer* in the Philippines. *Jarq-Japan Agricultural Research Quarterly*, *38*, 69–73.
- Maran, B. A. V., Seng, L. T., Ohtsuka, S., & Nagasawa, K. (2009). Records of *Caligus* (Crustacea: Copepoda: Caligidae) from Marine Fish Cultured in Floating Cages in Malaysia with a Redescription of the Male of *Caligus longipedis* Bassett-Smith, 1898. *Zoological Studies*, *48*, 797–807.
- Molnár, K. (1989). Nodular and epicellular coccidiosis in the intestine of cyprinid fishes. *Diseases of Aquatic Organisms*, *7*, 1–12.
- Molnár, K. (1996). Nodular coccidiosis of the pikeperch *Stizostedion lucioperca* and Volga perch *Stizostedion volgensis*. *Diseases of Aquatic Organisms*, *27*, 35–41.
- Molnár, K. (2006). Phylum Apicomplexa. In: Woo, P.T.K. (Ed.) *Fish Diseases and Disorders*. Vol. 1: *Protozoan and Metazoan Infections*, 2nd edn. Wallingford: CAB International, pp. 183–204.

- 1
2
3
4
5
6
7
8
9
10
11
12
13
14
15
16
17
18
19
20
21
22
23
24
25
26
27
28
29
30
31
32
33
34
35
36
37
38
39
40
41
42
43
44
45
46
- Molnár, K., & Rohde, K. (1988). New coccidians from freshwater fishes of Australia. *Journal of Fish Diseases*, *11*, 161–169.
- Molnár, K., Shaharom, F., & Székely, Cs. (2003). A survey of coccidian infections of freshwater fishes of Peninsular Malaysia, with descriptions of three species of *Goussia* Labbé, 1896 (Apicomplexa: Eimeriidae). *Systematic Parasitology*, *55*, 11–18.
- Muhd-Faizul, H. A. H., Kua, B. C., & Leaw, Y. Y. (2012). Caligid infestation in Asian seabass, *Lates calcarifer*, Bloch 1790 cultured at different salinity in Malaysia. *Veterinary Parasitology*, *184*, 68–72.
- Nash, G., Anderson, I. G., Shariff, M., & Shamsudin, M. N. (1987). Bacteriosis associated with epizootic in the giant sea perch, *Lates calcarifer*, and the estuarine grouper, *Epinephelus tauvina*, cage cultured in Malaysia. *Aquaculture*, *67*, 105–111.
- Norfatimah, M. Y., Siti Azizah, M. N., Othman, A. S., Patimah, I., & Jamsari, A. F. J. (2009). Genetic variation of *Lates calcarifer* in Peninsular Malaysia based on the cytochrome *b* gene. *Aquaculture Research*, *40*, 1,742–1,749.
- Ransangan, J., & Manin, B. O. (2010). Mass mortality of hatchery-produced larvae of Asian seabass, *Lates calcarifer* (Bloch), associated with viral nervous necrosis in Sabah, Malaysia. *Veterinary Microbiology*, *145*, 153–157.
- Székely, Cs., & Molnár, K. (1992). *Goussia trichogasteri* n. sp. (Apicomplexa: Eimeriidae) infecting the aquary cultured golden gouramy (*Trichogaster trichopterus*). *Diseases of Aquatic Organisms*, *13*, 79–81.
- Yang, T. B., Kritsky, D. C., Sun, Y., Zhang, J. Y., Shi, S. H., & Agrawal, N. (2006). Diplectanids infesting the gills of the Asian seabass *Lates calcarifer* (Bloch) (Perciformes: Centropomidae), with the proposal of *Laticola* n. g. (Monogenoidea : Diplectanidae). *Systematic Parasitology*, *63*, 127–141.

47 Figure legends

48
49
50
51
52
53
54
55

Fig. 1 Four unsporulated oöcysts of *Goussia kuehae* n. sp. lined up in a row in the smear from the intestinal epithelium of *Lates calcarifer*. *Scale-bar*: 10 µm

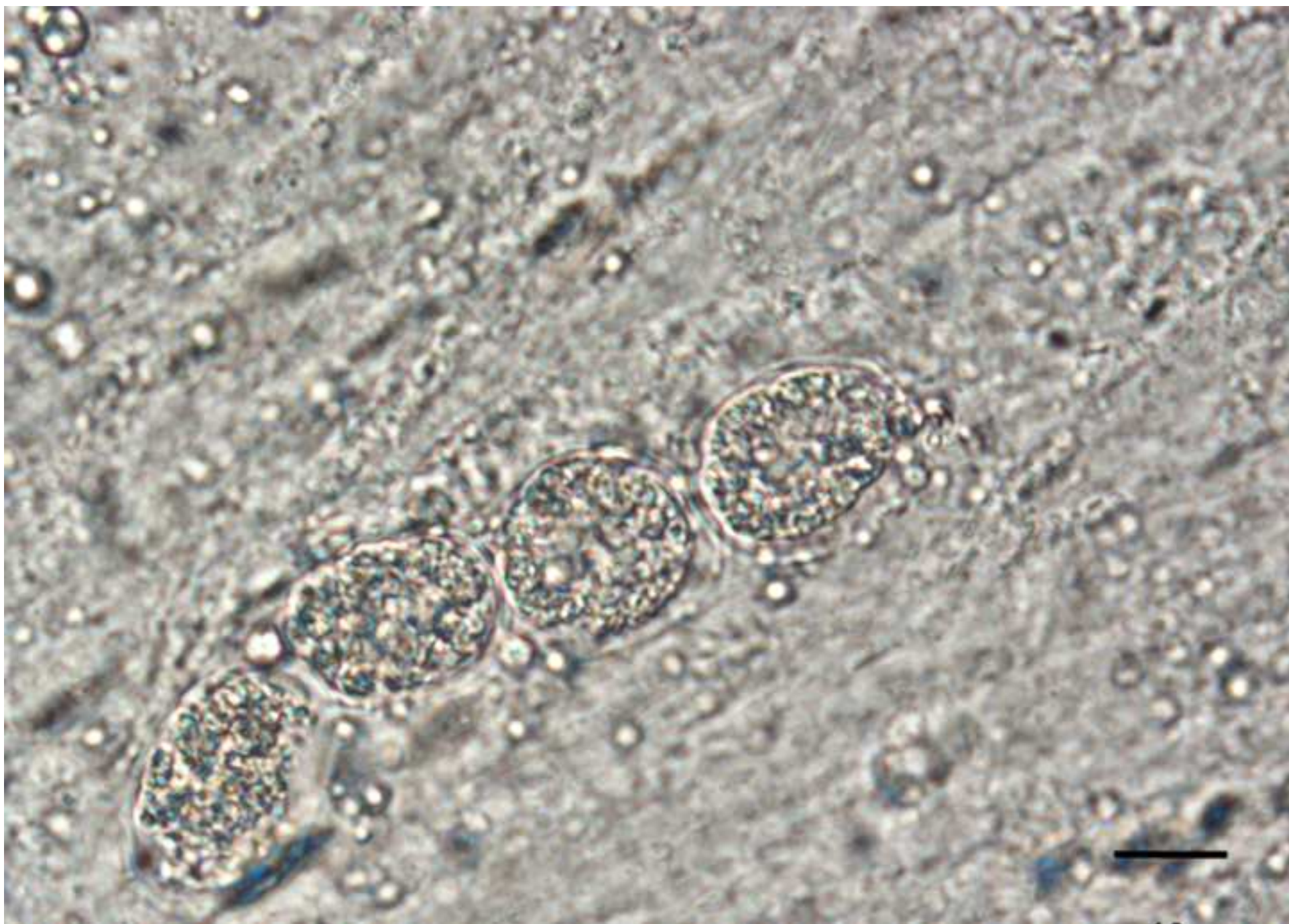
56
57
58
59
60
61
62
63
64
65

Fig. 2 Sporulated oöcysts of *Goussia kuehae* n. sp. in the mucus from the intestinal epithelium of *Lates clcarifer*. Besides the four sporocysts present in each oocyst, pale (p) and compact (arrows) oöcyst residuum-like bodies are also found in oöcysts. *Scale-bar*: 10 µm

Fig. 3 Schematic drawings of the oöcyst (A) and sporocyst (B) of *Goussia kuehae* n. sp. Scale-
bars: 10 µm

1
2
3
4
5
6
7
8
9
10
11
12
13
14
15
16
17
18
19
20
21
22
23
24
25
26
27
28
29
30
31
32
33
34
35
36
37
38
39
40
41
42
43
44
45
46
47
48
49
50
51
52
53
54
55
56
57
58
59
60
61
62
63
64
65

Revised Fig. 1
[Click here to download high resolution image](#)



Revised Fig. 2
[Click here to download high resolution image](#)

