

Acta Med. Okayama, 2014
Vol. 68, No. 1, pp. 53-56

Copyright©2014 by Okayama University Medical School.

Acta Medica
Okayama

<http://escholarship.lib.okayama-u.ac.jp/amo/>

Case Report

Long-term Observation of Osteomalacia Caused by Adefovir-Induced Fanconi's Syndrome

Tomohiro Terasaka^a, Eijiro Ueta^a, Hiroataka Ebara^a, Koichi Waseda^a,
Yoshihisa Hanayama^a, Akinobu Takaki^b, Tomoko Kawabata^c, Hitoshi Sugiyama^c,
Ko Hidani^d, and Fumio Otsuka^{a*}

Departments of ^aGeneral Medicine, ^bGastroenterology and Hepatology, and ^cMedicine and Clinical Science,
Okayama University Graduate School of Medicine, Dentistry and Pharmaceutical Sciences, Okayama 700-8558, Japan, and
^dDepartment of Orthopedics, National Hospital Organization Fukuyama Medical Center, Fukuyama, Hiroshima 720-8520, Japan

A 64-year-old man suffering polyarthralgia and bone pain was referred to our hospital. Renal dysfunction, hypophosphatemia and increased levels of bone alkaline phosphatase were found. The patient's serum creatinine level had gradually increased after the initiation of adefovir dipivoxil administration for hepatitis B. In agreement with multifocal uptakes of bone scintigraphy, iliac bone biopsy revealed an abnormal increase in osteoid tissues. Reducing the dose of adefovir and initiating the administration of eldcalcitol were effective for reducing proteinuria and glucosuria, and for ameliorating bone pain with an increase in serum phosphate level. This case first showed a clinical course of hypophosphatemic osteomalacia caused by secondary Fanconi's syndrome for 8 years after adefovir administration. Early diagnosis is important for the reversibility of bone damage and for a better renal prognosis.

Key words: adefovir dipivoxil (ADV), eldcalcitol, Fanconi's syndrome, hypophosphatemia, osteomalacia

We present here an interesting case of severe bone pain, polyarthralgia and immobility due to osteomalacia caused by drug-induced renal tubular dysfunction. There has been a recent increase in reports regarding bone damage due to renal complications of anti-viral drugs [1-3], however, to the best of our knowledge, no detailed clinical course of the progress of renal dysfunction and bone malformation has yet been described. We present here a case of systemic pain due to hypophosphatemic osteomalacia caused by adefovir dipivoxil (ADV)-related renal insufficiency, in which laboratory data for 8 years after the

initiation of ADV were successfully pursued.

Case Presentation

A 64-year-old Japanese man who had suffered systemic polyarthralgia and bone pain was referred to our hospital (Fig. 1, upper panel). The cause of his persistent back pain had not been determined by regular checkups at other hospitals. The patient had been taking oral ADV (10 mg/day) and lamivudine (100 mg/day) to treat chronic hepatitis due to hepatitis B virus (HBV) hepatitis B surface antigen (HBsAg) was positive but neither HBs-antibody nor HBV-DNA was detected in his serum at the first visit. A detailed medical interview revealed that his lower back pain had deteriorated over a 3-year period of ADV admin-

Received August 8, 2013; accepted October 8, 2013.

*Corresponding author. Phone: +81-86-235-7342; Fax: +81-86-222-7345
E-mail: fumiotsu@md.okayama-u.ac.jp (F. Otsuka)

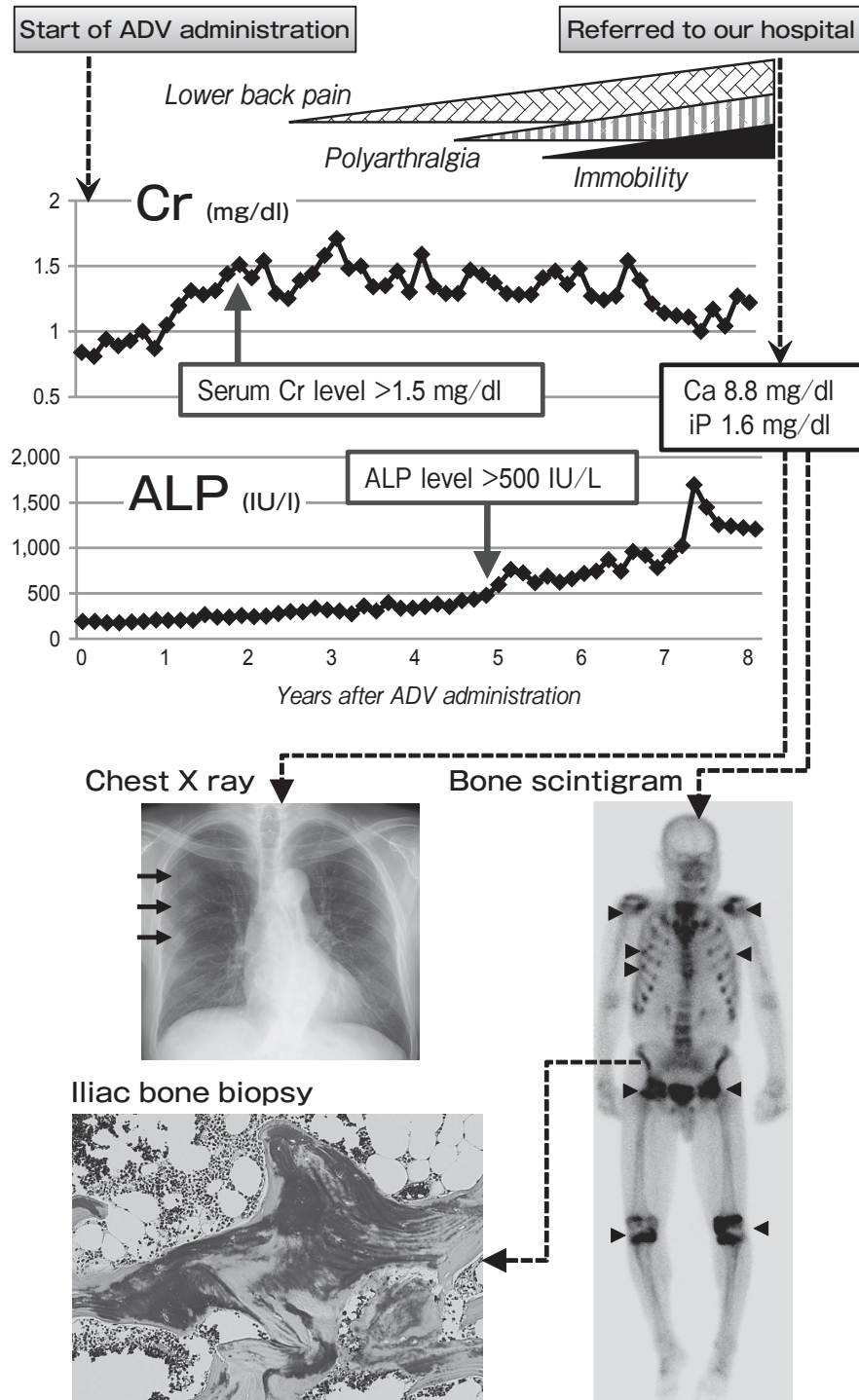


Fig. 1 Clinical course after ADV treatment. Chest X-ray, bone scintigraphy and pathological findings of iliac bone biopsy with Villanueva-Goldner staining are shown.

istration. He had also suffered bilateral hip joint pain, and the area of continuing pain had been spreading to his whole body including his shoulders, thorax, hip and knee joints. Gait disturbance and systemic polyarthralgia had also gradually progressed over the 3-year period. When the patient visited our hospital, his symptoms suggested ankylosing spondylitis since it was difficult for him to stretch his back and he was unable to bend his back even slightly due to his severe polyarthralgia and continuing bone pain. A laboratory workup showed renal dysfunction (creatinine, 1.29 mg/dl; normal: 0.6–1.1; and estimated glomerular filtration rate, 44.5 ml/min/1.73 m²), hypophosphatemia (1.4 mg/dl, normal: 2.5–4.6), but normocalcemia (8.8 mg/dl, normal: 8.6–10.1), and increased levels of alkaline phosphatase (ALP; 1,314 IU/l, normal: 110–360) and bone ALP (BAP; 116 IU/l, normal: 13–34) (Fig. 1, *upper panel*). Serum C-reactive protein, rheumatoid factor, anti-cyclic citrullinated peptide antibody and anti-nuclear factor were negative, and no consumption of serum complements was shown. The patient's level of renal tubular reabsorption of phosphate (%TRP) was extremely low at 30.9% (normal: 82–95%), indicating impairment of renal absorption of inorganic phosphate. Considering the complication of bone-related endocrine disorders that induce hypophosphatemia, we measured serum levels of intact parathyroid hormone (PTH; 59 pg/ml, normal: 10–65) and PTH-related peptide (PTHrP; < 1.1 pg/ml, normal: < 1.1), both of which were within normal range. Of note, the patient's serum 1,25-dihydroxyvitamin D3 level was found to be low at 14.0 pg/ml (normal: 20–60), possibly due to damage of the renal proximal tubules. Arterial blood gas analysis showed severe metabolic acidosis (pH, 7.27; HCO₃⁻, 16.4 mmol/l; serum potassium, 3.7 mmol/l; base excess, -9.6 mmol/l). Tumor-induced hypophosphatemia was excluded because of the suppression of serum fibroblast growth factor-23 (FGF-23; < 1.0 pg/ml, normal: 10–50). Urinalysis showed alkaluria (pH 7.5), proteinuria (3+), glucosuria (3+) and excess excretion of amino acids (Val, 4,002 μmol/day; Ala, 16,916 μmol/day; Leu, 1,551 μmol/day). Urinary levels of N-acetylglucosaminidase (26.4 U/day) and β₂-microglobulin (89.6 mg/day) were also increased. A chest X-ray revealed pseudofractures of the right ribs (Fig. 1, arrows in *lower panel*), and bone scintigraphy using ^{99m}Tc-hydroxymethylene diphosphonate showed multi-

focal uptake in both scapulae, ribs, femoral necks and knee joints, indicating the presence of metabolic bone disease (Fig. 1, arrowheads in *lower panel*). Laboratory data including the patient's past data showed that his serum creatinine level had gradually increased over a period of 8 years after the initiation of oral ADV administration (Fig. 1, *upper panel*). Together with the advent of bone pain, the patient's serum ALP level was also enhanced. For the diagnosis of bone malformation, iliac bone biopsy was performed, and an abnormal increase in osteoid tissues was revealed by Villanueva-Goldner staining (Fig. 1, *lower panel*). Based on these clinical and pathological findings, we made a diagnosis of hypophosphatemic osteomalacia caused by secondary Fanconi's syndrome possibly due to ADV. Since the complete cessation of ADV administration might cause a recurrence of acute hepatitis, we reduced the patient's daily dose from 10 mg to 5 mg based on a previous report showing that ADV reduction improved Fanconi's syndrome [4]. After this reduction, the patient's proteinuria and glucosuria gradually improved over a period of 6 months. For osteomalacia with accompanying hypophosphatemia, the patient was treated with oral eldcalcitol and bicarbonate, resulting in an increase in his serum phosphate level (~2.4 mg/dl) and ameliorating his systemic pain and arthralgia for 6 months.

Discussion

Approximately 40% of patients with Fanconi's syndrome are complicated with secondary osteomalacia [5]. Some cases of Fanconi's syndrome are congenital, but most cases are caused by various nephrotoxic agents such as acetazolamide, outdated tetracycline, aminoglycoside antibiotics, valproate, 6-mercaptopurine, streptozotocin, and ifosfamide [5]. Fanconi's syndrome includes dysfunction of the proximal tubular resorption of glucose, phosphate and amino acids in the kidney. ADV is used as an antiviral agent for the treatment of chronic hepatitis B and human immunodeficiency virus (HIV) infection. ADV-induced nephrotoxicity is generally caused by a high dose (60–120 mg/day) of ADV therapy for HIV infection, however, it has recently been reported that the same complication can occur even with low-dose therapy for chronic hepatitis [1–3]. The underlying mechanism seems to be related to the preferential accumulation of

ADV in the proximal tubules via specific organic anion transporters [6] and the resultant depletion of mitochondrial DNA in the proximal tubular epithelium through its replicative inhibition, leading to renal tubular damage [7, 8]. In the present case, we judged that the onset of renal insufficiency occurred approximately 2 years after the commencement of ADV treatment, and the subsequent bone malformation induced by hypophosphatemia appeared after 5 years of ADV treatment. The standard treatment for this complication is the cessation of ADV administration and supplementation of oral phosphate [1–3]. However, in the present case, reducing ADV was effective for inhibiting the progression of renal damage including proteinuria and glucosuria. In addition, the administration of eldcalcitol, which is effective not only for increasing calcium absorption from the gastrointestinal tract but also for inhibiting bone resorption [9, 10], was effective for this bone complication, ameliorating bone pain and increasing the patient's serum phosphate level.

Thus, serum phosphorus and ALP levels should be examined in patients with systemic bone pain and/or persistent polyarthralgia, and inorganic phosphate and ALP levels, as well as urinalysis and renal function, should be regularly monitored in patients being treated with ADV. With respect to Fanconi's syndrome caused by ADV, abnormalities in urinalysis including those in urinary pH, glucose and protein are most likely to be the earliest manifestations. Early diagnosis of this complication through regular urinary checkups is extremely important for the reversibility of bone damage and for a better renal prognosis.

Acknowledgments. The authors would like to thank Dr. Akemi Ito (Ito Bone Histomorphometry Institute, Niigata, Japan) for pathological diagnosis and important suggestions regarding the bone biopsy specimen.

References

1. Jung YK, Yeon JE, Choi JH, Kim CH, Jung ES, Kim JH, Park JJ, Kim JS, Bak YT and Byun KS: Fanconi's syndrome associated with prolonged adefovir dipivoxil therapy in a hepatitis b virus patient. *Gut Liver* (2010) 4: 389–393.
2. Wong T, Girgis CM, Ngu MC, Chen RC, Emmett L, Archer KA and Seibel MJ: Hypophosphatemic osteomalacia after low-dose adefovir dipivoxil therapy for hepatitis b. *J Clin Endocrinol Metab* (2010) 95: 479–480.
3. Tanaka M, Setoguchi T, Ishidou Y, Arishima Y, Hirotsu M, Saitoh Y, Nakamura S, Kakoi H, Nagano S, Yokouchi M, Kamizono J and Komiya S: Pathological femoral fractures due to osteomalacia associated with adefovir dipivoxil treatment for hepatitis b: A case report. *Diagn Pathol* (2012) 7: 108.
4. Tamori A, Enomoto M, Kobayashi S, Iwai S, Morikawa H, Sakaguchi H, Habu D, Shiomi S, Imanishi Y and Kawada N: Add-on combination therapy with adefovir dipivoxil induces renal impairment in patients with lamivudine-refractory hepatitis b virus. *J Viral Hepat* (2010) 17: 123–129.
5. Rodriguez Soriano J: Renal tubular acidosis: The clinical entity. *J Am Soc Nephrol* (2002) 13: 2160–2170.
6. Cihlar T, Lin DC, Pritchard JB, Fuller MD, Mendel DB and Sweet DH: The antiviral nucleotide analogs cidofovir and adefovir are novel substrates for human and rat renal organic anion transporter 1. *Mol Pharmacol* (1999) 56: 570–580.
7. Tanji N, Tanji K, Kambham N, Markowitz GS, Bell A and D'Agati V D: Adefovir nephrotoxicity: Possible role of mitochondrial DNA depletion. *Hum Pathol* (2001) 32: 734–740.
8. Cundy KC, Bidgood AM, Lynch G, Shaw JP, Griffin L and Lee WA: Pharmacokinetics, bioavailability, metabolism, and tissue distribution of cidofovir (hpmpc) and cyclic hpmpc in rats. *Drug Metab Dispos* (1996) 24: 745–752.
9. Harada S, Mizoguchi T, Kobayashi Y, Nakamichi Y, Takeda S, Sakai S, Takahashi F, Saito H, Yasuda H, Udagawa N, Suda T and Takahashi N: Daily administration of eldcalcitol (ed-71), an active vitamin d analog, increases bone mineral density by suppressing rankl expression in mouse trabecular bone. *J Bone Miner Res* (2012) 27: 461–473.
10. Kikuta J, Kawamura S, Okiji F, Shirazaki M, Sakai S, Saito H and Ishii M: Sphingosine-1-phosphate-mediated osteoclast precursor monocyte migration is a critical point of control in antibone-resorptive action of active vitamin d. *Proc Natl Acad Sci U S A* (2013) 110: 7009–7013.