

Two Cases of Acrodermatitis Continua of Hallopeau Associated with Generalized Arthritis

INTRODUCTION

Acrodermatitis continua of Hallopeau (ACH), a variant of pustular psoriasis, chiefly affects distal parts of the hands and feet (1,2). Arthritis occasionally occurs in psoriasis, including pustular psoriasis, as psoriatic arthritis (3), but it is uncommon in ACH. Here, we report on two cases of ACH with arthritis that was improved by infliximab together with methotrexate as well as salazosulfapyridine. As arthritis is refractory to conventional therapies, our cases could provide a clue to clarifying therapies for ACH.

CASE REPORTS

Case 1

A 29-year-old man visited our hospital with polyarthralgia chiefly at the fingers and big toes. Four years

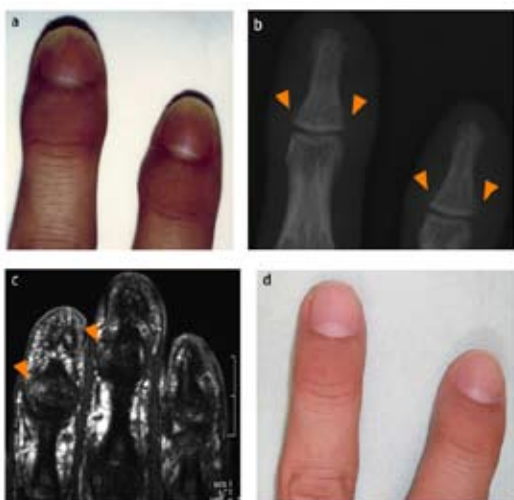


Figure 1. (a) Clinical features included edematous erythema on the acral parts of the fingers, pustules within the nail bed, and partial shedding of the nail plate; (b) bone x-ray image: arrows show bone erosion; (c) magnetic resonance imaging: arrows show the enhancement; (d) clinical feature: improvement of skin manifestation after the administration of infliximab and methotrexate.

previously, he found cloudy alterations in the nail of the left middle finger. Two years later, distal interphalangeal joints of the bilateral hands became swollen, reddish and painful, together with pustular formation under the nail plate. The nails became deformed and discolored gradually. Reddish eruptions had not appeared over the trunk and extremities except for acral regions. On the first visit, distal interphalangeal joints of the hands and metatarsophalangeal joints of the big toes were swollen left to right asymmetrically, together with onycholysis and subungual hyperkeratosis (Fig. 1a). Erythematous changes were diffusely distributed on peripheral regions of the fingers and toes. Routine hematologic and immunologic examinations were normal. Bone x-rays showed small erosions at the base of the distal phalanx (Fig. 1b). Magnetic resonance imaging for evaluation of their activities revealed enhancement at the base of the distal phalanx (Fig. 1c). Based on a diagnosis of ACH, the patient was treated with topical clobetasol propionate 0.05% ointment and oral cyclosporin (5 mg/body weight kg/day) for several months, which improved the cutaneous manifestation, but not arthralgia. In addition, arthritis developed in his right elbow. Then, instead of corticosteroid and cyclosporin, we administered intravenous infliximab at a dose of 5 mg/kg on weeks 0, 2, and 6, and every 8 weeks, together with oral methotrexate 6 mg weekly. His arthralgia disappeared immediately, and the joint swelling and nail deformity gradually improved (Fig. 1d).

Case 2

A 55-year-old woman visited our hospital with polyarthralgia chiefly at the fingers, big toes, knees and ankles. Three months before the first visit, she had bilateral knee pain together with swelling. In a short time, painful swelling had also developed in the fingers and ankles, which was followed immediately by nail deformity of the bilateral big toes with swelling and purulent discharge around the nails. Previ-

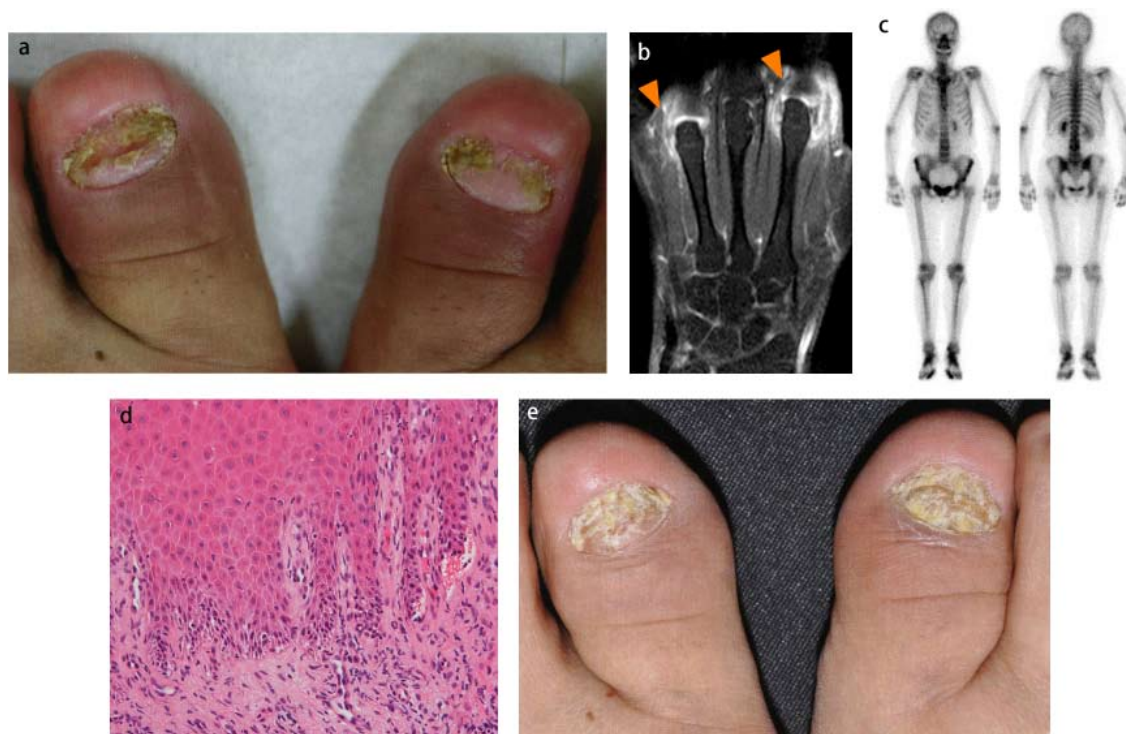

Figure 2. (a) Clinical features: nail destruction with paronychia erythema on the bilateral big toes; (b) magnetic resonance imaging: arrows show synovitis in metatarsophalangeal joints; (c) bone scintigraphy showing multiple uptakes; asymmetric involvement of the distal and proximal interphalangeal joints; (d) histopathologic findings of erythema on the big toes: elongation of rete ridges with exocytosis of neutrophils and lymphocytes HE; x200; (e) clinical feature: improvement of skin manifestation after the administration of salazosulfapyridine with topical tacrolimus.

ously, reddish eruptions had not appeared except for acral regions. Examination showed yellowish-white discolored nails with atrophy in the bilateral big toes and erythema in the paronychia regions (Fig. 2a). Purulent discharge was seen from the subungual space and the surrounding erythema. Routine hematologic and immunologic examinations were normal except for an increase in antinuclear antibody, $\times 160$. Fungal and bacterial cultures from the pustules and nails were negative. While bone x-rays showed no abnormalities, magnetic resonance imaging revealed synovitis in the metatarsophalangeal joints of the left index and ring fingers (Fig. 2b). In addition, bone scintigraphy indicated increased uptakes in multiple joints (Fig. 2c). A biopsy from the toe skin showed elongation of rete ridges as well as dermal infiltration of neutrophils and lymphocytes, extending to the epidermis (Fig. 2d). The patient was treated with oral salazosulfapyridine 1000 mg daily as well as an occlusive dressing of tacrolimus ointment, which alleviated the cutaneous and joint symptoms (Fig. 2e).

DISCUSSION

Acrodermatitis continua of Hallopeau usually develops on the distal portion of the digits with pustulation

of the nail bed/matrix, which leads to onychodystrophy (1). We diagnosed these two cases as ACH, based on dystrophic nails surrounded by erythema with the history of relapsing periungual and subungual pustules as well as no eruptions except for acral regions.

Whereas arthritis is uncommon in ACH, these two cases showed polyarthritis chiefly distributed to the acral joints. However, its occurrence is not surprising because ACH is usually considered a variant of pustular psoriasis (2). Inflammation may extend from the nail folds and beds to the joints underneath. In addition, articular inflammation does not always localize to acral joints, as our two cases. The image findings in our case 1 were consistent with those of enthesitis. Enthesitis is a hallmark finding for psoriatic arthritis. The detection of enthesitis is facilitated by the use of magnetic resonance imaging and bone scintigraphy. They can evaluate not only the presence of enthesitis, but also its activities, which are enthesal-related bone formations and erosions (4).

Therapeutic guidelines for ACH with arthritis do not seem to be established. ACH is frequently recalcitrant to topical therapies using steroid, vitamin D₃ or tacrolimus (5,6). In case 1, oral cyclosporin with topical

steroid was effective for the skin lesions, but not for arthritis. Cyclosporin is usually not potently effective for arthralgia in psoriatic arthritis, and arthritis seems to be more refractory to conventional therapies than cutaneous manifestations (7). Based on the concept that ACH is a variant of pustular psoriasis, arthritis accompanied by ACH should be improved by therapies for psoriatic arthritis, including salazosulfapyridine, methotrexate and tumor necrosis factor- α (TNF- α) inhibitors (8). TNF- α inhibitors have been reported to provide satisfactory control of ACH (9). On the other hand, the clinical condition of ACH is occasionally refractory to TNF- α inhibitors (10,11). In our case, intravenous infliximab combined with methotrexate was effective for arthritis and nail lesions in ACH. Based on the clinical manifestations including therapeutic responses, ACH with generalized arthritis would have similar pathological condition to psoriatic arthritis.

References

- Sehgal VN, Verma P, Sharma S, Srivastava G, Aggarwal AK, Rasool F *et al.* Acrodermatitis continua of Hallopeau: evolution of treatment options. *Int J Dermatol* 2011;50:1195-211.
- Gluckman SJ, Heyman W. Diagnosis: acrodermatitis continua of Hallopeau. *Clin Infect Dis* 2001;32:431, 505.
- Gladman DD. Psoriatic arthritis from Wright's era until today. *J Rheumatol Suppl* 2009;83:4-8.
- Anandarajah A. Imaging in psoriatic arthritis. *Clin Rev Allergy Immunol* 2013;44:157-65.
- Emtestam L, Weden U. Successful treatment for acrodermatitis continua of Hallopeau using topical calcipotriol. *Br J Dermatol* 1996;135:644-6.
- Wilsmann-Theis D, Hagemann T, Dederer H, Wenzel J, Bieber T, Novak N. Successful treatment of acrodermatitis continua suppurativa with topical tacrolimus 0.1% ointment. *Br J Dermatol* 2004;150:1194-7.
- Gul U, Gonul M, Kilic A, Erdem R, Cakmak SK, Gunduz H. Treatment of psoriatic arthritis with etanercept, methotrexate, and cyclosporin A. *Clin Ther* 2006;28:251-4.
- Menter A, Gottlieb A, Feldman SR, Van Voorhees AS, Leonardi CL, Gordon KB *et al.* Guidelines of care for the management of psoriasis and psoriatic arthritis: Section 1. Overview of psoriasis and guidelines of care for the treatment of psoriasis with biologics. *J Am Acad Dermatol* 2008;58:826-50.
- Puig L, Dauden E, Carrascosa JM. Commentary on European and British guidelines for the treatment of psoriasis. *Actas Dermosifiliogr* 2010;101:285-90.
- Thielen AM, Barde C, Marazza G, Saurat JH. Long-term control with etanercept of a severe acrodermatitis continua of Hallopeau refractory to infliximab. *Dermatology* 2008;217:137-9.
- Adişen E, Oztaş M, Gürer MA. Lack of efficacy of etanercept in acrodermatitis continua of Hallopeau. *Int J Dermatol* 2007;46:1205-7.

Hiroshi Okuno¹, Ken Ogura¹, Ryuhei Okuyama², Eiji Itoi¹

¹Department of Orthopedic Surgery, Tohoku University Graduate School of Medicine, ²Department of Dermatology, Shinshu University School of Medicine, Sendai, Japan

Corresponding author:

Hiroshi Okuno
Department of Orthopedic Surgery
Tohoku University Graduate School of Medicine
1-1 Seiryō-machi, Aoba-ku
Sendai, 980-8574
Japan
okuno@med.tohoku.ac.jp

Received: December 10, 2012

Accepted: November 15, 2013