

ID Design Press, Skopje, Republic of Macedonia
 Open Access Macedonian Journal of Medical Sciences. 2019 Mar 30; 7(6):903-907.
<https://doi.org/10.3889/oamjms.2019.215>
 eISSN: 1857-9655
Basic Science



Comparison of the Microwave-Heated Ziehl-Neelsen Stain and Conventional Ziehl-Neelsen Method in the Detection of Acid-Fast Bacilli in Lymph Node Biopsies

Gehan Mohammed Ahmed¹, Ali Seed Ahmed Mohammed¹, Albadawi Abdulbagi Taha¹, Ahmad Almatroudi², Khaled S. Allemailem^{2,3}, Ali Yousif Babiker², Mohamed Alkhatim Alsammani^{4,5*}

¹Department of Medical Laboratory Sciences, University of Gezira, Wad Medani, Sudan; ²Department of Medical Laboratories, College of Applied Medical Sciences, Qassim University, Buraidah, Saudi Arabia; ³Department of Histopathology and Cytology, College of Medical Laboratory Sciences, University of Sciences and Technology, Omdurman, Sudan; ⁴Department of Obstetrics and Gynecology, College of Medicine, Qassim University, Buraidah, Saudi Arabia; ⁵Department of Obstetrics and Gynecology, College of Medicine, University of Bahri, Khartoum, Sudan

Abstract

Citation: Ahmed GM, Mohammed AS, Taha AA, Almatroudi AA, Allemailem KS, Babiker AY, Alsammani MA. Comparison of the Microwave-Heated Ziehl-Neelsen Stain and Conventional Ziehl-Neelsen Method in the Detection of Acid-Fast Bacilli in Lymph Node Biopsies. Open Access Maced J Med Sci. 2019 Mar 30; 7(6):903-907. <https://doi.org/10.3889/oamjms.2019.215>

Keywords: Ziehl-Neelsen; Conventional staining; Tuberculosis; Lymphadenitis

***Correspondence:** Mohamed Alkhatim Alsammani. Department of Obstetrics and Gynecology, Qassim University, College of Medicine, Buraydah, Saudi Arabia; Bahri University, Khartoum, Sudan. E-mail: m_sammani@yahoo.com

Received: 30-Dec-2019; **Revised:** 05-Mar-2019; **Accepted:** 06-Mar-2019; **Online first:** 24-Mar-2019

Copyright: © 2019 Gehan Mohammed Ahmed, Ali Seed Ahmed Mohammed, Albadawi Abdulbagi Taha, Ahmad Almatroudi, Khaled S. Allemailem, Ali Yousif Babiker, Mohamed Alkhatim Alsammani. This is an open-access article distributed under the terms of the Creative Commons Attribution-NonCommercial 4.0 International License (CC BY-NC 4.0)

Funding: This research did not receive any financial support

Competing Interests: The authors have declared that no competing interests exist

BACKGROUND: Tuberculosis is a chronic inflammatory disease with lymphadenopathy being the most common extra-pulmonary manifestation. The conventional Ziehl-Neelsen method plays an essential role in the diagnosis of tuberculosis; however, it has a low sensitivity in detecting acid-fast bacilli.

AIM: The present study emphasises the role of the microwave-heated method (modified Ziehl-Neelsen) over conventional Ziehl-Neelsen stain and to set at the best condition for irradiation.

MATERIAL AND METHODS: The study included 90 patients with clinically suspected tuberculous lymphadenopathy who were referred to the Department of Pathology at Omdurman Military Hospital, Sudan. Demographic data such as age, sex, and site of swelling were documented for each patient. Specimens were stained with conventional Ziehl-Neelsen, fluoresce and the modified methods.

RESULTS: Patient's age ranged from 20 to 70 year. Of the total 90 cases with clinically suspected tuberculous lymphadenopathy, 18 cases were positive for AFB in conventional Ziehl-Neelsen method giving a sensitivity of 13.3%, while in microwave-heated method 82 cases of TB were detected positive for AFB yielded sensitivity and specificity of 97.6% and 85.7%, respectively, and positive and negative predictive values of 98.8% and 75.0% respectively compared to fluorescence methods.

CONCLUSION: In the present study, the microwave-heated Ziehl-Neelsen method, was found to have sensitivity and specificity of 97.6% and 85.7%, respectively which matches the fluorescence technique. It has specificity in detecting lymph node tuberculosis that makes it superior over all other modified methods. However, the availability and cost-effectiveness might limit the use of fluorescence in routine practice. Furthermore, the study set the best staining temperature is provided at power 1 level (60 w) for 1.5 minutes.

Introduction

Tuberculous lymphadenitis is a chronic, specific granulomatous infection of the lymph node with caseation necrosis, caused by *Mycobacterium tuberculosis* and less frequently by *Mycobacterium bovis*. Tuberculosis remains a major global public health problem. The average incidence of new cases worldwide is 26,000 and the global treatment success rate of 83%, similar to recent years. Globally, the incidence of tuberculosis is falling at about 2% per

year [1].

Lymphadenopathy is the most common form of extra-pulmonary TB. Tuberculous lymphadenitis accounts for nearly 35% of extra-pulmonary TB. The diagnosis of tuberculous lymphadenitis can be morphologically by fine needle aspiration cytology (FNAC) of the lymph node [2].

The diagnosis of tuberculous lymphadenitis poses great challenge because it mimics other pathologic processes. The diagnosis of TB often requires a tissue biopsy and staining for acid-fast

bacilli (AFB). Newer advance and expensive tests such as polymerase chain reaction (PCR) help obtain an early diagnosis but, it is costly to be routinely used in developing countries [3]. *Conventional Ziehl-Neelsen (ZN) stain* is a rapid, useful and practical *method* for detecting *acid-fast bacilli (AFB)*. However, the major disadvantage of *Conventional Ziehl-Neelsen* is its low sensitivity, ranging from 20% to 43 % [4], [5].

The cell wall of Mycobacterium possesses mycolic acid that makes it impervious to staining by aqueous staining solutions. Heating the slide helps to soften the mycolic acid on the bacterial cell wall as in conventional ZN stain. Many previous studies focused on improving the sensitivity of *conventional Ziehl-Neelsen using different techniques*. Controlled heating can be provided with a microwave oven. There is scant literature on microwave method.

The few published literature on the microwave- heated methods concentrated on sputum smear. The diagnosis of tuberculous lymphadenitis posed great challenged for the practitioner. Thus, the present study emphasized the role of the microwave-heated method (modified Ziehl-Neelsen) over conventional Ziehl-Neelsen stain and to set at the best condition for irradiation in diagnosing tuberculous lymphadenitis.

Methods and Materials

The studies comprised 90 cervical lymph node specimens obtained from patients with clinically diagnosed tuberculous lymphadenitis. The specimens were obtained by excision biopsy. Tissues specimens were referred to the Department of Pathology in the Military Hospital Omdurman, Sudan between 2016 and 2017. The cases comprised both gender and all age group. The study was approved by the Ethics committee board of University of Gazira and Ministry of Health Sudan. Demographic data were collected from patients' case notes.

Inclusion criteria: All patients with lymph node blocks diagnosed as tuberculosis, suggestive or highly suggestive tuberculosis (T.B) and not on antituberculous treatment before specimen result.

Exclusion criteria: Patients diagnosed as tuberculosis and on antitubercular therapy.

Sample preparations

Two hundred seventy paraffin wax sections from the ninety lymph nodes tissues (3 specimens from each lymph node tissues) each with a thickness of 3-5 microns by using rotary microtome were prepared.

All sections of lymph nodes paraffin were mounted on clean glass slides (Cat NO.: 7.105, Size: 25.4X76.2 mm, Thick: 1-1.2 mm) and stained as follows:

Group (A): control cases which include 90 paraffin wax sections thickness 3-5 mm applied fluorescence dyes Auramine-O Rhodamine.

Group (B): 90 paraffin wax sections stained routinely by classical Ziehl-Neelsen stain heat carbol fuchsin and differentiated by 1% acid alcohol.

Group (C): which included 90 slides stained by modified Ziehl-Neelsen stain under microwave oven level 1 (60 w) 1.5 min.

Microwave Oven

A domestic oven (Sharp model-20AS (W)) with a maximum output of 600 watts, four power settings, and a digital timer was used.

Steps for conventional Ziehl-Neelsen Preparations [6]

1. Deparaffinized and rehydrated through graded alcohol to distilled water.
2. Flood the sections with freshly carbol fuchsin and heated to steaming with intermediate flaming 15 minutes 56-60°C.
3. Wash in tap water 2 minutes.
4. Differentiation with 1% acid alcohol 3 minutes.
5. Wash in tap water to remove the excess of the acid counter.
6. Stain in methylene blue 15 seconds.
7. Dehydrate clear and mounted with DPX.

Steps for fluorescence techniques Preparations [6]

1. Deparaffinize and rehydrated through graded alcohol to D.W.
2. Stain, preheated (60°C) fluorescence dyes for 10 minutes (Auramine-rhodamine-B).
3. Wash in tap water.
4. Differentiation with 0.5% acid alcohol (0.5 ml coc.HCL +99.5 70% alcohol).
5. Wash in tap water 2 minutes.
6. Eliminate the background fluorescent by 5% potassium permanganate for 2 minutes.
7. Wash in tap water.
8. Mount in aqueous mounting media.

Steps for microwave technique preparations

1. Deparaffinize and hydrated the slide to filter water.
2. Placed slide in carbon fuchsin in glass Coplin jar vol. 25 ml and microwave at power 1 level (60 w) for 1.5 minutes dipped the slide up & down several times and remained in warm solutions 15 minutes.
3. Washed in running tap water to removes the excess of stain.
4. Differentiation with 3% acid alcohol until sections became pale pink.
5. Washed in running tap water 1 minute 2 changes in D.W to remove excess of acid.
6. Counterstain the background with methylene blue 15 seconds.
7. Washed in water rinsed in 95% absolute alcohol 2 changes.
8. Cleared in 3 to 4 change in xylene.
9. Mounted media DPX.

Results

A total of 90 excised cervical lymph nodes diagnosed as tuberculous lymphadenitis were included in the present study.

Patient's ages ranged from 20 to 80 years. The majority (37.8%) of subjects' age ranged from 20-40 years, followed by age group of 61-80 years (34.4%), while middle age represented the minority of cases (27.8%). Females gender preponderance was noted accounting for 66.7% (60/90) with a male to female ratio of 2:1, Table1.

Table 1: Frequency of age and gender distribution

Age group	Frequency	Per cent
20-40	34	37.8
41-60	25	27.8
61-80	31	34.4
Sex		
Females	60	66.7
Males	30	33.3

Data presents as number (%).

Of the 90 specimens, tissue positivity for AFB on the conventional ZN method was 20% (18/90), the positivity increased to 91.1% (83/90) on the modified ZN method. The correlation between the conventional ZN method and the modified ZN method (Table 2) showed statistical significance ($\chi^2 = 108.542$, $df = 1$, $P < 0.00$).

Table2: Comparison of detection rate between classical Z.N, Modified Z.N with microwave and fluorescence technique

Tests	Result		Total
	Positive (%)	Negative (%)	
Classical	18 (20)	72 (80)	90
Modification	82 (91.1)	8 (8.9)	90
Fluorescence	83 (92.2)	7 (7.8)	90

P > 0.0001; Data presents as number (%).

Figures 1 showed the rod shape acid-fast bacilli (arrow) in lymph node paraffin wax section by ZN classical method (x 100).



Figure 1: Rod shape Acid alcohol fast bacilli (arrow) in lymph node paraffin wax section by conventional Z.N method (x 100)

Figure 2, showed acid-fast bacilli were easily visualised as fragmented or beaded red rods when it was set at the best condition of 1W and 1.5 min. irradiation (x 1000).




Figure 2: Fragmented or beaded Red rods (A.F.B) arrow seen inside and outside macrophages in modified ZN staining (x1000)

Figure 3 showing acid-fast bacilli in lymph node paraffin wax performed using the fluorescence technique (x1000).

Histopathology diagnosis of the tuberculosis lymph node was based on the criteria proposed by Jain 1999(7) (i) purulent with caseation; caseation with epithelioid cells (ii); only caseation (iii); and (iv) noncaseating with epithelioid cells. All cases in classical ZN method showed granuloma and giant cells no other chronic inflammation cells were demonstrated.

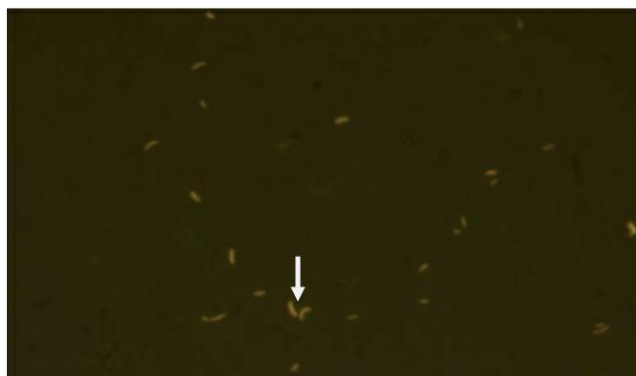


Figure 3: Acid-fast bacilli (Arrow) by Auramine – Rhodamine Fluorescence stain in lymph node paraffin section (x1000)

In the modified Z.N method the majority of histological features were 61(75.3%) granuloma with giant cells, while there were few epithelioid cells 6(7.4%) and gaseous necrosis similar to the finding obtained by fluorescence method Table 3.

Table 3: Comparison of the histopathological features, by classical Z.N, Modified Z.N with microwave and fluorescence technique

Histopathological feature	Classical ZN method (n = 90)	Fluorescence method (n = 90)	Modified ZN method (n = 90)
Epithelioid cells	0	7 (8.4)	6 (7.4)
Granuloma	0	10 (12.1)	10 (12.3)
Granuloma & giant cells	18 (100)	61 (73.5)	61 (75.3)
Gaseous necrosis	0	5 (6)	5 (6.2)
Total positive	18	83	81

Data presents as number (%).

Discussion

This study aimed to evaluate the efficacy of microwave-heated method as an example of an effective method for the diagnosis of acid-fast bacilli in comparison with conventional Ziehl-Neelsen stain. The validation of microwave-heated method based on revealing high sensitivity (97.6% specificity (85.7%) and positive and negative predictive values (98.8%), (75.0%) respectively in comparison with fluorescence techniques as a standard gold method. While the conventional method showed a sensitivity of 13%, this result highlighted the ability of microwave-heated method over the conventional methods that have a poor selectivity in detecting AFB ranging from 20% to 43% [3], [4]. The fluorescence method for the microscopic identification of tubercle bacilli in the present study as a standard gold test showed that 92.2% (83/90) of cases were positive AFB, this result is comparable to a previous study done [8].

It is known that the success of the Mycobacteria staining depends on the degree and stability of temperature at which dye uniformly penetrate the waxy cell wall barrier of the organism

without cell distortion [9]. We attributed the higher detection rate of acid-fast bacilli by the microwave-heated method in the present study to the degree of temperature used to facilitate staining (power 1 level (60 w) for 1.5 minutes). This level of temperature and time frame in this study provided the optimal and the best condition for irradiation compared to heating beneath the slide as in conventional ZN STAIN.

Furthermore, excessive use of phenol in all preparations steps could negatively influence the identification of Mycobacterium leading to removing much of the dye and hence decreasing microscopic efficacy. In this study, phenol is used in only the last step. A previous study was done by Funashima Y [10] and his colleagues exploring the potential use of a microwave to improve microscopic efficacy in identifying AFB in sputum they proposed 600 W and 10-sec irradiation as the best condition.

The present study showed that the higher incidence of TBLA in age group (20-40) and (61-80) than Age (41-60), this finding is similar to the result obtained by Eshete and his colleagues 2011 [11]. Moreover, studies from Somalia and Asia showed that the age group between 25-44 and 45-64 years of age were more likely to have EPTB than young age group 15-24 years. In contrast, in Greenland, the oldest age groups were relatively less likely to be infected compared to the younger age group [12]. The occurrence of tuberculosis at the extreme of age can be explained by a diminution in immune function in these age groups. Globally, it was reported that age greater 65 years is associated with a higher risk of morbidity and mortality due to atypical clinical manifestations which result in a delay in diagnosis and initiation of anti-tuberculous therapy [13].

Tuberculous lymphadenitis was reported to be more common among females than males. Previous studies showed that Asian women and black women are at a higher risk than males for developing tuberculous lymphadenitis [14], [15]. In the present study we reported that female to males ratio was 2:1; this result is similar to study from India that yielded a ration of 2:1 [16]. The present study cannot explain gender preponderance, but some authors suggest socio-dynamics factors as risk for increase incidence among females [17].

In the current study, all subjects were previously diagnosed as having tuberculous lymphadenitis depending on variable histological evidence. According to these histological evidence we calcified the histopathologic patterns into epithelioid histiocytes only, granuloma, granuloma with giant cells, and caseation necrosis. Compared to other histopathology variables, granuloma with giant cells in the present study are considered as strong evidence for establishing the diagnosis of tuberculous lymphadenitis. This study showed that all cases in classical ZN method demonstrated granuloma with giant cells while this was demonstrated in 73.5% and

75.3% in fluorescence and the modified method respectively, Such findings have been previously reported by some authors (Ahmed, Vincent) [18], [19]. However, the absence of a characteristic histopathological picture of TB does not imply the absence of the disease [20].

We conclude that the modified ZN method is more sensitive and specific than the conventional ZN method. Furthermore, it is simple and easy. The modified ZN method greatly improves the diagnostic value of microscopic examination, and it is comparable to fluorescence technique in identifying patients with low-density bacilli. Furthermore, the study set the best staining temperature is provided at power 1 level (60 w) for 1.5 minutes. Further studies are warranted to investigate the diagnostics accuracy of this method in tuberculous lymphadenitis.

References

1. Benjelloun A, Darouassi Y, Zakaria Y, Bouchentouf R, Errami N. Lymph nodes tuberculosis: a retrospective study on clinical and therapeutic features. *Pan Afr Med J*. 2015; 20:65. <https://doi.org/10.11604/pamj.2015.20.65.5782> PMID:26090023 PMCid:PMC4450036
2. Rammeh S, Romdhane E, ArfaouiToumi A, Houcine Y, Lahiani R, Sassi A1, Mardassi H, Ben Salah M, Ferjaoui M. Efficacy of Fine-Needle Aspiration Cytology in the Diagnosis of Tuberculous Cervical Lymphadenitis. *Acta Cytol*. 2018; 62(2):99-103. <https://doi.org/10.1159/000487503> PMID:29587250
3. Winn WC, Allen SD, Janda WM, Koneman EW, Procop GW, Schreckenberger, et al. In Koneman's Color atlas and text book of diagnostic microbiology. 6th ed. Philadelphia: Lippincott Williams and Wilkins; Mycobacteria; 2006:1071–7.
4. Daniel TM. Rapid diagnosis of tuberculosis: Laboratory techniques applicable in developing countries. *Rev Infect Dis*. 1989; 11(Suppl 2):S471–8. https://doi.org/10.1093/clinids/11.Supplement_2.S471 PMID:2652258
5. Balows A, Hausler WJ, Hermann KL, Shadomy HJ. Manual of clinical Microbiology. 5th ed. Washington: D.C: American society for Microbiology, 1991:308–11.
6. Bancroft JD, Stevens A. Theory and practice of histological techniques. Fourth edition, New York: Churchill Livingstone, 1996.
7. Jain M, Majumdar DD, Agarwal K, Bais AS, Choudhury M. FNAC as a diagnostic tool in pediatric head and neck lesions. *Indian Pediatr*. 1999; 36:921–3. PMID:10744873
8. Sule P, Tilvawala R, Behinaein P, Walkup GK, Cirillo JD. New directions using reporter enzyme fluorescence (REF) as a tuberculosis diagnostic platform. *Tuberculosis (Edinb)*. 2016; 101S:S78-S82. <https://doi.org/10.1016/j.tube.2016.09.009> PMID:27729258 PMCid:PMC5183490
9. Gopalkrishna Bhat K, Bhat G. Simple cold staining method for acid-fast bacilli. *Trop Doct*. 2000; 30(4):224. <https://doi.org/10.1177/004947550003000414> PMID:11075657
10. Funashima Y, Kato K, Narita T, Hanaiwa H, Akiwa M, Sekiguchi JI, Nagasawa Z, Sugahara K, Miyamoto H. Utility of the Rapid Staining with the Use of Microwave for Detection of Genus Mycobacterium. *Rinsho Biseibutsu Jinsoku Shindan Kenkyukai shi= JARMAM: Journal of the Association for Rapid Method and Automation in Microbiology*. 2017; 27(1):33-41. PMID:28274129
11. Eshete A, Zeyinudin A, Ali S, Abera S, Mohammed M. M. tuberculosis in Lymph Node Biopsy Paraffin-Embedded Sections. *Tuberc Res Treat*. 2011; 2011:127817. <https://doi.org/10.4269/ajtmh.2011.10-0630> PMID:21813849 PMCid:PMC3144827
12. Zhang X1, Andersen AB, Lillebaek T, Kamper-Jørgensen Z, Thomsen VØ, Ladefoged K, et al. Effect of sex, age, and race on the clinical presentation of tuberculosis: a 15-year population-based study. *Am J Trop Med Hyg*. 2011; 85(2):285-90. <https://doi.org/10.1093/ajtmh.2011.10-0630> PMID:21813849 PMCid:PMC3144827
13. Rajagopalan S. Tuberculosis and aging: a global health problem. *Clin Infect Dis*. 2001; 33(7):1034-9. <https://doi.org/10.1086/322671> PMID:11528577
14. Carrol ED, Clark JE, Cant AJ. Non-pulmonary tuberculosis. *Paediatric Respiratory Reviews*. 2001; 2(2):113-9. <https://doi.org/10.1053/prrv.2000.0118> PMID:12531057
15. Polesky A, Grove W, Bhatia G. Peripheral tuberculous lymphadenitis: epidemiology, diagnosis, treatment, and outcome. *Medicine*. 2005; 84(6):350-62. <https://doi.org/10.1097/01.md.0000189090.52626.7a> PMID:16267410
16. Purohit MR, Mustafa T, Mørkve O, Sviland L. Gender differences in the clinical diagnosis of tuberculous lymphadenitis — a hospital-based study from Central India. *Int J Infect Dis*. 2009; 13(5):600-5. <https://doi.org/10.1016/j.ijid.2008.06.046> PMID:19111495
17. Mohammad Shah Kamal, Md. Hafiz Ehsanul Hoque, Fazle Rabbi Chowdhury, and Rubina Farzana. Cervical Tuberculous Lymphadenitis: Clinico-demographic Profiles of Patients in a Secondary Level Hospital of Bangladesh. *Pak J Med Sci*. 2016; 32(3):608–612. PMID:27375699 PMCid:PMC4928408
18. Ahmed HG, Nassar AS, Ginawil. Screening for tuberculosis and its histological pattern in patients with enlarged lymph node. *Patholog Res Int*. 2011; 2011:417635. <https://doi.org/10.4061/2011/417635>
19. Vincent BY, William AK, Allan HG. Blueprints Medicine, Blackwell. 3rd edition, 2003.
20. Narayana Reddy RA, Narayana SM, Shariff S. Role of fine-needle aspiration cytology and fluid cytology in extra-pulmonary tuberculosis. *Diagn Cytopathol*. 2013; 41(5):392-8. <https://doi.org/10.1002/dc.22827> PMID:22351190