

## The first report on epicardial cavernous hemangioma in farmed sturgeon, *Acipenser baerii*, a microscopic survey

Rezaie A.<sup>1\*</sup>; Alishahi M.<sup>1</sup>; Tulaby Dezfuly Z.<sup>1</sup>

Received: November 2016

Accepted: July 2017

1-Faculty of veterinary medicine, Shahid Chamran University of Ahvaz, Ahvaz, Iran.  
\*Corresponding author's Email: a.rezaie@scu.ac.ir

**Keywords:** Cavernous hemangioma, Epicardium, Sturgeon, *Acipenser baerii*

### Introduction

Haemangioma is a benign tumor of vascular endothelial cells or their progenitors. This tumor is common in dogs and rare in cats, horses and other domestic animals (Goldschmidt and Hendrick, 2002). In dogs, hemangiomas are typically benign and solitary that are often formed in the dermis of the skin, while hemangiosarcomas are regularly present as disseminated tumors that involve the spleen, heart, lung, liver, soft tissues of the trunk and extremities (Brown, 1985).

Hemangioma may be histologically classified as capillary, cavernous, infiltrative hemangioma, arteriovenous hemangioma, granulation tissue type hemangioma, spindle cell hemangioma, solar induced dermal hemangioma, angiokeratomas and angioliopomas (Gross *et al.*, 2007). Rare occurrences of capillary, cavernous haemangiomas,

haemangioendotheliomas and haemangio-endotheliosarcomas affecting integument and visceral organs have been recorded in fish from the USA by Harshbarger (1969).

Certain neoplasms affecting fishes have been related with oncogenic viruses, parasites, and environmental contaminants, while relationship between environmental contaminants and fish neoplasms can be used as sentinels for environmental degradation. In addition, because fish are often an important source of protein, especially in developing countries, an investigation of piscine neoplasms may have implication for human consumers (Vergneau-Grosset *et al.*, 2017).

There are few reports about hemangioma specially cardiac hemangioma in aquatic animals. The last report of hemangioma is related to Hyatt *et al.* (2013) that showed retroperitoneal hemangiosarcoma in a

common carp. In another case study, Sahoo *et al.* (2012) indicated cavernous hemangioma in the skin of cultured olive barb, *Puntius sarana* (Hamilton). In an experimental study Couch (1995) found an unusually high, unprecedented prevalence of cardiac hemangioendotheliomata, including hemangiomas, hemangioendotheliomas and hemangioendotheliosarcomas in a laboratory cohort of the small, teleost fish *Rivulus marmoratus* that was fed a lyophilized chicken liver diet for up to 9 months. According to available literature, this is the first report of epicardial cavernous hemangioma in fish and so in pond-cultured *Acipenser baerii*.

### Materials and methods

In spring of 2016, an *A. baerii*, (+3 years, 2.2 kg weight) was referred to department of Aquatic Animal health, Faculty of Veterinary Medicine, Shahid Chamran university of Ahvaz with oxygenated plastic bag. The clinical signs were skeletal malformation, severe emaciation, exophthalmoses and skin ulcers. Wet mounts of gill and skin scrapings were prepared to detect any parasite involvement. Moderate infestation of the protozoan parasite, *Trichodina*, was seen in the skin and gills using a light microscope (Noga, 2010).

After taking samples from skin and gills, euthanization and necropsy were carried out. Macroscopic examinations revealed ascites. Also the heart had a cobblestone appearance which was characterized by multiple dark red cysts

of different sizes (2-5 mm). They were raised from the surface and scattered on the ventricular and the atrium epicardium (Fig. 1). The heart were removed and fixed in 10% neutral buffered formalin. Other organs had normal structures. The sections of heart were processed by routine methods, embedded in paraffin, sectioned and stained with Haematoxylin and Eosin (H&E) (Luna, 1968).

### Results and discussion

Microscopic examination of transverse sections of ventricles and atrium revealed multiple big cysts adhered to epicardium (Figs. 2 and 3). They were of different sizes and shapes (Fig. 4) and were filled with erythrocytes and white blood cells (Fig. 5). They were covered with proliferated pleomorphic endothelial cells, which were cuboidal to squamous, and supported by pericytes (Fig. 6). Intercavernous septa contained stroma and a number of fibroblasts and inflammatory cells (Fig. 5). There were no signs of invasion to the myocardium and the myocytes of ventricles and atrium had normal structures. No mitotic figures were observed. According to microscopic results, epicardial cavernous hemangioma was diagnosed.

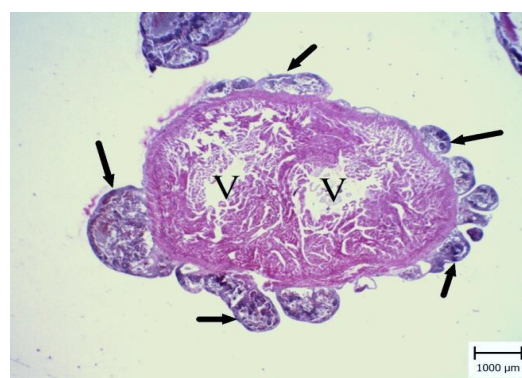To date, no reports of primary cardiac, endothelial cell-derived neoplasms have been published in fishes; although noncardiac hemangiomas are more common and cutaneous hemangioma is the most common (Sahoo *et al.*, 2012). O'Hagan and Raidal (2006) reported the first

cavernous hemangioma developing in a goldfish which was retrobulbar. The mass was removed by surgery. Generally, hemangiomas are locally invasive tumors that once diagnosed, are indicated as poor prognosis for the fish (O'Hagan and Raidal, 2006).

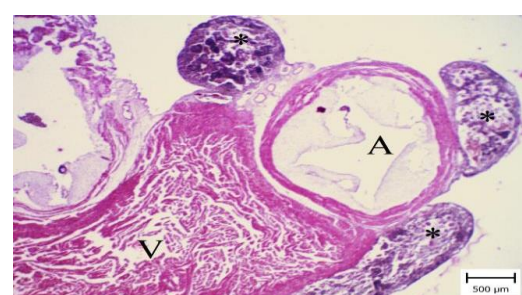
Although cardiac tumors are more common on the right side of the heart (Yamamoto *et al.*, 2013), in this case most parts of the epicardium was complicated and there was no side predilection. Also, raised and convex cysts on the surface of the heart gave a cobblestone appearance which was unique. Hemangioma has the potential to occur anywhere in the heart; depending on its location, hemangioma may result in compression of cardiac structures, congestive heart failure, cardiac rhythm disturbances or pericardial tamponade (Sata *et al.*, 2004). However, in this report, invasion was not detected but the fish was in poor condition due to severe effects of cavernous hemangioma on heart function. The most important clinical manifestation was ascites which is the sign of heart failure.



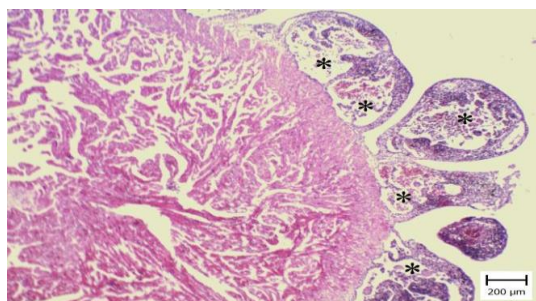
**Figure 1:** Heart of *Acipenser baerii*. Note the cobblestone appearance of heart. There are different raised cysts on ventricles and atrium wall.



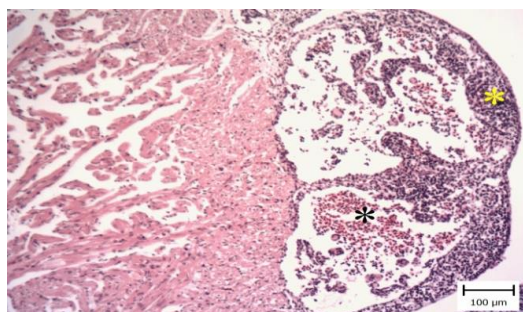
**Figure 2:** Epicardial cavernous hemangioma. Heart of *Acipenser baerii*. Note the multiple raised cysts on the surface of ventricular (V) epicardium (arrows). They were of different sizes and shapes (H&E).



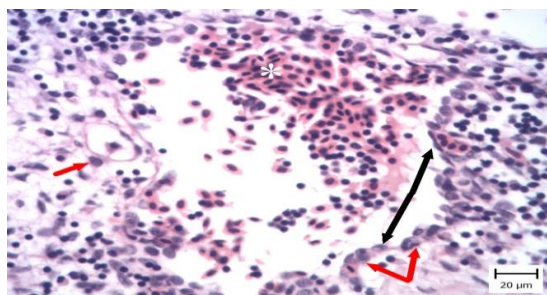
**Figure 3:** Epicardial cavernous hemangioma of *Acipenser baerii*. Epicardial raised cysts (asterisks) on the surface of ventricle (V) and atrium (A) are obvious. They were of different sizes and shapes (H&E).



**Figure 4: Epicardial cavernous hemangioma.** Heart of *Acipenser baerii*. The cysts (asterisks) are similar to big stones on the surface of epicardium and they are filled with blood cells. Normal structure of myocardium is obvious (H&E).



**Figure 5: Epicardial cavernous hemangioma.** Heart of *Acipenser baerii*. Note the adherence of cysts to the epicardium filled with blood cells (black asterisk) and the thickened intercavernous septa (yellow asterisk) (H&E).



**Figure 6: Epicardial cavernous hemangioma.** Heart of *Acipenser baerii*. Note the big channel which is filled with erythrocytes and white blood cells. Also it is covered with endothelial cells (black arrows) which have variable shapes, squamous to cuboidal. They are supported by pericytes (red arrows). The cysts are surrounded by stroma and inflammatory cells (H&E).

Also emaciation and muscular atrophy may be due to congestion and decreased food consumption.

Differential diagnoses of masses in the heart myxoma, cysts, thrombi, lipoma, fibroma and malignant tumors, all have different microscopic features. Microscopic examination revealed big cysts filled with erythrocytes and leukocytes which were attached to epicardium and pericytes surrounding them. Also infiltration of inflammatory cells in the connective tissue of intercavernous septa were obvious and this is in accordance with other reports (O'Hagan and Raidal, 2006 and Sahoo *et al.*, 2012).

In conclusion this manuscript describes the clinical, macroscopic and microscopic features of epicardial cavernous hemangioma in a farmed sturgeon, *Acipenser baerii*. According to the mentioned characteristics and literature review, this is the first report on primary epicardial cavernous hemangioma in *A. baerii*.

## References

- Brown, N.O., Patnaik, A.K. and MacEwen, E.G., 1985.** Canine hemangiosarcoma. *Journal of the American Veterinary Medical Association*, 186, 56–58.
- Couch, J.A., 1995.** Invading and metastasizing cardiac hemangioendothelial neoplasms in a cohort of the fish *Rivulus marmoratus*: Unusually high prevalence, histopathology, and possible etiologies. *Cancer Research*, 55, 2438-2447.

- Goldschmidt, M.H. and Hendrick, M.J., 2002.** Tumors of the skin and soft tissues. In: Tumors in domestic animals (ed. by D.J. Meuten), Iowa State Press, Ames, Iowa, 45 P.
- Gross, T.L., Ihrke, P.J., Walder, E.J. and Affolter, V.K., 2007.** Vascular tumors. In: Skin disease of the dog and cat: Clinical and histopathological diagnosis (ed. by T.L. Gross; P.J. Ihrke; E.J., Walder; V.K., Affolter), Blackwell Science, Oxford, UK, 735 P.
- Harshbarger, J.C., 1969.** Registry of tumors in lower animals. *National Cancer Institute monograph*, 31, pp. XI-XVI.
- Hyatt, M.W., Clauss, T.M., Dennison, S.E. and Camus, A.C., 2013.** Retroperitoneal hemangiosarcoma in a common carp *Cyprinus carpio*: a case report. *Diseases of aquatic organisms*, 107(2), 151-160.
- Luna, L.G., 1968.** Manual of histologic staining methods of the Armed Forces Institute of Pathology. New York, Blakiston Division, McGraw-Hill.
- Noga, E.J., 2010.** Fish disease: diagnosis and treatment. John Wiley and Sons. 137 P.
- O'Hagan, B.J. and Raidal, S.R., 2006.** Surgical removal of retrobulbar hemangioma in a goldfish (*Carassius auratus*). *Veterinary Clinics of Exotic Animals*, 9, 729-733.
- Sahoo, P.K., Mohanty, B.R., Das, A., Mahapatra, K.D. and Saha, J.N., 2012.** Cavernous haemangioma in cultured olive barb, *Puntius sarana* (Hamilton). *Journal of Fish Diseases*, 35, 695-697.
- Sata, N., Moriyama, Y., Hamada, N., Horinouchi, T. and Miyahara, K., 2004.** Recurrent pericardial tamponade from atrial hemangioma. *Annals of Thoracic Surgery*, 78, 1472-1475.
- Vergneau-Grosset, C., Nadeau, M.E. and Groff, J.M., 2017.** Fish oncology: Diseases, diagnostics, and therapeutics. *Veterinary Clinics of North America: Exotic Animal Practice*, 20(1), 21-56.
- Yamamoto, Sh., Hoshi, K., Hirakawa, A., Chimura, S., Kobayashi, M. and Machida, N., 2013.** Epidemiological, clinical and pathological features of primary cardiac hemangiosarcoma in dogs: A review of 51 cases. *Journal of Veterinary Medical Science*, 75, 1433-1441.