

LONDON
SCHOOL of
HYGIENE
& TROPICAL
MEDICINE



Patel, Trupti A; Scadding, Glenis K; Phillips, David E; Lockwood, Diana N (2017) Case Report: Old World Mucosal Leishmaniasis: Report of Five Imported Cases to the Hospital for Tropical Diseases, London, United Kingdom. *The American journal of tropical medicine and hygiene*, 97 (4). pp. 1116-1119. ISSN 0002-9637 DOI: <https://doi.org/10.4269/ajtmh.17-0162>

Downloaded from: <http://researchonline.lshtm.ac.uk/4652589/>

DOI: [10.4269/ajtmh.17-0162](https://doi.org/10.4269/ajtmh.17-0162)

Usage Guidelines

Please refer to usage guidelines at <http://researchonline.lshtm.ac.uk/policies.html> or alternatively contact researchonline@lshtm.ac.uk.

Available under license: Copyright the publishers

Case Report: Old World Mucosal Leishmaniasis: Report of Five Imported Cases to the Hospital for Tropical Diseases, London, United Kingdom

Trupti A. Patel,^{1*} Glenis K. Scadding,² David E. Phillips,³ and Diana N. Lockwood¹

¹Hospital for Tropical Diseases, University College London Hospitals NHS Foundation Trust, London, United Kingdom; ²Royal National Throat, Nose and Ear Hospital, University College London Hospitals NHS Foundation Trust, London, United Kingdom; ³Department of Ear, Nose and Throat Surgery, Warwick Hospital, Warwick, United Kingdom

Abstract. Old World species of *Leishmania* typically cause visceral and cutaneous leishmaniasis. Mucosal involvement is typically seen with infection by *Leishmania* species found in South America, usually after the healing of cutaneous leishmaniasis. We present five imported cases of mucosal leishmaniasis caused by Old World Mediterranean *Leishmania infantum* exclusively affecting the nasal mucosa or vocal cord. In only one case was there a recollection of a preceding cutaneous lesion compatible with cutaneous Leishmaniasis. Of significance was that four out of five cases were receiving local corticosteroids for chronic lung disorders and four were systemically immunosuppressed. This report highlights the importance of considering mucosal leishmaniasis in the differential diagnosis in those presenting with upper respiratory tract mucosal lesions with a relevant travel history to the Mediterranean and in whom malignancy has been excluded.

INTRODUCTION

Leishmaniasis has three main clinical forms: visceral, cutaneous, and mucosal disease. Worldwide there is an estimated annual incidence of 1.3 million cases across 98 countries with an additional 310 million at risk of infection.¹ It is a disease caused by the protozoan parasite *Leishmania*, transmitted by the bite of the female sandfly. A number of animals serve as natural reservoirs including domestic and wild dogs, foxes, wolves, sloths, rats, and mice.² Human beings are directly involved as a principal reservoir host in two forms of the disease: visceral leishmaniasis (VL) caused by *Leishmania donovani* and cutaneous leishmaniasis (CL) caused by *Leishmania tropica*.³

There are more than 20 species of *Leishmania*; the resulting clinical syndrome typically relates to the infecting species.³ In the Old World, *L. donovani* (in regions of India, Pakistan, China, and Africa) and *Leishmania infantum* (in the Mediterranean Region) typically cause VL.

There have also been reports of VL caused by *L. tropica* in the Middle East and India.^{4,5} In comparison, *Leishmania major* and *L. tropica* cause CL.

Mucosal leishmaniasis (ML) is a disease largely confined to South America whereby a small proportion of patients (1–10%) mainly infected with *Leishmania braziliensis* and *Leishmania panamensis* develop mucous membrane involvement of the nose, and less commonly the oral cavity, pharynx, and or larynx, months to years after healing of primary cutaneous lesions.^{6,7} This report contributes to the recognition in recent decades that Old World species can cause localized mucosal disease, contributed to by local or systemic immunosuppression.^{8–19}

CASES

Case 1. A 72-year-old man, with a past medical history of Addison's disease on hydrocortisone, was referred in May

2012 with nasal swelling and unilateral deafness. He had lived in Spain intermittently for the previous 35 years and mostly for the preceding 5 years. He gave a history of lifelong hay fever treated with a corticosteroid nasal spray. He had also been taking methotrexate and prednisolone for rheumatoid arthritis and myelodysplasia for 4 years.

Symptoms began 3 years earlier with nasal congestion. Two years later he developed a blocked nose associated with epistaxis and was given a diagnosis of localized anti-neutrophil cytoplasmic antibodies-negative Wegener's Granulomatosis (now renamed granulomatosis with polyangiitis). Later that same year he developed visible swelling and erythema of his nose and unilateral deafness. At the time of grommet insertion, a biopsy was taken of the local tissue and this demonstrated evidence of *Leishmania* amastigotes and was confirmed with detection of *L. donovani* complex DNA by polymerase chain reaction (PCR) (nested PCR-based schizodeme method).²⁰

He was commenced on a 30-day course of oral miltefosine, 150 mg once daily, and the level of immunosuppression reduced. At the end of the treatment course, his *Leishmania* direct agglutination test (DAT) (one in 25,600 [cutoff 1:1,600]; KIT-Biomedical Research, Royal Tropical Institute, Netherlands) and rK39 antibody (recombinant kinesin) were positive. The DAT detects antibodies to *L. donovani* in the blood or serum of those infected by means of direct agglutination.²¹ The rK39 rapid antibody test detects antibodies to a protein-encoding gene (K39) found in *Leishmania* species.²² A bone marrow sample from 2010 was obtained and this did not have any amastigotes and PCR for *Leishmania* DNA was negative. Nine months posttreatment, he had no further fevers and had gained weight. Two years later, biopsies taken during nasal reconstruction were PCR negative for *Leishmania* DNA.

Case 2. A 69-year-old man was referred with a 30-month history of a hoarse voice in June 2014. He had been living in southern Spain for 3–4 months over the preceding few years. He had a past medical history of asthma and bronchiectasis for which he regularly used a corticosteroid inhaler and systemic steroids. In December 2013, an irregular left vocal cord was noted on routine bronchoscopy. Microlaryngoscopy

* Address correspondence to Trupti A. Patel, Royal Free London NHS Foundation Trust, Pond Street, London NW3 2QG, UK. E-mail: truptipatel1@nhs.net

in April 2014 demonstrated a firm cystic area arising from the surface of the left true vocal cord. Histology of a total excision biopsy demonstrated numerous *Leishmania* amastigotes, confirmed with detection of *L. donovani* complex DNA by PCR. Three months later, a bronchoscopy demonstrated an abnormal trachea with a nodular and cobbledstoned appearance (Figure 1).

At presentation, there was no organomegaly or lymphadenopathy and his *Leishmania* DAT was positive at a low titer of one in 3,200. A 30-day course of miltefosine was started during which time the inhaled prednisolone was discontinued. One year after completing treatment, he had had no evidence of *Leishmania* recurrence.

Case 3. A 56-year-old man was referred in July 2011 with a 2-year history of inflammatory swellings of the nasal lining causing nasal block. Travel history included annual visits to Greece for the previous 14 years.

His symptoms began 7 years prior with sinusitis and difficulty breathing. He had a past medical history of rheumatoid arthritis for which he was taking methotrexate, adalimumab, and rituximab. Initial biopsies in 2009 demonstrated a lymphocytic infiltrate. On the basis that he had possibly had a local form of granulomatosis with polyangiitis, he was given corticosteroids. After this, his symptoms worsened with nasal swelling, blockage, and ulceration. A further biopsy 2 years later detected *L. donovani* complex DNA by PCR. At presentation, he had massive swelling and erythema of his nose and crusting of the nasal passages with minimal lymphadenopathy and a palpable splenic tip (Figure 2). A *Leishmania* DAT was negative but the K39 antibody was positive. He was started on once daily intravenous sodium stibogluconate (SSG) for 28 days. During treatment, his immunosuppressants were stopped temporarily. Twelve months later, his nose lesion had healed completely and he was recurrence free 3 years later.

Case 4. A 60-year-old woman was referred in May 2015 with a 4 month history of a hoarse voice and occasional fever. She recalled a previous skin lesion affecting the neck which had spontaneously healed which may have been localized CL. She had lived in southern Spain for the past 7 years. She had a 10-year history of asthma, for which she

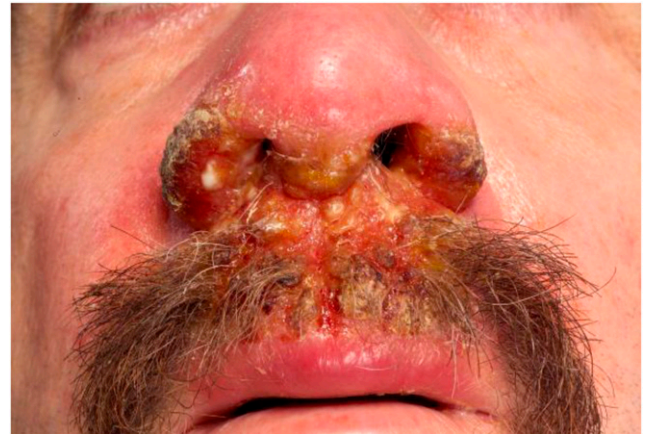

FIGURE 2. Case 3. Granulomatous lesions of mucosal leishmaniasis of nasal passages and surrounding skin. This figure appears in color at www.ajtmh.org.

took regular corticosteroid inhalers and short courses of prednisolone.

Laryngoscopy in April 2015 demonstrated left vocal cord palsy with granulomatous inflammation of both false cords. Histology demonstrated numerous amastigotes of *Leishmania*, confirmed with detection of *L. donovani* complex DNA by PCR. *Leishmania* DAT was positive at a titer of 1 in 102,400 and K39 antibody was positive. Twelve months after a 30-day course of miltefosine, her hoarse voice had resolved with no evidence of vocal cord recurrence on endoscopy.

Case 5. A 54-year-old woman was referred in February 2016 with a 3-month history of a hoarse voice, cough, and choking episodes. She had a history of a previous crusted ulcer on her leg, which spontaneously healed 8 years prior to presentation. She had lived for periods in a rural area of Greece for the previous 11 years. She has had a past medical history of emphysema for 15 years for which she had received numerous courses of mainly inhaled but also systemic corticosteroids.

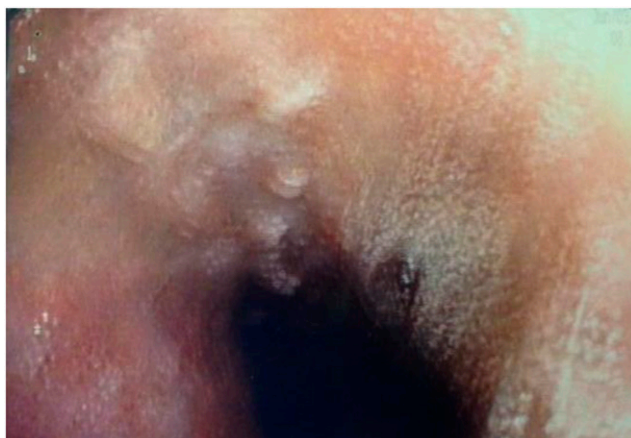

FIGURE 1. Case 2. Nodular appearance of trachea on bronchoscopy, due to mucosal leishmaniasis. This figure appears in color at www.ajtmh.org.

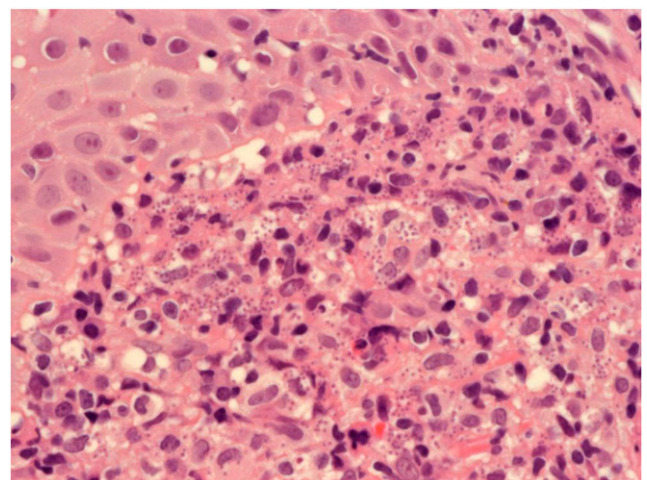


FIGURE 3. Case 5. Histology of vocal cord biopsy demonstrating *Leishmania* amastigotes. This figure appears in color at www.ajtmh.org.

TABLE 1
Summary of five cases of Old World ML

	Case 1	Case 2	Case 3	Case 4	Case 5
Site of ML	Nasal mucosa and middle ear	Vocal cord	Nasal mucosa	Vocal cord	Vocal cord
Country of acquisition	Spain	Spain	Greece	Spain	Greece
Significant conditions	Rheumatoid arthritis Myelodysplasia Allergic rhinitis	Asthma Bronchiectasis	Rheumatoid arthritis	Asthma	Emphysema
Local immunosuppression	Yes	Yes	No	Yes	Yes
Systemic immunosuppression:					
Corticosteroids	Yes	Yes	Yes	Yes	Yes
Biologic agents	No	No	Yes—adalimumab, rituximab	No	No
Other immunosuppression	Yes - methotrexate	No	Yes—methotrexate	No	No
Treatment (days)	Miltefosine (30)	Miltefosine (30)	SSG (28)	Miltefosine (30)	Miltefosine (30)
Recurrence free (months)	24	12	36	12	1

ML = mucosal leishmaniasis; SSG = sodium stibogluconate.

Nasendoscopy in February 2016 demonstrated granulomatous lesions affecting the vocal cords. Histology of a biopsy demonstrated amastigotes of *Leishmania* (Figure 3), confirmed with detection of *L. donovani* complex DNA by PCR. *Leishmania* DAT was negative and K39 antibody weakly positive. She was treated with a 30-day course of miltefosine. She experienced severe adverse effects during the course including vomiting, abdominal pain, and headaches. Two weeks after completion of treatment, her voice, swallowing, and exercise tolerance had improved.

DISCUSSION

Over the past three decades, and increasingly so more recently, it has been recognized that ML can exist outside the South American continent where clinical presentations are less well defined.⁸ In comparison to the destructive predominantly nasal (90%) mucosal lesions of New World ML, Old World ML appears to commonly affect other areas such as the buccal mucosa as well as the pharynx and larynx.^{7,10–16,23} Immunocompromise, systemic or local, appears to be a significant risk factor making *L. infantum* an opportunistic pathogen in this setting.^{8,9,24} Localized mucosal disease can be either accompanied or preceded by CL or VL in Old World ML. In only one case could the patient recall a preceding lesion of CL. In three of five cases presented here, the high DAT titers and/or positive K39 antibody was likely to represent a systemic response to infection.

Leishmania donovani complex was detected by PCR of affected tissue. In all five cases, the likely causative species was *L. infantum* given the travel history and geographical distribution of *L. infantum* in the Mediterranean with the domestic dog serving as the main reservoir host.²

The route by which *Leishmania* protozoa localize to mucous membranes in Old World ML is unclear. It has been suggested that it is either from hematogenous spread from a distant initial inoculation or from direct mucosal injection of parasites.^{24,25} Evidence suggests that the former explanation is more plausible, considering the high rates of asymptomatic carriage of *L. infantum* in the Mediterranean region.²⁶ Important, however, to the development of disease is the fact that four of the five cases presented here were taking inhaled corticosteroids. This has previously been suggested to be a risk factor for developing ML, along with tobacco smoke and upper respiratory tract diseases, by inducing localized mucosal immunosuppression.^{8–10,24} Four of the five were

also significantly systemically immunosuppressed, due to corticosteroids or other immunosuppressive drugs, which is also a recognized risk factor for the development of ML (see Table 1 for summary of five cases).^{24,27} Cessation of immunosuppressants during therapy is therefore likely to increase the chances of cure and prevent disease relapse.

Pentavalent antimonials such as SSG, administered intravenously for 28 days, are recommended by the World Health Organization for the treatment of South American ML.²⁸ Alternatives include amphotericin B (deoxycholate or a lipid formulation), paramomycin, and pentamidine.²⁹ The mainstay of treatment of Mediterranean leishmaniasis has also been the antimonials with good reported cure rates.⁸ However, due to significant toxicity issues and the need for potential hospitalization to administer these drugs, oral miltefosine (150 mg once daily), an agent used for the treatment of VL acquired in India, could be a highly effective alternative for the treatment of mucosal disease caused by *L. infantum* in an outpatient setting. Three treatment studies of Old World CL caused by *L. major* have demonstrated a mean cure rate of 93% with miltefosine.^{30–32} Evidence for its use in the treatment of CL caused by *L. tropica* and *L. donovani* is limited to a small number of case reports. A recent case series and literature review of 24 patients with Old World CL as well as ML has demonstrated good cure rates with miltefosine, particularly in the absence of immunosuppression.³³ Most studies evaluating treatment lengths and dosing regimens have demonstrated that a 28-day course is sufficient in the treatment of VL and Old World CL but the duration of treatment in those with immunocompromise, human immunodeficiency virus (HIV) or other etiologies, has not yet been established.^{34–36} The rationale for a 30-day course used in the patients presented here is based on limited published evidence of encouraging cure rates in HIV-coinfected patients given an initial median duration of treatment of 30 days.³⁷ In line with reported cure rates of 75% with miltefosine in Bolivian ML, four cases treated here were successfully treated without the need for hospitalization.^{38,39}

Received March 2, 2017. Accepted for publication May 10, 2017.

Published online July 24, 2017.

Authors' addresses: Trupti A. Patel and Diana N. Lockwood, Hospital for Tropical Diseases, University College London Hospitals NHS Foundation Trust, London, UK, E-mails: truptipatel1@nhs.net and diana.lockwood@lshtm.ac.uk. Glenis K. Scadding, Royal National Throat, Nose and Ear Hospital, University College London Hospitals NHS Foundation Trust, London, UK, E-mail: gscadding@gmail.com.

David E. Phillips, Department of Ear, Nose and Throat Surgery, Warwick Hospital, Warwickshire, UK, E-mail: david.phillips@swft.nhs.uk.

REFERENCES

- World Health Organization, 2013. *Sustaining the Drive to Overcome the Global Impact of Neglected Tropical Diseases. Second WHO Report on Neglected Tropical Diseases.* Geneva, Switzerland: World Health Organization. Available at: http://www.who.int/neglected_diseases/9789241564540/en/. Accessed December 1, 2016.
- Alborzi A, Rasouli M, Shamsizadeh A, 2006. Leishmania tropica-isolated patient with visceral leishmaniasis in southern Iran. *Am J Trop Med Hyg* 74: 306–307.
- World Health Organization, 2010. *Technical Report Series 949. Control of the Leishmaniasis.* Available at: http://whqlibdoc.who.int/trs/WHO_TRS_949_eng.pdf. Accessed January 11, 2017.
- Sacks DL, Kenney RT, Kreutzer RD, Jaffe CL, Gupta AK, Sharma MC, Sinha SP, Neva FA, Saran R, 1995. Indian kala-azar caused by *Leishmania tropica*. *Lancet* 345: 959–961.
- Magill AJ, 2009. *Leishmania* species: Visceral (kala-azar), cutaneous, and mucosal leishmaniasis. Mandell GL, Bennett JE, Dolin R, eds. *Mandell, Douglas and Bennett's Principles and Practice of Infectious Diseases*, Vol. 2, 7th edition. Philadelphia, PA: Churchill Livingstone, 3481.
- Jones TC, et al., 1987. Epidemiology of American cutaneous leishmaniasis due to *Leishmania braziliensis braziliensis*. *J Infect Dis* 156: 73–83.
- Lessa MM, Lessa HA, Castro TW, Oliveira A, Scherifer A, Machado P, Carvalho EM, 2007. Mucosal leishmaniasis: epidemiological and clinical aspects. *Rev Bras Otorrinolaringol (Engl Ed)* 73: 843–847.
- Aliaga L, Cobo F, Mediavilla JD, Bravo J, Osuna A, Amador JM, Martín-Sánchez J, Cordero E, Navarro JM, 2003. Localized mucosal leishmaniasis due to *Leishmania (Leishmania) infantum*: clinical and microbiologic findings in 31 patients. *Medicine (Baltimore)* 82: 147–158.
- Cocuzza S, Strazzulla A, Pinzone MR, Cosentino S, Serra A, Caltabiano R, Lanzafame S, Cacopardo B, Nunnari G, 2013. Isolated laryngeal leishmaniasis in immunocompetent patients: an underdiagnosed disease. *Case Rep Infect Dis* 2013: 165409.
- Richter J, Hanus I, Haussinger D, Löscher T, Harms G, 2011. Mucosal *Leishmania infantum* infection. *Parasitol Res* 109: 959–962.
- Tiseo D, Tosone G, Conte MC, Scordino F, Mansueto G, Mesolella M, Parrella G, Pennone R, Orlando R, 2008. Isolated laryngeal leishmaniasis in an immunocompetent patient: a case report. *Infez Med* 16: 233–235.
- Alvar J, Ballesteros JA, Soler R, Benito A, van Eys GJ, Schooner GJ, Cabrera B, 1990. Mucocutaneous leishmaniasis due to *Leishmania (Leishmania) infantum*: biochemical characterization. *Am J Trop Med Hyg* 43: 614–618.
- Tomson N, Symonds RP, Moir AA, Kendall CH, Wiselka MJ, 2002. New World leishmaniasis from Spain. *Postgrad Med J* 78: 757–758.
- García de Marcos JA, Dean FA, Alamillos GF, Ruiz Masera JJ, Cortés Rodríguez B, Vidal Jiménez A, García Lainez A, Lozano Rodríguez-Mancheno A, 2007. Localized Leishmaniasis of the oral mucosa. A report of three cases. *Med Oral Patol Oral Cir Bucal* 12: E281–E286.
- Borzoni F, Gradoni L, Gramiccia M, Maccioni A, Valdes E, Loddo S, 1991. A case of lingual and palatine localization of a viscerotropic *Leishmania infantum* zymodeme in Sardinia, Italy. *Trop Med Parasitol* 42: 193–194.
- Casolari C, Guaraldi G, Pecorari M, Tamassia G, Cappi C, Fabio G, Cesinaro AM, Piolini R, Rumpianesi F, Presutti L, 2005. A rare case of localized mucosal leishmaniasis due to *Leishmania infantum* in an immunocompetent Italian host. *Eur J Epidemiol* 20: 559–561.
- Cobo F, Aliaga L, Talavera P, Concha A, 2007. The histological spectrum of non-granulomatous localized mucosal leishmaniasis caused by *Leishmania infantum*. *Ann Trop Med Parasitol* 101: 689–694.
- Pau M, Atzori L, Aste N, Aste N, 2009. Two cases of primary endonasal leishmaniasis in Sardinia (Italy). *Dermatol Online J* 15: 5.
- Maroli M, Rossi L, Baldelli R, Capelli G, Ferroglio E, Genchi C, Gramiccia M, Mortarino M, Pietrobelli M, Gradoni L, 2008. The northward spread of leishmaniasis in Italy: evidence from retrospective and ongoing studies on the canine reservoir and phlebotomine vectors. *Trop Med Int Health* 13: 256–264.
- Noyes HA, Reyburn H, Bailey JW, Smith D, 1998. A nested-PCR-based schizodeme method for identifying *Leishmania* kinetoplast minicircle classes directly from clinical samples and its application to the study of the epidemiology of *Leishmania tropica* in Pakistan. *J Clin Microbiol* 36: 2877–2881.
- Adams ER, Jacquet D, Schooner G, Gidwani K, Boelaert M, Cunningham J, 2012. Leishmaniasis direct agglutination test: using pictorials as training carriers to reduce inter-reader variability and improve accuracy. *PLoS Negl Trop Dis* 6: e1946.
- Sundar S, Pai K, Sahu M, Kumar V, Murray HW, 2002. Immunochromatographic strip-test detection of anti-K39 antibody in Indian visceral leishmaniasis. *Ann Trop Med Parasitol* 96: 19–23.
- Fsadni C, Fsadni P, Piscopo T, Mallia AC, 2007. Laryngeal leishmaniasis in Malta. *J Infect* 54: e61–e63.
- Faucher B, et al., 2011. Mucosal *Leishmania infantum* leishmaniasis: specific pattern in a multicentre survey and historical cases. *J Infect* 63: 76–82.
- Habibzadeh F, Sajedianfard J, Yadollahie M, 2005. Isolated lingual leishmaniasis. *J Postgrad Med* 51: 218–219.
- Michel G, Pomares C, Ferrua B, Marty P, 2011. Importance of worldwide asymptomatic carriers of *Leishmania infantum (L. chagasi)* in human. *Acta Trop* 119: 69–75.
- Guerra JA, Coelho LI, Pereira FR, Siqueira AM, Ribeiro RL, Almeida TM, Lacerda MV, Barbosa Md, Talhari S, 2011. American tegumentary leishmaniasis and HIV-AIDS association in a tertiary care center in the Brazilian Amazon. *Am J Trop Med Hyg* 85: 524–527.
- World Health Organization, 2013. *Leishmaniasis in the Americas. Recommendations for Treatment.* Geneva, Switzerland: World Health Organization. Available at: <http://www.who.int/leishmaniasis/research/en/>. Accessed December 1, 2016.
- Aronson N, et al., 2016. Diagnosis and treatment of leishmaniasis: clinical practice guidelines by the (IDSA) and the American Society of Tropical Medicine and Hygiene (ASTMH). *Clin Infect Dis* 63: e202–e264.
- van Thiel PP, et al., 2010. Miltefosine treatment of *Leishmania major* infection: an observational study involving Dutch military personnel returning from northern Afghanistan. *Clin Infect Dis* 50: 80–83.
- Mohebbi M, Fotouhi A, Hooshmand B, Zarei Z, Akhondi B, Rahnama A, Razaghian AR, Kabir MJ, Nadim A, 2007. Comparison of miltefosine and meglumine antimoniate for the treatment of zoonotic cutaneous leishmaniasis (ZCL) by a randomized clinical trial in Iran. *Acta Trop* 103: 33–40.
- Rahman SB, ul Bari A, Mumtaz N, 2007. Miltefosine in cutaneous leishmaniasis. *J Coll Physicians Surg Pak* 17: 132–135.
- Mosimann V, Blazek C, Grob H, Chaney M, Neumayr A, Blum J, 2016. Miltefosine for mucosal and complicated cutaneous old world leishmaniasis: a case series and review of the literature. *Open Forum Infect Dis* 3: ofw008.
- Sundar S, Jha TK, Thakur CP, Bhattacharya SK, Rai M, 2006. Oral miltefosine for the treatment of Indian visceral leishmaniasis. *Trans R Soc Trop Med Hyg* 100: S26–S33.
- Sundar S, Jha TK, Thakur CP, Bhattacharya SK, Rai M, 2002. Oral miltefosine for Indian visceral leishmaniasis. *N Engl J Med* 347: 1739–1746.
- Bhattacharya SK, et al., 2007. Phase 4 trial of miltefosine for the treatment of Indian visceral leishmaniasis. *J Infect Dis* 196: 591–598.
- Sindermann H, Engel KR, Fischer C, Bommer W, 2004. Miltefosine compassionate use program: oral miltefosine for leishmaniasis in immunocompromised patients: compassionate use in 39 patients with HIV infection. *Clin Infect Dis* 39: 1520–1523.
- Soto J, et al., 2007. Treatment of Bolivian mucosal leishmaniasis with miltefosine. *Clin Infect Dis* 44: 350–356.
- Soto J, Rea J, Valderrama M, Toledo J, Valda L, Ardiles J, Berman J, 2009. Efficacy of extended (six weeks) treatment with miltefosine for mucosal leishmaniasis in Bolivia. *Am J Trop Med Hyg* 81: 387–389.