

Case Reports & Case Series

Cervical myelopathy presenting with an acute Horner's syndrome[☆]

Rory J. Lubner^a, Jared Fridley^a, David B. Choi^a, Albert E. Telfeian^a, Jonathan F. Cahill^b,
Ziya L. Gokaslan^a, Adetokunbo A. Oyelese^{a,*}

^a Department of Neurosurgery, Rhode Island Hospital, The Warren Alpert Medical School of Brown University, Providence, RI, USA

^b Department of Neurology, Rhode Island Hospital, The Warren Alpert Medical School of Brown University, Providence, RI, USA



ARTICLE INFO

Keywords:

Horner's syndrome
Cervical myelopathy
Anisocoria
Disc herniation
Sympathetic pathway

ABSTRACT

Cervical myelopathy due to a disc herniation commonly manifests with difficulty in walking, spastic weakness of upper limbs and hands, hyperreflexia, and patchy sensory loss due to mechanical disruption and vascular compromise of spinal cord pathways to the extremities. We report a rare manifestation of cervical myelopathy in a thirty-five year old woman with an acute cervical disc herniation in the form of Horner's syndrome.

1. Introduction

Cervical myelopathy is a clinical syndrome resulting from dysfunction of the spinal cord [1]. Early symptoms of cervical myelopathy include weakness, decreased sensation, diminished dexterity, and gait instability, while later symptoms include urinary and bowel incontinence, and spasticity [2]. There are no pathognomonic findings, but classic neurologic exam signs include pathologic reflexes such as Hoffman sign, Babinski sign, and ankle clonus [1,2].

However, cervical myelopathy can theoretically be caused by any disruption of the pathways in the cervical spine, which may lead to a wide array of different presenting symptoms. Rare cases include presentations of false localizing sciatica-like leg pain, acute onset paraplegia, and hypoventilation [3–5]. We present a rare case of a 35-year-old female presenting with concurrent cervical myelopathy and Horner's syndrome caused by an acute C6–7 disc herniation.

Horner's syndrome is characterized by injury to preganglionic first order, second-order, or third-order neurons that constitute the sympathetic innervation to the head and neck [6]. Patients classically present with a triad of ipsilateral pupillary miosis, partial eyelid ptosis, and anhidrosis. Common etiologies of Horner's syndrome include surgery, trauma, or tumors that interrupt sympathetic nerve signaling along the three-neuron pathway [7]. There is no specific treatment for Horner's syndrome, but it most often resolves when the underlying cause (e.g. trauma, iatrogenic, infection) is accurately identified and treated.

2. Case report

A 35-year-old female initially presented to an optometrist, and subsequently an ophthalmologist, for evaluation of worsening right eye visual acuity. She was diagnosed with Horner's syndrome after she was found on examination to have right eye ptosis and miosis and sent to neurology and neurosurgery for further evaluation. Upon questioning she noted right sided radiculopathic arm pain, subjective right arm and leg weakness, as well as decreased right arm sensation. On examination cranial nerves were intact, and motor examination revealed full strength in all extremities. There was mild right eyelid ptosis and anisocoria (right pupil smaller), with both pupils reactive to light. Extraocular movements were intact and conjugate in all cardinal directions without nystagmus. Sensory examination was significant for diffuse numbness of the right extremities and trunk. She had 3+ hyperreflexia of both patellar reflexes.

Computed tomography (CT) of the brain was unremarkable. A CT angiogram of the neck showed no evidence of vascular dissection. MRI of the cervical spine revealed a large C6–7 paracentral disc herniation causing severe stenosis and cord compression, along with T2 cord signal change suggesting edema versus gliosis. (Figs. 1 and 2). Given the physical exam and imaging findings, the patient elected to undergo a C6–7 anterior cervical discectomy and interbody fusion. A significant herniated disc fragment was removed during surgery. A 6 mm lordotic cervical allograft was inserted and a 14 mm titanium plate was placed from C6 to C7 (Fig. 3).

Immediately after surgery the patient had a persistent Horner's

[☆] Declarations of interest: none.

* Corresponding author at: Dept. of Neurosurgery, Rhode Island Hospital, 593 Eddy Street APC-6, Providence, RI 02903, USA.

E-mail address: Aoyelese@Lifespan.org (A.A. Oyelese).

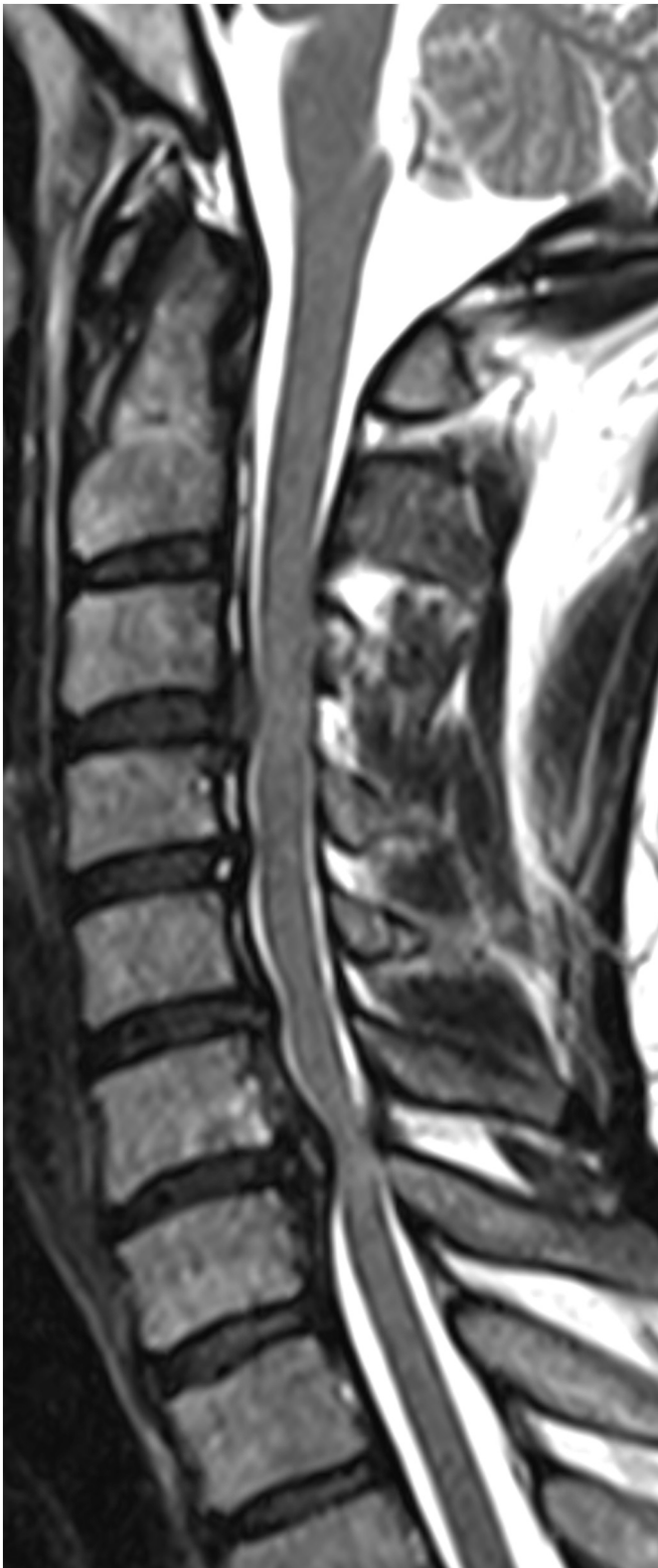

Fig. 1. Preoperative MRI of the cervical spine, T2 sagittal sequence demonstrating intervertebral disc herniation and spinal gliosis at the C6–C7 junction.

syndrome, but experienced partial resolution of her pain and numbness in the right upper extremity. Five months postoperatively, the patient reported resolution of her right arm pain and right arm/leg hypoesthesias, as well as improved visual acuity and resolution of her right eye miosis and ptosis.

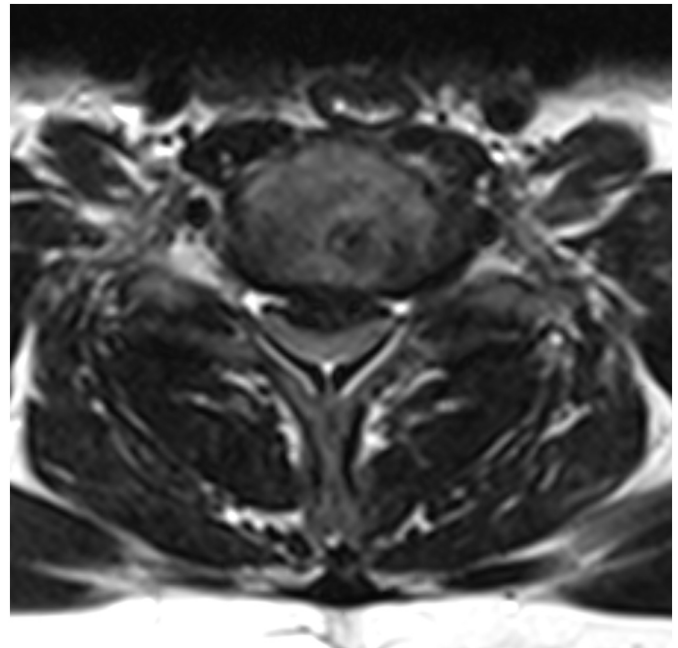


Fig. 2. Preoperative MRI of the cervical spine, T2 axial sequence demonstrating intervertebral posterior disc herniation at the C6–C7 junction.

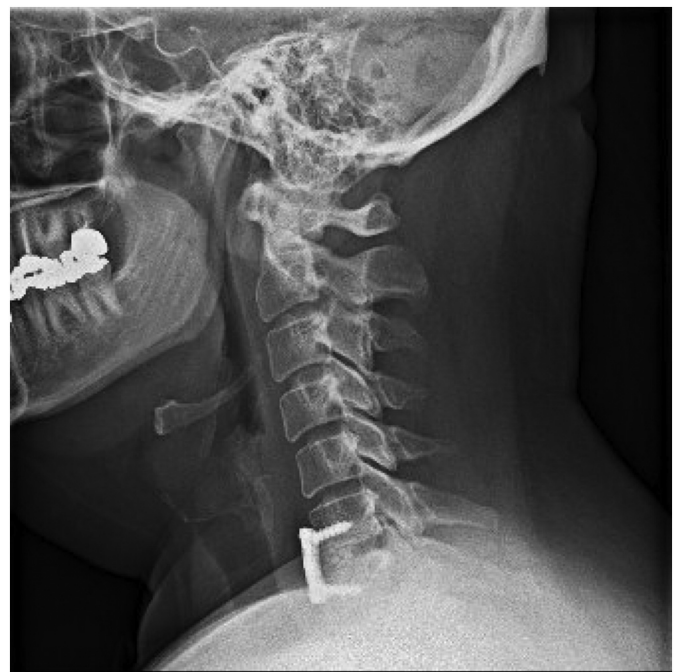

Fig. 3. Five-month Post-operative lateral cervical spine X-ray demonstrating anterior fusion of C6–C7 in standard alignment with no evidence of hardware complication, as well as partial bone graft incorporation at the C6–C7 disc space.

3. Discussion

Horner's syndrome results from damage to the sympathetic nervous system at any level of the three-order neuron pathway (Fig. 4) [6]. Sympathetic neurons originate in the posterolateral hypothalamus and travel through the brainstem and cervical spinal cord, terminating in the ciliospinal center of Budge located in the interomediolateral cell columns between C8 and T2 in the spinal cord. Pre-ganglionic sympathetic neurons exit the spinal cord via the ventral nerve roots from C8–

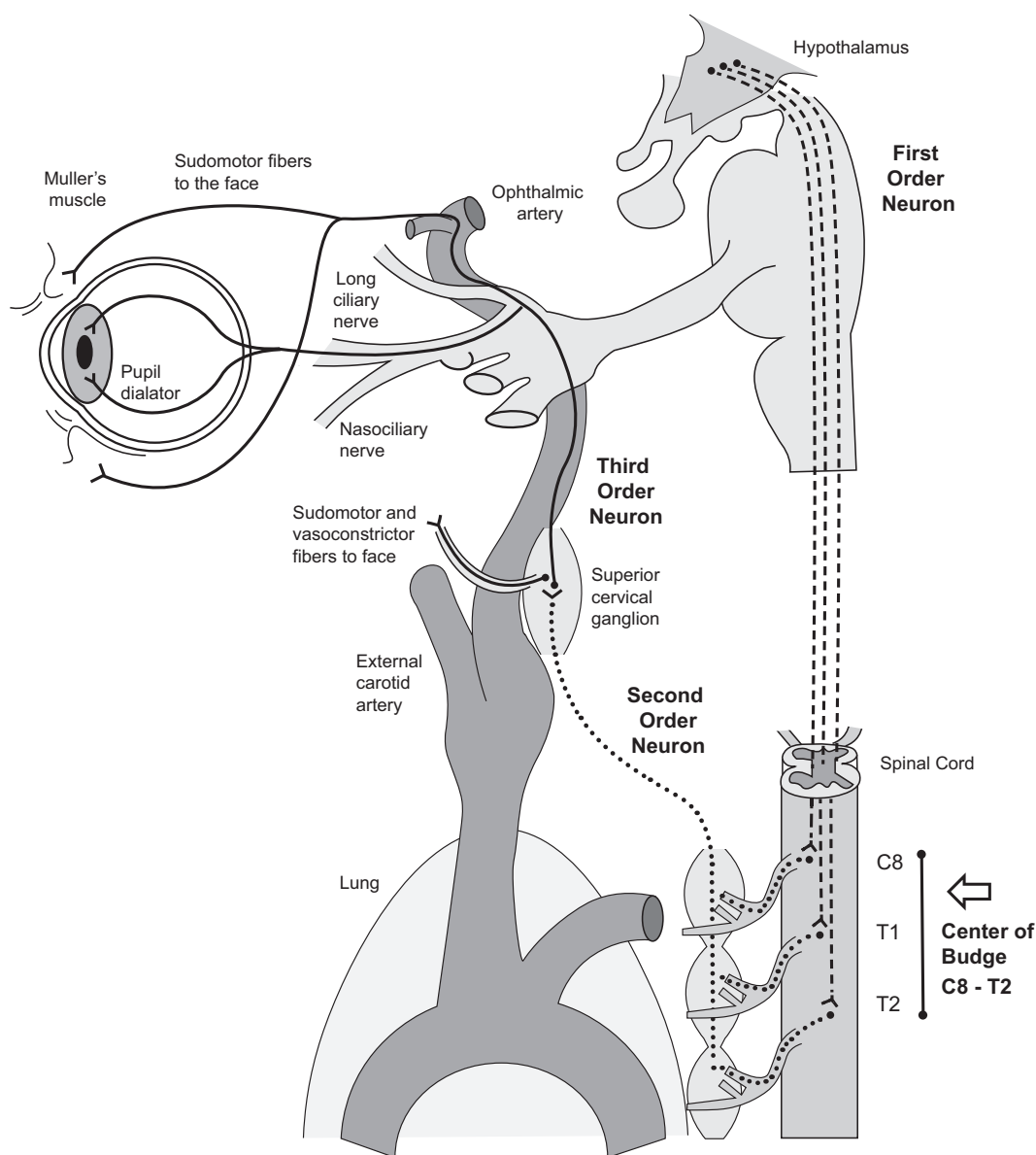


Fig. 4. A diagram of the three-neuron sympathetic pathway disrupted in Horner's Syndrome. Damage to any part of this pathway can result in Horner's Syndrome. The ciliocenter of Budge (labeled) is located in the intermediolateral cell columns of the spinal cord between C8–T2 and represents the location in which first-order sympathetic neurons from the hypothalamus synapse onto pre-ganglionic, second-order neurons. This area is named after Ludwig Julius Budge, who discovered its critical role in pupillary dilatation.

T2 and travel within the sympathetic chain over the lung apex and up the carotid sheath, terminating in the superior cervical ganglion located near the common carotid artery bifurcation [6,8]. The majority of the identifiable causes of Horner's syndrome originate along this pathway [9]. Breast and lung cancer malignancies account for nearly 1 in 4 patients with pre-ganglionic Horner's syndrome. The classic malignancy associated with Horner's syndrome is a Pancoast tumor [8]. Syringomyelia has also been described in the literature as a rare cause of pre-ganglionic Horner's syndrome [10,11].

Post-ganglionic neurons emerge from the superior cervical ganglion and ascend along the adventitia of the internal carotid artery to form the internal carotid nerve, or sympathetic plexus. Sympathetic plexus fibers innervate the pupillary dilators and Muller's muscle, smooth muscles in the upper and lower eyelids, and contribute to sweating in the ipsilateral face [5,6], which is why injury to the sympathetic pathway can lead to the classic Horner's triad of meiosis, ptosis, and anhidrosis. A post-ganglionic sympathetic injury due to internal carotid artery dissection is a common cause of Horner's syndrome [12,13].

Neuroblastoma in the neck, lymphadenopathy, and iatrogenic injury are other reported etiologies [5,8,14].

Our patient presented with an acute C6–C7 disc herniation with resultant cord compression, likely injuring the sympathetic fibers traveling through the cervical spinal cord to the ciliospinal center of Budge. Our patient's symptoms resolved soon after undergoing surgical decompression of the cervical spinal cord. There are only two other reported cases of an acquired Horner's syndrome associated with a herniated cervical disc [15,16]. The first described a 41-year old male with sudden onset left ptosis, miosis, and anhidrosis, coupled with right sided numbness below the T8 dermatome, without any history of trauma or physical stress. Cervical spine MRI demonstrated a large left paramedian disc herniation with unilateral spinal cord compression at C4–C5 level. Similar to our case, the authors suggested that a first-order lesion within the spinal cord was responsible for the patient's symptoms, which completely resolved following surgical decompression [16]. The second case report described a 51-year-old woman presented with right sided Horner's syndrome. However, unlike our case, she was

also found to have right sided hemiparesis and spasticity with diminished sensation to pain and temperature in the lower left trunk and limbs, indicative of Brown-Sequard Syndrome [15]. Cervical spine MRI demonstrated a large central and right extradural C5–6 disc herniation. The patient's symptoms completely resolved following decompression, again demonstrating the important role and favorable prognostic outcomes for prompt neurosurgical evaluation in these cases.

4. Conclusion

Horner's syndrome is a clinical constellation of neurologic signs caused by interruption of the sympathetic pathway traveling to the preganglionic neurons of the intermediolateral cell columns in the cervicothoracic spinal cord. Patients with Horner's syndrome should undergo a thorough history and physical examination to help localize the source of sympathetic disruption. The possibility of cervical spinal cord compression should be kept in mind in any patient with both Horner's syndrome and signs of cervical myelopathy.

Conflict of interest

No author of this case report has any relevant conflicts of interest to report.

References

- [1] C.C. Edwards, K.D. Riew, P.A. Anderson, A.S. Hilibrand, A.F. Vaccaro, Cervical myelopathy: current diagnostic and treatment strategies, *Spine J* (2003), [https://doi.org/10.1016/S1529-9430\(02\)00566-1](https://doi.org/10.1016/S1529-9430(02)00566-1).
- [2] M.T. Murray, B.K.B. Tay, Natural history of cervical myelopathy, *Semin Spine Surg* (2004), <https://doi.org/10.1053/j.semss.2004.10.002>.
- [3] C.K. Chan, H.Y. Lee, W.C. Choi, J.Y. Cho, S.H. Lee, Cervical cord compression presenting with sciatica-like leg pain, *Eur. Spine J.* (2011), <https://doi.org/10.1007/s00586-010-1585-5>.
- [4] V. Joanes, Cervical disc herniation presenting with acute myelopathy, *Surg. Neurol.* (2000), [https://doi.org/10.1016/S0090-3019\(00\)00236-6](https://doi.org/10.1016/S0090-3019(00)00236-6).
- [5] S. Cavazza, C. Bocciolini, E. Gasparrini, G. Tassinari, Iatrogenic Horner's syndrome, *Eur. J. Ophthalmol.* (2005), [https://doi.org/10.1016/0883-9441\(90\)90045-B](https://doi.org/10.1016/0883-9441(90)90045-B).
- [6] A. George, A.A. Haydar, W.M. Adams, Imaging of Horner's syndrome, *Clin. Radiol.* (2008), <https://doi.org/10.1016/j.crad.2007.12.006>.
- [7] Y. Gao, H. Zhang, J. Yang, Q. Fu, J. Zheng, M. Shuai, et al., Thoracolumbar arachnoid cyst with Horner syndrome: a case report and review of the literature, *Cell Biochem. Biophys.* (2014), <https://doi.org/10.1007/s12013-014-0347-0>.
- [8] S. Kanagalingam, N.R. Miller, Horner syndrome: clinical perspectives, *Eye Brain* (2015), <https://doi.org/10.2147/EB.S63633>.
- [9] K.M. Khurana, P.J.L. Hunter, Horner's syndrome produced by hypertrophic spurs from the cervical spine, *Br. J. Ophthalmol.* 48 (1964) 227–229, <https://doi.org/10.1136/bjo.48.4.227>.
- [10] J.B. Kerrison, V. Biousse, N.J. Newman, Isolated Horner's syndrome and syringomyelia, *J. Neurol. Neurosurg. Psychiatry* (2000), <https://doi.org/10.1136/jnnp.69.1.131>.
- [11] K.S. Paul, R.H. Lye, F.A. Strang, J. Dutton, Arnold-Chiari malformation, *J. Neurosurg.* (1983), <https://doi.org/10.3171/jns.1983.58.2.0183>.
- [12] G.M. Garbo, A.J. Harmatz, G. Isaacson, Incomplete Horner syndrome: report of a case and description of the sympathetic nervous system anatomy involved in Horner syndrome, *Ear Nose Throat J* 90 (2) (2011).
- [13] P.M. Flaherty, J.M. Flynn, Horner syndrome due to carotid dissection, *J Emerg Med* (2011), <https://doi.org/10.1016/j.jemermed.2008.01.017>.
- [14] F.G. Johnston, H.A. Crockard, One-stage internal fixation and anterior fusion in complex cervical spinal disorders, *J. Neurosurg.* (1995), <https://doi.org/10.3171/jns.1995.82.2.0234>.
- [15] Y. Meng, L. Zhou, X. Liu, H. Wang, J. Shi, Y. Guo, Brown-Sequard syndrome associated with Horner syndrome following cervical disc herniation, *Spinal Cord Ser Cases* 2 (2016) 16037, <https://doi.org/10.1038/scsanc.2016.37>.
- [16] H. Ma, I. Kim, Horner syndrome associated with a herniated cervical disc: a case report, *Korean J Spine* 9 (2012) 108, <https://doi.org/10.14245/kjs.2012.9.2.108>.