


## Accepted Manuscript

Title: Latent Tuberculosis Infection and renal transplantation – diagnosis and management

Authors: Sriram Krishnamoorthy, Natarajan Kumaresan, Alimuddin Zumla



PII: S1201-9712(19)30062-1  
DOI: <https://doi.org/10.1016/j.ijid.2019.01.049>  
Reference: IJID 3481

To appear in: *International Journal of Infectious Diseases*

Received date: 7 January 2019  
Revised date: 30 January 2019  
Accepted date: 31 January 2019

Please cite this article as: { <https://doi.org/>

This is a PDF file of an unedited manuscript that has been accepted for publication. As a service to our customers we are providing this early version of the manuscript. The manuscript will undergo copyediting, typesetting, and review of the resulting proof before it is published in its final form. Please note that during the production process errors may be discovered which could affect the content, and all legal disclaimers that apply to the journal pertain.

Invited viewpoint review: IJID Submission for World TB Day issues 2019

**Title:**

**Latent Tuberculosis Infection and renal transplantation – diagnosis and management**

**Authors:**

**Sriram Krishnamoorthy, Natarajan Kumaresan and Alimuddin Zumla**

**Institutional affiliations:**

Department of Urology & Renal transplantation, Sri Ramachandra Medical College & Research Institute, Chennai, Tamil Nadu, India  
**Prof. Sriram Krishnamoorthy** FRCS (Electronic address: sriramuro@gmail.com)

Department of Urology & Renal transplantation, Sri Ramachandra Medical College & Research Institute, Chennai, Tamil Nadu, India.  
**Prof. Natarajan Kumaresan** MD Electronic address: drknatarajan@yahoo.co.in )

Division of Infection and Immunity, Center for Clinical Microbiology, University College London, and the National Institute of Health Research Biomedical Research Centre at University College London Hospitals NHS Foundation Trust, London, UK.  
**(Sir Prof. Alimuddin Zumla** FRCP. Electronic address: a.zumla@ucl.ac.uk)

**Correspondence to:**

Prof. Sriram Krishnamoorthy  
Electronic address: sriramuro@gmail.com

**HIGHLIGHTS**

- Kidney transplantation is now universally performed in high and low Tuberculosis endemic countries.
- Tuberculosis is an important infectious disease cause of morbidity and death in transplant recipients.
- Tuberculosis can also cause loss of kidney allograft
- Screening of both donor and recipient for latent TB infection (LTBI) pre-transplant is required

- A high degree of clinical awareness of the possibility of active TB disease or LTBI is required for early diagnosis and treatment.

## Abstract

**Background:** Tuberculosis (TB) continues to be the commonest infectious disease cause of death worldwide. Tuberculosis is an important infectious disease cause of morbidity and death in renal transplant recipients. Tuberculosis can also cause loss of kidney allograft

**Objectives:** The purpose of this viewpoint is to highlight the issues related to prevention, diagnosis and treatment of tuberculosis in renal transplant recipients.

**Methods:** The PubMed database was searched for publications and guidelines on diagnosis and management of LTBI in renal transplantation. Publications on renal allograft recipients with LTBI and TB in post-operative period were also analysed. Specialist Society guidelines were also used.

**Findings:** Tuberculosis is one of the most important infectious diseases related cause of morbidity and death in transplant recipients. LTBI in allograft recipients continues to be a clinical management problem. It can occur either from donor kidney or from endogenous reactivation of latent tuberculosis infection or acquiring new *Mycobacterium tuberculosis* infection. Tuberculosis can also cause loss of kidney allograft.

**Conclusions:** Kidney transplantation is now universally performed in high and low Tuberculosis endemic countries. A high index of awareness of the possibility of TB disease or LTBI is required prior to renal transplant aligned to reduce renal allograft damage, morbidity and death due to tuberculous. WHO Management recommendations for LTBI screening and treatment should be followed.

**Keywords:** Latent tuberculosis infection (LTBI), renal transplantation, Interferon gamma assay, Tuberculin skin test, allograft, immune suppression.

## Introduction

Tuberculosis (TB) is the commonest infectious disease cause of death worldwide (WHO 2018a). An estimated 1.3 million people died of tuberculosis in 2017. Recent modelling re-calculations indicate that there are 1.7 billion people worldwide with latent *Mycobacterium tuberculosis* infection (LTBI) (Houben & Dodd 2016). Latent tuberculosis infection is defined by the World Health Organisation (WHO) as 'a state of persistent immune response to stimulation by *Mycobacterium tuberculosis* (*M.tb*) antigens with no evidence of clinically manifest active TB disease' (WHO, 2018b). Upto 10% of people with LTBI will progress to developing active TB disease during their lifetime. The highest risk for developing TB disease occurs when a range of risk factors for re-activation LTBI are when conditions of immunosuppression are present such as diabetes, malnutrition, HIV, and prescription of biologics and immunosuppressive agents including anti-rejection therapies in transplant patients (Hasan et al, 2018).

The incidence of active TB disease among renal transplant recipients is much higher than in general population (Lopez et al, 2010) and causes much morbidity and death occurring in these patients (Anand et al, 2017). TB is also responsible for loss of the renal allograft (transplanted kidney) in approximately one third of cases. Most of the TB cases in renal transplant recipients are due to re-activation of LTBI in the recipient or from donor kidney (Viana et al, 2018; Abad et al, 2018a; Abad et al, 2018b). TB can also occur due to increased susceptibility to acquiring new *M.tb* infection which rapidly progresses to miliary TB because of immunosuppressive therapy. Living donors who were born and lived in high TB endemic countries and migrated to low TB endemic areas may have higher rates of LTBI. The diagnosis and treatment of LTBI and active TB disease in donors and transplant recipients can be

quite challenging since the presentation is cryptic with non-specific symptoms and signs, and the diagnosis can easily be missed unless there is a high degree of awareness of the possibility of TB. The clinical presentation of TB occurring in transplant recipients is said to differ from that in the general population and an increased frequency of extrapulmonary TB is seen (Viana et al, 2018; Abad et al, 2018a; Abad et al, 2018b).

### **Screening and Diagnosis of LTBI**

Kidney transplantation is now universally performed in high and low TB endemic countries. All renal transplant recipients and their donors should undergo screening for LTBI and active TB disease prior to transplant. There is no gold standard test for diagnosing LTBI accurately. WHO recommends three tests for screening for LTBI: Tuberculin skin test (TST) and two interferon gamma release assays (IGRAs) namely, QuantiFERON®-TB (QFT) Gold In-Tube and T-SPOT® T (WHO 2018b). The TST may be unreliable in patients with advanced chronic kidney disease and in those on immunosuppressive agents (Guirao-Arrabal et al 2018). IGRAs are more specific to *M.tb* antigens and offer high specificity in detecting LTBI in immunosuppressed patients (Pai et al, 2014; Guirao-Arrabal et al, 2018). There is a scanty data on the sensitivities and specificities of IGRAs and TST in screening for LBI in renal transplant recipients. Based on extrapolating data from studies of haemodialysis patients, there are likely to be more false positive, false negative and indeterminate results of IGRAs in transplant recipients (Schluger and Burzynski, 2010). A systematic review and meta-analysis assessed the use of the TST and IGRAs (QFT and T-SPOT) in different organ transplantations including liver, renal and haemopoetic stem cell (Rahimifard et al, 2018). A higher rate of LTBI was found in patients undergoing renal transplantation than those undergoing other organ

transplantation, especially when IGRA tests were used compare to the TST. Thus IGRAs (both QFT and T-SPOT) have been shown to be more sensitive than the TST for the diagnosis of LTBI in patients requiring renal transplantation. Furthermore, post-transplant TB was more common in renal recipients than in liver transplant patients although many variables might have influenced this. In low resource settings, TST continues to be used for diagnosing LTBI.

A diagnostic approach for detection of active and latent tuberculosis has been outlined by Demir and Sever, 2017. Clinical workup of donors and transplant recipients to screen for LTBI and active TB is shown in Fig 1. The TBNET consensus group has summarized pathogenesis of LTBI in post-transplant patients (Bumbacea et al, 2012). A modification of the pathogenetic mechanisms is depicted in Fig 2. Fig 2A depicts the normal allograft transplantation, where neither the donor nor the recipient has TB infection. The post-transplant period is uneventful with the recipient having a normal post-operative period. Fig 2B depicts the donor kidney being infected by *M.tb* bacilli, which has gone unrecognized pre-transplant evaluation of the donor. The *M.tb* bacilli remain dormant within the transplant kidney for months to years. Due to immunosuppressive therapy, there is reactivation of LTBI to active TB disease. Fig 2C describes the LTBI in recipient that has gone undiagnosed during pre-transplant evaluation, which either continues to persist as LTBI or may undergo endogenous reactivation in the post-transplant period. Fig 2D depicts a scenario where both the donor and the recipient have been free from disease. Post-transplant period also has been uneventful until when the recipient gets exposed to *M.tb* bacilli and develops *denovo* LTBI.

Fig 3 illustrates a 44 year old male, who developed derived endogenous reactivation of LTBI which progressed to active TB disease of the kidney. The patient had

undergone a right open nephrectomy for non-functioning right kidney (Fig 3A, 3B). At the time of right nephrectomy, he had a normal functioning solitary left kidney. Three years later, he developed pelvi-ureteric junction stricture and mid ureteric stricture of the solitary left kidney and active TB was diagnosed. Anti-TB treatment and percutaneous nephrostomy did not prevent further deterioration of the renal function (Fig 3C). A left open nephrectomy was done and was on maintenance haemodialysis for 24 months. A live related renal transplantation was subsequently done 2 years later (Fig 3D). Four years after the transplant, there was a mild and gradual worsening of the renal biochemical parameters, though he was totally asymptomatic. In view of mildly rising serum creatinine levels, per cutaneous biopsy from the renal allograft was performed, which showed evidence of epithelioid granuloma with Langhans giant cells in the graft kidney, suggestive of TB in the renal allograft (Fig 3E). Patient had a symptomatic and biochemical improvement after initiation of anti-TB treatment treatment.

Various meta-analyses and subsequent guidelines recommend that all renal transplant candidates should be routinely screened for LTBI (Stagg et al, 2014). This should be done prior to transplant wherever practicable. British Thoracic Society guidelines suggest screening for LTBI where tuberculosis incidence rates are high or in patients with risk factors for developing tuberculosis in low incidence areas (Milburn et al British Thoracic Society Guidelines, 2010). Similarly those with epidemiologic risk factors such as history of TB in the past, previous rejection episodes, high-dose corticosteroids, diabetes mellitus and those living in endemic areas need to be evaluated with chest radiography and other screening tests as part of the screening for latent tuberculosis (Horne et al, 2013).

In low TB endemic countries, LTBI screening is recommended for population subgroups with a high prevalence of TB or those with a high likelihood of progression from LTBI to active disease. These include close contacts of patients with active tuberculosis, recently arrived foreign-born persons, drug users, incarcerated persons, and homeless individuals and were advised screening for LTBI (Horsburgh, 2004). Chest X-ray, detailed background history of previous exposure to patients with TB and risk factor assessment for travel or migration from endemic areas was the most frequent recommendation for LTBI screening in immunosuppressed individuals and those undergoing Solid Organ Transplant (SOT). (Hasan et al, 2018). Kowada recommends an active TB screening with IGRA for all renal allograft recipients with individualized risk assessment of each of the patients during LTBI treatment (Kowada, 2018). Those patients are recommended to initiate anti-TB treatment while they were on waiting list, aiming at a complete treatment schedule prior to transplantation. Meanwhile, if there is a need to undergo transplantation, it's worthwhile to temporarily stop the drug intake and recommence the treatment schedule to completion once patients were clinically stable.

### **Treatment of LTBI in donor and recipient**

As tuberculosis could directly affect the allograft function, it is extremely important to take utmost efforts to prevent transmission of TB infection in such select subgroup of patients. Every effort must be made to diagnose and treat LTBI and active tuberculosis in both live donor and recipient before transplantation. Treatment of LTBI should follow WHO 2018 guidelines (WHO, 2018b).

The Consensus Statement from the Spanish Group for the Study of Infectious Diseases in Transplant Recipients defines the indications for treatment of LTBI in



SOT recipients (Aguado et al, 2009). The WHO, 2018 guidelines outline the following treatment options for LTBI (WHO, 2018b).

- Isoniazid monotherapy for 6 months is recommended for treatment of LTBI in both adults and children in countries with high and low TB incidence.
- Rifampicin plus Isoniazid daily for 3 months should be offered as an alternative to 6 months of isoniazid monotherapy as preventive treatment for children and adolescents aged < 15 years in countries with a high TB incidence.
- Rifapentine and Isoniazid weekly for 3 months may be offered as an alternative to 6 months of Isoniazid monotherapy as preventive treatment for both adults and children in countries with a high TB incidence.
- The following options are recommended for treatment of LTBI in countries with a low TB incidence as alternatives to 6 months of isoniazid monotherapy: 9 months of isoniazid, or a 3-month regimen of weekly rifapentine plus isoniazid, or 3–4 months of isoniazid plus rifampicin, or 3–4 months of rifampicin alone.

Patients may find completing the long course of LTBI treatment difficult due to adverse effects and the interactions with immunosuppressive drugs and hence shorter courses of treatment are recommended. There is a need for well-designed prospective controlled cohort trials of short course LTBI treatment regimens in transplant recipients, which should also assess their efficacy, safety, hepatotoxicity and adherence to treatment.

### **Treatment of active TB**

Treatment of drug-sensitive and drug resistant active TB disease in renal transplant recipients should follow WHO treatment guidelines (WHO, 2017; WHO, 2018c). Treatment of patients with active tuberculosis detected after renal allograft

transplantation remains a challenging task. Hepatotoxicity is a serious dose limiting side effects of both Isoniazid and Rifampicin and this risk is further accentuated in patients with pre-existing liver disease and alcoholics. Peripheral neuropathy caused by Isoniazid can be prevented by co-administration of pyridoxine. Rifampicin interferes with the efficacy of many drugs by interfering with their metabolism. It may not be an ideal choice for patients taking oral contraceptives or HIV-infected individuals on protease inhibitors or non-nucleoside reverse- transcriptase inhibitors. Rifabutin has fewer pharmacologic interactions with antiretroviral agents than Rifampicin and can be used in combination with Isoniazid for the treatment of latent tuberculosis infection (Matteelli, 1999). Adherence to one specific standardized regime, completion of the recommended duration of the regime and a close monitoring and early identification of the adverse effects of the drugs would greatly enhance the effectiveness of treatment against LTBI. In order to achieve this, each transplant centre should design their individual protocol as per the evidence based guidelines that would enable a national audit programme be performed to improve the quality of health care for this subset LTBI patients (Maynard Smith, 2014). Proactive TB screening with IGRA with individualized risk assessment of each of the patients and monitoring the drug toxicity during LTBI treatment is to be recommended for all renal allograft recipients.

## **Conclusions**

Renal transplantation is now widely available globally. TB is a serious complication in renal transplant recipients and causes much morbidity and mortality. Due to immunosuppression, transplant recipients are at a higher risk of re-activating LTBI from within themselves or from the transplanted donor kidney. Several guidelines

are available and are consistent in recommending that all donors and recipients are routinely screened for LTBI and active TB disease prior to transplant whenever possible. A high degree of awareness of the possibility of TB is required in all renal transplant patients so that it can be diagnosed and treated early, reducing the risk of loss of allograft.

**Conflicts of Interest:** The authors have no conflict of interest to declare.

**Funding Source:** None

**Ethical Approval:** N/A

**Author declarations:** Authors declare no conflicts of interest

ACCEPTED MANUSCRIPT

## References

Abad CLR, Razonable RR. Donor derived Mycobacterium tuberculosis infection after solid-organ transplantation: A comprehensive review. *Transpl Infect Dis.* 2018a Oct;20(5):e12971.

Abad CLR, Razonable RR. Mycobacterium tuberculosis after solid organ transplantation: A review of more than 2000 cases. *Clin Transplant.* 2018b Jun;32(6):e13259.

Aguado JM, Torre-Cisneros J, Fortun J, Benito N, Meije Y, Doblaz A, Munoz P. Tuberculosis in solid-organ transplant recipients: consensus statement of the group for the study of infection in transplant recipients (GESITRA) of the Spanish Society of Infectious Diseases and Clinical Microbiology. *Clin Infect Dis.* 2009 May 1;48(9):1276-84.

Anand M, Nayyar E, Concepcion B, Salani M, Schaefer H. Tuberculosis in kidney transplant recipients: A case series. *World J Transplant.* 2017;7(3):213-221.

Bumbacea D, Arend SM, Eyuboglu F, Fishman JA, Goletti D, Ison MG, Jones CE, Kampmann B, Kotton CN, Lange C, Ljungman P, Milburn H, Morris MI, Muller E, Muñoz P, Nellore A, Rieder HL, Sester U, Theodoropoulos N, Wagner D, Sester M. The risk of tuberculosis in transplant candidates and recipients: a TBNET consensus statement. *Eur Respir J.* 2012 Oct;40(4):990-1013.

Demir E, Sever MS. Post-transplant Tuberculosis. *Exp Clin Transplant.* 2017 Feb;15 (Suppl 1):10-15.

Guirao-Arrabal E, Santos F, Redel-Montero J, Vaquero JM, Cantisán S, Vidal E, Torre-Giménez Á, Rivero A, Torre-Cisneros J. Risk of tuberculosis after lung transplantation: the value of pretransplant chest computed tomography and the impact of mTOR inhibitors and azathioprine use. *Transpl Infect Dis.* 2016 Aug;18(4):512-9.

Guirao-Arrabal E, Torre-Cisneros J. Tuberculin skin test, Interferon gamma release assays or just chest x-ray to study latent tuberculosis before solid organ transplantation? *Transpl Infect Dis*. 2018 Aug;20(4):e12920

Hasan T, Au E, Chen S, Tong A, Wong G. Screening and prevention for latent tuberculosis in immunosuppressed patients at risk for tuberculosis: a systematic review of clinical practice guidelines. *BMJ Open*. 2018 Sep 12;8(9):e022445.

Horne DJ, Narita M, Spitters CL, Parimi S, Dodson S, Limaye AP. Challenging issues in tuberculosis in solid organ transplantation. *Clin Infect Dis*. 2013 Nov;57(10):1473-82.

Horsburgh CR Jr. Priorities for the treatment of latent tuberculosis infection in the United States. *N Engl J Med* 2004;350:2060-7.

Houben RM, Dodd PJ. The Global Burden of Latent Tuberculosis Infection: A Re-estimation Using Mathematical Modelling. *PLoS Med*. 2016 Oct 25;13(10):e1002152.

Kowada A. Interferon-gamma release assay for tuberculosis screening of solid-organ transplant recipients is cost-effective. *J Infect*. 2018 Jul 24. pii: S0163-4453(18)30215-9.

Lopez de Castilla D, Schluger NW. Tuberculosis following solid organ transplantation. *Transpl Infect Dis*. 2010 Apr;12(2):106-12.

Matteelli A, Olliaro P, Signorini L, et al. Tolerability of twice-weekly rifabutin isoniazid combinations versus daily isoniazid for latent tuberculosis in HIV-infected subjects: a pilot study. *Int J Tuberc Lung Dis* 1999;3:1043-6.

Maynard-Smith L, Fernando B, Hopkins S, Harber M, Lipman M. Managing latent tuberculosis in UK renal transplant units: how does practice compare with published guidance? *Clin Med (Lond)*. 2014 Feb;14(1):26-9.

Milburn H, Ashman N, Davies P, Doffman S, Drobniewski F, Khoo S, Ormerod P, Ostermann M, Snelson C. Guidelines for the prevention and management of Mycobacterium tuberculosis infection and disease in adult patients with chronic kidney disease. British Thoracic Society Standards of Care Committee and Joint Tuberculosis Committee. *Thorax*. 2010 Jun;65(6):557-70.

Rahimifard N, Mahmoudi S, Mamishi S, Pourakbari B. Prevalence of latent tuberculosis infection in transplant candidates: A systematic review and meta-analysis. *Microb Pathog*. 2018 Oct 4;125:401-410.

Pai M, Denkinger CM, Kik SV, et al. Gamma interferon release assays for detection of Mycobacterium tuberculosis infection. *Clin Microbiol Rev*. 2014;27(1):3.

Schluger NW, Burzynski J. Recent advances in testing for latent TB. *Chest*. 2010;138(6):1456-63.

Stagg H. R, D. Zenner, R.J. Harris, L. Munoz, M.C. Lipman, I. Abubakar. Treatment of latent tuberculosis infection: a network meta-analysis. *Ann Intern Med*, 2014, 161: 419-428

Viana LA, Cristelli MP, Santos DW, Tavares MG, Dantas MTC, Felipe CR, Silva HT, Pestana JM. Influence of epidemiology, immunosuppressive regimens, clinical presentation, and treatment on kidney transplant outcomes of patients diagnosed with tuberculosis: A retrospective cohort analysis. *Am J Transplant*. 2018 Dec 17. doi: 10.1111/ajt.15220.

WHO 2018a. Global Tuberculosis Report 2018. Geneva: WHO, 2018. Available at [http://www.who.int/tb/publications/global\\_report/en/](http://www.who.int/tb/publications/global_report/en/) (accessed 6th November 2018).

WHO 2018b. Latent tuberculosis infection – updated consolidated guidelines for programmatic management. <https://www.who.int/tb/publications/latent-tuberculosis-infection/en/> (Accessed 7 Dec 2018)

WHO 2017. Guidelines for treatment of drug susceptible tuberculosis and patient care 2017 update.

<https://apps.who.int/iris/bitstream/handle/10665/255052/9789241550000-eng.pdf?sequence=1> (Accessed January 29<sup>th</sup> 2019)

WHO 2018c. WHO treatment guidelines for rifampicin- and multidrug-resistant tuberculosis, 2018 update <https://www.who.int/tb/areas-of-work/drug-resistant-tb/treatment/gdg-meeting-mdr-rr-tb-treatment-2018-update/en/>

ACCEPTED MANUSCRIPT

**Figure 1****Clinical workup of donors and transplant recipients to screen for LTBI and active TB****HISTORY:**

- Contact with patient with active pulmonary TB
- Previous TB treatment

**SYMPTOMS:**

- Chronic cough, night sweats, weight loss, anorexia

**FULL CLINICAL EXAMINATION:**

- Examine for active pulmonary TB
- Exclude extra pulmonary TB

**INVESTIGATIONS:**

- Full Blood Count and differential
- C-Reactive protein (CRP)
- Renal and liver function Tests
- Microscopy (for acid fast bacilli) and culture for *M.tb* (Sputum and early morning urine samples)
- Histology of biopsy or aspirates (acid fast bacilli and granuloma)
- GeneXpert MTB/Rif Assay (on sputum, urine or biopsy)

**TESTS FOR LTBI:**

- Tuberculin skin test (TST)
- IGRA test (either TSPOT.TB or QuantiFERON)

**IMAGING:**

- Chest X-ray
- Renal ultrasound
- MRI or CT scan (where indicated)
- PET/CT scan (where indicated)



FIG 2 : Pathogenetic mechanisms of LTBI and active TB occurrence in renal allograft recipients

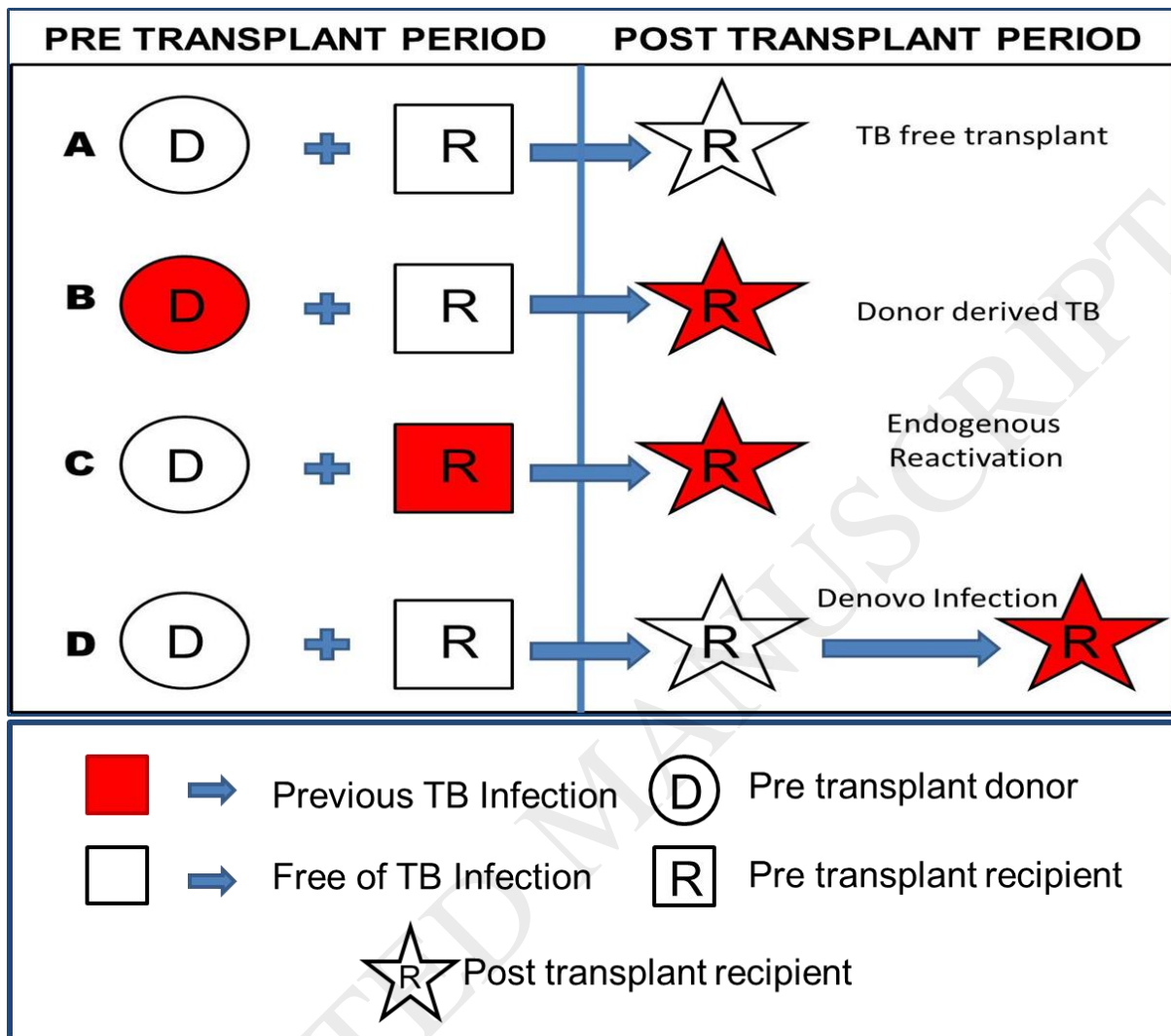


FIG 3 : Imaging and histological features of a case of endogenous reactivation of LTBI progressing to active TB disease.

FIG 3A. Intravenous urogram and FIG 3B ultrasonography showing normal functioning solitary left kidney

FIG 3C. Intravenous urogram showing hydronephrosis and nephrostomy of the left kidney (three years later)

FIG 3D. MRI showing transplanted kidney (allograft)

FIG 3E. Histology of allograft biopsy:

(Upper panel: Epithelioid granulomas with Langhans Giant cells)

(Lower left: Granulomas with caseous necrosis)

(Lower right:

