

## S-[18F]THK-5117-PET and [11C]PIB-PET Imaging in Idiopathic Normal Pressure Hydrocephalus (iNPH) in Relation to Confirmed Amyloid- $\beta$ Plaques and Tau in Brain Biopsies

Running head:

Key Words: Idiopathic Normal Pressure Hydrocephalus, Alzheimer's disease, positron emission tomography, tau, amyloid-beta

Ville Leinonen, PhD, MD<sup>a</sup>, Tuomas Rauramaa, PhD, MD<sup>b</sup>, Astrid Bottelbergs, PhD<sup>c</sup>, Ina Tesseur, PhD<sup>c</sup>, Peter Van Der Ark, PhD<sup>c</sup>, Darrel Pemberton, PhD<sup>c</sup>, Anne M Koivisto, MD, PhD<sup>d</sup>, Juha E Jääskeläinen, MD, PhD<sup>a</sup>, Mikko Hiltunen, PhD<sup>d,e</sup>, Sanna-Kaisa Herukka, MD, PhD<sup>d</sup>, Kaj Blennow, MD, PhD<sup>f,g</sup>, Henrik Zetterberg, MD, PhD<sup>f,g,h,i</sup>, Jarkko Johansson, PhD<sup>j</sup>, Pekka Jokinen, MD PhD<sup>j,k</sup>, Johanna Rokka, PhD<sup>j</sup>, Semi Selin, PhD<sup>j</sup>, Merja Haaparanta-Solin, PhD<sup>l,m</sup>, Olof Solin, PhD<sup>j,n,o,p</sup>, Nobuyuki Okamura, MD, PhD<sup>q</sup>, Hartmuth C Kolb, PhD<sup>r</sup> and Juha O. Rinne, MD, PhD<sup>j,s</sup>

<sup>a</sup>Institute of Clinical Medicine – Neurosurgery, University of Eastern Finland and Department of Neurosurgery, Kuopio University Hospital, Kuopio, Finland

<sup>b</sup>Institute of Clinical Medicine – Pathology, University of Eastern Finland and Department of Pathology, Kuopio University Hospital, Kuopio, Finland

<sup>c</sup>Janssen Research & Development, A Division of Janssen Pharmaceutica, Beerse, Belgium,

<sup>d</sup>Institute of Clinical Medicine – Neurology, University of Eastern Finland and Department of Neurology, Kuopio University Hospital, Kuopio, Finland

<sup>e</sup>Institute of Biomedicine, University of Eastern Finland, Kuopio, Finland

<sup>f</sup>Clinical Neurochemistry Laboratory, Sahlgrenska Academy Hospital, Mölndal, Sweden

<sup>g</sup>Dept. of Psychiatry and Neurochemistry, Institute of Neuroscience and Physiology, Sahlgrenska Academy at University of Gothenburg, Mölndal, Sweden

<sup>h</sup>Department of Molecular Neuroscience, Institute of Neurology, University College London, Queen, Square, United Kingdom

<sup>i</sup>UK Dementia Research Institute, London, United Kingdom

<sup>j</sup>Turku PET Centre University of Turku, Turku, Finland

<sup>k</sup>Department of Neurosurgery, Turku University Hospital, Turku, Finland

<sup>l</sup>PET Preclinical Imaging Laboratory, Turku PET Centre, University of Turku, Turku, Finland.

<sup>m</sup>MediCity Research Laboratory, University of Turku, Turku, Finland

<sup>n</sup>Radiopharmaceutical Chemistry Laboratory, Turku PET Centre, University of Turku, Turku, Finland

<sup>o</sup>Department of Chemistry, University of Turku, Turku, Finland

<sup>p</sup>Accelerator Laboratory, Turku PET Centre, Åbo Akademi University, Turku, Finland

<sup>q</sup>Tohoku Medical and Pharmaceutical University, Sendai, Japan

<sup>r</sup>Janssen Research and Development, San Diego, CA, USA

<sup>s</sup>Division of Clinical Neurosciences, Turku University Hospital, Turku, Finland.

### Corresponding author

Ville Leinonen MD, PhD

Department of Neurosurgery

Kuopio University Hospital

P.O.Box 100, FIN-70029 KYS, Finland

tel. +358-40-514 7320, +358-44-717 2303

fax. +358-17-173 916

e-mail: ville.leinonen@kuh.fi

Number of characters in the title:

Number of characters in the running head:

Number of words in the abstract:

Number of words in the in the body of the manuscript:

Number of figures:

Number of tables:

## Abstract

**Introduction:** A definite diagnosis of Alzheimer's disease (AD) can only be made at autopsy with the confirmation of hallmark lesions, *i.e.*, amyloid  $\beta$  ( $A\beta$ ) aggregates in the neuropil together with hyperphosphorylated tau ( $HP\tau$ ) as neuropil threads and intraneuronal tangles. Half of shunted idiopathic normal pressure hydrocephalus (iNPH) patients eventually become demented despite initial mitigation of neurological symptoms after shunt, often due to concomitant AD pathology. Brain samples taken during shunt surgery offer a unique opportunity to validate new biomarkers as diagnostic and prognostic tools of iNPH and AD. The aim of this study was to evaluate the association between the cerebrospinal fluid (CSF) AD biomarkers ( $A\beta_{1-42}$ , total tau, and P-tau<sub>181</sub>), tau ( $[^{18}F]$ THK-5117) and amyloid ( $[^{11}C]$ PIB) PET against AD lesions in brain biopsy to clarify their potential role in differential diagnostics and to detect comorbid AD in iNPH.

**Methods:** Fourteen selected iNPH patients (7 male) with previous shunt surgery including right frontal cortical brain biopsy (mean age at biopsy 72.4 years) underwent brain MR imaging,  $[^{11}C]$ PIB PET and S- $[^{18}F]$ THK-5117 PET imaging (mean age at imaging 75.4 years; mean MMSE 23.3) in Turku PET Centre.

**Results:** Four patients had normal brain biopsy, 7 patients had amyloid- $\beta$  ( $A\beta$ ) plaques (4G8), 2 patients both  $A\beta$  plaques and hyperphosphorylated tau ( $HP\tau$ , AT8) and one patient had only  $HP\tau$ . Mean CSF  $A\beta_{1-42}$  was 790, total tau 176, and P-tau<sub>181</sub> 32.5. As expected increased brain biopsy  $A\beta$  (both 4G8 and Thioflavin-S) was associated with higher  $[^{11}C]$ PIB uptake in PET. However, S- $[^{18}F]$ THK-5117 uptake did not show any statistically significant correlation with either brain biopsy  $HP\tau$  or CSF P-tau<sub>181</sub> or total tau.

**Discussion:** Neuropathologically verified  $A\beta$  pathology was well associated with  $[^{11}C]$ PIB-PET, further corroborating the specificity of this PET tracer to  $A\beta$ . However, S- $[^{18}F]$ THK-5117 lacked clear association with neuropathologically verified tau pathology in brain biopsy, which may be at least partially due to the off-target binding properties of this tracer.

**Keywords:** Tau, PET, THK-5117, PIB, Neuropathology, Alzheimer's disease, Normal-pressure hydrocephalus

## Introduction

Idiopathic normal pressure hydrocephalus (iNPH) is a progressive brain disease caused by disturbance in cerebrospinal fluid (CSF) dynamics resulting in ventriculomegaly (Relkin et al. 2005, Andren et al. 2014). Classical clinical characteristics are impaired gait, cognitive decline and urinary incontinence (Hakim & Adams 1965). The only treatment currently available is removal of excess CSF through a neurosurgically implanted shunt, which usually alleviates symptoms in properly selected patients (Kazui et al. 2015). However, the long-term benefit of operative treatment is only modest and concomitant Alzheimer's disease (AD) seems to be frequent (Leinonen et al. 2012, Koivisto et al. 2013).

Non-invasive detection of tau deposits in the brain can be used to diagnose, monitor, and predict AD progression. Tau positron emission tomography (PET) radiolabelled probes such as T807, THK-5117, and PBB3 can image the pathology of the disease *in vivo*. Several 18F-labeled tau imaging agents like [<sup>18</sup>F]-THK-5351, [<sup>18</sup>F]-T807 ([<sup>18</sup>F]-AV-1451), and [<sup>18</sup>F]-RO6958948 are presently under evaluation in clinical studies and clinical trials worldwide. This imaging methodology could be applied to enable preclinical diagnoses and to study the effect of disease-modifying drugs for AD (Furumoto et al. 2017).

The [<sup>18</sup>F]THK-5117 tracer could provide information on tau regional distribution. In clinical PET studies, [<sup>18</sup>F]THK-5117 binding in the temporal lobe clearly distinguished patients with AD from healthy elderly subjects (Harada et al. 2015). Compared with the ligand for fibrillary  $\beta$ -amyloid [<sup>11</sup>C]PIB, [<sup>18</sup>F]THK-5117 retention was higher in the medial temporal cortex. In post mortem samples, the distribution of [<sup>3</sup>H]THK-5117 matched the tau immunohistochemistry (also the Harada ref?). In addition, microautoradiography showed the selective binding ability of [<sup>3</sup>H]THK-5117 to neurofibrillary tangles and [<sup>3</sup>H]PIB binding to A $\beta$  plaques. THK-5117 did not bind to diffuse A $\beta$  deposits in the striatal sections which were labelled with [<sup>3</sup>H]PIB (Harada et al. 2015). A longitudinal PET-study using [<sup>18</sup>F]THK-5117, visualized the pathologic time course of neurofibrillary tangle formation in relation to cognitive decline (Ishiki et al. 2015).

Except for PET biomarkers, there are a set of AD CSF biomarkers reflecting the key pathology of the disease, including A $\beta$  deposition (A $\beta$ <sub>1-42</sub>), tau pathology (P-tau<sub>181</sub>), and intensity of neurodegeneration (total tau) (REF). A very large number of studies have consistently found a reduced CSF level of A $\beta$ <sub>1-42</sub> in AD, accompanied by increases in both P-tau<sub>181</sub> and total tau (REF), the so called "AD CSF profile". Importantly, a high concordance between normal and abnormal results on for CSF A $\beta$ <sub>1-42</sub> and amyloid PET has been found in a large number of studies (REF),

The aim of this study was to evaluate the association between the core CSF AD biomarkers, tau ([<sup>18</sup>F]THK-5117) and amyloid ([<sup>11</sup>C]PIB) PET against AD lesions in brain biopsy to clarify their potential role in differential diagnostics and to detect comorbid AD in iNPH.

## Methods

### *Study population*

Altogether 176 patients underwent shunt surgery due to iNPH in Kuopio Neurosurgery between December 2010 and December 2015. Out of them, 14 subjects (in two cases also their next of kin) gave an informed consent to participate in this study (Table 1). The study was approved by the Kuopio University Hospital (KUH) Research Ethical Committee

KUH iNPH diagnostic work-up included systematic CSF sampling from all patients suspected from iNPH according to three-step prognostic test protocol. Shunt surgery was recommended with CSF tap test of at least 20% improvement in gait speed. In case of a negative tap test, lumbar infusion test was performed, where a pathological finding was considered as conductance  $\leq 10$  (Malm et al. 2013, Junkkari et al. 2017). Finally, patients with negative findings in both of the above tests underwent 24-hour monitoring of intraventricular pressure (ICP).

Seven patients were shunted according to the positive response to CSF removal (tap-test), four according to pathological finding in lumbar infusion test (negative tap-test), two according to 24-hour ICP monitoring (negative tap-test and normal infusion test) and one according to clinical and radiological characteristics (negative tap-test and normal infusion test).

### *Brain biopsy*

Insertion of ventricular catheter for CSF shunt or ICP monitoring included of obtaining cylindrical cortical brain biopsies of 2–5 mm in diameter and 3 to 10 mm in length through the burr hole. A part of the sample was placed in buffered formalin and after overnight fixation was embedded in paraffin. Consecutive 7  $\mu\text{m}$  thick sections were stained with hematoxylin-eosin (HE) and immunohistochemistry (IHC) including AT8, p62, and A $\beta$  [6F/3D labelling both parenchymal aggregates i.e. plaques as well as cerebral amyloid angiopathy (CAA) and 4G8 labelling primarily parenchymal A $\beta$  aggregates and especially fleecy and diffuse aggregates seen at early stages]. Stained sections were assessed under light microscopy at x100 to x200 magnifications. Cellular or neuritic HPT-structures were sought for and rated as negative or positive. In A $\beta$ -IHC stained sections, fleecy, diffuse and dense plaques were assessed (Dr Rauramaa) and the staining results of A $\beta$  were semiquantitatively rated (Seppälä et al. 2012). In addition, thioflavin-S staining was done to evaluate fibrillar amyloid.

### *CSF sampling and analysis*

CSF samples were obtained by lumbar puncture during diagnostic tap-test in outpatient clinic and from the right lateral ventricle after insertion of ventricular catheter during shunt procedure. Low protein binding PP tubes were used. Samples were centrifuged, divided into 1ml tubes and frozen at  $-80^{\circ}\text{C}$ . CSF AD biomarkers (total tau, phospho-tau<sub>181</sub>, A $\beta$ <sub>1-42</sub>) were measured in University of Eastern Finland (UEF) Neurology using INNOTEST ELISA kits (Fujirebio Europe, Ghent, Belgium).

Genomic DNA was extracted from white blood cells and genotyped for *APOE* in UEF Neurology.

### *MR imaging*

Additional brain MR scans were performed in all subjects in Turku PET Center. T1-weighted and T2-weighted MR images were obtained using 3.0-Tesla machine.

### *[<sup>11</sup>C]PIB Amyloid PET imaging*

[<sup>11</sup>C]PIB was produced by the reaction of 6-OH-BTA-0 and [<sup>11</sup>C]methyl triflate as reported earlier (Leinonen et al. 2008). [<sup>11</sup>C]PIB was injected intravenously as a bolus and patients underwent a 90

min dynamic PET scan with HRRT PET scanner (Siemens Medical Solutions, Knoxville, TN, USA) in the 3D scanning mode. PET imaging was performed without the knowledge of the neuropathological data of the patient.

Data analysis. Before the voxel-based statistical analysis and automated region-of-interest (ROI) analysis, dynamic images are first computed into quantitative parametric images. Parametric images representing [<sup>11</sup>C]PIB uptake in each voxel were calculated as a region-to-cerebellum ratio of the radioactivity concentration over 60 to 90 minutes as described earlier (Leinonen et al. 2008). Cerebellar data are extracted by using automated ROI analysis as described below.

Statistical Parametric Mapping (SPM) analysis. Voxel-based statistical analyses of [<sup>11</sup>C]PIB data was performed using Statistical Parametric Mapping version 8 (SPM8) and Matlab for Windows (Math Works, Natick, MA). Briefly, spatial normalization of parametric images was performed using a ligand-specific [<sup>11</sup>C]PIB template. Ligand-specific template was generated in a two-step procedure. First, the control subjects' MRI data were used to map [<sup>11</sup>C]PIB sum images into MNI (Montreal Neurological Institute) space and averaged, and second, the study subjects' [<sup>11</sup>C]PIB sum images were normalized using the controls' average image as a reference, after which all data was averaged to form the final template. MRI data of study subjects' could not be used for normalization due to shunt induced metal artefacts. The between-group comparison equalling two-sample t-tests and testing the difference in ratio values was performed as an explorative analysis covering the whole brain. Multiple comparison corrected p-values below 0.05 were considered significant.

Automated ROI analysis. To obtain quantitative regional values of [<sup>11</sup>C]PIB uptake, automated ROI analysis was performed bilaterally on the prefrontal cortex (PFC), lateral temporal cortex (LTC), medial temporal lobe (MTL), anterior and posterior cingulate cortices (ACC, PCC), inferior parietal lobe (IPL), lateral occipital cortex (LOC), precuneus (Prec), striatum (STR), and cerebellar cortex (CER). A composite score of [<sup>11</sup>C]PIB was calculated within PFC, LTC, ACC, PCC and Prec. ROI definitions were generated on the basis of control subjects' data by using automatic FreeSurfer (<http://surfer.nmr.mgh.harvard.edu/>) MRI parcellations projected in the MNI space; union of mask voxels formed a final ROI mask. The average regional ratio values of [<sup>11</sup>C]PIB uptake were calculated using these ROIs from spatially normalized parametric ratio images (see SPM analyses above) and subjected to statistical analysis conducted using SPSS for Windows.

#### *S-[<sup>18</sup>F]THK-5117 Tau PET imaging*

S-[<sup>18</sup>F]THK-5117 was synthesized in the Turku PET Centre using a previously described method (Okamura et al. 2013) with slight modifications. The specific activity of S-[<sup>18</sup>F]THK-5117 was >1 TBq/μmol, and radiochemical purity was >98%.

S-[<sup>18</sup>F]THK-5117 was injected intravenously as a bolus and all patients underwent a 90 min dynamic PET scan with HRRT PET scanner (Siemens Medical Solutions, Knoxville, TN, USA) in the 3D scanning mode. S-[<sup>18</sup>F]THK-5117 PET images from 60 to 80 min post-injection were used for the following analysis.

Data analysis. Similar to [<sup>11</sup>C]PIB analysis, parametric S-[<sup>18</sup>F]THK-5117 uptake images were calculated as tissue-to-cerebellum ratio over 60 to 90 minutes from the tracer injection. A ligand-specific S-[<sup>18</sup>F]THK-5117 template was generated by using the same two-step procedure as for [<sup>11</sup>C]PIB (see above), and the same ROIs are considered as for [<sup>11</sup>C]PIB (see above).

#### *Statistical analysis*

For statistical analysis of demographic and clinical data, IBM SPSS Statistics 24.0 software was used. Values of  $P < .05$  were considered significant.

## Results

Four patients had normal brain biopsy, 7 patients had amyloid- $\beta$  ( $A\beta$ ) plaques (4G8) and 2 patients both  $A\beta$  plaques and hyperphosphorylated tau (HPT, AT8). One patient (#3) had only HPT without any  $A\beta$ , which was confirmed 6 months later in autopsy (patchy HPT in frontal, occipital and temporal cortex, hippocampus and entorhinal cortex fulfilling Braak stage III, but not in basal ganglia).

Mean CSF  $A\beta_{1-42}$  was  $790\pm 205$ , total tau  $176\pm 153$ , and p-tau<sub>181</sub>  $32.5\pm 14$  (ng/L).

All patients underwent brain MRI, [<sup>11</sup>C]PIB and S-[<sup>18</sup>F]THK-5117 PET average of 3 years after the brain biopsy (range from 4 months to 6 years) (Figure 1).

As expected, brain biopsy measures of  $A\beta$  deposition by both 4G8 immunohistochemistry ( $r = .60$ ,  $P = .02$ ) and Thioflavin-S staining ( $r = .63$ ,  $P = .02$ ) were associated with [<sup>11</sup>C]PIB uptake (composite score) in PET (Figure 1A-B) and CSF  $A\beta_{1-42}$  (?). Further, both CSF  $A\beta_{1-42}$  ( $r = -0.58$ ,  $P = .03$ ) and p-tau<sub>181</sub> ( $r = .76$ ,  $P = .01$ ) levels correlated with [<sup>11</sup>C]PIB uptake (composite score) in PET (Figure 2A-B).

However, S-[<sup>18</sup>F]THK-5117 uptake (composite score, prefrontal cortex or mesial temporal cortex) did not show statistically significant correlation ( $r = -.370 - .233$ ) with either brain biopsy HPT or CSF p-tau<sub>181</sub> or total tau (Figure 2C-D).

A notable off-target binding of S-[<sup>18</sup>F]THK-5117 is seen in basal ganglia of all the 14 cases (Figure 1). Furthermore, no visible binding is seen in medial temporal lobe, which could be expected at least in cases 1-3 and with high probability also in cases 9-10.

## Discussion

Neuropathologically verified A $\beta$  pathology was associated with [<sup>11</sup>C]PIB-PET as expected. Further CSF A $\beta$ <sub>1-42</sub> levels showed a strong negative correlation with [<sup>11</sup>C]PIB uptake composite score, in agreement with previous studies (REF=the same as in the Intro). In addition, also CSF levels of p-tau<sub>181</sub> correlated with [<sup>11</sup>C]PIB uptake, probably reflecting that cases with amyloid deposition also often have tau pathology.

However, S-[<sup>18</sup>F]THK-5117 showed no clear association either with neuropathologically verified tau pathology in brain biopsy or CSF total tau or phospho-tau, which may be at least partially due to known (?) off-target binding properties of this tracer (refs).

The mean interval from biopsy to PET was 3 years but is unlikely to explain the lack of association between brain biopsy hyperphosphorylated tau pathology and S-[<sup>18</sup>F]THK-5117 uptake in PET, since tau pathology in the brain is expected to increase rather than decrease over time.

*In vitro*, THK-5117 is indicated to bind pathological tau (Okamura et al. 2013). Off-target binding of [<sup>18</sup>F]THK-5351 (and [<sup>18</sup>F]THK-5317) into MAO-B, which is concentrated in basal ganglia, is different from typical distribution of tau pathology (Ng et al. 2017). The potential explanations for the lack of association of S-[<sup>18</sup>F]THK-5117 and brain tissue tau pathology can be the confounding effect of the off-target binding, insensitivity of the tracer to detect the tau pathology or the low number of cases with tau-positive tissue in our patient population.

Our finding regarding the lack of correlation between CSF total tau or phospho-tau and S-[<sup>18</sup>F]THK-5117 uptake is not in line with a previous study reporting a moderate correlation between CSF total-tau and phosphorylated-tau levels with [<sup>18</sup>F]-AV-1451 tau PET retention despite the off-target binding of [<sup>18</sup>F]-AV-1451 in the basal ganglia (Mattson et al. 2017). The lack of the association with CSF tau or phosphorylated tau and low uptake even in medial temporal lobe in patients with frontal cortical tau and widespread amyloid pathology indicate potential insensitivity of S-[<sup>18</sup>F]THK-5117 to detect tau pathology. Furthermore, the radiochemical purity of S-[<sup>18</sup>F]THK-5117 was excellent and is thus unlikely an explanation for our negative findings.

After all, it seems that the association between *in vivo* amyloid PET (measured by [<sup>11</sup>C]PIB) and tissue A $\beta$  is stronger than the association between *in vivo* tau measured by S-[<sup>18</sup>F]THK-5117 and tissue pathology of tau. Further studies with larger samples of patients with different tau tracers are urgently needed.

The detection of simultaneous A $\beta$  and tau pathology in iNPH is important since that may indicate poorer and especially shorter response for CSF shunt surgery compared with no pathology (Hamilton et al. 2010, Junkkari et al. 2017).



**Acknowledgments**

We would like to acknowledge Marita Parviainen, RN, for patient handling. The study was funded by Janssen Pharmaceutica NV.

## References

- Andrén K, Wikkelsø C, Tisell M, Hellström P. Natural course of idiopathic normal pressure hydrocephalus. *J Neurol Neurosurg Psychiatry*. 2014 Jul;85(7):806-10
- Furumoto S, Tago T, Harada R, Kudo Y, Okamura N. 18F-Labeled 2-Arylquinoline Derivatives for Tau Imaging: Chemical, Radiochemical, Biological and Clinical Features. *Curr Alzheimer Res*. 2017;14(2):178-185.
- Hakim S, Adams RD. The special clinical problem of symptomatic hydrocephalus with normal cerebrospinal fluid pressure. Observations on cerebrospinal fluid hydrodynamics. *J Neurol Sci* 1965 Jul-Aug;2(4):307-27.
- Hamilton R, Patel S, Lee EB, Jackson EM, Lopinto J, Arnold SE, Clark CM, Basil A, Shaw LM, Xie SX, Grady MS, Trojanowski JQ. Lack of shunt response in suspected idiopathic normal pressure hydrocephalus with Alzheimer disease pathology. *Ann Neurol*. 2010 Oct;68(4):535-40. doi: 10.1002/ana.22015.
- Harada R, Okamura N, Furumoto S, Furukawa K, Ishiki A, Tomita N, Hiraoka K, Watanuki S, Shidahara M, Miyake M, Ishikawa Y, Matsuda R, Inami A, Yoshikawa T, Tago T, Funaki Y, Iwata R, Tashiro M, Yanai K, Arai H, Kudo Y. [(18)F]THK-5117 PET for assessing neurofibrillary pathology in Alzheimer's disease. *Eur J Nucl Med Mol Imaging*. 2015 Jun;42(7):1052-61. doi: 10.1007/s00259-015-3035-4.
- Ishiki A, Okamura N, Furukawa K, Furumoto S, Harada R, Tomita N, Hiraoka K, Watanuki S, Ishikawa Y, Tago T, Funaki Y, Iwata R, Tashiro M, Yanai K, Kudo Y, Arai H. Longitudinal Assessment of Tau Pathology in Patients with Alzheimer's Disease Using [18F]THK-5117 Positron Emission Tomography. *PLoS One*. 2015 Oct 13;10(10):e0140311. doi: 10.1371/journal.pone.0140311.
- Jonasson M, Wall A, Chiotis K, Saint-Aubert L, Wilking H, Sprycha M, Borg B, Thibblin A, Eriksson J, Sörensen J, Antoni G, Nordberg A, Lubberink M. Tracer Kinetic Analysis of (S)-<sup>18</sup>F-THK5117 as a PET Tracer for Assessing Tau Pathology. *J Nucl Med*. 2016 Apr;57(4):574-81. doi: 10.2967/jnumed.115.158519.
- Junkkari A, Häyrynen A, Rauramaa T, Sintonen H, Nerg O, Koivisto AM, Roine RP, Viinamäki H, Soininen H, Luikku A, Jääskeläinen JE, Leinonen V. Health-related quality-of-life outcome in patients with idiopathic normal-pressure hydrocephalus - a 1-year follow-up study. *Eur J Neurol*. 2017 Jan;24(1):58-66. doi: 10.1111/ene.13130.
- Kazui H, Miyajima M, Mori E, Ishikawa M; SINPHONI-2 Investigators. Lumboperitoneal shunt surgery for idiopathic normal pressure hydrocephalus (SINPHONI-2): an open-label randomised trial. *Lancet Neurol*. 2015 Jun;14(6):585-94.
- Koivisto AM, Alafuzoff I, Savolainen S, Sutela A, Rummukainen J, Kurki M, Jääskeläinen JE, Soininen H, Rinne J, Leinonen V. Poor cognitive outcome in shunt-responsive idiopathic normal pressure hydrocephalus. *Neurosurgery*. 2013 Jan;72(1):1-8. doi: 10.1227/NEU.0b013e31827414b3.
- Koivisto AM, Kurki MI, Alafuzoff I, Sutela A, Rummukainen J, Savolainen S, Vanninen R, Jääskeläinen JE, Soininen H, Leinonen V. High Risk of Dementia in Ventricular Enlargement with Normal Pressure Hydrocephalus Related Symptoms. *J Alzheimers Dis*. 2016 Mar 22;52(2):497-507. doi: 10.3233/JAD-150909.

- Leinonen V, Alafuzoff I, Aalto S, Suotunen T, Savolainen S, Nägren K, Tapiola T, Pirttilä T, Rinne J, Jääskeläinen JE, Soininen H, Rinne JO. Assessment of beta-amyloid in a frontal cortical brain biopsy specimen and by positron emission tomography with carbon 11-labeled Pittsburgh Compound B. *Arch Neurol*. 2008 Oct;65(10):1304-9. doi: 10.1001/archneur.65.10.noc80013.
- Leinonen V, Koivisto AM, Savolainen S, Rummukainen J, Sutela A, Vanninen R, Jääskeläinen JE, Soininen H, Alafuzoff I. Post-mortem findings in 10 patients with presumed normal-pressure hydrocephalus and review of the literature. *Neuropathol Appl Neurobiol*. 2012 Feb;38(1):72-86. doi: 10.1111/j.1365-2990.2011.01195.x
- Leinonen V, Rinne JO, Virtanen KA, Eskola O, Rummukainen J, Huttunen J, von Und Zu Fraunberg M, Nerg O, Koivisto AM, Rinne J, Jääskeläinen JE, Buckley C, Smith A, Jones PA, Sherwin P, Farrar G, McLain R, Kailajärvi M, Heurling K, Grachev ID. Positron emission tomography with [<sup>18</sup>F]flutemetamol and [<sup>11</sup>C]PiB for in vivo detection of cerebral cortical amyloid in normal pressure hydrocephalus patients. *Eur J Neurol*. 2013 Jul;20(7):1043-52. doi: 10.1111/ene.12102.
- Lemoine L, Saint-Aubert L, Marutle A, Antoni G, Eriksson JP, Ghetti B, Okamura N, Nennesmo I, Gillberg PG, Nordberg A. Visualization of regional tau deposits using (3)H-THK5117 in Alzheimer brain tissue. *Acta Neuropathol Commun*. 2015 Jul 2;3:40. doi: 10.1186/s40478-015-0220-4.
- Malm J, Graff-Radford NR, Ishikawa M, Kristensen B, Leinonen V, Mori E, Owler BK, Tullberg M, Williams MA, Relkin NR. Influence of comorbidities in idiopathic normal pressure hydrocephalus - research and clinical care. A report of the ISHCSF task force on comorbidities in INPH. *Fluids Barriers CNS*. 2013 Jun 10;10(1):22. doi: 10.1186/2045-8118-10-22.
- Malm J, Jacobsson J, Birgander R, Eklund A. Reference values for CSF outflow resistance and intracranial pressure in healthy elderly. *Neurology*. 2011 Mar 8;76(10):903-9. doi: 10.1212/WNL.0b013e31820f2dd0.
- Mattsson N, Schöll M, Strandberg O, Smith R, Palmqvist S, Insel PS, Hägerström D, Ohlsson T, Zetterberg H, Jögi J, Blennow K, Hansson O. 18F-AV-1451 and CSF T-tau and P-tau as biomarkers in Alzheimer's disease. *EMBO Mol Med*. 2017 Jul 25. pii: e201707809. doi: 10.15252/emmm.201707809
- Ng KP, Pascoal TA, Mathotaarachchi S, Therriault J, Kang MS, Shin M, Guiot MC, Guo Q, Harada R, Comley RA, Massarweh G, Soucy JP, Okamura N, Gauthier S, Rosa-Neto P. Monoamine oxidase B inhibitor, selegiline, reduces <sup>18</sup>F-THK5351 uptake in the human brain. *Alzheimers Res Ther*. 2017 Mar 31;9(1):25. <https://www.ncbi.nlm.nih.gov/pubmed/28359327>
- Okamura N, Furumoto S, Harada R, Tago T, Yoshikawa T, Fodero-Tavoletti M, Mulligan RS, Villemagne VL, Akatsu H, Yamamoto T, Arai H, Iwata R, Yanai K, Kudo Y. Novel 18F-labeled arylquinoline derivatives for noninvasive imaging of tau pathology in Alzheimer disease. *J Nucl Med*. 2013 54(8):1420-7.
- Pyykkö OT, Lumela M, Rummukainen J, Nerg O, Seppälä TT, Herukka SK, Koivisto AM, Alafuzoff I, Puli L, Savolainen S, Soininen H, Jääskeläinen JE, Hiltunen M, Zetterberg H, Leinonen V. Cerebrospinal fluid biomarker and brain biopsy findings in idiopathic normal pressure hydrocephalus. *PLoS One*. 2014 Mar 17;9(3):e91974. doi: 10.1371/journal.pone.0091974.
- Relkin N, Marmarou A, Klinge P, Bergsneider M, Black PM. Diagnosing idiopathic normal-pressure hydrocephalus. *Neurosurgery*. 2005 Sep;57(3 Suppl):S4-16.
- Seppälä TT, Nerg O, Koivisto AM, Rummukainen J, Puli L, Zetterberg H, Pyykkö OT, Helisalmi S, Alafuzoff I, Hiltunen M, Jääskeläinen JE, Rinne J, Soininen H, Leinonen V, Herukka SK. CSF

biomarkers for Alzheimer disease correlate with cortical brain biopsy findings. *Neurology*. 2012 May 15;78(20):1568-75. doi: 10.1212/WNL.0b013e3182563bd0.

Table 1. Patient characteristics and immunohistochemical findings of frontal cortical biopsy

Patient *Tap / Infusion / ICP / Shunt response	Gender APOE	Age at biopsy (years)	MMSE at biopsy	Parenchymal amyloid- $\beta$ (4G8)	Thioflavin- S positive plaques	HP $\tau$ (AT8)	Age at PET (years)	MMSE at PET
1 1008/790 -/-/+ / +	M 2/3	80	25	+	4	+	85	18
2 1017/850 +/0/0/+	F $\frac{3}{4}$	77	28	+	6	+	80	28
3 1027/940 +/0/0/-	M 3/3	73	14	none	none	+	73	14**
4 1003/852 +/0/0/+	M 3/3	72	24	+	none	none	75	24
5 1004/877 -/+ / 0/+	M 3/3	78	28	+	none	none	82	27
6 2005/886 +/0/0/+	M 3/3	65	26	none	none	none	68	27
7 1009/826 -/-/+ / +	F $\frac{3}{4}$	73	28	+	3	none	77	26
8 2007/889 (+)/- / 0/+	F 3/3	73	21	none	none	none	75	23
9 1019/842 +/0/0/+	F $\frac{3}{4}$	71	23	+	8	none	75	21
10 1026/921 -/+ / 0/+	M $\frac{3}{4}$	72	28	+	3 + CAA	none	73	28
11 2013/764 -/0/0/+	M 3/3	72	25	none	NA	none	78	15
12 2011/920 -/+ / 0/+	F 3/3	71	26	none	none	none	72	28
13 1018/887 +/0/0/+	F 3/3	75	25	+	3	none	78	23
14 1006/859 -/+ / 0/+	F $\frac{3}{4}$	62	24	+	none	none	65	24

\*-=negative, 0=not done, +=positive

\*\*No follow-up MMSE evaluations

Abbreviations: NA, not available; MMSE, Mini-Mental State Examination; HP $\tau$ , hyperphosphorylated tau; PET, Positron emission tomography; CAA, cerebral amyloid angiopathy

## Figure legends

### Figure 1.

Representative axial [ $^{11}\text{C}$ ]PIB and S-[ $^{18}\text{F}$ ]THK-5117 PET images (reference-Logan derived parametric images) from all the patients. Biopsy status indicates amyloid  $\beta$  ( $\text{A}\beta$ , 4G8) and hyperphosphorylated tau ( $\text{HP}\tau$ , AT8) according to immunohistochemistry of right frontal cortical brain biopsy (0 - no  $\text{A}\beta$  and no  $\text{HP}\tau$ ; 1 -  $\text{A}\beta$  but no  $\text{HP}\tau$ ; 2 -  $\text{A}\beta$  and  $\text{HP}\tau$ ; 3 –  $\text{HP}\tau$  but no  $\text{A}\beta$ ). Patients #3 was not able to undergo full 90-min [ $^{11}\text{C}$ ]PIB imaging (negative until 80-min). Patient numbering corresponds that of Table 1.

### Figure 2.

Pearson correlations between [ $^{11}\text{C}$ ]PIB uptake in PET and CSF  $\text{A}\beta_{1-42}$  (A) and p-tau $_{181}$  (B) and S-[ $^{18}\text{F}$ ]THK-5117 uptake in PET and CSF p-tau $_{181}$  (C-D).

Figure 1

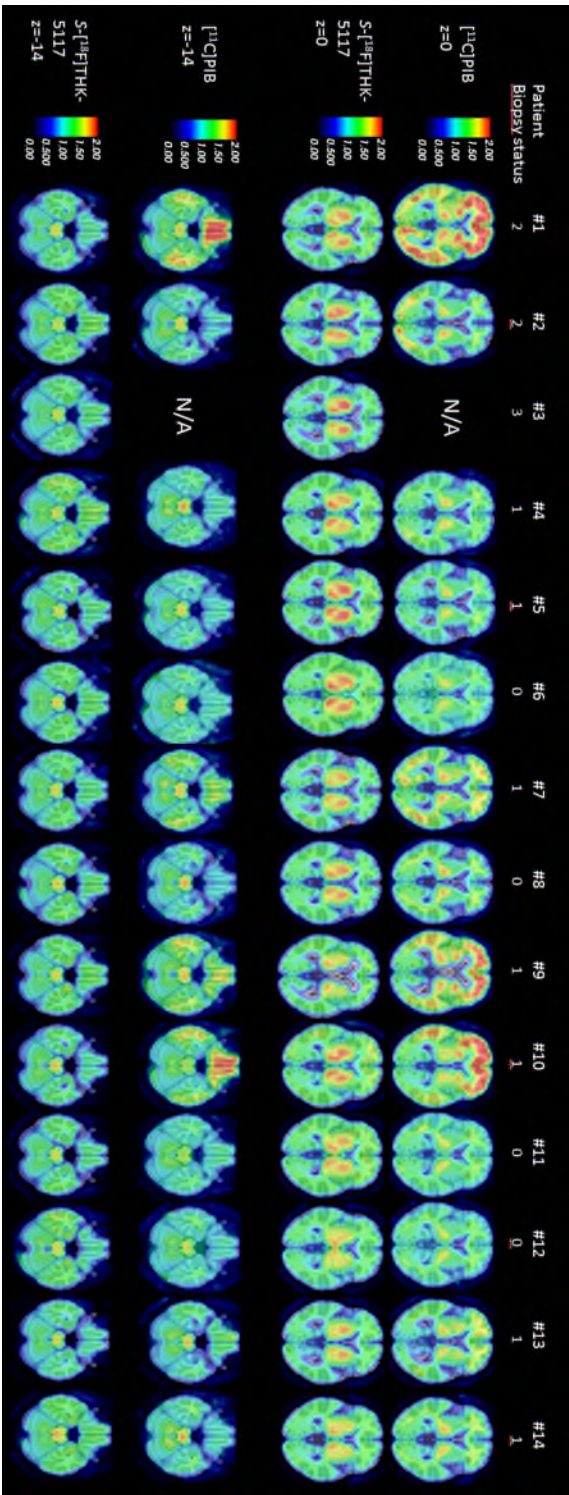


Figure 2

