

## TITLE PAGE

### Full title of paper:

Intracranial neoplasms in the first year of life: results of a third cohort of patients from a single institution

### Authors:

Sebastian M Toescu	MBChB (Hons), BSc (Hons), MRCS
Gregory James	BSc (Hons) MB BS PhD FRCS (Eng) FRCS (Neuro. Surg.)
Kim Phipps	RGN, RSCN, BSc (Hons)
Owase Jeelani	BMedSci, MBA, MPhil (Medical Law), FRCS (NeuroSurg)
Dominic Thompson	MBBS, BSc, FRCS (SN)
Richard Hayward	FRCS
Kristian Aquilina	FRCS(SN) MD

### Affiliation:

Department of Neurosurgery, Great Ormond Street Hospital for Children, London, WC1N 3JH

### Corresponding author:

Sebastian M Toescu, Department of Neurosurgery, Great Ormond Street Hospital for Children, London, WC1N 3JH, [s.m.toescu@gmail.com](mailto:s.m.toescu@gmail.com)

Work previously presented in abstract form at International Symposium of Paediatric Neuro-Oncology, Liverpool, June 2016 (poster); European Society of Paediatric Neurosurgery, Paris, May 2016 (oral); International Society for Paediatric Neurosurgery, Izmir, Turkey, October 2015 (oral).

The authors have no financial support or industry affiliations to disclose.

### Acknowledgements

The authors thank Dr Aidan O’Keeffe, of the Department of Statistical Science, University College London, for his assistance with statistical analysis.

## **ABSTRACT**

*Background:* Brain tumors in the first year of life are rare and their management remains challenging.

*Objective:* To report on the contemporary management of brain tumors in infants with reference to previous series from our institution.

*Methods:* Retrospective cohort study design. Electronic/paper case note review of all brain tumors diagnosed at our institution in children aged <1y since the publication of our previous series.

*Results:* 98 patients were seen. The most common presentations were with vomiting and macrocrania, at a median age of 184 days. 62% of tumors were supratentorial. 91 patients underwent 230 procedures; 7 patients had no surgery. 118 operations were directly on brain tumors (biopsy 37, subtotal resection 47, gross total resection 34). 91 CSF diversions, 9 endoscopic procedures, and 13 pre-operative embolizations were performed. Operative mortality was 4.4%. Tumor types in order of frequency were choroid plexus papillomas(CPP;17), primitive neuroectodermal tumor(PNET;12), atypical teratoid/rhabdoid tumor(ATRT;10), high grade glioma (HGG;9), optic glioma(9), ependymoma(8), low grade glioma(LGG;6), pilocytic astrocytoma(6), choroid plexus carcinoma(5) and teratoma(5), with 11 miscellaneous tumors. Survival was 93% at 1m(91/98), 64% at 1y(61/95), 44% at 5y(32/73), 28% at 10y(16/58). No patients with CPP or LGG died. Five-year survival rates were lowest for anaplastic ependymoma, PNET and ATRT. 77% of children reaching school age were in mainstream schooling.

*Conclusion:* Overall survival from neonatal brain tumors remains similar to previous series; analysis of tumor subtypes reveals improvements for CPP and gliomas. Despite increasing operative intervention, operative mortality continues to decline for this group of challenging patients.

### **Running title:**

Neonatal brain tumors

### **Keywords:**

Infant; brain tumor; survival; choroid plexus papilloma; PNET; ATRT; glioma

## **Introduction**

Intracranial tumors are the most common solid neoplasm of childhood. They are, however, rare in infants, where they account for only 0.5-1.9% of all pediatric central nervous system (CNS) tumors<sup>1</sup>. The management of this patient group is complex, due to a combination of histological heterogeneity, surgical and anesthetic challenges, and the deleterious effects of adjuvant chemotherapy and radiotherapy to the developing brain. Many series have previously reported poor survival, with 5-year survival rates between 21 and 81%<sup>2-9</sup>. Due to their rarity, much of the literature about infant brain tumors consists of limited surgical series, individual case reports and reviews. Here, we report the results of a third iteration of a consecutive series from a single institution, extending back over more than sixty years, and comprising the largest continuous case group in the literature<sup>3,10</sup>; the principal features of each study are summarized in Table 1. Our objective is to characterize the contemporary management of brain tumors in infants (aged under 1 year) presenting to a single institution between 1997 and 2014 inclusive.

## **Methods**

Eligible participants were all children below one year of age diagnosed with brain tumors at our center, since the time of publication of this institution's second cohort<sup>3</sup> (i.e. from April 1997 to January 2014). Prospectively maintained databases were retrospectively interrogated to yield data on demographics, presentation, radiology, surgical techniques, adjuvant therapies, pathology, and survival. Patients were routinely followed up in neuro-oncology multidisciplinary team meetings and clinics. Our institution does not require additional patient consent or ethical approval for retrospective audits of this nature. A small proportion of patients from early in the cohort were lost to follow up due to emigration, but no missing data was encountered otherwise. Histopathological samples were analyzed by a team of specialist pediatric neuropathologists. Descriptive statistical analysis, Kaplan-Meier survival curves, and Breslow and Log Rank tests applied to these were performed with IBM SPSS Statistics (IBM, Armonk, New York). A prospectively determined *p* value of 0.05 was used to indicate a significant difference.

## **Results**

### *Demography and clinical presentation*

98 patients presented during the study period; 55 were male. An average of 5.4 cases were referred per year, compared to 3.4 per year in our first series. The age at presentation ranged from day 1 of life to 354 days, with a median of 184 days. A mean of 8.2 patients presented in each month of age (range 3-14). The mean duration of symptoms prior to presentation was 49 days. The most common presenting symptom was vomiting, followed by increased head circumference. The most common clinical signs on presentation were related to increased head circumference and hydrocephalus (see Figure 1).

### *Imaging*

Multiple imaging modalities were used to investigate this group of patients. 94 patients (96%) had a magnetic resonance (MR) scan, 56 patients (57%) had a computed tomography (CT) scan, and 10 patients (10%) underwent cranial ultrasound (US). 52 patients (53%) had both MRI and CT. None of the patients had pre-operative diagnostic digital subtraction angiography or skull radiography. In one patient the lesion was diagnosed in the antenatal period by US.

### *Neurosurgical procedures*

91 patients underwent a total of 230 surgical procedures, with 65 patients having more than one procedure (see Figure 2). Seven patients had no surgery: 4 had a radiological diagnosis of a low-grade lesion (3 optic pathway gliomas, 1 low grade glioma); 1 child died pre-operatively; 1 child had surgery elsewhere and another was referred for palliative care for a very large tumor that was deemed inoperable.

Median post-operative stay in hospital on index admission was 19 days (range 1 to 86 days). 85 patients underwent 118 surgical procedures directly on brain tumors. Extent of resection, as judged by the operating surgeon and post-operative imaging, was biopsy in 37, subtotal resection in 47, and gross total resection in 34 operations. Safe maximal resection was attempted in all cases. A total of 89 cerebrospinal fluid (CSF) diversion procedures were performed (57 ventriculoperitoneal shunt (VPS) procedures and 32 external ventricular drains (EVDs)) on 54 patients. 2 ventricular access devices were implanted.

Endoscopic procedures were performed on 9 patients during the study period. Of these, 7 patients underwent endoscopic third ventriculostomy (ETV) for obstructive hydrocephalus. Following the publication of a validated ETV success scoring system in 2009, these criteria were incorporated in the decision-making process<sup>11</sup>. 3 patients underwent septostomy; and 5 underwent endoscopic biopsy (none of the patients undergoing endoscopic biopsy had a separate biopsy procedure). These endoscopic procedures were performed in combination or alone, and in all but one patient included an ETV or septostomy/fenestration. 3 of 8 children who had primary endoscopic management of hydrocephalus later underwent VPS procedures.

Five patients underwent operative management but did not have a procedure on the tumor: 3 underwent primary VPS procedures, 1 had an EVD later converted to a VPS, and 1 had a successful ETV performed. Only one of these children went on to have chemotherapy. Twelve patients, all with choroid plexus tumors, underwent 13 pre-operative tumor embolization procedures (see Figure 3 for an illustrative case).

There were 4 peri-operative deaths (with 3 of these occurring in the first 7 years of the series), giving an overall operative mortality of 4.4%, a reduction compared to our previous cohorts' figures of 7.6%<sup>3</sup> and 30%<sup>10</sup>. All of these occurred within 30 days of surgery, but only in two cases was this due to unexpected complications of surgical procedures on the tumor (1 due to blood loss during tumor surgery, 1 contralateral intracerebral haemorrhage following biopsy). The remaining two post-operative deaths occurred in controlled circumstances in a palliative setting, with treatment limiting decisions made due to poor prognosis.

### *Tumor pathology*

61 tumors were supratentorial, 36 infratentorial; 1 tumor extended into both compartments. In 86 patients, a definitive histological diagnosis was made. In 83 patients this was achieved through the first surgical procedure on the tumor, and in 3 at post-mortem examination. Those without histology were diagnosed on clinical and radiological grounds. The different tumor types seen in this cohort are shown in Figure 4. Histological diagnoses in the 'other' category were cavernous angioma, craniopharyngioma, ganglioglioma, primary neuroepithelial tumor, angiosarcoma, ETANTR (embryonal tumor with abundant neuropil and true rosettes), melanocytic

neuroectodermal tumor of infancy and two unknown entities. Histological diagnoses in the miscellaneous glioma group were desmoplastic infantile astrocytoma and a non-specific glioma.

#### *Adjuvant therapy*

45 patients received adjuvant chemotherapy as part of their management. 1 patient underwent neo-adjuvant chemotherapy prior to any surgical treatment (which was a biopsy of a pilocytic astrocytoma). 11 patients received adjuvant radiotherapy. Four patients were given primary radiotherapy at a mean age of 13.8 months (range 12-15 months); all patients had PNETs. Seven patients underwent radiotherapy at tumor recurrence at a mean age of 42.4 months (range 18-78 months), for a variety of tumors (ATRT, ganglioglioma, ependymoma, 2 anaplastic ependymoma, 2 glioma). No patients received radiotherapy under the age of 1 year.

#### *Survival*

Overall, 42 patients died during the study period, with the worst prognoses conferred by diagnosis of anaplastic ependymoma and PNET (5-year survival rate 0% for both diagnoses). None of the patients with choroid plexus papilloma (17) or histologically proven low-grade glioma (6) died during the study period. Mean overall follow up of survivors was 6.74 years (S.D. 4.60 years). Table 2 shows interval survival rates for all patients in the cohort.

A Kaplan Meier survival curve for all patients treated surgically in the current series is shown in Figure 5, alongside the curve for our previous institutional series. A Breslow (generalised Wilcoxon) test did not show any significant difference between these distributions ( $\chi^2$  statistic 0.072,  $p = .79$ ). The resolution of the data from the first published institutional series<sup>10</sup> was insufficient to generative a similar survival curve; in this study the cumulative average survival was 27 months for the whole group, and 37 months for those infants who underwent surgery<sup>10</sup>. Survival rates stratified by tumor type are shown in Table 3. Kaplan-Meier survival curves generated from these data are shown in Figure 6. A non-parametric Log Rank (Mantel-Cox) test was applied to the differential survival curves, indicating a significant difference in survival between the four most numerous tumors in the cohort ( $\chi^2$  statistic 24.78,  $p < .001$ ).

#### *Functional outcome*

Data on educational status was collected as an indicator of quality of life in those patients surviving to school age. 46 patients survived to school age and follow up data were available for 39 patients (5 patients emigrated, 2 patients lost to follow up). 30 children (77%) were in mainstream schooling, of whom 10 (26%) required educational assistance; the remaining 9 (23%) were in a special school. None of the patients requiring special schooling streams had undergone radiotherapy as part of their treatment protocol. Of the 20 children in unassisted mainstream schooling, 14 were diagnosed with more benign pathologies (CPP/LGG/pilocytic astrocytoma).

### *Multidisciplinary care*

All patients were managed within the pediatric neuro-oncology multidisciplinary group, which includes neurosurgeons, neuroradiologists, neuropathologists, oncologists, allied health professionals and nurse specialists. In addition, 47% of patients benefited from formal consultation from one or more allied medical specialities (ophthalmology (23%), endocrinology (11%), palliative care (6%), neurology (4%), pediatric intensive care services (4%) and audiology (3%)).

### **Discussion**

The surgical management of brain tumors in infants remains challenging, and survival rates for many tumors remain low<sup>4,6,7,12,13</sup>. The results of the third iteration of this single centre cohort presented here show 5-year overall survival rates concordant with those reported in the literature<sup>5</sup>, but with significant variation in survival rates for different tumors<sup>14,15</sup>.

Our series demonstrates a significant heterogeneity to the modes of presentation within this patient group (see Figure 1). However, in keeping with other case series<sup>12,13,16,17</sup>, the most common clinical sign on presentation was macrocrania. Vomiting was the most common symptom at presentation, with a reduction seen in more advanced neurological signs (such as papilloedema, nystagmus and focal neurological deficits) compared to our previous cohorts<sup>3,10</sup>. Improved infant surveillance in the neonatal period may underlie this finding, although the

duration of symptoms remains in the range of seven weeks, similar to previously<sup>3</sup>, due to the often non-specific nature of symptoms in this age group.

Almost all patients (96%) underwent MR imaging. Although our results show a declining trend in its use, CT scanning is still commonly employed in primary hospitals as a first-line diagnostic tool, and 53% of patients had both CT and MR. In only one patient was diagnosis made prenatally. However, the increasing availability of advanced antenatal imaging techniques, particularly foetal MRI, may allow earlier diagnosis, safer parturition, and better surgical planning in the near future.

In contrast to our previous cohort, where 25% of patients underwent diagnostic cerebral angiography<sup>3</sup>, this technique was not employed as a purely diagnostic test in any of the patients in this cohort. The only indication for pre-operative angiography was as an interventional procedure for patients where imaging was consistent with choroid plexus neoplasms. Twelve patients subsequently underwent embolization procedures, which have been shown to reduce perioperative blood loss and increase gross total resection rate<sup>18</sup>.

The operative data from the current series indicate an increasing trend towards operative intervention compared to previous series. 66% of patients managed surgically underwent more than one procedure. This is partly explained by a preference in our unit to consider staged procedures; 23 children in this series underwent more than one tumor operation. This rise in operative intervention was not associated with an increase in surgical mortality; in fact, overall surgical mortality has declined in our current series, due to improvements in both surgical and anaesthetic safe practice. Gross total resection was achieved in 29% of the procedures performed directly on brain tumors, a similar figure to that noted in a recent retrospective report<sup>19</sup>. Our series also underlines the increasing use of endoscopy, undertaken in 9 infants, which has been shown to be safe, with low incidence of adverse events, in this patient population<sup>20</sup>. This allowed effective management of hydrocephalus and tumor biopsy (see Figure 2).

In contrast to intracranial tumors in later childhood, infant brain tumors occur more commonly in the supratentorial space<sup>21</sup>, as shown in 62% of our patients. As molecular profiling of brain



tumors assumes greater relevance, there is an increasing value to obtaining tissue for definitive diagnosis, particularly in cases where no surgical treatment is to be recommended. In the current series, this was achieved in 88% of cases (compared to 78% previously<sup>3</sup>). Large database<sup>15</sup> and literature<sup>22</sup> reviews indicate that gliomas are the most common histological tumor type in this patient group, although smaller, retrospective surgical series have not always been consistent with this<sup>16,23,24</sup>. In this large series, there is a greater number of choroid plexus neoplasms (22% of tumors) compared with other series<sup>3,10,12,22</sup>. Our overall survival rates for these tumors of 95% compare reasonably well to those reported in the wider literature of around 73%<sup>12</sup>.

The incidence of low grade glioma in this cohort (23 of 98 patients) was identical to that noted in a previous literature review<sup>22</sup>. The three-year observed survival of infants with low grade gliomas in a large review of the Surveillance, Epidemiology and End Results (SEER) database<sup>15</sup> was 85.6%, a figure which tallies with our 1-year and 5-year survival rates of 95% and 79% respectively. High-grade gliomas had a 3-year survival of 52.1%<sup>15</sup>, also similar to the 50% 1- and 5-year survival observed in our patients; this was an improvement upon our previous series result of 44%<sup>3</sup>. See Figure 7 for an illustrative case of this pathology. Other reports<sup>25</sup> also indicate similar survival rates of high grade glioma in infants, which are better than those of older children and adults. These pathology-specific conclusions are however inherently limited in their robustness by the relatively small sample size compared to larger database studies.

Compared with the previous series, we describe marginally fewer diagnoses of PNET (12% compared with 17%<sup>3</sup>), with a corresponding increase in the diagnosis of ATRT, a clinical entity only described within the last thirty years<sup>26</sup>, which shares histopathological characteristics with PNET and was previously misclassified as such. See Figure 8 for an illustrative case of this pathology. Both tumors have a poor prognosis in infants. At 1 year, survival of ATRTs and PNETs was 11% and 33% respectively, corroborating evidence from the SEER database<sup>15</sup> that these tumors are amongst the most aggressive and difficult to manage in this age group.

Comparison of Kaplan-Meier survival curves of surgically treated patients in the current series with those of our previous series<sup>3</sup> (Figure 4) appears to show marginally worse survival of patients at early time points, but superior overall survival at later time points. We note, however,

that the Breslow test statistic showed no significant difference between the two distributions. This apparent difference may be partly explained by the high number of successfully treated choroid plexus papillomas seen in the present series, as well as improved anaesthetic, surgical and oncological techniques in the current cohort.

As with any retrospective cohort, limitations in the validity of the data exist due to the nature of data collection, although this was mitigated by interrogating a well-maintained prospective database of all brain tumor patients at our institution. Misclassification bias at chart review was limited by adherence to a rigorous pre-designed abstraction format. Selection bias was eliminated by including all patients under age one with a newly diagnosed brain tumor, which included patients from a wide referral network with an ethnically diverse population, making the results externally generalizable. Indeed, most brain tumors in infants are managed in highly specialised paediatric neurosurgical units accepting national and international referrals.

In recent years, concerns regarding the long-term outcomes of children with intracranial tumors in the first year of life have been addressed, with an increasing emphasis on quality of life in survivors. There are a wide range of medical, psychosocial and economic<sup>27</sup> sequelae of brain tumor treatment in infancy, as well as a cumulative mortality at 30 years of 25%<sup>28</sup>. The quality of life outcomes measured in this cohort of patients, in the form of educational ability and stream, are similar to that of our previous cohort, although too unrefined to characterise nuances of cognitive outcome. No patients requiring assisted or special schooling streams later in life had undergone radiotherapy as part of their treatment protocol in infancy, so the results from this limited series unfortunately cannot address the question of the functional consequences of focal radiation therapy in infants. In addition, the presence of other disabilities such as epilepsy, shown to have a prevalence of up to 25% in a historical International Society of Pediatric Neurosurgery survey<sup>21</sup>, have not been recorded here. Long-term data on functional outcome from neurosurgery for brain tumors in the first year of life are beginning to emerge<sup>29</sup>, however, with favourable results; future studies should aim to incorporate neurocognitive and developmental outcomes into their reporting.

With the broadening of the multidisciplinary team remit in recent years has come the practise of shared care between neuro-oncology and neurosurgical teams. Other specialists may advocate active treatment of cases that to the neurosurgical eye may appear futile, and only likely to prolong the family's suffering. Where the clinical course for these patients is complicated by serious sequelae, and overall prospects of survival are poor, it is not unreasonable to ask whether some of these children should be treated at all. This is a difficult issue requiring sensitive communication with families and carers.

## **Conclusion**

Despite advances in surgery and adjuvant therapy, overall survival from neonatal brain tumors remains poor and not significantly improved over the last thirty years. However, analysis of individual tumor types reveals improvements particularly with respect to choroid plexus tumors and gliomas, notwithstanding the inherent limitations of this single-center series. Despite increasing operative intervention, surgical mortality continues to decline. Endoscopic and interventional radiology procedures have made a significant contribution to the management of this group of patients. Future studies addressing long-term quality of life and neurocognitive outcomes are awaited.

## **References**

1. Orbach D, Sarnacki S, Brisse HJ, et al. Neonatal cancer. *Lancet Oncol.* 2013;14(13):e609-20.
2. Jaing TH, Wu CT, Chen SH, et al. Intracranial tumors in infants: a single institution experience of 22 patients. *Childs Nerv Syst.* 2011;27(3):415-419.
3. Kane PJ, Phipps KP, Harkness WF, Hayward RD. Intracranial neoplasms in the first year of life: results of a second cohort of patients from a single institution. *Br J Neurosurg.* 1999;13(3):294-298.
4. Oi S, Matsumoto S, Choi JU, et al. Brain tumors diagnosed in the first year of life in five Far-Eastern countries. Statistical analysis of 307 cases. *Childs Nerv Syst.* 1990;6(2):79-85.
5. Lang S-S, Beslow L a, Gabel B, et al. Surgical treatment of brain tumors in infants

- younger than six months of age and review of the literature. *World Neurosurg.* 2012;78(1-2):137-144.
6. Larouche V, Huang A, Bartels U, Bouffet E. Tumors of the central nervous system in the first year of life. *Pediatr Blood Cancer.* 2007;49(7 Suppl):1074-1082.
  7. Rivera-Luna R, Medina-Sanson A, Leal-Leal C, et al. Brain tumors in children under 1 year of age: emphasis on the relationship of prognostic factors. *Childs Nerv Syst.* 2003;19(5-6):311-314.
  8. Young HK, Johnston H. Intracranial tumors in infants. *J Child Neurol.* 2004;19(6):424-430.
  9. Serowka K, Chiu Y, Gonzalez I, et al. Central nervous system (CNS) tumors in the first six months of life: the Children's Hospital Los Angeles experience, 1979-2005. *Pediatr Hematol Oncol.* 2010;27(2):90-102.
  10. Jooma R, Hayward RD, Grant DN. Intracranial neoplasms during the first year of life: analysis of one hundred consecutive cases. *Neurosurgery.* 1984;14(1):31-41.
  11. Kulkarni A V, Drake JM, Mallucci CL, et al. Endoscopic third ventriculostomy in the treatment of childhood hydrocephalus. *J Pediatr.* 2009;155(2):254-9.e1.
  12. Isaacs H. II. Perinatal brain tumors: a review of 250 cases. *Pediatr Neurol.* 2002;27(5):333-342.
  13. Isaacs H. I. Perinatal brain tumors: a review of 250 cases. *Pediatr Neurol.* 2002;27(4):249-261.
  14. Qaddoumi I, Sultan I, Gajjar A. Outcome and prognostic features in pediatric gliomas: a review of 6212 cases from the Surveillance, Epidemiology, and End Results database. *Cancer.* 2009;115(24):5761-5770.
  15. Bishop AJ, McDonald MW, Chang AL, et al. Infant brain tumors: incidence, survival, and the role of radiation based on Surveillance, Epidemiology, and End Results (SEER) Data. *Int J Radiat Oncol Biol Phys.* 2012;82(1):341-347.
  16. Mehrotra N, Shamji MF, Vassilyadi M, Ventureyra ECG. Intracranial tumors in first year of life: the CHEO experience. *Childs Nerv Syst.* 2009;25(12):1563-1569.
  17. Jaing T-H, Wu C-T, Chen S-H, et al. Intracranial tumors in infants: a single institution experience of 22 patients. *Childs Nerv Syst.* 2011;27(3):415-419.
  18. Haliasos N, Brew S, Robertson F, Hayward R, Thompson D, Chakraborty A. Preoperative

- embolisation of choroid plexus tumours in children: part I-does the reduction of perioperative blood loss affect the safety of subsequent surgery? *Childs Nerv Syst.* 2013;29(1):65-70.
19. Shamji MF, Vassilyadi M, Lam CH, Montes JL, Farmer J-P. Congenital tumors of the central nervous system: the MCH experience. *Pediatr Neurosurg.* 2009;45(5):368-374.
  20. Bowes AL, King-Robson J, Dawes WJ, James G, Aquilina K. Neuroendoscopic surgery in children: does age at intervention influence safety and efficacy? A single-center experience. *J Neurosurg Pediatr.* July 2017:1-5.
  21. Di Rocco C, Iannelli A, Ceddia A. Intracranial tumors of the first year of life. A cooperative survey of the 1986-1987 Education Committee of the ISPN. *Childs Nerv Syst.* 1991;7(3):150-153.
  22. Larouche V, Huang A, Bartels U, Bouffet E. Tumors of the central nervous system in the first year of life. *Pediatr Blood Cancer.* 2007;49(7 Suppl):1074-1082.
  23. Rivera-Luna R, Medina-Sanson A, Leal-Leal C, et al. Brain tumors in children under 1 year of age: emphasis on the relationship of prognostic factors. *Childs Nerv Syst.* 2003;19:311-314.
  24. Jurkiewicz E, Brozyna A, Grajkowska W, et al. Congenital brain tumors in a series of 56 patients. *Child's Nerv Syst.* 2012;28:1193-1201.
  25. Duffner PK, Krischer JP, Burger PC, et al. Treatment of infants with malignant gliomas: the Pediatric Oncology Group experience. *J Neurooncol.* 1996;28(2-3):245-256.
  26. Rorke LB, Packer RJ, Biegel JA. Central nervous system atypical teratoid/rhabdoid tumors of infancy and childhood: definition of an entity. *J Neurosurg.* 1996;85(1):56-65.
  27. Turner CD, Rey-Casserly C, Liptak CC, Chordas C. Late effects of therapy for pediatric brain tumor survivors. *J Child Neurol.* 2009;24(11):1455-1463.
  28. Armstrong GT, Liu Q, Yasui Y, et al. Long-term outcomes among adult survivors of childhood central nervous system malignancies in the Childhood Cancer Survivor Study. *J Natl Cancer Inst.* 2009;101(13):946-958.
  29. Lundar T, Due-Tønnessen BJ, Egge A, et al. Neurosurgical treatment of brain tumors in the first 6 months of life: long-term follow-up of a single consecutive institutional series of 30 patients. *Childs Nerv Syst.* 2015;31(12):2283-2290.
  30. Friedrich C, von Bueren AO, von Hoff K, et al. Treatment of young children with CNS-

primitive neuroectodermal tumors/pineoblastomas in the prospective multicenter trial HIT 2000 using different chemotherapy regimens and radiotherapy. *Neuro Oncol.* 2013;15(2):224-234.

31. Bartelheim K, Nemes K, Seeringer A, et al. Improved 6-year overall survival in AT/RT - results of the registry study Rhabdoid 2007. *Cancer Med.* 2016;5(8):1765-1775.

## Figures

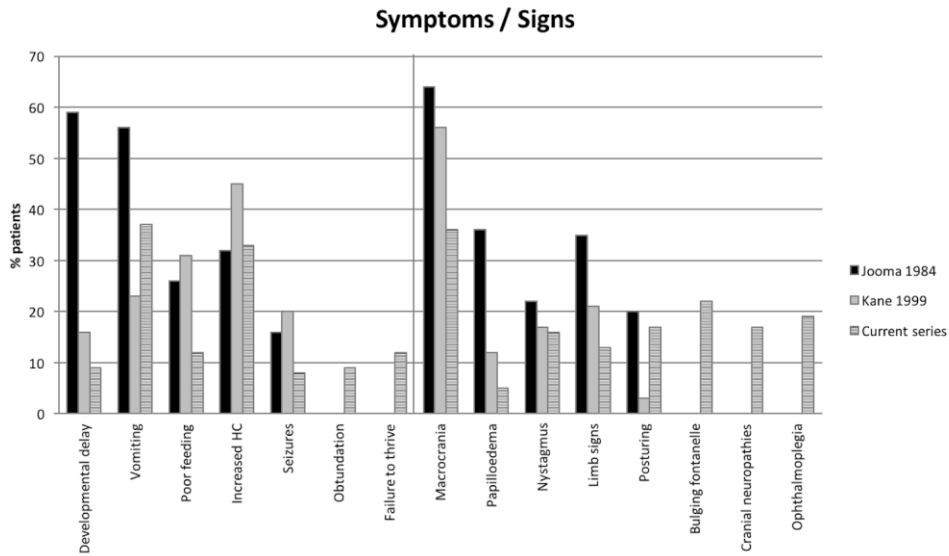


Figure 1. Bar chart showing incidence of clinical symptoms and signs on presentation (in %) in the current series along with comparative figures from previous institutional cohorts.

	<i>Jooma et al</i> <sup>10</sup>	<i>Kane et al</i> <sup>3</sup>	<i>Current series</i>
Recruitment period	1953 – 1981	1982 – 1996	1997 – 2014
Size of cohort	100	75	98
Mean duration of symptoms (weeks)	up to 14	6.5	7
CT scan (%)	14	88	57
MRI scan (%)	0	47	96
Patients undergoing tumour surgery (%)	68	88	87
Gross total resection (%)	28	33	29
Subtotal resection or biopsy (%)	72	44	71
Operative mortality (%)	33	7.6	4.4
Radiotherapy (as part of initial treatment) (%)	39	17	4
Chemotherapy (as part of initial treatment) (%)	0	34	45

Table 1. Comparison table between three institutional series of neonatal brain tumors.

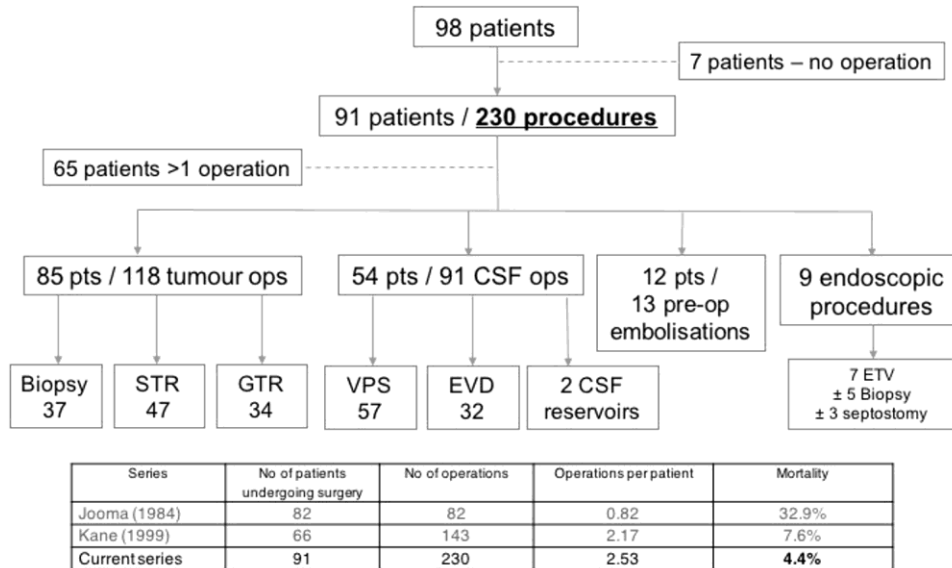


Figure 2. Flowchart showing nature of neurosurgical operations performed on the patient cohort. The table shows operative data across the three institutional series. STR, subtotal resection; GTR, gross total resection; VPS, ventriculoperitoneal shunt; EVD, external ventricular drain; CSF, cerebrospinal fluid; ETV, endoscopic third ventriculostomy; pts, patients; ops, operations.



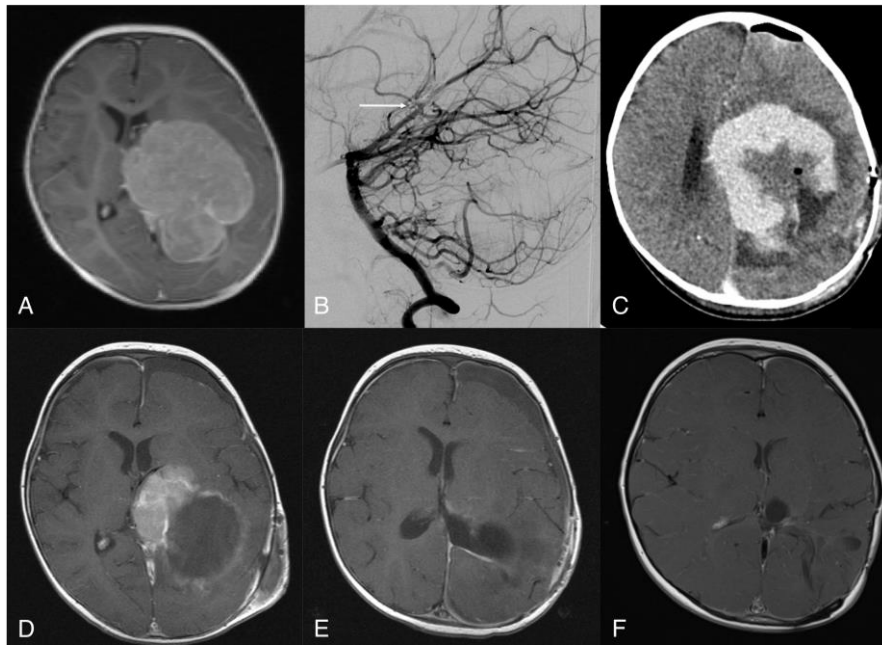


Figure 3. Eleven month-old girl with a large left hemispheric choroid plexus carcinoma. The patient underwent pre-operative embolization followed by staged resection, involving three craniotomies over four weeks. Despite tumor embolization, intra-operative blood loss remained a significant problem, and limited the first and second procedures. Following surgical recovery she underwent 6 courses of Cyclophosphamide, Etoposide and Vincristine chemotherapy over 6 months. A, pre-operative MR scan showing large enhancing left hemispheric lesion. B, pre-operative digital subtraction angiogram, lateral view of left vertebral artery contrast injection showing glue embolization of tumor-supplying left posterior choroidal artery (black arrow). C, contrast-enhanced axial CT scan after first craniotomy and resection. D, MR scan after second craniotomy showing significant reduction in tumor volume. E, MR scan after third craniotomy with gross total resection of tumor; this was followed by chemotherapy. F, 2-year follow up MR scan showing no tumor recurrence. All scans are axial T1-weighted post-Gadolinium MRI.

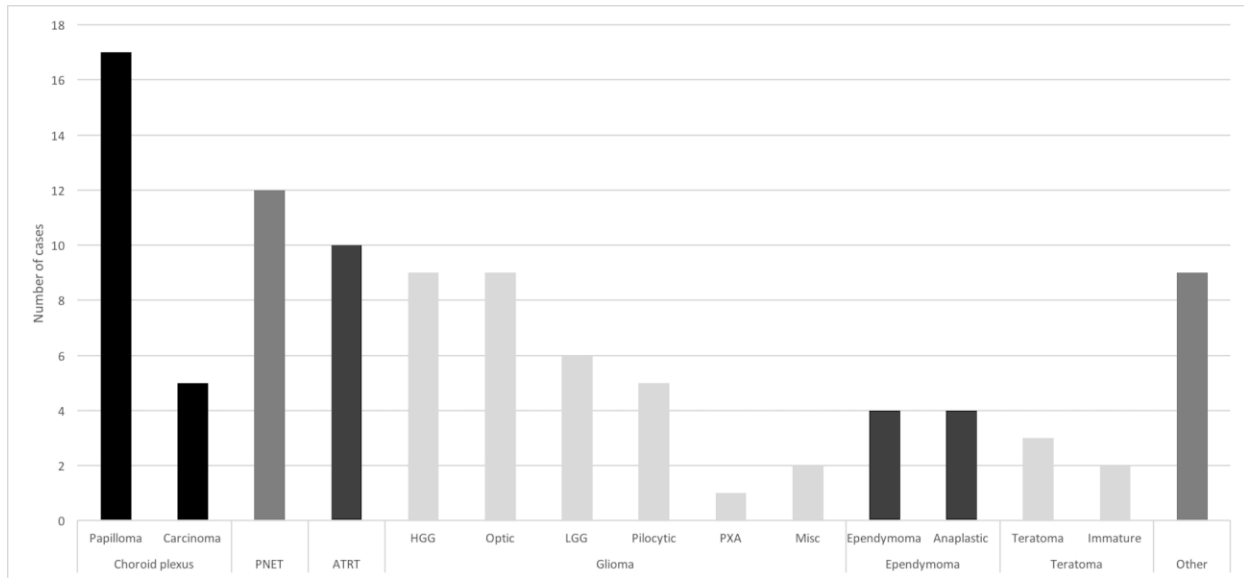


Figure 4. Incidence of tumor types seen in patient cohort. PNET, primitive neuroectodermal tumor (of which 4 were supratentorial); ATRT, atypical rhabdoid/teratoid tumor; HGG, high grade glioma; LGG, low grade gliomas; PXA, pleomorphic xanthoastrocytoma; Misc, miscellaneous.

<b>Survival at</b>	
1 month	93% (91/98)
6 months	71% (67/95)
1 year	64% (61/95)
3 years	55% (47/86)
5 years	44% (32/73)
10 years	28% (16/58)

Table 2. Interval survival rates for all tumor types in cohort.

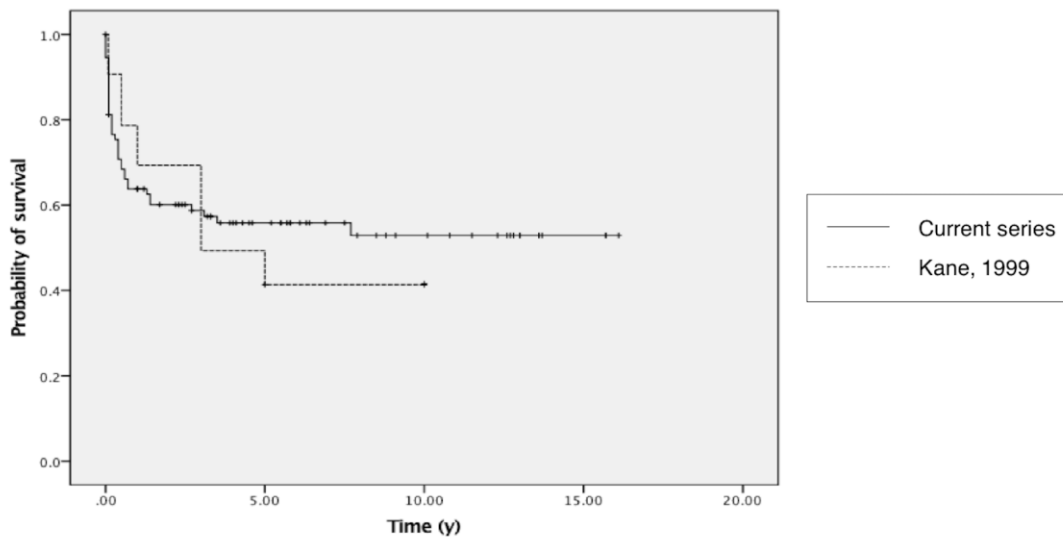


Figure 5. Kaplan-Meier survival curves for all patients treated surgically in the current series (solid line), and for our previous institutional series (dashed line). Breslow (generalised Wilcoxon)  $\chi^2$  statistic 0.072,  $p = .79$ .

<b>Tumour type</b>	<b>1 month</b>	<b>1 year</b>	<b>5 year</b>	<b>10 year</b>
CPP	17/17 (100%)	17/17 (100%)	17/17 (100%)	17/17 (100%)
LGG	22/22 (100%)	21/22 (95%)	11/14 (79%)	7/10 (70%)
CPC	5/5 (100%)	3/4 (75%)	2/3 (67%)	2/3 (67%)
HGG	7/9 (78%)	4/8 (50%)	4/8 (50%)	1/5 (20%)
PNET	11/12 (92%)	4/12 (33%)	0/10 (0%)	0/8 (0%)
Teratomas	5/5 (100%)	2/5 (40%)	0/3 (0%)	0/3 (0%)
ATRT	7/10 (70%)	1/9 (11%)	1/9 (11%)	0/7 (0%)
Ependymomas	6/8 (75%)	4/8 (50%)	1/8 (12.5%)	1/8 (12.5%)

Table 3. Survival rates at 1 month, 1, 5 and 10 years for specific tumor types. LGG group includes optic gliomas, PXAs, pilocytic astrocytomas, true low grade gliomas and 2 miscellaneous non-malignant gliomas. CPP, choroid plexus papilloma; LGG, low grade gliomas; CPC, choroid plexus papilloma; HGG, high grade glioma; PNET, primitive neuroectodermal tumor; ATRT, atypical teratoid / rhabdoid tumor.

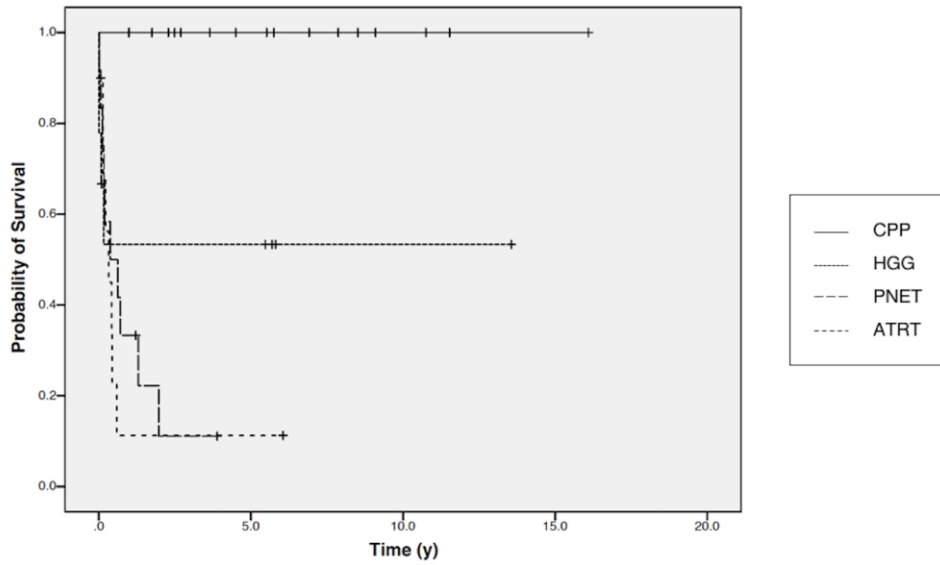


Figure 6. Kaplan-Meier curve showing differential survival of 4 most numerous tumors seen in the current cohort;  $\chi^2$  statistic 24.78,  $p < .001$ . CPP, choroid plexus papilloma; HGG, high grade glioma; PNET, primitive neuroectodermal tumor; ATRT, atypical teratoid / rhabdoid tumor.

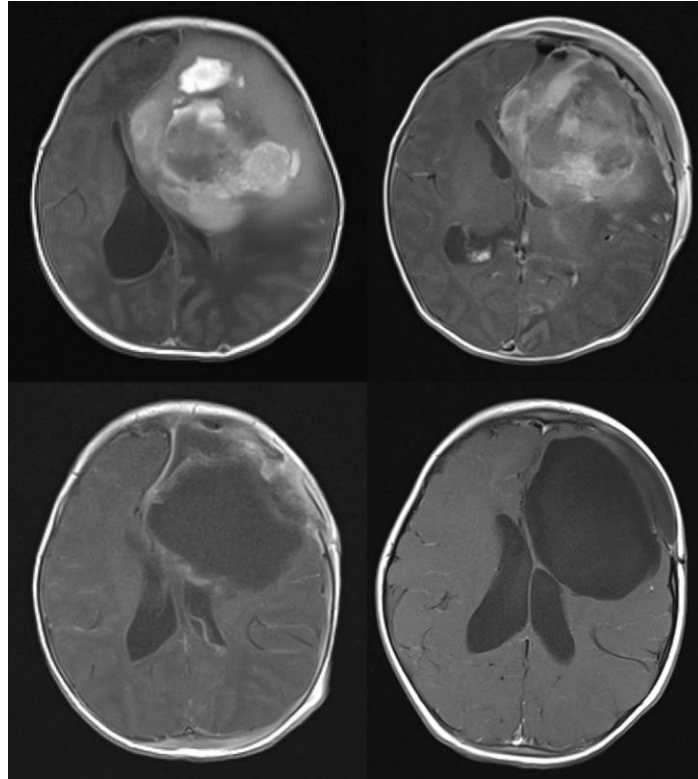


Figure 7. Infant girl with large left frontal high grade glioma diagnosed on day 1 of life. The patient was initially managed surgically with an open biopsy followed by gross total resection. She then underwent 2 cycles of chemotherapy on a modified HIT-SKK protocol<sup>30</sup> involving cyclophosphamide, vincristine, carboplatin, etoposide and methotrexate. A, pre-operative axial T2-weighted MRI. B, post-biopsy scan with some relief of mass effect. C, post-resection scan, consistent with gross total resection. D, 2 year follow up scan showing no tumor recurrence. All scans axial T1-weighted post-Gadolinium MRI.

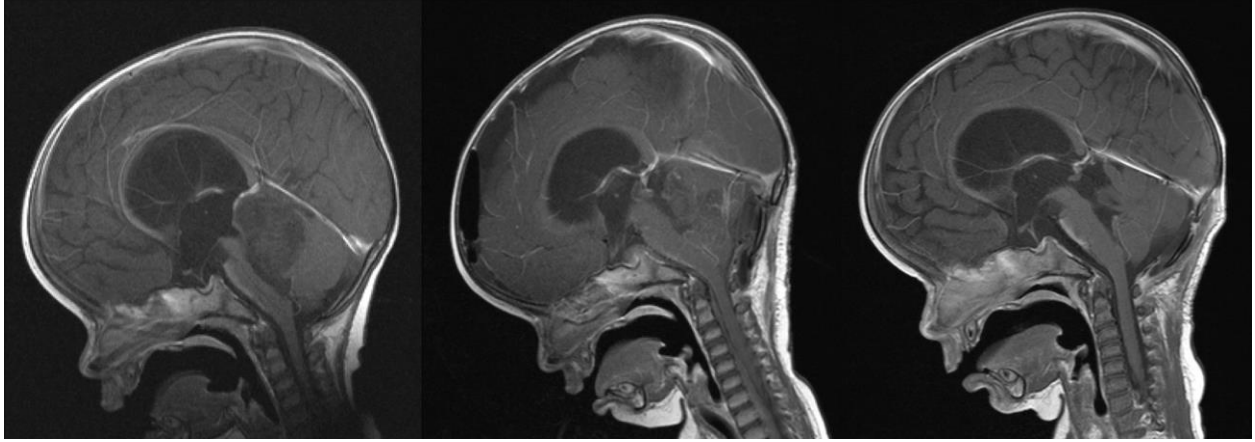

Figure 8. Ten month old girl with infratentorial heterogeneous non-enhancing atypical teratoid/rhabdoid tumor. Following gross total resection, she underwent chemotherapy according to a published protocol<sup>31</sup> involving Vincristine, Cyclophosphamide, Actinomycin, with subsequent high dose Carboplatin and Thiotepa and peripheral stem cell rescue. A, pre-operative scan. B, post-operative scan demonstrating gross total resection. C, surveillance scan at three years. All scans sagittal T1-weighted post-Gadolinium MRI.