

FOCUS ON MOLECULAR IMAGING

ADDITIONAL CLINICAL VALUE FOR PET/MRI IN ONCOLOGY:

MOVING BEYOND SIMPLE DIAGNOSIS

Kenneth A. Miles^{1,2}

Stefan A. Voo¹

Ashley M. Groves¹

1. Institute of Nuclear Medicine

University College London

London, UK

2. Department of Diagnostic Imaging

Princess Alexandra Hospital

Brisbane, Australia

Corresponding Author: Kenneth A. Miles

Department of Radiology

Princess Alexandra Hospital

199 Ipswich Road

Woolloongabba

Queensland 4102

Australia

Tel: + 61 7 3176 1820

Fax: + 61 7 3176 1828

E mail: kenneth.miles@ucl.ac.uk

Word count: 3876

Running Title: PET/MRI: BEYOND SIMPLE DIAGNOSIS

ABSTRACT

Initial clinical research comparing the diagnostic performance of Positron Emission Tomography (PET)/ Magnetic Resonance Imaging (MRI) and PET/ Computed Tomography (PET/CT) has largely shown equivalent diagnostic capabilities for these modalities in oncology. These uncertainties about the magnitude of diagnostic benefit are compounded by the considerable health economic challenges associated with clinical implementation. Therefore, there is a need to identify ways to extend the use of this technology beyond simple diagnosis so that PET/MRI can add sufficient clinical value beyond PET/CT or MRI alone, and become a cost-effective imaging modality in clinical practice. A major advantage of PET/MRI over other imaging modalities is the ability to generate multiple quantitative images from a single examination. This article describes how a multi-parametric PET/MRI approach can not only add clinical value through contributing to precision medicine but also establish PET/MRI as a potentially cost-effective imaging modality in oncology.

INTRODUCTION

Since the introduction of clinical PET/MRI in 2010, much of the research into this modality has focused on diagnostic performance. However, comparative studies to date have largely shown equivalent diagnostic capabilities for these modalities (1,2). Where benefits for PET/MRI have been demonstrated, they are typically small or apply to relatively small populations of patients. Furthermore, the extent to which these benefits might be equally achievable through sequentially performed PET/CT and dedicated MRI examinations is often unclear. There is therefore a need to identify PET/MRI applications that provide additional value beyond modest improvements in diagnostic performance.

The translation of stand-alone PET from a research technique to a routine clinical modality was predicated on demonstrating cost-effectiveness and similar requirements can be anticipated for hybrid PET/MRI. There are considerable health economic challenges that need to be overcome before PET/MRI can be widely adopted into clinical practice. Currently, the cost of a PET/MRI machine is comparable to separate purchases of PET/CT and dedicated MRI systems. Substantial incremental health benefits over PET/CT, and/or significant reductions in equipment costs, will therefore be required for PET/MRI to achieve cost-effectiveness. The economic challenges are further magnified if acquisition times for either modality during PET/MRI extend beyond the time required to obtain images of diagnostic quality for one of the modalities alone. It is highly unlikely that these economic burdens will be offset by any health benefits achieved through the modest improvements in diagnostic performance shown to date, and extending the use of the technology beyond simple diagnosis will be required if PET/MRI is to become a cost-effective imaging modality.

A major advantage of PET/MRI over other imaging modalities is the ability to generate multiple quantitative images from a single examination. In this article, we review how this multi-parametric PET/MRI approach can not only add clinical value through contributing to precision medicine but also establish PET/MRI as a potentially cost-effective imaging modality in oncology.

FUNCTIONAL & MOLECULAR IMAGING IN THE ERA OF PRECISION CANCER MEDICINE

Precision medicine aims to identify sub-groups of patients with similar disease characteristics so that the safest, most effective and/or cost-effective treatment can be selected for individual patients. Expanding the role of imaging to include acquisition of data

that allows these sub-groups to be identified as part of routine diagnosis constitutes a major opportunity for radiology to contribute significantly to this new era (3). Both PET and MRI offer specific advantages for engaging with this opportunity and the potential benefits of combining PET and MRI assessments for precision medicine have been highlighted by image-based prognostic nomograms proposed for patients with cervical cancer (4).

Simultaneous image acquisition using PET/MRI can enhance this potential by reducing total imaging time and avoiding complex image co-registration techniques.

A major focus for precision medicine in oncology is the identification of patients most likely to respond to drugs that target specific molecular mechanisms. The ability of PET to quantitatively assess molecular biology in-vivo therefore makes this modality a logical candidate technique for guiding precision medicine (5). Molecular imaging has several advantages that suggest a complementary role to tissue-based assays such as genomic analysis. Imaging is non-invasive and can assess tissues that are not amenable to biopsy. Heterogeneity of tumor biology within a single tumor site, between tumor sites and within individual tumors over time represents a significant constraint on tissue analysis of biopsy material due to possible sampling error (6). Conversely, imaging can assess whole tumors as well as multiple disease sites, with the option to repeat assessments over several time points. By depicting the tumor phenotype, molecular imaging not only reflects the tumor genetic landscape but also the expression of particular gene mutations in the biological behavior. These downstream processes can potentially affect the efficacy of drugs selected on the basis of genetic assays.

There is a wide range of established and novel PET tracers that reflect key aspects of tumor biology with the potential to contribute to precision medicine. Even tumor uptake of

Fluorodeoxyglucose (FDG), the most widely used PET radiotracer for oncological diagnosis, has been associated with several tumor biological features of therapeutic significance including mutations of the Kirsten Rat Sarcoma Viral Oncogene Homolog and angiogenesis-related genes in colorectal cancer (7,8), c-kit mutations in Gastrointestinal Stromal Tumors (9), p16 status in head & neck cancer (10,11) and p-glycoprotein mediated multidrug resistance in non-small cell lung cancer and hepatocellular carcinoma (12,13). However, the fact that FDG uptake can reflect several different biological features indicates a need to combine measurements of FDG uptake with other parameters to improve specificity.

MRI offers a range of quantitative functional imaging techniques that are complementary to PET yet more extensive than is available with CT. Diffusion-weighted imaging can assess tumor cellularity, chemical shift imaging evaluates fractional water content and hypoxic blood volume, while dynamic contrast enhanced techniques reflect angiogenesis. Contrast enhancement dynamics and apparent diffusion coefficient from diffusion-weighted sequences have been shown to be associated with specific molecular subtypes in breast cancer (14-16) and to be predictive of treatment response in a range of cancers (17). These techniques can therefore potentially contribute to precision medicine in their own right.

IMPLEMENTING MULTI-PARAMETRIC PET/MRI FOR PRECISION MEDICINE

PET/MRI is particularly well suited to a role within precision medicine for a number of reasons. Firstly, imaging data that would have been acquired for clinical management using PET/CT or whole-body MRI can be obtained concurrently with a broad range of quantitative imaging techniques. Secondly, the accurate co-registration of PET and MRI datasets afforded by simultaneous image acquisition for the two modalities enables derivation

of combined PET/MRI parameters. Thirdly, multiple MR acquisitions can be acquired with no increase in radiation dose.

The multi-parametric approach to PET/MRI can be extended further by deriving additional quantitative features that reflect the heterogeneity of the biological process depicted by each PET/MRI image through utilization of image processing techniques such as texture analysis. Although a similar approach is feasible using PET/CT, the number of quantitative images available for texture analysis is much greater for PET/MRI. The potential value of MRI-based texture analysis has been illustrated recently by studies reporting that imaging results correlate with the p53 status in head & neck cancer and survival outcomes in breast cancer (18,19). Methods for deriving prognostic or predictive imaging signatures from the very large sets of parameters produced by applying image processing to multiple image acquisitions (sometimes known as radiomics) are currently poorly developed. However, these datasets are amenable to multi-parametric analysis methods such as recursive-partitioning and principle component analysis. The feasibility of radiomic analysis as applied to PET/MRI data has recently been confirmed by Antunes et al who described a 3-parameter signature combining fluorothymidine SUV from PET with texture features from T2-weighted images and **Apparent Diffusion Coefficient** maps from MRI, to maximize detection of early treatment effects in two patients with renal cancer (20).

Multi-Parametric PET/MRI for Precision Medicine in Place of Diagnostic PET/CT

When implementing multi-parametric PET/MRI for precision medicine in place of a clinically indicated diagnostic PET/CT, a broad range of MRI parameters reflecting various aspects of tumor biology can be acquired with no additional radiation burden. On the other hand, the parameters that can be derived from the PET component of the examination will be

constrained by the radiopharmaceutical required for clinical purposes, typically FDG. However, the longer acquisition time required for multi-parametric MRI creates an opportunity for simultaneous acquisition of dynamic PET data from which a range of additional parameters reflecting the temporal changes in radiotracer can be derived. Quantitative parameters from dynamic FDG PET have been shown to predict response to chemotherapy in locally advanced breast cancer and metastatic colorectal cancer (21,22). Pre-clinical studies indicate that dynamic FDG PET may also distinguish between tumors with and without inflammation (23). If confirmed in clinical studies, this capability would suggest a potential role in predicting response to immune checkpoint inhibitor for which the presence of tumor-associated inflammation is considered to be associated with long lasting response (24). Using PET/CT, derivation of these additional parameters would entail a significant extension of the examination time with corresponding impact on workflows and cost.

Some non-FDG PET tracers such as Dotatate and HBED-CC initially developed for cancer detection are now also being used to determine likely response to targeted radionuclide therapy employing the same radiopharmaceutical labelled with a therapeutic radioisotope. Using multi-parametric PET/MRI for such theranostic applications in place of PET/CT offers the potential for further improvements in the identification of patients most likely to benefit from subsequent targeted radionuclide therapy.

Multi-Parametric PET/MRI for Precision Medicine in Place of Whole-Body MRI

Whole-body MRI is now recommended for the assessment of asymptomatic myeloma patients and staging of solitary plasmacytomas (25) while whole-body MRI with diffusion imaging is emerging as a clinical tool for assessing therapeutic response in skeletal metastases (26). Although entailing an additional radiation exposure, the use of PET/MRI for

these indications in place of whole-body MRI could enable a wide range of established and novel PET tracers to be deployed for the assessment tumor biology, with the possibility of providing an indication of likely treatment response as an adjunct to the diagnostic data afforded by the whole-body MRI examination. For example, amino acid PET has shown promise as a marker of disease activity in multiple myeloma (27) and if deployed using PET/MRI could potentially improve the identification of patients requiring treatment beyond whole-body MRI alone. However, the potential to append novel PET tracers to a diagnostic whole-body MRI is currently constrained by the fact that remarkably few PET radiotracers developed during the last decades have obtained regulatory approval for routine clinical use.

HEALTH ECONOMIC IMPLICATIONS OF MULTI-PARAMETRIC PET/MRI FOR PRECISION MEDICINE

The use of multi-parametric PET/MRI to identify sub-populations of patients with a greater or lesser likelihood of treatment failure or post-treatment recurrence offers the potential to optimize clinical care according to specific characteristics of an individual patient's tumor and so improve health outcomes and reduce health care expenditure. At present, there is insufficient data to undertake formal economic evaluations to identify precise circumstances in which multi-parametric PET/MRI can replace PET/CT. However, modelling techniques such as decision tree analysis can be used to explore the outcomes that might be expected from deployment of multi-parametric PET/MRI in a range of clinical scenarios. In this way, it is possible to determine the circumstances under which multi-parametric PET/MRI has the potential to add sufficient value to replace PET/CT, given a set of plausible estimates for the model's input assumptions. These analyses can then act as a focus for future research concentrating on applications of multi-parametric PET/MRI that offer the prospect of achieving clinical cost-effectiveness (28). The incremental cost of

PET/MRI over PET/CT is a key determinate of likely cost-effectiveness and the impact of different cost estimates on likely cost-effectiveness can be evaluated using sensitivity analysis. For PET/MRI to have a realistic chance of achieving cost-effectiveness, this value needs to exceed current estimates for the incremental cost of PET/MRI. Allowing for the higher equipment cost, increased examination time and expertise required, the incremental cost of PET/MRI is currently thought to be as high as \$4000 per examination.

The identification of patients with a high likelihood of disease recurrence following treatment represents one example of precision medicine in which multi-parametric PET/MRI can potentially add sufficient value to replace PET/CT. In this scenario, the results of PET/MRI could be used to de-escalate surveillance in low-risk patients thereby reducing health-care expenditure through fewer patients undergoing surveillance. Risk-adapted follow-up of patients after colorectal cancer surgery constitutes a specific implementation of this approach. Figure 1 summarizes a decision tree sensitivity analysis that explores this scenario. Strategies 1 & 2 use diagnostic PET/CT or PET/MRI to identify metastatic disease that would render patients unsuitable for surgery. The superior diagnostic performance for PET/MRI results in fewer patients identified as suitable for surgery. In strategy 3, the addition of multi-parametric PET/MRI enables identification of a low-risk sub-population for whom surveillance can be avoided. The sensitivity analysis shows the most cost-effective strategy for paired values for probability of detecting early recurrence during surveillance (x-axis) and incremental cost of PET/MRI over PET/CT (y-axis). Despite greater diagnostic performance that PET/CT, diagnostic PET/MRI alone is unlikely to be cost-effective under any circumstances unless the incremental cost over PET/CT is less than approximately \$2000. However, multi-parametric PET/MRI is potentially cost-effective over a wide range of probabilities for detecting recurrence, even with an incremental cost of \$4000 (shaded zone).

The analysis identifies the likelihood of detecting recurrence in low-risk in comparison to high-risk patients as a key unknown that requires evaluation by future research. The estimate of 1:3 used in this analysis is comparable to that reported in a prospective evaluation of risk-adapted follow-up of colorectal cancer in which pathological features were used to stratify patients (29).

The greatest promise for economic benefit from the use of multi-parametric PET/MRI in precision medicine lies in identifying patients unlikely to receive sufficient benefit from a particular treatment. Selection of patients for immune checkpoint blockade constitutes a specific implementation of this approach for which histological techniques are currently under evaluation (30). A similar concept could be applied to theranostic applications of PET/MRI with multi-parametric imaging further refining the selection of patients for radionuclide therapy. Figure 2 summarizes a decision tree sensitivity analysis that explores such scenarios. In strategies 1 & 2, diagnostic PET/CT is used to identify patients unsuitable for chemotherapy but cannot determine the likelihood of response to targeted therapy. Therefore, all patients must receive either standard therapy (Chemotherapy A – strategy 1) or targeted therapy (Chemotherapy B – strategy 2). In strategy 3, multi-parametric PET/MRI has the same diagnostic capability as PET/CT but adds value by identifying a sub-population of patients most likely to respond to targeted therapy. The sensitivity analysis shows the most cost-effective strategy for paired values for prevalence of responders (x-axis) and incremental cost per patient of PET/MRI over PET/CT (y-axis). Multi-parametric PET/MRI is potentially cost-effective over a wide range of values for prevalence of responders, even with an incremental cost of \$4000 (shaded zone). There are no conditions under which PET/MRI would be cost-effective if used for diagnosis alone.

CHALLENGES FACING THE USE OF PET/MRI FOR PRECISION MEDICINE IN ONCOLOGY

The success of the above approach is predicated on meeting a number of challenges that face the use of multi-parametric imaging within the precision medicine paradigm in oncology.. Technological issues include the lack of purpose-designed computer software for extraction and reporting of multi-parametric imaging data, and methods for identifying and validating multi-parametric imaging signatures are currently underdeveloped. It is also essential to establish protocols that ensure measurement consistency of multi-parametric PET/MRI across different imaging platforms. There is a requirement for training of radiologists and technical staff who may be unfamiliar with the concepts of precision medicine. As the use of imaging for precision medicine represents a novel paradigm within cancer care, an initial reluctance by clinicians to accept this role for imaging can be also anticipated. It will also be necessary to demonstrate the value of multi-parametric imaging in comparison to competing technologies such as tissue and blood-based assays.

CONCLUSIONS

PET/MRI is a remarkable hybrid imaging device that combines the advantages of two powerful modalities. However, the diagnostic benefits of this combination appear to be limited and supplementary clinical roles must be established for PET/MRI to become a routine modality within clinical cancer care. Although the challenges involved should not be underestimated, the use of multi-parametric PET/MRI for precision medicine can not only increase the clinical value accruing from deployment of this technology but also potentially establish it as cost-effective modality within clinical cancer care.

REFERENCES

1. Spick C, Herrmann K, Czernin J. 18F-FDG PET/CT and PET/MRI **perform equally well in cancer: evidence from studies on more than 2,300 patients**. *J Nucl Med*. 2016;57:420-30.
2. Kuwert T, Ritt P. PET/MRI and PET/CT: is there room for both at the top of the food chain? *Europ J Nucl Med Mol Imaging*. 2016;43:209-11.
3. Krishnaraj A, Weinreb JC, Ellenbogen PH, Allen B, Norbash A, Kazerooni EA. The future of imaging biomarkers in radiologic practice: proceedings of the thirteenth annual ACR forum. *J Am Col Radiol*. 2014;11:20-3.
4. Sala E, Micco M, Burger IA, et al. Complementary prognostic value of pelvic magnetic resonance imaging and whole-body fluorodeoxyglucose positron emission tomography/computed tomography in the pretreatment assessment of patients with cervical cancer. *Int J Gynecol Cancer*. 2015;25:1461–1467.
5. Schillaci O, Urbano N. Personalized medicine: a new option for nuclear medicine and molecular imaging in the third millennium. *Europ J Nuclear Med Mol Imaging*. 2017; 44:563-566
6. Chowdhury R, Ganeshan B, Irshad S, **et al**. The use of molecular imaging combined with genomic techniques to understand the heterogeneity in cancer metastasis. *Brit J Radiol*. 2014;8:20140065.
7. Strauss LG, Koczan D, Klippel S, et al. Impact of angiogenesis-related gene expression on the tracer kinetics of 18F-FDG in colorectal tumors. *J Nucl Med*. 2008;49:1238–44.
8. Kawada K, Toda K, Nakamoto Y, **et al**. Relationship between 18F-FDG PET/CT scans and KRAS mutations in metastatic colorectal cancer. *J Nucl Med*. 2015;56:1322-7.

9. Strauss LG, Dimitrakopoulou-Strauss A, Koczan D, Pan L, Hohenberger P. Correlation of dynamic PET and gene array data in patients with gastrointestinal stromal tumors. *ScientificWorldJournal*. 2012;2012:721313.
10. Joo YH, Yoo IR, Cho KJ, Park JO, Nam IC, Kim MS. Preoperative 18F-FDG PET/CT and high-risk HPV in patients with oropharyngeal squamous cell carcinoma. *Head Neck*. 2014;36:323-7.
11. Kendi AT, Magliocca K, Corey A, et al. Do 18F-FDG PET/CT parameters in oropharyngeal and oral cavity squamous cell carcinomas indicate HPV status? *Clin Nucl Med*. 2015;40:e196.
12. Higashi K, Ueda Y, Ikeda R, et al. P-glycoprotein expression is associated with FDG uptake and cell differentiation in patients with untreated lung cancer. *Nucl Med Commun*. 2004;25:19-27.
13. Seo S, Hatano E, Higashi T, et al. Fluorine-18 fluorodeoxyglucose positron emission tomography predicts tumor differentiation, P-glycoprotein expression, and outcome after resection in hepatocellular carcinoma. *Clin Cancer Res*. 2007;13:427-33.
14. Mazurowski MA, Zhang J, Grimm LJ, et al. Radiogenomic analysis of breast cancer: luminal B molecular subtype is associated with enhancement dynamics at MR imaging. *Radiology*. 2014; 273:365–372.
15. Agner SC, Rosen MA, Englander S, et al. Computerized image analysis for identifying triple-negative breast cancers and differentiating them from other molecular subtypes of breast cancer on dynamic contrast-enhanced MR images: a feasibility study. *Radiology*. 2014;272:91–99.
16. Youk JH, Son EJ, Chung J, Kim JA, Kim EK. Triple-negative invasive breast cancer on dynamic contrast-enhanced and diffusion-weighted MR imaging: comparison with other breast cancer subtypes. *Eur Radiol*. 2012;22:1724-34.

17. Thoeny HC, Ross BD. Predicting and monitoring cancer treatment response with diffusion-weighted MRI. *J Magn Reson Imaging*. 2010;32:2-16.
18. Dang M, Lysack JT, Matthews TW, et al. MRI texture analysis predicts p53 status in head and neck squamous cell carcinoma. *AJNR Am J Neuroradiol*. 2015;36:166-701
19. Michoux N, Van Den Broeck S, Lacoste L, et al. Texture analysis on MR images helps predicting non-response to NAC in breast cancer. *BMC Cancer*. 2015;15:574
20. Antunes J, Viswanath S, Rusu M, et al. Radiomics analysis on FLT-PET/MRI for characterization of early treatment response in renal cell carcinoma: a proof-of-concept study. *Transl Oncol*. 2016;9:155-62.
21. Mankoff DA, Dunnwald LK, Gralow JR, et al. Blood flow and metabolism in locally advanced breast cancer: relationship to response to therapy. *J Nucl Med*. 2002;43:500-9.
22. Dimitrakopoulou-Strauss A, Strauss LG, Burger C, et al. Prognostic aspects of 18F-FDG PET kinetics in patients with metastatic colorectal carcinoma receiving FOLFOX chemotherapy. *J Nucl Med*. 2004;45:1480-7
23. Yang Z, Zan Y, Zheng X, et al. Dynamic FDG-PET **imaging to differentiate malignancies from inflammation in subcutaneous and in situ mouse model for Non-Small Cell Lung Carcinoma (NSCLC)**. *PLoS One*. 2015;10:e0139089.
24. Tsaknakis B, Schaefer IM, Schwörer H, et al. Long-lasting complete response of metastatic melanoma to ipilimumab with analysis of the resident immune cells. *Med Oncol*. 2014;31:813.
25. Rajkumar SV, Dimopoulos MA, Palumbo A, et al. International Myeloma Working Group updated criteria for the diagnosis of multiple myeloma. *Lancet Oncol*. 2014;15:e538-48.
26. Lecouvet FE, Larbi A, Pasoglou V, et al. MRI for response assessment in metastatic bone disease. *Eur Radiol*. 2013;23:1986-97

27. Lapa C, Knop S, Schreder M, et al. ^{11}C -Methionine-PET in multiple myeloma: correlation with clinical parameters and bone marrow involvement. *Theranostics*. 2016;6:254-61
28. Chilcott J, Brennan A, Booth A, Karnon J, Tappenden P. The role of modelling in prioritising and planning clinical trials. *Health Technol Assess*. 2003;7:1-25
29. Secco GB, Fardelli R, Gianquinto D, et al. Efficacy and cost of risk-adapted follow-up in patients after colorectal cancer surgery: prospective, randomized controlled trial. *Eur J Surg Oncol*. 2002;28:418-423
30. Aguiar PN, Perry L, Penny-Dimr J, et al. The effect of PD-L1 testing on the cost-effectiveness and economic impact of immune checkpoint inhibitors for the second-line treatment of NSCLC. *Ann Oncol*. 2017;28:2256-2263

FIGURES

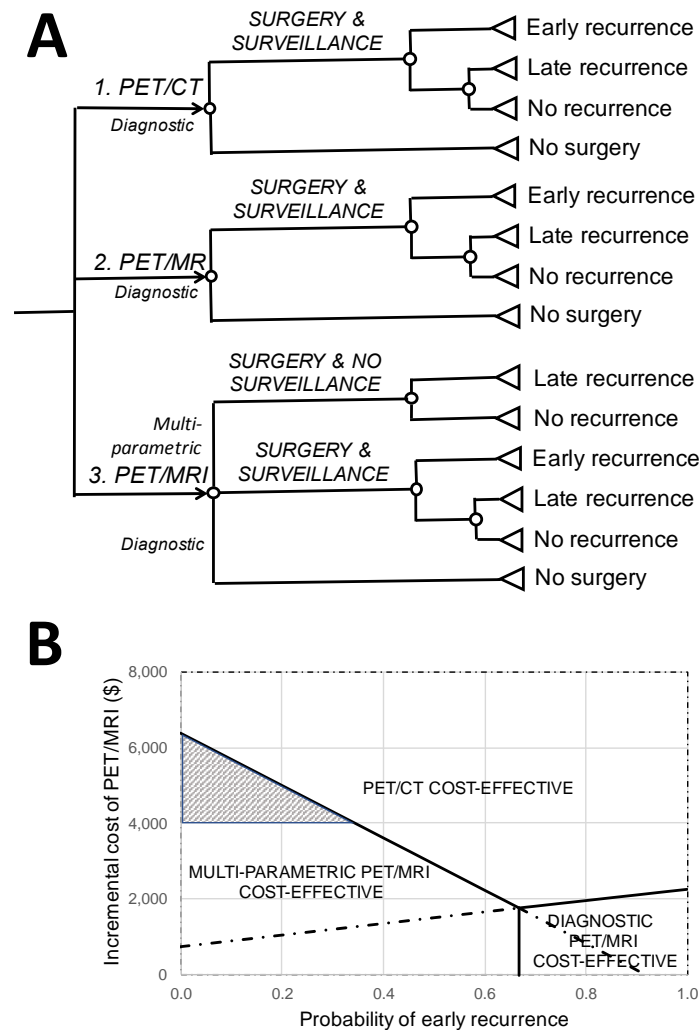


Figure 1: Illustrative decision tree (A) and sensitivity analysis (B) exploring the health economic conditions under which multi-parametric PET/MRI could add value by enabling risk-adapted post-surgical surveillance for the early detection and treatment of recurrence. (Assumptions: Likelihood of detecting metastatic disease; 20% for PET/CT & 25% for PET/MRI, Likelihood of detecting recurrence in low-risk patients; 1/3 of that for high-risk patients, Incremental costs per patient for surveillance and treatment of early recurrence; \$15,000 and \$30,000 respectively, Incremental benefit per patient from early treatment of recurrence; 1.5 QALY, Health purchaser's willingness to pay; \$50,000/QALY. Solid lines indicate where two strategies have equal Net Monetary Benefit.)

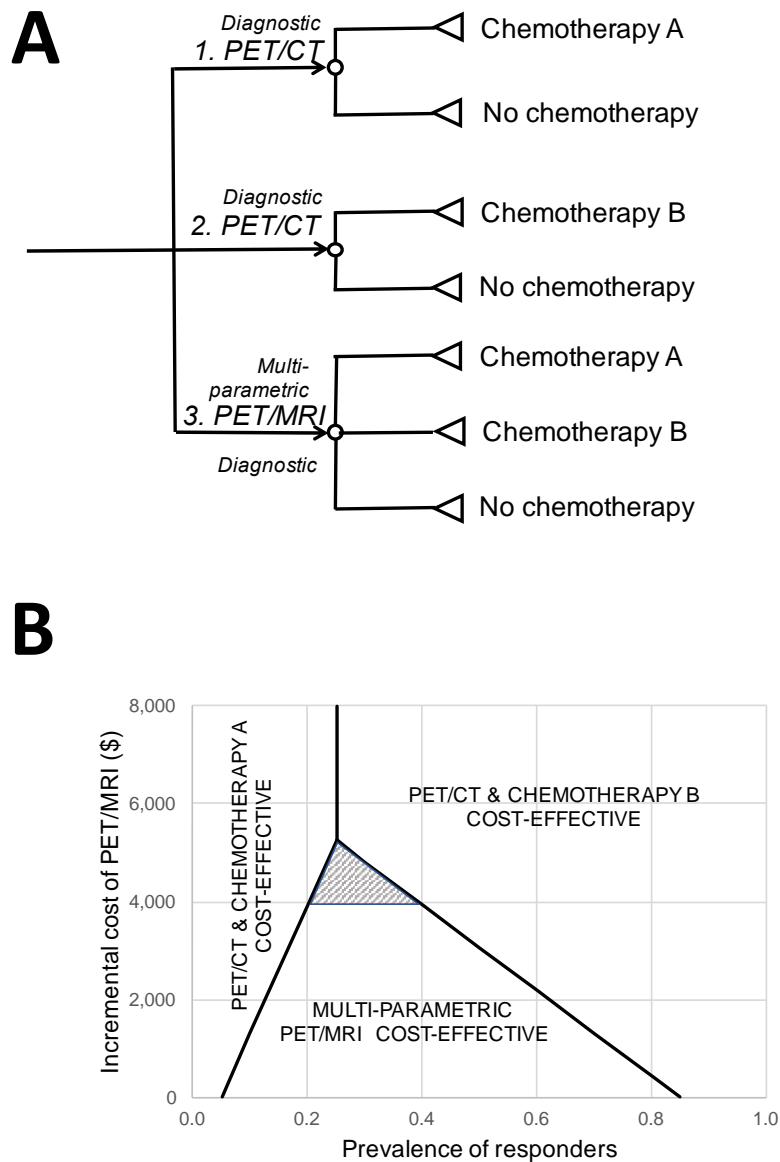


Figure 2: Illustrative decision tree (A) and sensitivity analysis (B) to identify health economic conditions under which multi-parametric PET/MRI could add value by identifying a sub-population enriched for response to targeted therapy. (Assumptions: Likelihood of receiving chemotherapy; 70%, False positive and false negative rates for PET/MRI identification of responders; 15% and 5% respectively, Incremental cost and benefit per patient for chemotherapy B over chemotherapy A; \$12,500 and 1.0 QALY respectively, Health purchaser's willingness to pay; \$50,000/QALY. Solid lines indicate where two strategies have equal Net Monetary Benefit.)

Financial Disclosure: Author KAM is a shareholder in Feedback PLC which supplies software for CT texture analysis.