



**University of Dundee**

## **Epidermal desquamation in Thiel-embalmed cadavers**

Dzetkulicová, Veronika; Langstaff, Helen; Hackman, Sarah

*Publication date:*  
2018

*Document Version*  
Publisher's PDF, also known as Version of record

[Link to publication in Discovery Research Portal](#)

*Citation for published version (APA):*

Dzetkulicová, V., Langstaff, H., & Hackman, S. (2018). Epidermal desquamation in Thiel-embalmed cadavers: histologic study. Poster session presented at 2nd Annual Science and Engineering PhD Symposium, Dundee, United Kingdom.

### **General rights**

Copyright and moral rights for the publications made accessible in Discovery Research Portal are retained by the authors and/or other copyright owners and it is a condition of accessing publications that users recognise and abide by the legal requirements associated with these rights.

- Users may download and print one copy of any publication from Discovery Research Portal for the purpose of private study or research.
- You may not further distribute the material or use it for any profit-making activity or commercial gain.
- You may freely distribute the URL identifying the publication in the public portal.

### **Take down policy**

If you believe that this document breaches copyright please contact us providing details, and we will remove access to the work immediately and investigate your claim.

# Epidermal desquamation in Thiel-embalmed cadavers: histologic study

Sabolova V., Hackman L., Langstaff H.

## Introduction

Fingerprint comparison is often used to identify dead. Direct comparison of dermal and epidermal fingerprints can be vital to the identification of bodies that have been in water for long periods of time and epidermal skin layer is lost.

Epidermal desquamation occurs during the fixation of bodies in Thiel embalming fluid. The desquamation process therefore provides an opportunity to compare dermal and epidermal fingerprints from the same individual, however current literature is vague on the histology of the detached skin layer in Thiel-embalmed bodies.

In order to understand the desquamation process that exposes dermal fingerprints, it is important to confirm at which histological level of the skin the desquamation occurs. The desquamation that occurs as a result of the Thiel embalming process allows investigation to establish both where the separation of the skin layers occurs, but also at which point during exposure of the skin to a wet environment this separation might be expected to happen.

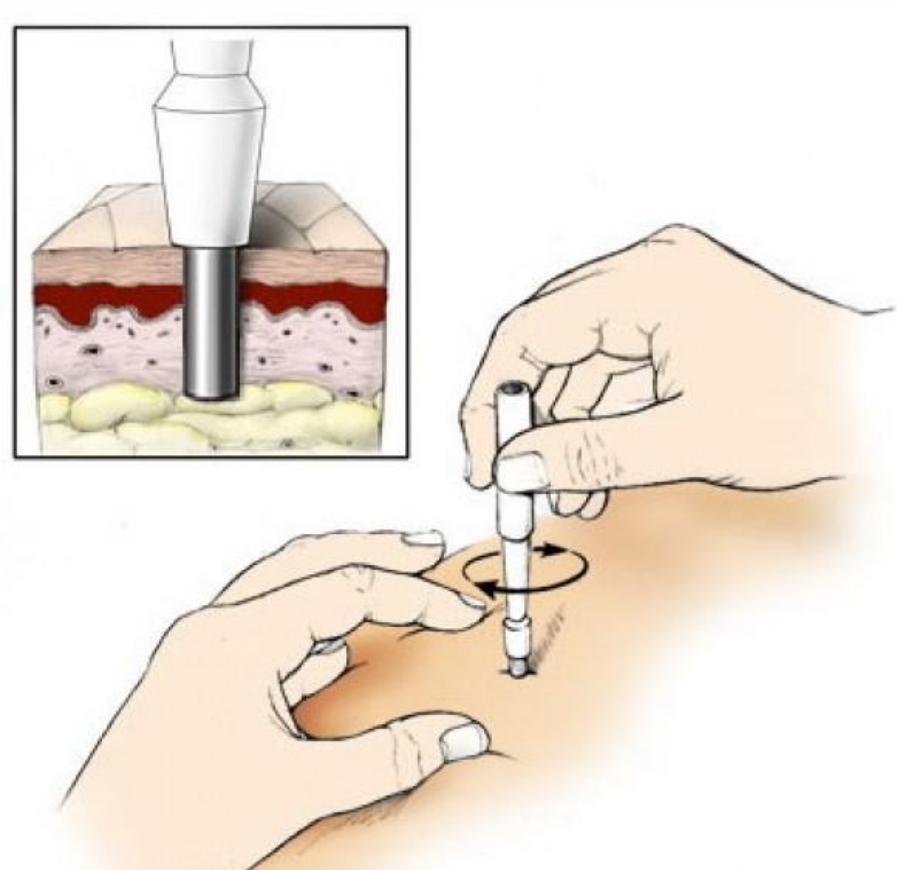
## Aim

To establish a timeframe of epidermal desquamation and describe the histology of epidermal desquamation which occurs as a result of the Thiel embalming process.

## Material and Method

- Individuals bequeathed to CAHID (N = 8)
- Left thumb
- Biopsy skin punch (Ø 4mm)
- Hematoxylin-Eosin staining
- Optical light microscopy
- Sampled prior to embalming and then weekly for 4 to 6 weeks after the immersion into embalming tank

Individual	Sex	Age	Week of last sampling
1	M	98	4
2	F	91	4
3	F	90	4
4	F	84	4
5	F	75	4
6	F	81	6
7	F	77	6
8	M	62	4



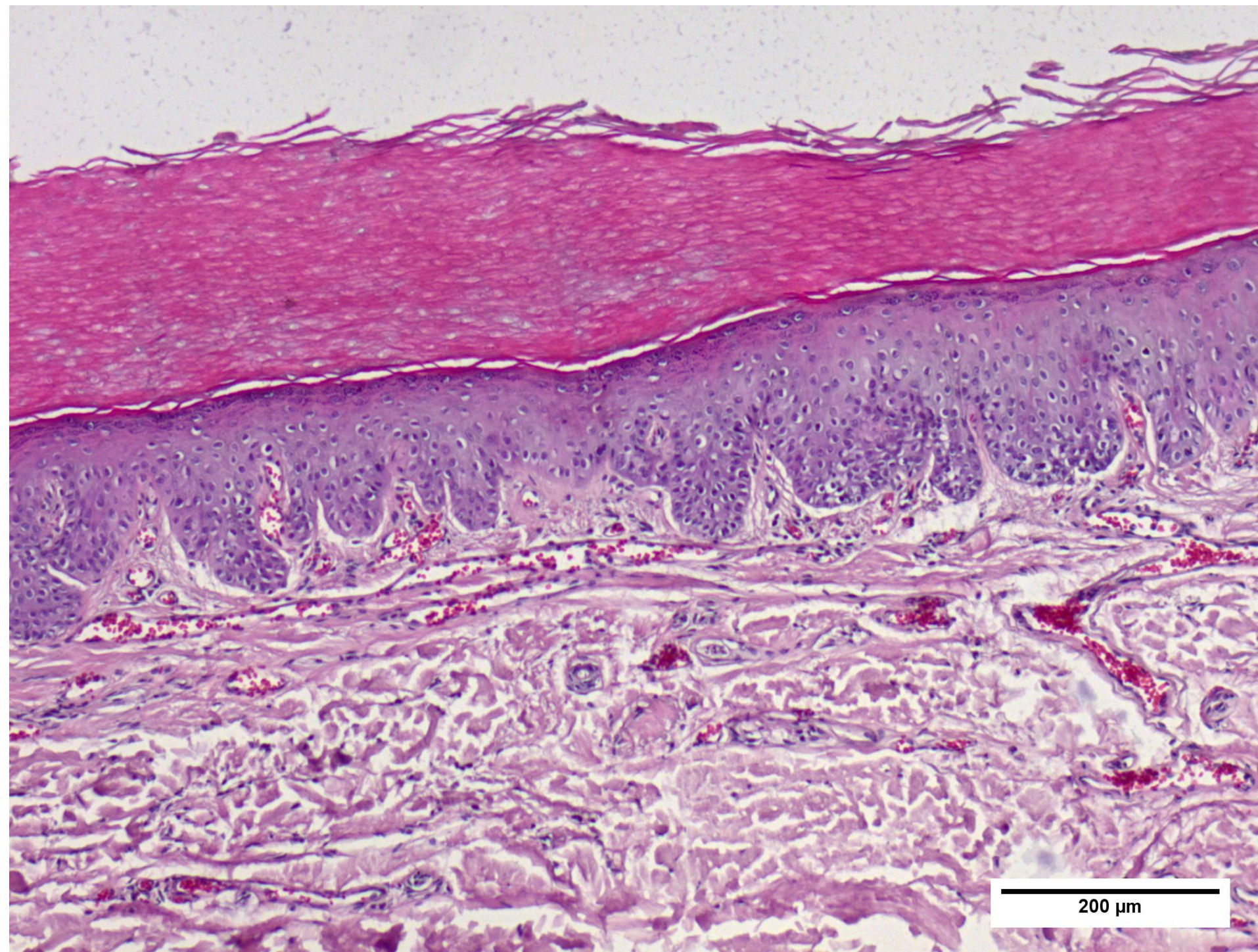
Biopsy skin punch



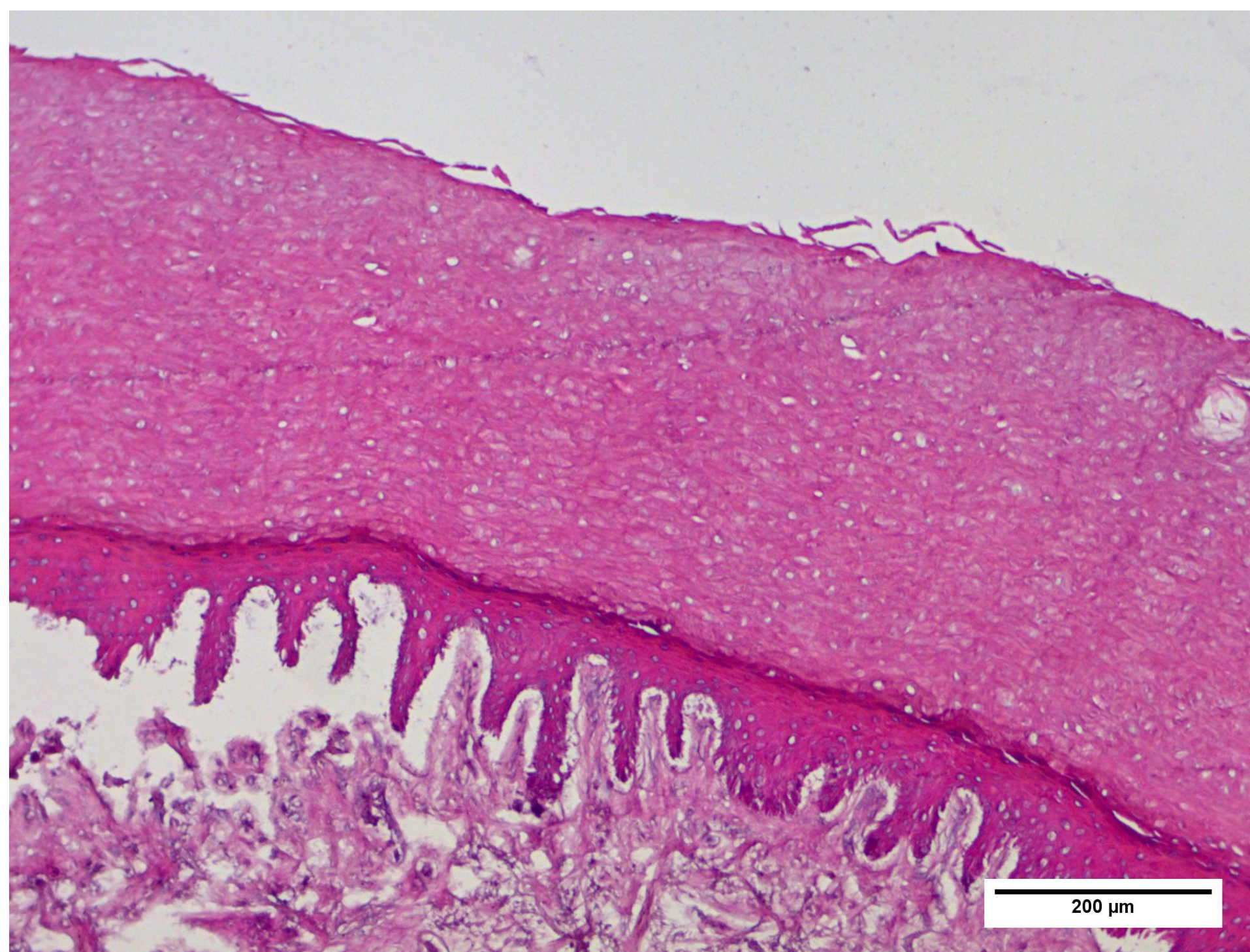
Binocular microscope

## Results

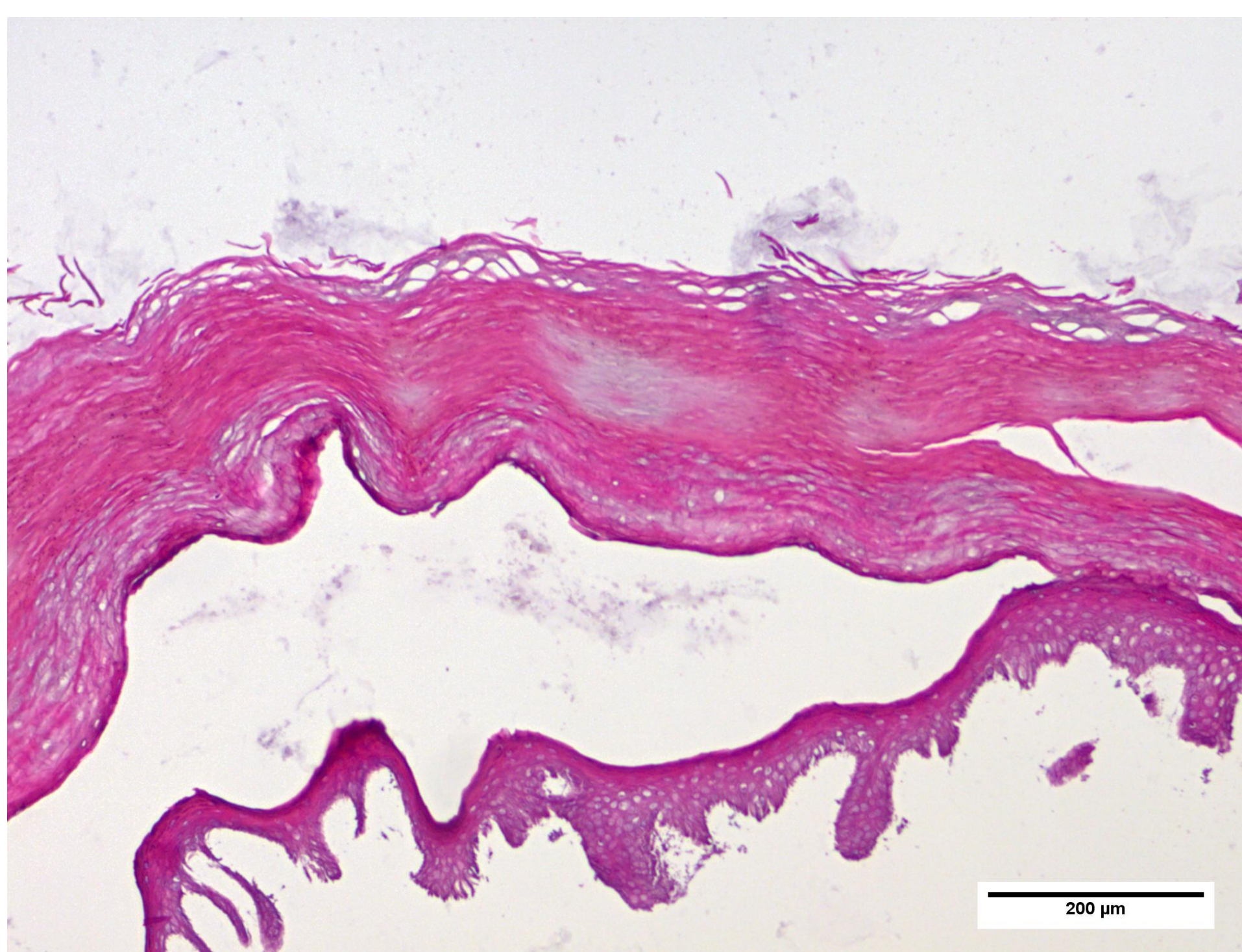
The epidermal skin layer became completely detached between the first and the sixth week after immersion into Thiel embalming fluid.



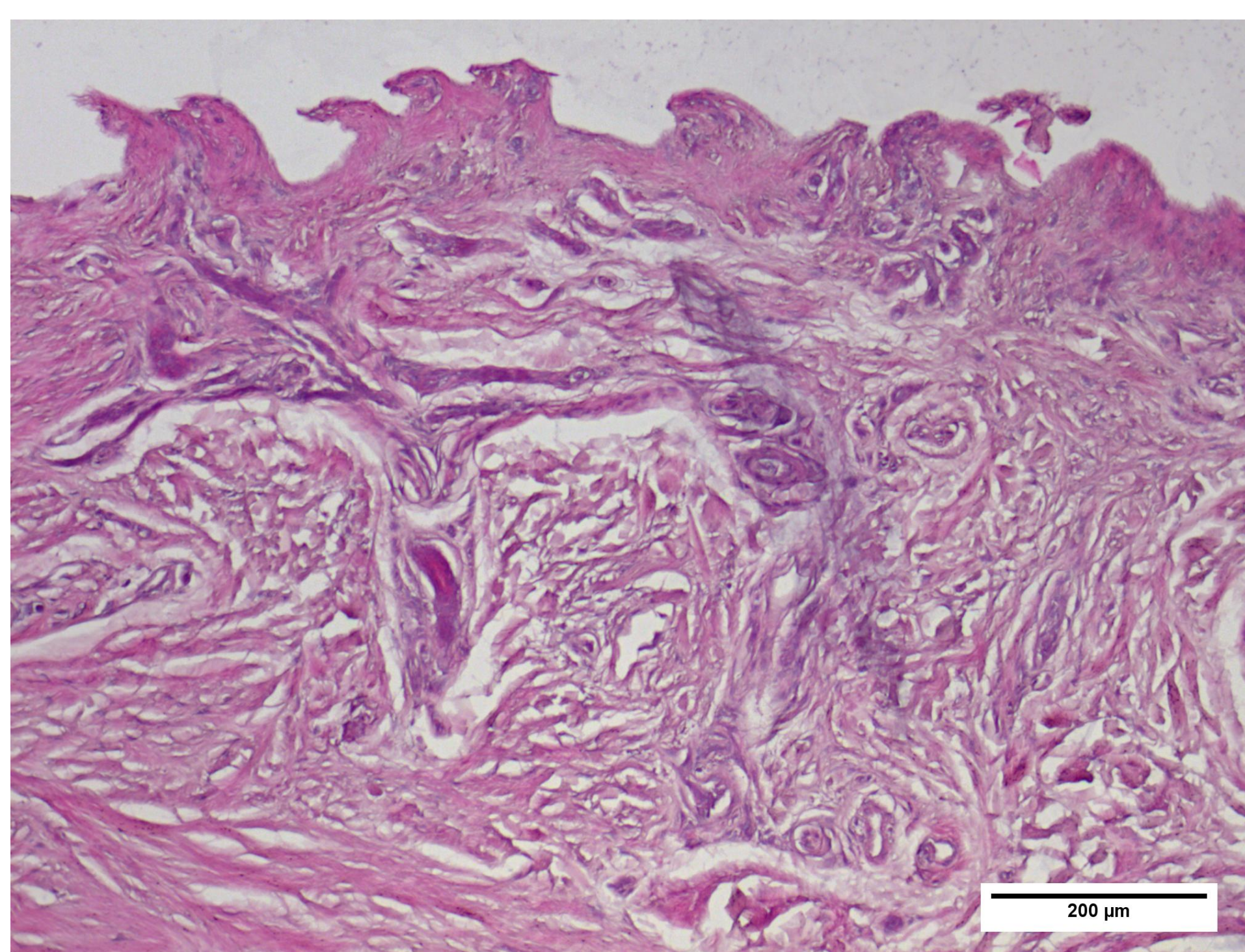
Individual 4 pre-embalming: epidermis attached to dermis



Individual 2 week 3 in Thiel fluid: detaching of epidermis from dermis



Individual 5 week 1 in Thiel fluid: detached epidermis



Individual 1 week 1 in Thiel fluid: exposed dermis

## Results

Epidermal desquamation was completed by week four of immersion in Thiel embalming fluid in six sampled individuals.

Surface skin layer observed in histologic section.  
E = epidermis, D = dermis


Individual	Pre-embalming	Week 1	Week 2	Week 3	Week 4	Week 5	Week 6
1	E	D	D	D	D	-	-
2	E	E	D	E	D	-	-
3	E	D	D	D	D	-	-
4	E	E	E	D	D	-	-
5	E	D	D	D	D	-	-
6	E	E	E	E	E	E	E
7	E	E	D	E	E	D	D
8	E	E	E	E	D	-	-

## Conclusions

By week four of the immersion in the embalming fluid, desquamation was completed in a majority of individuals. For three samples, desquamation occurred during week one of the immersion in embalming fluid. More samples are required to study temporal variations in epidermal desquamation caused by Thiel embalming process.

As epidermal desquamation during embalming process exposes the dermal skin layer, Thiel-embalmed cadavers are suggested as suitable models for further research of dermal-epidermal fingerprint comparison.

Dermal fingerprints can be collected from Thiel-embalmed bodies after week six of the immersion in embalming fluid.



Epidermal fingerprint

Dermal fingerprint

## Acknowledgements

The authors would like to thank all the bequeathed who kindly donated their bodies for teaching and research purposes to the Centre for Anatomy and Human Identification and without whom this research would not be possible. Further thanks go to the anatomy technical staff and colleagues from the centre for all the help and support provided.