



Walter, C., Chapple, I. L. C., Ower, P., Tank, M., West, N. X., Needleman, I., ... Dietrich, T. (2019). Periodontal diagnosis in the context of the BSP implementation plan for the 2017 classification system of periodontal diseases and conditions: Presentation of a patient with a history of periodontal treatment. *British Dental Journal*, 226(4), 265-267.
<https://doi.org/10.1038/s41415-019-0015-2>

Peer reviewed version

Link to published version (if available):
[10.1038/s41415-019-0015-2](https://doi.org/10.1038/s41415-019-0015-2)

[Link to publication record in Explore Bristol Research](#)
PDF-document

This is the author accepted manuscript (AAM). The final published version (version of record) is available online via BDJ at <https://doi.org/10.1038/s41415-019-0015-2> . Please refer to any applicable terms of use of the publisher.

University of Bristol - Explore Bristol Research

General rights

This document is made available in accordance with publisher policies. Please cite only the published version using the reference above. Full terms of use are available:
<http://www.bristol.ac.uk/pure/about/ebr-terms>

Periodontal diagnosis in the context of the BSP implementation plan for the 2017 classification system of periodontal diseases and conditions: Presentation of a patient with a history of periodontal treatment

Walter C, Chapple ILC, Ower P, Tank M, West NX, Needleman I, Wadia R, Milward MR, Hodge PJ, Dietrich T*

***Corresponding author:**

Prof. Thomas Dietrich

The School of Dentistry

University of Birmingham

5 Mill Pool Way

Birmingham

B5 7EG

UK

Tel.: +44-121-4665494

Email: t.dietrich@bham.ac.uk

In brief

This case report is the fourth in a series that illustrates the application of the BSP implementation plan for diagnosing periodontitis patients according to the 2017 classification. It demonstrates the diagnostic approach and disease classification for a previously treated patient, who presented with a diagnosis of unstable generalised periodontitis stage IV grade C.

Abstract

This case report is the fourth in a series that illustrates the application of the BSP implementation plan for diagnosing periodontitis patients according to the 2017 classification. It demonstrates the diagnostic approach and disease classification for a previously treated patient who presented with a diagnosis of unstable generalised periodontitis; stage IV, grade C. We describe a case of a 49-year-old patient who attended with a history of periodontal treatment over several years. Following a full periodontal assessment, the patient was diagnosed with 'generalised periodontitis; stage IV, grade C; currently unstable'. This case report presents an example of how to classify and diagnose a patient using the 2017 classification system and highlights challenges with the application of the new classification in patients with a previous history of periodontal therapy.

Keywords:

Demonstrates the diagnostic approach and disease classification for a previously treated patient; Highlights challenges with the application of the new classification in patients with a previous history of periodontal therapy.; Illustrates the diagnosis and classification of periodontitis according to the 2017 classification system as recommended in the British Society of Periodontology (BSP) implementation plan.; grade C.; who presented with a diagnosis of unstable generalised periodontitis stage IV

Introduction

The comprehensive oral health assessment of a newly presenting patient includes a periodontal assessment. In patients without a history of periodontal disease or in whom a clinical inspection does not indicate its presence, periodontal probing is required to confirm or otherwise the absence of periodontal disease. This will typically involve the use of an established screening tool, such as the Basic Periodontal Examination (BPE), which will either confirm the absence of periodontal disease, result in a diagnosis of localised or generalised gingivitis, or trigger further clinical and radiographic examination. The rationale for the application of the BPE is to carefully screen for signs of periodontitis (i.e., increased probing depth), while at the same time, avoiding the time-consuming process of recording a detailed periodontal chart in patients with no periodontitis. However, in patients with clear evidence of periodontitis based on their history and/or clinical inspection (i.e. the presence of interproximal attachment loss), the BPE is essentially redundant, and a full periodontal assessment is indicated.

In this case presentation we report on a patient who presented with a history of treatment for periodontitis. We demonstrate step-by-step how the BSP recommendations for implementation of the 2017 classification system can be applied in practice to reach an appropriate periodontal diagnosis.^{1,2,3,4}

Case report

A 49 year old female patient who had recently moved into the area presented in good general health. Specifically she has not been diagnosed with diabetes mellitus, was not taking any medications regularly, reported a history of several courses of periodontal treatment by her previous GDP. Clinical examination revealed overt interproximal recession/clinical attachment loss (Fig. 1).

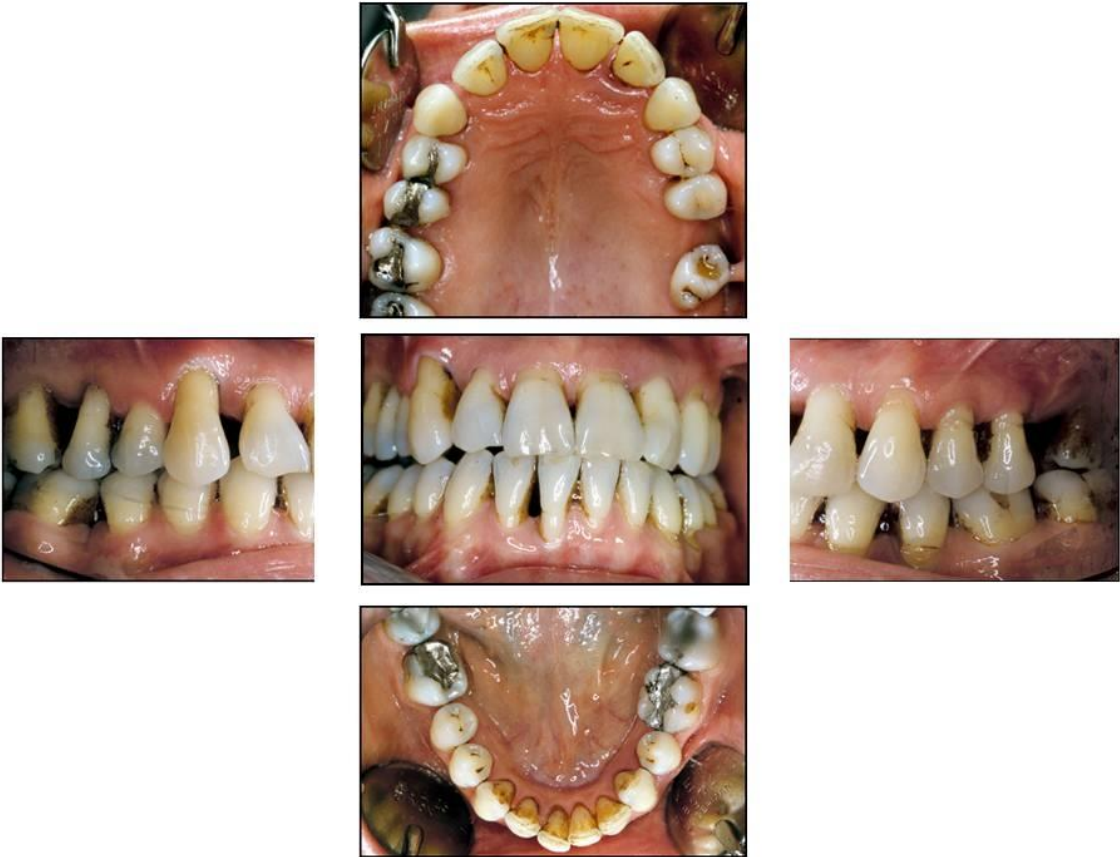


Fig. 1 Intraoral view

Given the history of periodontitis provided by the patient and the clear evidence of interproximal clinical attachment loss due to periodontitis, a detailed pocket chart (DPC) was indicated (Fig 2).

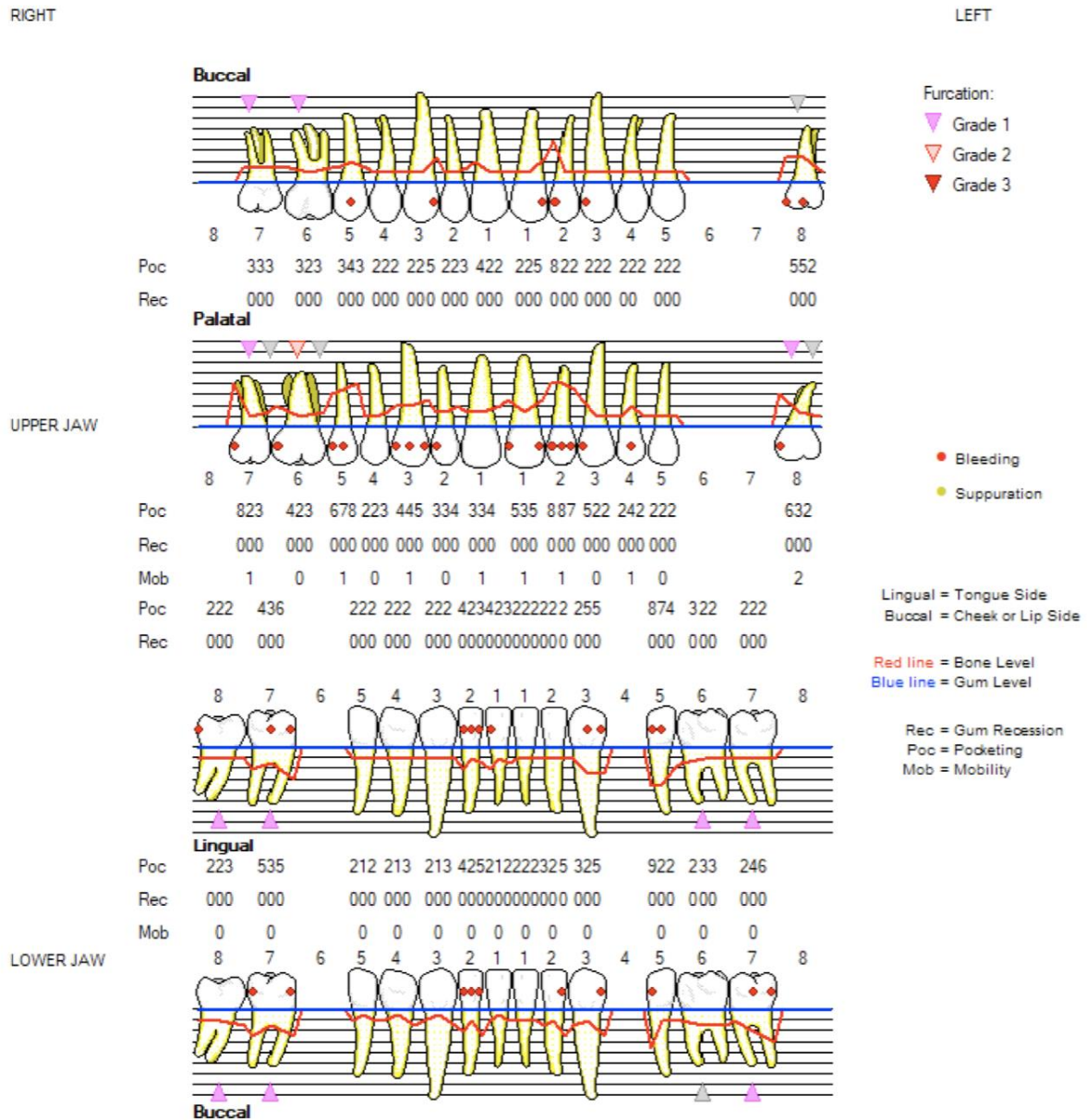


Fig. 2 Detailed periodontal chart

The DPC showed deep pockets (>5mm) on 7 teeth with pocket depths extending to 9mm, and moderate pockets (4-5mm) on an additional 11 teeth. Furcation involvement was evident on all molars and both upper first premolars. Periapical radiographs were taken (Fig. 3).

The medical and dental history as well as the clinical and radiographic findings were consistent with a diagnosis of periodontitis, and staging and grading was performed as the next step.

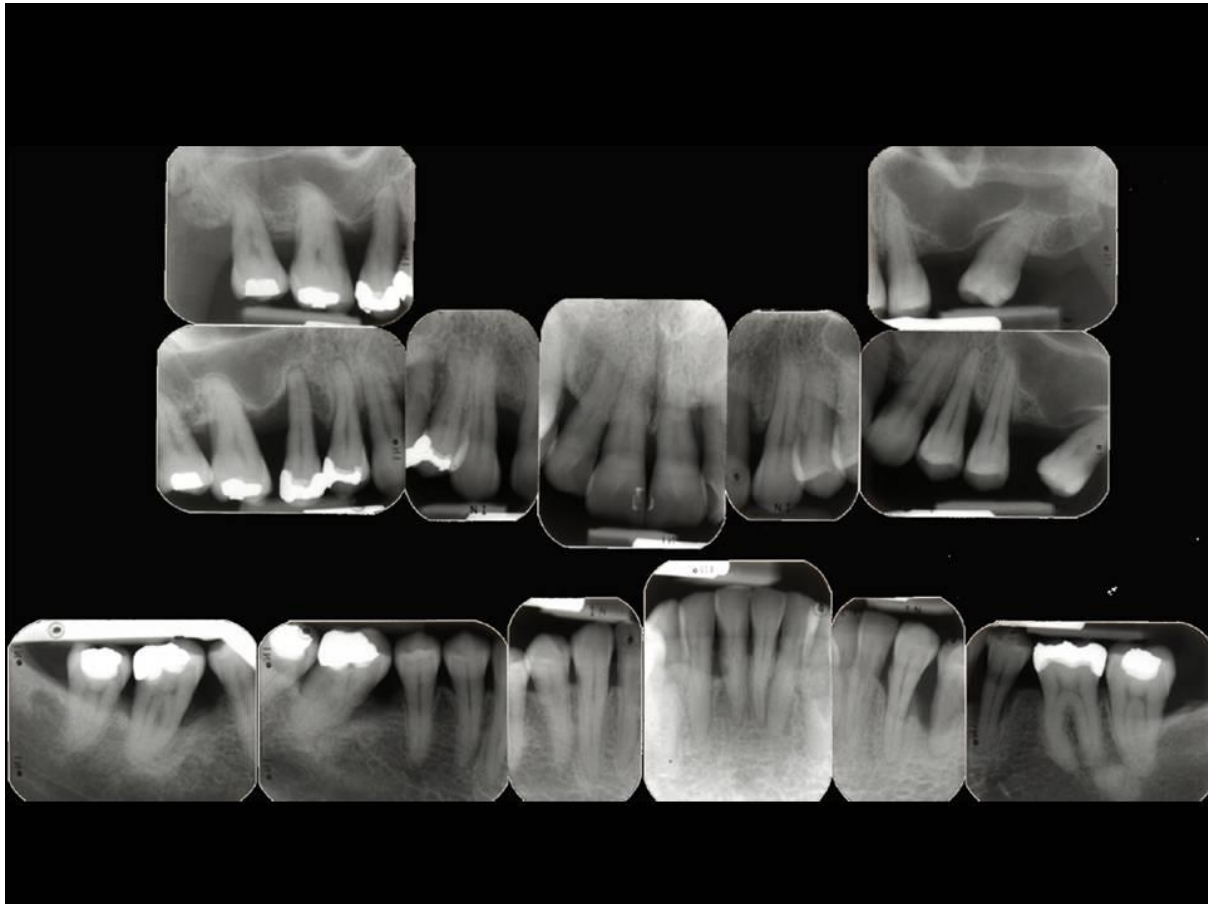


Fig. 3 Periapical radiographs

The radiographs showed evidence of bone loss on all teeth with the possible exception of teeth 43, 44, 45, 47 and 36. On tooth 15 and 35, bone loss appeared to extend into the apical third of the root (80% bone loss on 15), resulting in a classification of stage IV periodontitis for this patient. Given that the patient was 49 years old, the disease was classified as grade C periodontitis (80% bone loss divided by age 49 years results in a percentage boneloss/age ratio > 1.0 , indicating a grade C). At least 21 out of 26 teeth exhibited bone loss due to periodontitis, making this a case of generalised periodontitis.

In summary, the definitive diagnosis was 'generalised periodontitis; Stage IV/Grade C; currently unstable'. The patient concerned will always be a periodontitis patient, with evidence of high disease susceptibility (as indicated by grade C), requiring careful and intensive periodontal maintenance, risk factor control and monitoring.

Discussion/Summary

This case report provides an example of how to diagnose a patient with a history of periodontitis according to the 2017 classification of periodontal and peri-implant diseases and conditions by following the BSP implementation plan ¹. Because the patient gave a history of periodontal treatment and presented with clear evidence for generalised interproximal attachment loss due to periodontitis upon inspection, a diagnosis of periodontitis was made without the use of a BPE, as the use of a screening test in a patient who is already known to have the disease of interest is not helpful. Instead, a full periodontal assessment was performed immediately.

One of the main new features of the new 2017 classification system is the staging and grading of disease in patients diagnosed with periodontitis. The system represents a major advance as it allows for a clear distinction of disease severity (stage) on one hand, and disease susceptibility (grade), on the other. The disease stage reflects the amount of periodontal tissue loss that has already occurred due to periodontitis, and a higher stage will be associated with a higher complexity in terms of periodontal and restorative management of the disease. The disease grade reflects the interplay of all causal factors that have conspired to produce a particular level of tissue destruction in a specific patient over a given period of time.

Grading thus focuses the clinician's mind on the patient's risk of future disease progression and their 'risk factor profile'. For simplicity, the BSP implementation plan proposed to base disease grade on the ratio of radiographic bone loss to age¹, the application of which is demonstrated in this case report. However, these are limitations. Firstly, disease susceptibility may change as risk factors are managed (for example, if a patient quits smoking) or when new risk factors are acquired (for example, a patient may develop diabetes). Secondly, according to the 2017 classification system, the staging and grading of periodontitis are to be performed 'at presentation'.⁵ Periodontitis is a chronic inflammatory

disease that many patients live with for decades, and it is currently unclear if and if so, how often the staging and/or grading should be repeated.

Furthermore, in patients with a long-standing history of disease, previous periodontal therapy, depending on its effectiveness, will have affected disease progression to varying degrees. The patient presented here reported to have received several courses of therapy. These had clearly not been successful as she presented with unstable periodontitis (many sites with PPD 5+mm and bleeding sites with PPD 4+mm). A discussion of the reasons for not reaching a healthy and potentially stable treatment outcome is beyond the scope of this report. However, even if resolution of periodontitis had not been achieved, it is possible that the previous therapy had slowed progression of periodontal tissue loss to some extent. In the present case this did not affect the grading as the highest possible grade was assigned; however, this may result in an underestimate of disease grade in some patients, in particular in those who have been successfully treated and maintained for many years.

References

1. Dietrich T, Ower P, Tank M, et al. Periodontal diagnosis in the context of the 2017 classification system of periodontal diseases and conditions - implementation in clinical practice. *Br Dent J* 2019;226(1):16-22. doi: 10.1038/sj.bdj.2019.3 [published Online First: 2019/01/12]
2. Walter C, Chapple ILC, Ower P et al. Periodontal diagnosis in the context of the 2017 classification system of periodontal diseases and conditions: presentation of a pair of young siblings with periodontitis. *Br Dent J* 2019
3. Walter C, Owever P, Tank M et al. Periodontal diagnosis in the context of the 2017 classification system of periodontal diseases and conditions: Presentation of a middle-aged patient with localised periodontitis. *Br Dent J* 2019
4. Wadia R, Walter C, Chapple ILC. Periodontal diagnosis in the context of the 2017 classification system of periodontal diseases and conditions: Presentation of a patient with periodontitis localised to molar teeth. *Br Dent J* 2019
5. Papapanou PN, Sanz M, Buduneli N, et al. Periodontitis: Consensus report of workgroup 2 of the 2017 World Workshop on the Classification of Periodontal and Peri-Implant Diseases and Conditions. *J Clin Periodontol* 2018;45 Suppl 20:S162-S70. doi: 10.1111/jcpe.12946 [published Online First: 2018/06/22]