View metadata, citation and similar papers at core.ac.uk

brought to you by CORE

provided by Queen Mary Research Online

Haematologica
HAEMATOL/2017/183855
Version 3

Expanding the phenotypic and genetic spectrum of radioulnar synostosis associated hematological disease

Amanda Walne, Hemanth Tummala, Alicia Ellison, Shirleny Cardoso, Jasmin Sidhu, Gabriela Sciuccati, Tom Vulliamy, and Inderjeet Dokal

Disclosures: None

Contributions: AW, HT and AE performed the research. GS and ID provided clinical material and data. AW, HT,SC and JS wrote the manuscript. TV and ID supervised the study

Expanding the phenotypic and genetic spectrum of radioulnar synostosis associated hematological disease

Amanda Walne[1], Hemanth Tummala[1], Alicia Ellison[1], Shirleny Cardoso[1], Jasmin Sidhu[1], Gabriela Sciuccati[2], Tom Vulliamy[1], Inderjeet Dokal[1]

[1] Centre for Genomics and Child Health, Blizard Institute, Barts and The London School of Medicine and Dentistry, Queen Mary University of London, Barts NHS Trust, London, UK

[2] Sercico de Hematologia y Oncologia, Hospital de Pediatria "Prof. Dr. J.P. Garrahan", Buenos Aires, Argentina

Corresponding author – Amanda Walne (a.walne@qmul.ac.uk)

Word count 1460

Congenital radioulnar synostosis (RUS) is a rare developmental abnormality involving fusion of the bones of the forearms (radius and ulna) preventing normal supination of the affected forearm and has been recognized in the orthopaedic literature since the mid-1800s. It is apparent that there is a subgroup of patients with RUS who also present with hematological abnormalities ranging from thrombocytopenia to myelodysplastic syndrome (MDS). Here we report on a series of seven families with RUS and diverse hematological defects ranging from single cytopenias to global bone marrow failure (BMF); some individuals had severe BMF in childhood whilst others only a modest single cytopenia well into adulthood. We identify three different germline variants (two novel) in the MDS1 and EVI1 complex locus (MECOM) in five of the families. The other two families remain uncharacterized. We have further expanded the range of genotypes and phenotypes associated with RUS and hematological disease.

RUS can occur with other abnormalities in the skeleton, heart, urinary tract, as well as aneuploid syndromes[1]. RUS also occurs as part of the inherited BMF spectrum of diseases and is known as radioulnar synostosis with amegakaryocytic thrombocytopenia (RUSAT). It is usually characterized by thrombocytopenia which progresses to pancytopenia coupled with a congenital fusion of the radius and ulna. Heterozygous germline variants in two genes have been associated with RUSAT: *HOXA11* (Homeobox A11)[2] (RUSAT1, MIM#605432) and *MECOM* (MDS1 and EVI1 complex locus)[3] (RUSAT2, MIM#616738). HOXA11 is involved in upper limb development in early embryogenesis as well as normal hematopoiesis and leukemogensis. MECOM is essential for the proliferation of hematopoietic stem cells and is expressed in developing limbs[4].

We identified a cohort of nine cases from seven families with RUS and variable hematological disease. The clinical characteristics of these patients (including one we have previously described[5]) are detailed in Table 1. Radiographs of the radius and ulna fusions from families 4-6 (Figure 1), show all cases have a very similar radiological appearance. Using Sanger sequencing, we screened the coding exons of *HOXA11* and *MECOM* in the index cases of these families. No coding variants were identified in *HOXA11*. However we did identify coding variants in *MECOM* (NM_001105078) in seven individuals from five families. Families 1-3 shared the same variant (c.2248C>T; p.Arg750Trp: Figure 2A) as reported by Niihori et al[3]. Novel variants were identified in families 4 and 5. These were c.2278G>C; p.Pro760Ala and c.2272G>A; p.Glu758Lys, respectively (Figure 2B). Based on genetic studies and clinical presentation an autosomal dominant inheritance pattern was

observed in families 1 and 5. From the information available it appears that the variants in families 2-4 were *de novo* which is in agreement with the initial report.[3] After direct Sanger sequencing families 6 and 7 (Figure 2C) remain uncharacterized despite having a similar presentation, suggesting further genes may be involved in this disorder. There are three reports in the literature[5-7] of patients presenting with pancytopenia and RUS with no indication of the underlying genetic cause being given, as well as a more unusual case of RUS associated B-cell acute lymphoblastic leukaemia[8] where the BCR-ABL gene fusion is unlikely to explain the RUS (Supplementary Table 1). It is unlikely that a large germline *MECOM* deletion has been missed in families 6 and 7 as reports describe two cases where deletions encompassing some or all of *MECOM* result in thrombocytopenia but not the associated RUS[9, 10]. Further studies are needed in these two families to determine the underlying basis of the disease.

Reviewing the literature, the first disease gene to be associated with both RUS and bone marrow failure was *HOXA11*. The heterozygous variant c.872delA, p.Asn291ThrfsX3 was identified in six individuals from two families (Supplementary Table 1)[2] and causes a premature truncation of HOXA11. In both families the variant was inherited from the father. Interestingly both fathers showed skeletal abnormalities of the arm but neither had any hematological disease. All the affected children presented with thrombocytopenia from birth, with three out of the four undergoing BMT. Recently several papers have been published identifying germline variants in *MECOM* in patients with various bone marrow failures either with or without the presence of RUS (Supplementary Tables 1 and 2).[2, 3, 11-13] From these reports, together with findings of this study we are able to demonstrate that even with the same variant the age of onset and the severity of BMF is highly variable. We observe that the MECOM variant p.Arg750Trp is a recurrent change that can present with a variety of hematological defects in association with RUS. In five out of the six families with this variant (families 2 and 3 in this study, and cases described in references 3, 10, 12) the disease appears *de novo,* with presentation very early in infancy/childhood and all cases required a BMT. The sixth case with p.Arg750Trp (index case family 1) shows dominant inheritance pattern and the hematological involvement progressed from aplastic anemia to myelodysplastic syndrome (MDS); this presentation of RUS and development of MDS in adulthood is similar to the family reported by Ripperger et al[12] even though the causative variant is different. Autosomal dominant inheritance was also seen in a second family in our cohort (family 5). The hematological abnormality in the affected cases from family 5 was variable: ranging from normal blood count, mild single cytopenia to severe pancytopenia, again demonstrating variability in severity and age of onset. Interestingly, there are reports of

seven patients with germline heterozygous variants (including two deletions) affecting *MECOM* where there is no presence of RUS but the severe associated hematological disease required treatment with BMT.[9-11] These patients form a distinct group as they were sporadic, *de novo* cases who presented with disease in infancy. The reason behind this difference in phenotype is unclear at present.

All the heterozygous *MECOM* variants reported in this study are highly conserved from humans to yeast (Figure 2D), cluster within 10 amino acids (aa750-760) and impact on either the highly conserved Cys2His2 zinc finger motif (zinc finger 8, aa733-755) or the adjacent linker motif (aa756-760). Preliminary data suggest levels of MECOM appear to be reduced in lymphoblastoid cell lines heterozygous for p.Glu758Lys (Supplementary Figure 1). Cys2His2 zinc fingers are one of the most common DNA-binding motifs found in eukaryotic transcription factors and usually occur in groups allowing for multiple tandem contacts along the DNA. EVI1 has 2 zinc finger domains; proximal domain contains 7 motifs and the distal contains 3 motifs (Figure 2E) and it has been shown that these 2 domains can have different functions.[14] Studies removing the whole of the 8th zinc finger domain have shown that this can block granulopoiesis confirming this region is involved in hematopoiesis. All germline variants identified to date in MECOM are shown in Figure 2E. It is noteworthy that all variants associated with the co-presentation of RUS and hematological disease cluster in region spanning zinc fingers 8 and 9. The variants observed in patients with hematological disease without RUS (verified by x-ray)[11] are more widely distributed throughout the complex, including two deletions that either remove the MDS1 part of the complex or the entire gene region.[9, 10] Further reports may help to clarify whether there is a definitive genotype-phenotype correlation for disease associated variants in MECOM.

In this study we have genetically characterized patients from five out of seven families with RUS and hematological disease. As well as identifying novel pathogenic *MECOM* variants we show that three of the families share the same previously identified *MECOM* variant. The differences in presentation have enabled us to expand the clinical phenotype from a severe global bone marrow failure requiring transplantation that presents very early in infancy to a syndrome that presents with variable hematological disease in adults. The disease can also be inherited in families in a dominant manner and in these cases the hematological involvement is more variable both in terms of severity and age of presentation. It is also notable that the hematological features can be very variable, even amongst affected members of the same family as exemplified by families 1 and 5. Lack of variants in *MECOM*

and *HOXA11* in two of the families, together with uncharacterized families in the literature, suggest there may be other disease genes to be identified. Also in light of the number of BMF cases where *MECOM* variants can occur independently of the development of RUS, a genetic screen of *MECOM* should be undertaken in all new patients with BMF, particularly if there is no family history of disease. Finally, it has become clear that RUS associated hematological abnormalities are frequently more global and variable, rather than being limited to thrombocytopenia. The description RUS associated hematological disease (RUSHD) is therefore perhaps more appropriate than RUS associated amegakaryocytic thrombocytopenia (RUSAT) which was initially coined for the disease features observed in patients with germline *HOXA11* or *MECOM* variants.

Acknowledgements

We would like to thank all clinicians, specifically Drs Baleydier, Ball and Myint, and patients involved in these studies for making this work possible. We would also like to thank the staff at Barts and The London Genome Centre for Sanger sequencing analysis. Financial support is provided by The Medical Research Council, Children with Cancer and Bloodwise.

References

1. Rizzo R, Pavone V, Corsello G, Sorge G, Neri G, Opitz JM. Autosomal dominant and sporadic radio-ulnar synostosis. Am J Med Genet. 1997;68(2):127-134.
2. Thompson AA, Nguyen LT. Amegakaryocytic thrombocytopenia and radio-ulnar synostosis are associated with HOXA11 mutation. Nat Genet. 2000;26(4):397-398.
3. Niihori T, Ouchi-Uchiyama M, Sasahara Y, et al. Mutations in MECOM, Encoding Oncoprotein EVI1, Cause Radioulnar Synostosis with Amegakaryocytic Thrombocytopenia. Am J Hum Genet. 2015;97(6):848-854.
4. Perkins AS, Mercer JA, Jenkins NA, Copeland NG. Patterns of Evi-1 expression in embryonic and adult tissues suggest that Evi-1 plays an important regulatory role in mouse development. Development. 1991;111(2):479-487.
5. Dokal I, Ganly P, Riebero I, et al. Late onset bone marrow failure associated with proximal fusion of radius and ulna: a new syndrome. Br J Haematol. 1989;71(2):277-280.
6. Sola MC, Slayton WB, Rimsza LM, et al. A neonate with severe thrombocytopenia and radio-ulnar synostosis. J Perinatol. 2004;24(8):528-530.
7. Castillo-Caro P, Dhanraj S, Haut P, Robertson K, Dror Y, Sharathkumar AA. Proximal radio-ulnar synostosis with bone marrow failure syndrome in an infant without a HOXA11 mutation. J Pediatr Hematol Oncol. 2010;32(6):479-485.
8. Qari RM, Aljaouni SK. Congenital bilateral radioulnar synostosis with acute lymphoblastic leukemia: A case report. J Appl Hematol. 2017;8(1):36-38.
9. Nielsen M, Vermont CL, Aten E, et al. Deletion of the 3q26 region including the EVI1 and MDS1 genes in a neonate with congenital thrombocytopenia and subsequent aplastic anaemia. J Med Genet. 2012;49(9):598-600.
10. Bouman A, Knegt L, Groschel S, et al. Congenital thrombocytopenia in a neonate with an interstitial microdeletion of 3q26.2q26.31. Am J Med Genet A. 2016;170A(2):504-509.
11. Bluteau O, Sebert M, Leblanc T, et al. A landscape of germ line mutations in a cohort of inherited bone marrow failure patients. Blood. 2018;131(7):717-732.
12. Ripperger T, Hofmann W, Koch JC, et al. MDS1 and EVI1 complex locus (MECOM): a novel candidate gene for hereditary hematological malignancies. Haematologica. 2018;103(2):e55-e58.
13. Lord SV, Jimenez JE, Kroeger ZA, et al. A MECOM variant in an African American child with radioulnar synostosis and thrombocytopenia. Clin Dysmorphol. 2018;27(1):9-11.
14. Senyuk V, Li D, Zakharov A, Mikhail FM, Nucifora G. The distal zinc finger domain of AML1/MDS1/EVI1 is an oligomerization domain involved in induction of hematopoietic differentiation defects in primary cells in vitro. Cancer Res. 2005;65(17):7603-7611.

Table 1: Characteristics of cases in this study

FAMILY	1	2	3	4	5[5]	5[5]	5	6	7
Patient	Index case	Index case	Index case	Index case	IV-1 (Index case)	IV-3	V-1	Index case	Index case
Age at diagnosis	Childhood	NA	16 months	6 months	11 years	13 years	7 years	Birth	3 years
Nationality	NA	British	Kosovan	Argentinian	British	British	British	Portuguese	British
Variant	c.2248C>T p.Arg750Trp	c.2248C>T p.Arg750Trp	c.2248C>T p.Arg750Trp	c.2278G>C p.Pro760Ala	c.2272G>A p.Glu758Lys	c.2272G>A p.Glu758Lys	c.2272G>A p.Glu758Lys	None (MECOM HOXA11)	None (MECOM HOXA11)
PROVEAN score†	-4.299 deleterious	-4.299 deleterious	-4.299 deleterious	-6.948 deleterious	-3.457 deleterious	-3.457 deleterious	-3.457 deleterious		
RUS	Blt	Blt	Blt	Blt	Blt	Blt	Blt	Blt, Short radii,	Blt
Family history	Yes	No	No	No	Yes	Yes	Yes	No	No
Peripheral blood	Haemolytic anemia and MDS*	AA	Pancytopenia	Severe Pancytopenia	Normal	Thrombo-cytopenia	Normal	Pancytopenia	AA
Bone marrow	Hypercellular, erythroid dysplasia		↓ cellularity and mega-karyocytes	Hypocellular				Hypocellular	Hypocellular
Transfusion dependent	Yes		Yes		No	No		Yes	
HSC transplant	Under Consideration	Yes		Yes	No	No	No		Under Consideration
Chromosome breakage test	Normal		Normal	Normal	Normal	Normal		Normal	Normal
Hand abnormality	Blt, short 5th finger, nail ridging	Nail dysplasia			Mild nail abnormality				
Facial abnormality			Abnormal facies, ear abnormalities	Small head					
Other	Splenectomy		Tetralogy of Fallot	Clubfoot	Late onset hearing loss	Moya Moya disease		Reticular hyper-pigmentation, Premature	Premature, short stature, Immunodeficiency

NA – not available; Blt – bilateral; MDS- myelodysplastic syndrome; * - this patient had aplastic anemia in childhood which resolved, then at age 37 years he presented with trilineage MDS (subtype: refractory cytopenia); AA-aplastic anemia; †PROVEAN (Protein Variation Effect Analyzer) is a software tool which predicts whether an amino acid substitution or indel has an impact on the biological function of a protein. A score of -2.5 or less is predicted to be deleterious.

Haematologica HAEMATOL/2017/183855 Version 3

Legends

Figure 1: **X-rays of the forearms showing proximal fusion of the radius and ulna**

A -Radiographs of both arms from the index case of family 4. **B** - Affected mother of family 5 (generation III). **C** - Index case of family 6 in which neither *HOXA11* nor *MECOM* variants were detected. Arrows highlight proximal fusion of the radius and ulna.

Figure 2: **Family trees of all cases and *MECOM* variants identified in this study**

A - Families 1-3 share the same heterozygous variant in *MECOM.* **B** - Family trees and sequencing traces for families 4 and 5. **C** - Families 6 and 7 do not have variants in either *MECOM* or *HOXA11*. Unless indicated by a genotype, a DNA sample was unavailable for sequencing. Representative sequence traces of both the wild type and the variant are shown. RUS – radioulnar synostosis; AA –aplastic anemia; MDS – myelodysplasia; BMF – bone marrow failure; M/T – macrocytosis and thrombocytopenia; *RUS** - radioulnar synostosis is presumed from the clinical description; NAD – no abnormality detected; arrow indicates the index case. **D** - Protein sequence from different species showing the conservation of the variants identified in this study (red arrows). The underlined residues highlight part of zinc fingers 8 and 9. *H.sapiens* (human) NP_001098548.2, *M.musculus* (mouse) XP_011247963.1, *D.rerio* (zebra fish) XP_017206701.1, *X.laevis* (African clawed frog) NP_001089139.1, *D.melanogaster* (fruit fly) NP_001260545.1, *S.cervisiae* (yeast) KZV08884.1. **E** - Schematic representation of MECOM encompassing both the MDS1 and the EVI1 components of the complex. All germline variants identified to date are mapped on to this diagram. Red arrows/text - variants identified in patients with RUS and hematological defects. Blue arrows/text – variants in patients with hematological defects but no RUS. (6) – total number of different families reported for this variant. Protein numbering is relative to the EVI1 component of the complex only (NP_001098548.2). NLS – Nuclear localisation signal CtBP – C-terminal binding protein domain.

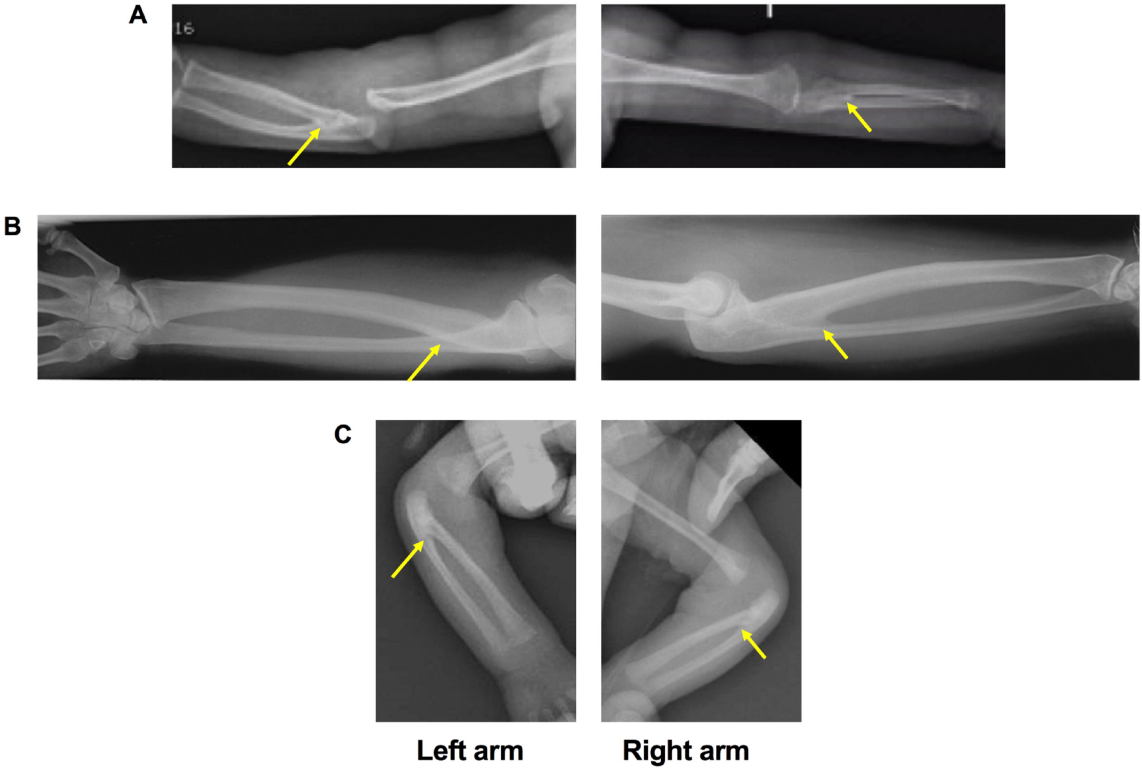
A
16
B
C
Left arm
Right arm

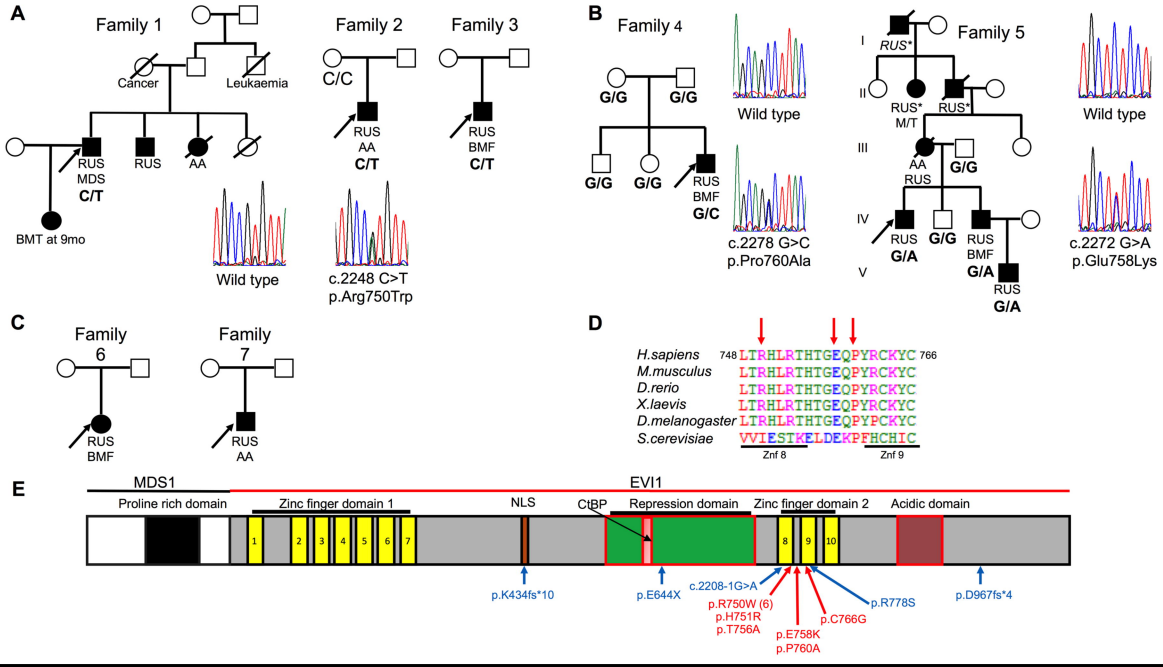
A
Family 1
Cancer
Leukaemia
RUS
MDS
C/T
RUS
AA
BMT at 9mo
Wild type
Family 2
C/C
RUS
AA
C/T
c.2248 C>T
p.Arg750Trp
Family 3
RUS
BMF
C/T
B
Family 4
G/G
G/G
G/G
G/G
RUS
BMF
G/C
Wild type
c.2278 G>C
p.Pro760Ala
Family 5
I
RUS*
II
RUS*
M/T
RUS*
III
AA
RUS
G/G
IV
RUS
G/A
G/G
RUS
BMF
G/A
V
RUS
G/A
Wild type
c.2272 G>A
p.Glu758Lys
C
Family
6
RUS
BMF
Family
7
RUS
AA
D
H.sapiens 748 LTRHLRTHTGEQPYRCKYC 766
M.musculus LTRHLRTHTGEQPYRCKYC
D.rerio LTRHLRTHTGEQPYRCKYC
X.laevis LTRHLRTHTGEQPYRCKYC
D.melanogaster LTRHLRTHTGEQPYPCKYC
S.cerevisiae VVIESTKELDEKPFHCHIC
Znf 8
Znf 9
E
MDS1
EVI1
Proline rich domain
Zinc finger domain 1
NLS
CtBP
Repression domain
Zinc finger domain 2
Acidic domain
1
2
3
4
5
6
7
8
9
10
p.K434fs*10
p.E644X
c.2208-1G>A
p.R750W (6)
p.H751R
p.T756A
p.E758K
p.P760A
p.C766G
p.R778S
p.D967fs*4