



THE UNIVERSITY *of* EDINBURGH

Edinburgh Research Explorer

Limb sparing achieved by ray amputation for osteosarcoma of the left third metacarpal bone in a Labrador

Citation for published version:

Hall, J & Mason, SL 2019, 'Limb sparing achieved by ray amputation for osteosarcoma of the left third metacarpal bone in a Labrador' *Veterinary Record Case Reports*. DOI: 10.1136/vetreccr-2018-000752

Digital Object Identifier (DOI):

[10.1136/vetreccr-2018-000752](https://doi.org/10.1136/vetreccr-2018-000752)

Link:

[Link to publication record in Edinburgh Research Explorer](#)

Document Version:

Peer reviewed version

Published In:

Veterinary Record Case Reports

General rights

Copyright for the publications made accessible via the Edinburgh Research Explorer is retained by the author(s) and / or other copyright owners and it is a condition of accessing these publications that users recognise and abide by the legal requirements associated with these rights.

Take down policy

The University of Edinburgh has made every reasonable effort to ensure that Edinburgh Research Explorer content complies with UK legislation. If you believe that the public display of this file breaches copyright please contact openaccess@ed.ac.uk providing details, and we will remove access to the work immediately and investigate your claim.



VetRecord CaseReports

Limb sparing achieved by ray amputation for osteosarcoma of the left third metacarpal bone in a Labrador

Journal:	<i>Veterinary Record Case Reports</i>
Manuscript ID	Draft
Manuscript Type:	Companion or pet animals
Species:	Dogs
Date Submitted by the Author:	n/a
Complete List of Authors:	Hall, Jon; University of Edinburgh Royal Dick School of Veterinary Studies, Veterinary medicine Mason, Sarah; Southfields Veterinary Specialists, Oncology
Keywords:	Neoplasia, Dog, Osteosarcoma, Limb sparing, Metacarpal, Chemotherapy
Topics:	Foot conditions, Lameness, Oncology, Surgery
Abstract:	A seven year old male neutered Labrador weighing 35kg with a two week history of left forelimb lameness was diagnosed with osteosarcoma of the third metacarpal bone. No pulmonary metastases were detected and ray amputation (removal of the left third metacarpal bone and 3rd phalanx en-bloc) was performed. Circumferential sutures were placed around metacarpals 2 and 4 to realign the adjacent bones and digits during the healing period. The dog received 6 cycles of single agent carboplatin (300mg/m ²) postoperatively. Restaging 9 months postoperatively revealed no evidence of metastasis or recurrence. Two years postoperatively, the dog has no evidence of complications or lameness. Thoracic limb amputation and postoperative adjunctive therapy are considered the gold standard treatment for appendicular osteosarcoma; however, an oncological compartment excision of the this bone tumour was performed with similar outcome for the patient whilst preserving the limb.

1
2
3
4
5
6
7
8
9
10
11
12
13
14
15
16
17
18
19
20
21
22
23
24
25
26
27
28
29
30
31
32
33
34
35
36
37
38
39
40
41
42
43
44
45
46
47
48
49
50
51
52
53
54
55
56
57
58
59
60

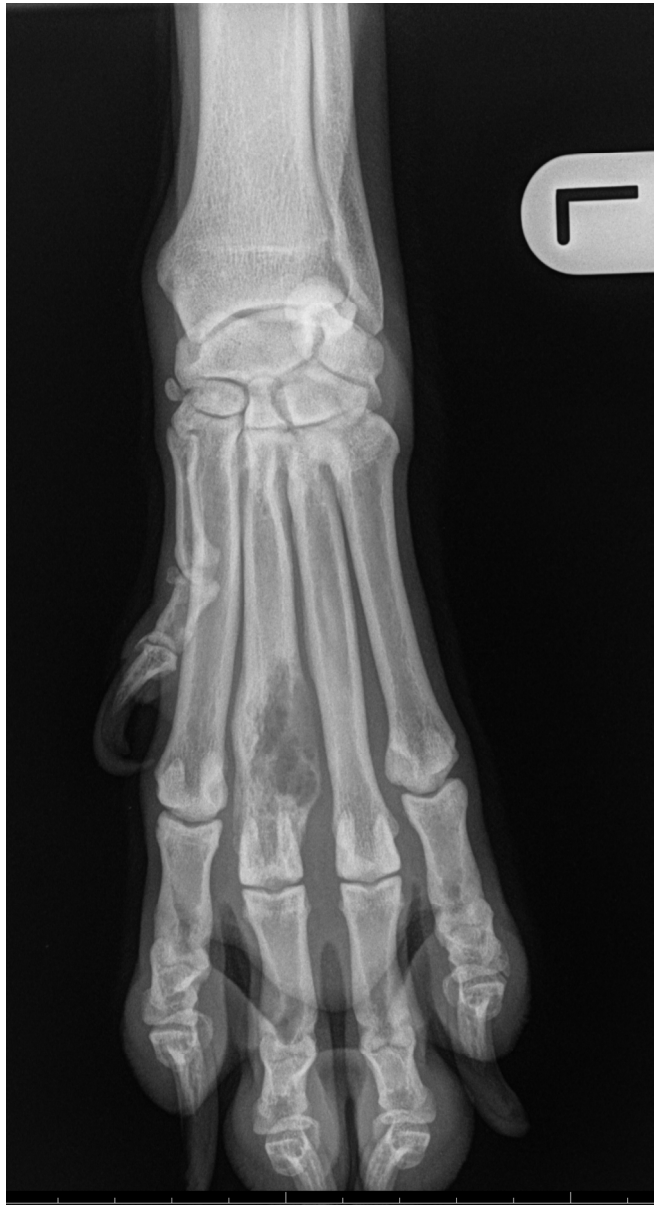

Figure 1. A dorsopalmar radiograph of the left carpus and manus showing severe osteolysis of the distal third of metacarpal III.

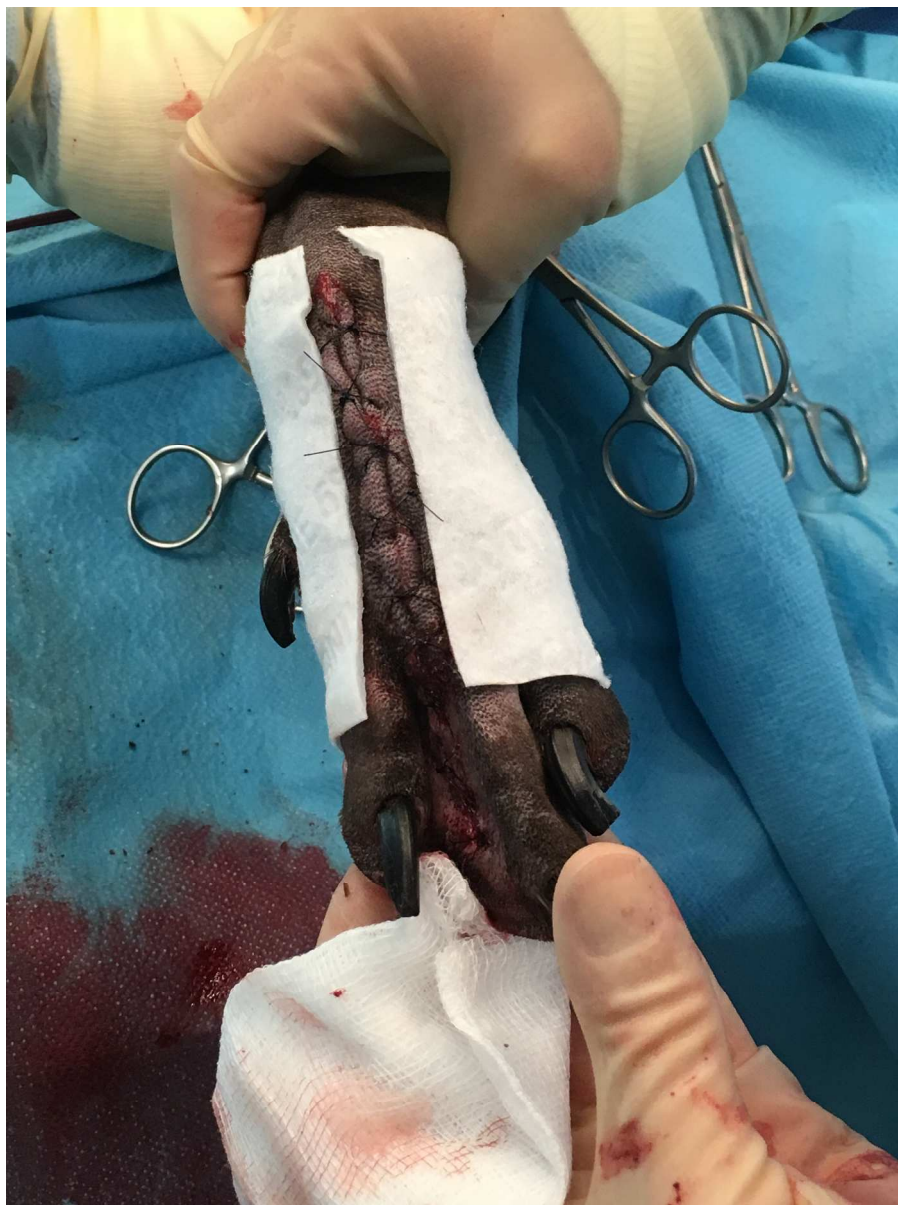

Figure 2 a-e. The appearance of the incision immediately postoperatively (3a), five days postoperatively (3b), eight weeks (3c), sixteen weeks (3d) and nineteen weeks (3e) postoperatively

1066x1422mm (72 x 72 DPI)

1
2
3
4
5
6
7
8
9
10
11
12
13
14
15
16
17
18
19
20
21
22
23
24
25
26
27
28
29
30
31
32
33
34
35
36
37
38
39
40
41
42
43
44
45
46
47
48
49
50
51
52
53
54
55
56
57
58
59
60

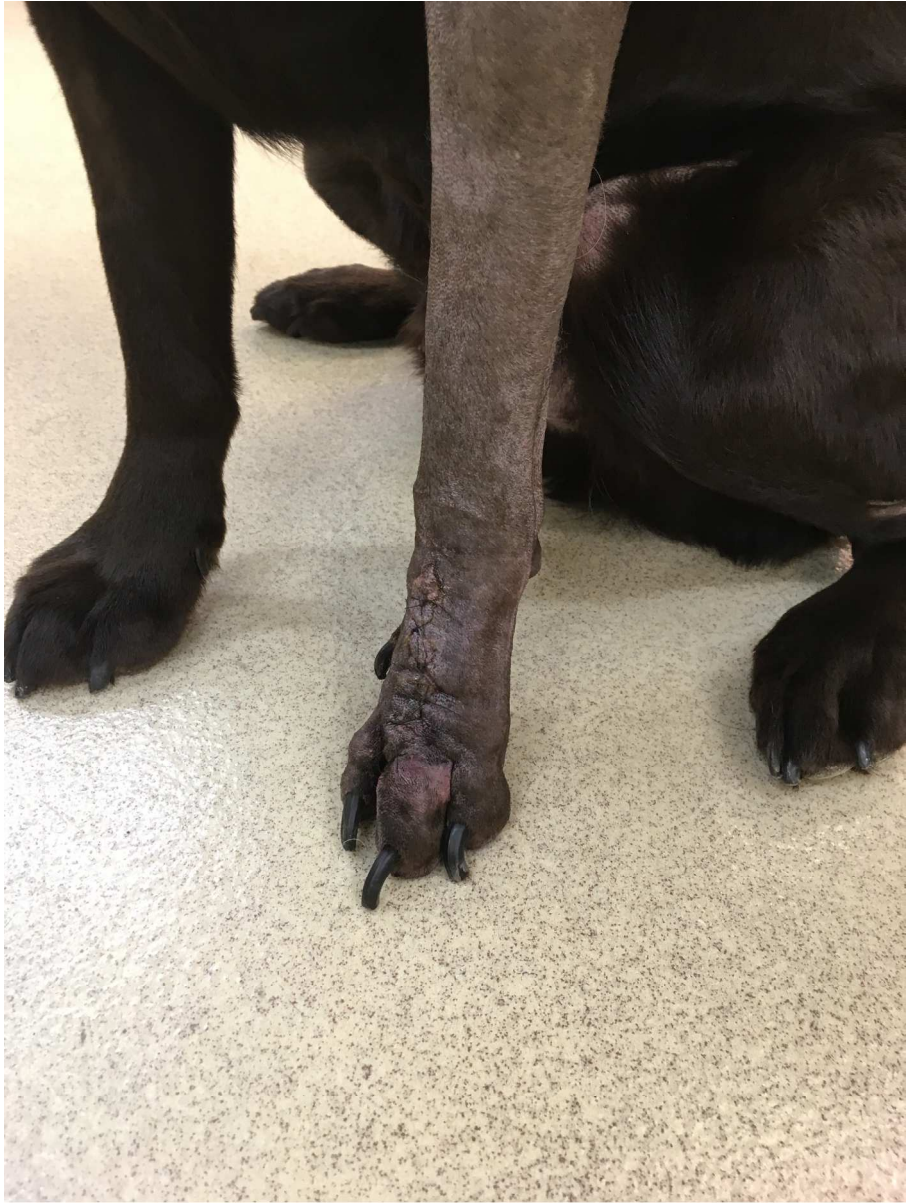

Figure 2 a-e. The appearance of the incision immediately postoperatively (3a), five days postoperatively (3b), eight weeks (3c), sixteen weeks (3d) and nineteen weeks (3e) postoperatively

1066x1422mm (72 x 72 DPI)

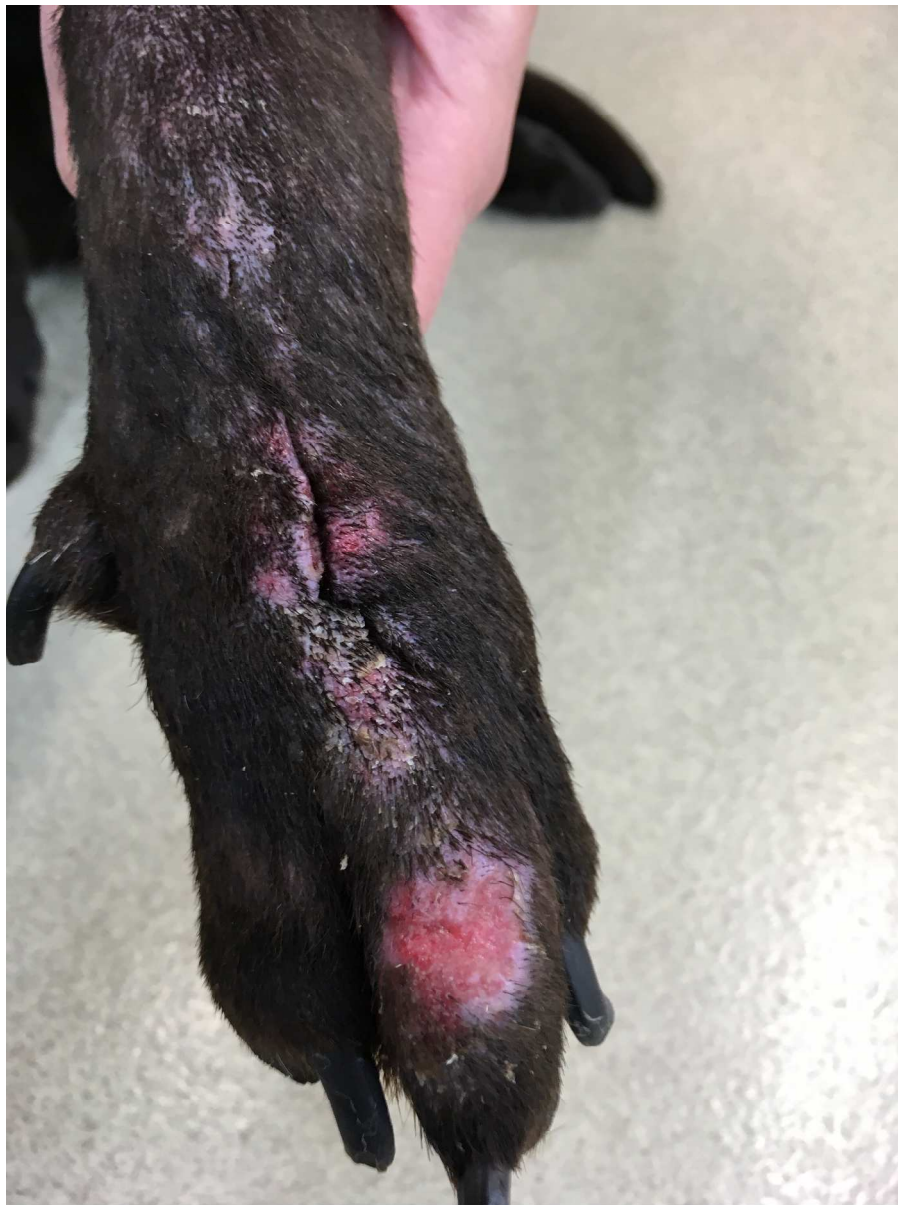

Figure 2 a-e. The appearance of the incision immediately postoperatively (3a), five days postoperatively (3b), eight weeks (3c), sixteen weeks (3d) and nineteen weeks (3e) postoperatively

1066x1422mm (72 x 72 DPI)

1
2
3
4
5
6
7
8
9
10
11
12
13
14
15
16
17
18
19
20
21
22
23
24
25
26
27
28
29
30
31
32
33
34
35
36
37
38
39
40
41
42
43
44
45
46
47
48
49
50
51
52
53
54
55
56
57
58
59
60

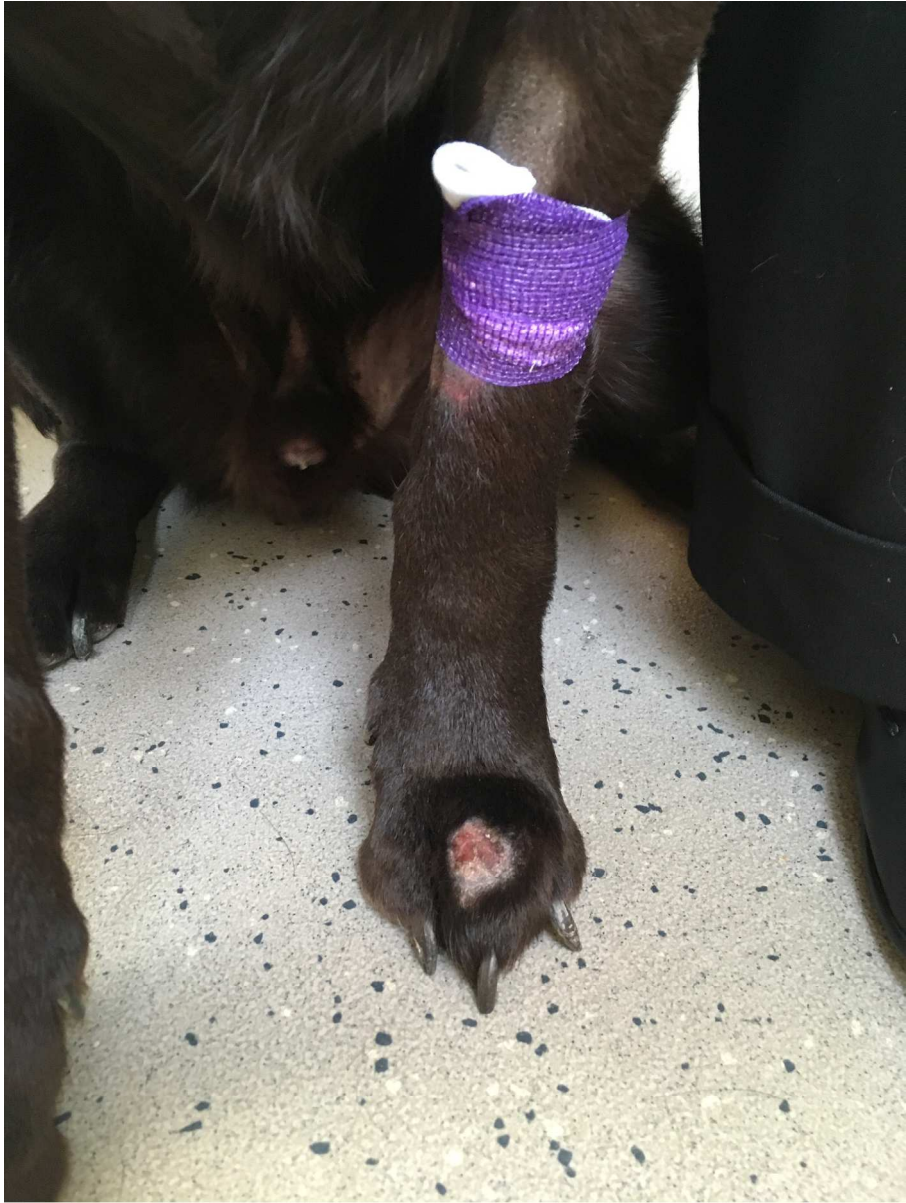

Figure 2 a-e. The appearance of the incision immediately postoperatively (3a), five days postoperatively (3b), eight weeks (3c), sixteen weeks (3d) and nineteen weeks (3e) postoperatively

1066x1422mm (72 x 72 DPI)

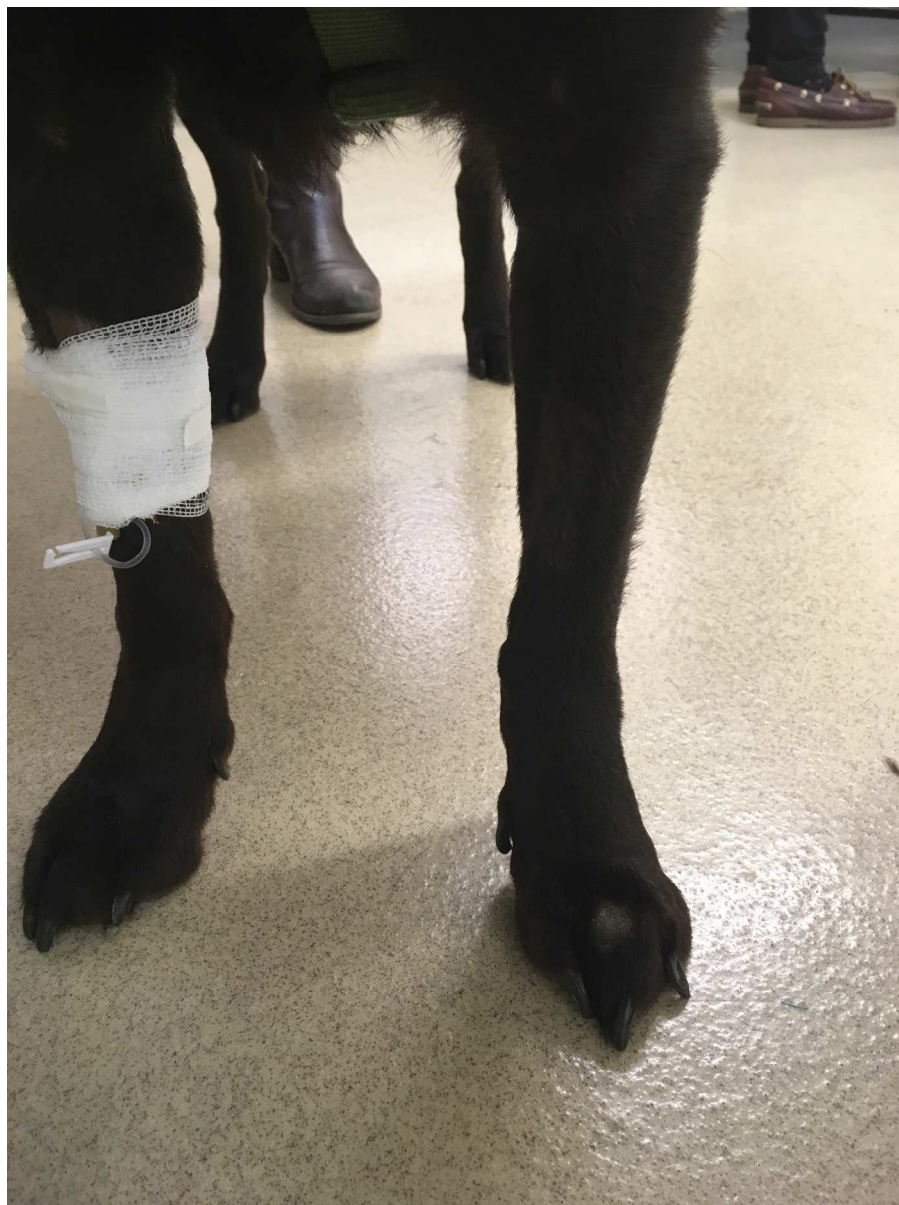

Figure 2 a-e. The appearance of the incision immediately postoperatively (3a), five days postoperatively (3b), eight weeks (3c), sixteen weeks (3d) and nineteen weeks (3e) postoperatively

1066x1422mm (72 x 72 DPI)

1
2
3
4
5
6
7
8
9
10
11
12
13
14
15
16
17
18
19
20
21
22
23
24
25
26
27
28
29
30
31
32
33
34
35
36
37
38
39
40
41
42
43
44
45
46
47
48
49
50
51
52
53
54
55
56
57
58
59
60

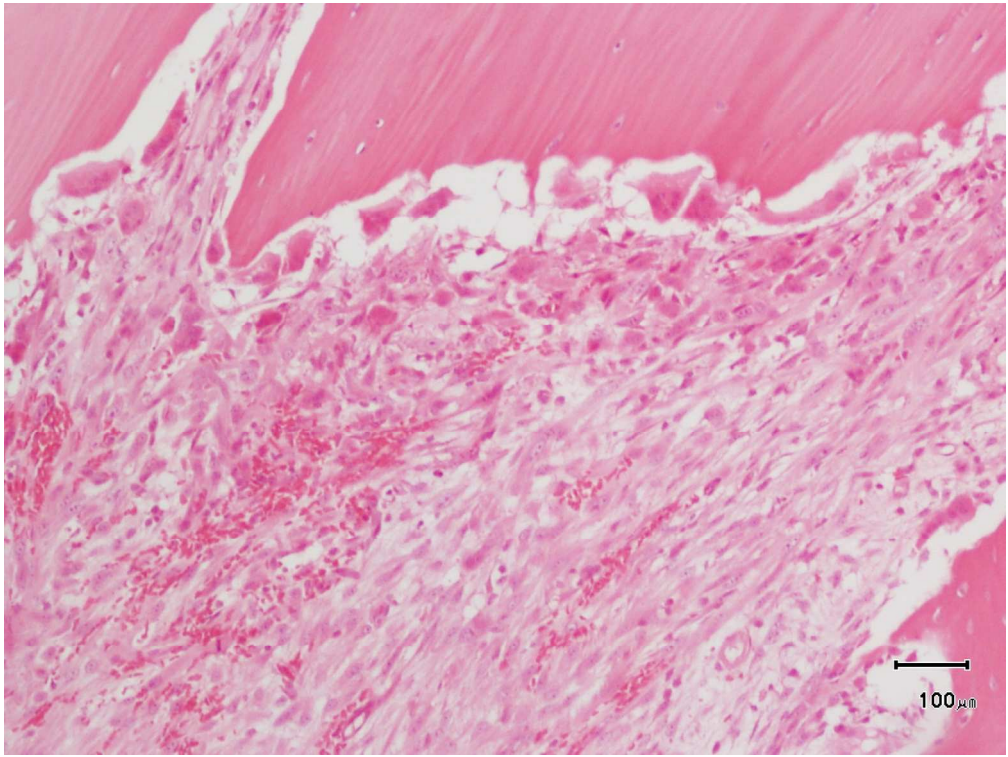


Figure 3. Histology of the mass consistent with osteosarcoma.

564x423mm (72 x 72 DPI)

1
2
3
4
5
6
7
8
9
10
11
12
13
14
15
16
17
18
19
20
21
22
23
24
25
26
27
28
29
30
31
32
33
34
35
36
37
38
39
40
41
42
43
44
45
46
47
48
49
50
51
52
53
54
55
56
57
58
59
60

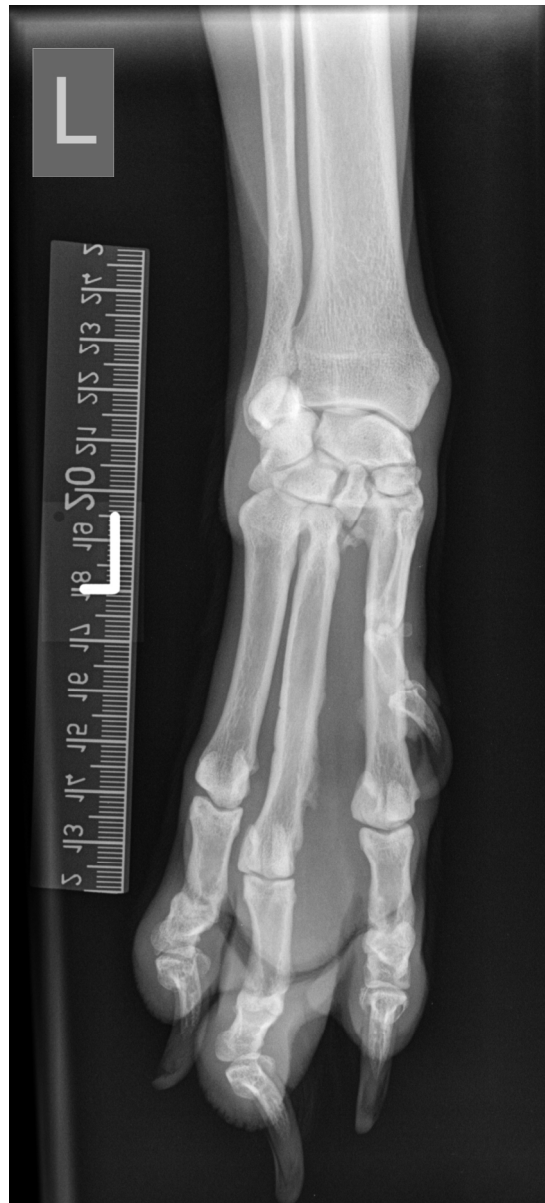

Figure 4. A dorsopalmar radiograph of the left manus taken 3.5 months postoperatively.

Veterinary Record casereports

Submission template for full cases

All case reports MUST be submitted online using this Word template. Please refer to the [Hints and Tips template](#) so you know what to include in each section

- o <http://mc.manuscriptcentral.com/vetreccr>
- o You will be asked for more detailed information on submission where you can also upload images, multimedia files, etc
- o Further details are available in the [Instructions for authors](#)

For studies using client-owned animals the article must demonstrate a high standard (best practice) of veterinary care and have informed client consent

You, your practice or institution must be a subscriber to Veterinary Record Case Reports in order to submit. Subscribers can submit as many cases as they like, access all the published material, and re-use any published material for personal use and teaching without further permission.

- o For more information on rates and how to purchase your subscription visit <http://vetrecordcasereports.bmj.com/site/about/Subslanding.xhtml>
- o Contact your librarian, head of department or practice owner to see if your institution already has a subscription

<p>TITLE OF CASE <i>Do not include "a case report"</i></p> <p>Limb sparing achieved by ray amputation for osteosarcoma of the left third metacarpal bone in a Labrador</p>
<p>SUMMARY <i>140 /150 words</i></p> <p>A seven year old male neutered Labrador weighing 35kg with a two week history of left forelimb lameness was diagnosed with osteosarcoma of the third metacarpal bone. No pulmonary metastases were detected and ray amputation (removal of the left third metacarpal bone and 3rd phalanx en-bloc) was performed. Circumferential sutures were placed around metacarpals 2 and 4 to realign the adjacent bones and digits during the healing period. The dog received 6 cycles of single agent carboplatin (300mg/m²) postoperatively. Restaging 9 months postoperatively revealed no evidence of metastasis or recurrence. Two years postoperatively, the dog has no evidence of complications or lameness. Thoracic limb amputation and postoperative adjunctive therapy are considered the gold standard treatment for appendicular osteosarcoma; however, an oncological compartment excision of the this bone tumour was performed with similar outcome for the patient whilst preserving the limb.</p>

BACKGROUND *Why you think this case is important – why did you write it up?*

Osteosarcoma (OSA) accounts for 85% of canine skeletal tumours and is the most common primary bone tumour in dogs¹⁻³. It usually affects the appendicular skeleton, although it can occur in the axial skeleton^{1,4}. Osteosarcoma of the digit is rare in dogs, accounting for only 1.3-3% of bone tumours in two large studies⁵⁻⁶ and only 13 cases of OSA distal to the antebrachiocarpal (n=5) and tarsocrural joints are reported to date (n=8)^{1,3,7}. Metacarpal OSA is also uncommon in people and to date very few cases have been described⁸⁻¹⁰.

OSA is a highly metastatic tumour and it is assumed that most dogs with appendicular OSA have micrometastasis at the time of initial presentation¹¹, with median survival times in the region of 4-6 months with amputation alone and 9-11 months with adjunctive chemotherapy for appendicular OSA of the long bones¹²⁻¹⁴. Several chemotherapeutic regimens have been reported in the adjunctive therapy of canine appendicular osteosarcoma including doxorubicin combined with platinum agents¹⁴⁻¹⁷, single agent cisplatin or carboplatin¹⁸⁻¹⁹ and carboplatin combined with gemcitabine²⁰, all resulting in similar median survival times in the region of 300 days. In the previous report of metacarpal, metatarsal and digit OSA, median survival was 466 days in dogs treated with surgery and adjunctive chemotherapy, with death occurring due to metastatic disease in most cases⁷.

This report describes limb salvage surgery to remove an osteosarcoma confined to the 3rd metacarpal bone followed by adjunctive chemotherapy. Full use of the limb was maintained with good long term control of the disease, avoiding the necessity of amputation or complex prosthetic devices.

CASE PRESENTATION *Presenting features, clinical and environmental history***History**

A seven year old male neutered Labrador weighing 35kg in body condition score 6/9 presented with a two week history of left forelimb lameness minimally-responsive to carprofen (2mg/kg bid po).

Clinical Examination

A diffuse, firm mass measuring 2.5cm diameter was palpable on the dorsal aspect of the left second and third metacarpal bones. The mass was uncomfortable on direct firm palpation. The dog showed marked left thoracic limb lameness (6/10) when walking. Full clinical, orthopaedic and neurological examinations were otherwise unremarkable and the lameness was attributed most likely to the mass.

INVESTIGATIONS *If relevant*

A single dorsopalmar radiograph of the manus and carpus revealed severe osteolysis of metacarpal three (Figure 1). Dorsoventral, left and right lateral thoracic radiographs revealed no evidence of pulmonary metastasis. Fine needle aspirates were taken from the lesion. Cytological samples were of low cellularity, but suspicious for sarcoma. Haematology and biochemistry were performed to assess for any prognostic markers associated with OSA and to exclude underlying sub-clinical disease and the results were unremarkable.

DIFFERENTIAL DIAGNOSIS *If relevant*

TREATMENT *If relevant*

The patient was prescribed carprofen (2mg/kg bid po) and paracetamol codeine (10mg/kg bid po) for seven days preceding surgery. On repeat presentation, he had a 4/10 left thoracic limb lameness and was uncomfortable on direct palpation of the left third metacarpal bone.

The dog received medetomidine (0.002mg/kg) and methadone (0.02mg/kg) for premedication and anaesthesia was induced with propofol and maintained with isoflourane. Post-operative analgesia was provided with methadone q4 hours (for 24 hours) then tramadol 2.8 mg/kg po q12 hours for 7 days alongside carporfen 2.8mg/kg q24 hours for 8 weeks. Amoxicillin clavulanate was administered at 20mg/kg iv at induction and 90 minutes later, followed by 12.5mg/kg po bid for 8 days post-operatively.

A tourniquet was placed to minimise intraoperative haemorrhage and preserve intraoperative visibility. A proximo-distal skin incision was made on the cranial surface of the carpus directly dorsal to the 3rd metacarpal. Distally, the incision bifurcated to pass either side of the 3rd digit, dividing the interdigital webbing either side of the toe. The incisions met between the digital pad of the 3rd digit and the metacarpal pad. The insertions of the lateral digital extensor and common digital extensor tendons were transected at the level of the carpometacarpal joint. The overlying skin and the soft tissue surrounding the bone were otherwise preserved. The 3rd metacarpal bone was freed from the adjacent metacarpal bones and radiocarpal bone using a combination of sharp dissection with a no.11 scalpel blade and levering with periosteal elevators and an osteotome. The palmar surface of the bone was released from the palmar fibrocartilage and ligaments by sharp dissection whilst the proximal metacarpal bone was levered cranially. Three cerclage sutures were placed using 3.5 metric polydioxanone (PDS II; Ethicon) encircling the 2nd and 4th metacarpal bones in the proximal, middle and distal thirds respectively. The sutures were tightened to hold the bones in an approximately normal anatomical relationship to one and other rather than to appose them tightly. The incision was closed using 3 metric polyglecaprone (Monocryl; Ethicon) in a simple continuous pattern. The interdigital skin was similarly reapposed to reconstruct the webbing in an attempt to prevent separation and splaying of the digits when

weight bearing. Cruciate skin sutures were placed using 3 metric monofilament nylon (Ethilon; Ethicon).

A postoperative dressing was applied extending to just below the elbow. This was changed the day after the surgery and was removed 3 days postoperatively. The dog was discharged with a protective collar with instructions to restrict the dog to lead exercise only and avoid boisterous activity for 4-6 weeks. Figures 3a-e show the foot immediately postoperatively (2a), five days postoperatively (2b), eight weeks (2c), sixteen weeks (2d) and nineteen weeks (2e) postoperatively. One week postoperatively the dog was 4/10 lame on his left thoracic limb; by 3 weeks postoperatively he had no evidence of lameness. The dog had a replacement collar at 26 days postoperatively because he traumatised the skin on the dorsum of his carpus using the edge of the collar causing a granulomatous reaction. This was considerably improved by 6-8 weeks post-surgery (Figure 2c). Carprofen was withdrawn 8 weeks post-surgery and no lameness was evident.

Histopathology confirmed the diagnosis of osteosarcoma (fibroblastic subtype) originating from the medullary cavity. Margin assessment confirmed complete excision of the affected bone (34mm from proximal articular surface) but reported multifocal extension of neoplastic cells into the overlying periosteum (Figure 3). Postoperatively, the dog received 6 cycles of single agent carboplatin (300mg/m²) with doses given every 3-4 weeks; timings were variable due to owner availability.

OUTCOME AND FOLLOW-UP

Re-staging at 9 months post-surgery revealed no evidence of pulmonary metastasis. Repeated radiographs of the foot were performed at 3.5 months post-surgery and showed periosteal new bone on the medial aspect of MCII (Figure 4). At 24 months post-surgery the dog was normal, with no evidence of lameness or mass recurrence and normal boisterous gait. The owner declined further staging but reported excellent exercise tolerance and that the dog underwent exploratory laparotomy to remove an intestinal foreign body 14.5 months after presentation.

DISCUSSION *Include a very brief review of similar published cases*

1 This case report describes an uncommon presentation of canine appendicular OSA and a novel
2 therapeutic approach.
3
4

5 Metacarpal OSA is rare in dogs⁷ and people⁸⁻¹⁰. Less than twenty cases are reported in people
6 with death from metastatic disease reported as uncommon (~13%)⁸. Interestingly, metacarpal
7 OSA in people most commonly affects the second and third metacarpal bone⁸, similar to the
8 case in this patient.
9
10
11
12
13
14

15 Standard of care for canine appendicular OSA is amputation or limb-sparing surgery²¹⁻²⁴. For
16 conventional limb salvage, removal of the affected bone can provide compartmental excision of
17 the tumour whilst preserving the soft tissue envelope to cover orthopaedic implants and facilitate
18 normal patient function without compromising survival time. Limb salvage utilising surgical
19 implants offers comparable survival times to amputation²⁴⁻³¹ and may even extend life
20 expectancy³²⁻³⁶, although complication rates of up to 78% infection²⁴, 24% tumour recurrence²⁴
21 and up to 40% implant failure²⁷ are reported. Consequently, it was felt that in this case,
22 compartmental amputation of metacarpal III, disarticulating the bone at the carpometacarpal
23 joint, would offer similar therapeutic benefits to previous reports without increasing the risks of
24 complications using surgical implants.
25
26
27
28
29
30
31
32
33
34
35
36

37 In a case series of eleven dogs undergoing partial foot amputation (defined as removal of two
38 adjacent digits), one dog had osteosarcoma and removal of digits 4 and 5 at the
39 carpometacarpal joint and a second with extraskeletal osteosarcoma had removal of digits 2 and
40 3 through the metacarpal bones²³. Both had chronic lameness as a consequence of surgery but
41 long term local control of disease. The dog having carpometacarpal amputation (similar to the
42 surgery we performed, although we removed a single metacarpal bone and phalanx rather than
43 two) developed carpal hyperextension and as a consequence, the authors of that paper
44 recommend avoiding carpometacarpal and tarsometatarsal amputations in case of disruption to
45 palmar/plantar fibrocartilage causing subsequent instability. Our patient had an excellent
46 functional outcome and no evidence of joint instability, although we only removed a single
47
48
49
50
51
52
53
54
55
56
57
58
59
60

1 metacarpal bone and digit, and the centrally positioned metacarpal 3 does not have a collateral
2 ligament insertion. In humans, 'ray amputation' describes the removal of a digit and
3 corresponding metatarsal bone³⁷⁻³⁸ although preservation of the proximal metatarsal bone is
4 again recommended to prevent the risk of tarsal instability. We felt that this would compromise
5 our oncological resection and the maximal benefit of surgery (beyond palliative analgesia) in this
6 patient would be lost.
7
8
9
10

11
12
13 Amputation of digits 3 and 4 is often described in books to result in increased morbidity than
14 other toes but this has not been found in recent studies^{23,39}, consistent with the authors'
15 experience. We were, however, concerned about postoperative splaying of metacarpal and digits
16 4 and 5 when weight bearing which could lead to disruption of the reconstructed interdigital web
17 in the short term, or chronic discomfort and lameness in the long term. We therefore placed
18 circum-metacarpal absorbable sutures to help support the tissues for the first few months during
19 healing, the inspiration for performing this taken from a case report describing something similar
20 to induce synostosis in a patient with ectrodactyly⁴⁰. However, rather than tightly apposing
21 metacarpals 2 and 4, they were secured in a normal anatomical relationship and without drilling
22 bone tunnels. In the only previous study documenting MC excision for canine OSA no surgical
23 technique nor outcome was described and it has to be assumed that this procedure was
24 tolerated⁷.
25
26
27
28
29
30
31
32
33
34
35
36
37
38
39
40

41 Most canine patients with osteosarcoma die of metastatic disease rather than primary recurrence
42 and in this case both are considered highly unlikely at the time of writing. Long term survival in
43 this case may be related to anatomical location, as previously reported^{7,23}. For three canine
44 patients with metacarpal osteosarcoma treated with excision of metacarpal 3,4 or 5 and
45 adjunctive cisplatin chemotherapy, survival time ranged from 466-653 days with two of the three
46 dogs suspected to develop metastatic disease to lungs and bone respectively. The third dog died
47 of haemangiosarcoma with no OSA evident at necropsy⁷. In another report, a dog with OSA
48 undergoing partial foot amputation of digits 4 and 5 at the carpometacarpal joint and adjunctive
49
50
51
52
53
54
55
56
57
58
59
60

1 chemotherapy had lung metastases diagnosed at 574 days, metastatectomy at 634 days and
2 was alive at follow up 962 days postoperatively ²³. The potential good outcome and long survival
3 associated with metacarpal OSA supported the decision to perform a limb-sparing procedure in
4 this case, especially due to the breed pre-disposition for obesity and osteoarthritis
5
6
7
8

9 Prognostic factors for appendicular osteosarcoma have been reported, however some are
10 controversial ⁴¹⁻⁴². This patient had a number of positive prognostic factors associated with
11 appendicular OSA, including normal serum ALP, small tumour size, body weight <40kg and
12 fibroblastic sub-type, although the tumour did extend into soft tissues which has been associated
13 with worse prognosis ⁴¹. These prognostic factors may not be applicable in metacarpal OSA.
14
15
16
17
18
19
20

21 The patient received adjunctive chemotherapy with single agent carboplatin due to the likely
22 metastatic potential of this tumour which also may have influenced long term survival. This
23 decision was made extrapolating from our knowledge of the benefit of adjunctive chemotherapy
24 in appendicular OSA, which of course, may not necessarily be applicable in this setting,
25 especially considering the low rate of metastatic disease reported in people with metacarpal
26 OSA. This is the first report of adjunctive single agent carboplatin in the treatment of MC OSA,
27 previous cases described in the literature were treated with alternating carboplatin and
28 doxorubicin²³ or single agent cisplatin⁷ with long term survival, although three of these four cases
29 did develop confirmed or suspected metastasis. Extrapolating from appendicular OSA, single
30 agent carboplatin is considered to be as effective as either of these protocols and is currently the
31 most widely used protocol ^{14,18}.
32
33
34
35
36
37
38
39
40
41
42
43
44

45 This is the first report of a novel limb salvage technique for a rare presentation of OSA. Although
46 the impact is inherently limited by the description of a single dog, the good functional and
47 survival outcome supports the use of this technique in dogs with metacarpal OSA. This
48 technique could also be employed for other primary tumours of the metacarpal bone.
49
50
51
52
53

54 **LEARNING POINTS/TAKE HOME MESSAGES 3 to 5 bullet points – this is a required**
55 **field**
56
57
58
59
60

- Osteosarcoma of the metacarpal and metatarsal bones is a rare but important differential diagnosis of osteolysis and uncomfortable swelling in the foot
- Complete amputation of a central metacarpal bone and digit can be performed without causing carpal instability and can result in normal use of the limb.
- Compartmental excision of metacarpal osteosarcoma resulted in comparable treatment outcome as entire limb amputation but preserved the thoracic limb and avoided complications associated with prostheses.

REFERENCES *Vancouver style*

1. Brodey RS, McGrath JT, Reynolds H. A clinical and radiological study of canine bone neoplasms). J Am Vet Med Assoc. 1959;**134**:53-71
2. Brodey RS, Sauer RM, Medway W. Canine bone neoplasms. J Am Vet Med Assoc. 1963;**143**:471-495
3. Lui S-K, Dorfman SK, Hurvitz AI, Patnaik AK. J Small Anim Pract 1977;**18**:313-326
4. Heyman SJ, Diefenderfer DL, Goldschmidt MH, Newton CD. Canine Axial Skeletal Osteosarcoma A Retrospective Study of 116 Cases (1986 to 1989) Vet surg 1992;**21**:304-310
5. Marino DJ, Matthiesen, DT, Stefanacci JD, and Moroff SD. Evaluation of dogs with digit masses: 117 cases (1981-1991). J Am Vet Med Assoc. 1995;**207**:726-728
6. Wobeser BK, Kidney BA, Powers BE, Withrow SJ, Mayer MN, Spinato MT, Allen AL. Diagnoses and Clinical Outcomes Associated with Surgically Amputated Canine Digits Submitted to Multiple Veterinary Diagnostic Laboratories. Vet Pathol 2007;**44**:355–361
7. Gamblin RM, Straw RC, Powers BE, Park RD, Bunge MM. and Withrow SJ. Primary osteosarcoma distal to the antebrachiocarpal and tarsocrural joints in nine dogs (1980-1992). J

Am Anim Hosp Assoc. 1995;**31**:86-91

1
2
3
4
5
6
7
8
9
10
11
12
13
14
15
16
17
18
19
20
21
22
23
24
25
26
27
28
29
30
31
32
33
34
35
36
37
38
39
40
41
42
43
44
45
46
47
48
49
50
51
52
53
54
55
56
57
58
59
60

8. Fowble VA, Pae R, Vitale A, Bryk E, Vigorita VJ. Case Reports: osteosarcoma of the hand: one case and a literature review. Clin. Orthop. Relat. Res. 2005;**440**:255–261

9. Jones KB, Buckwalter JA, McCarthy EF. Parosteal osteosarcoma of the thumb metacarpal: a case report. Iowa Orthop J 2006;**26**:134–137

10. Muir TM, Lehman TP, Meyer WH. Periosteal osteosarcoma in the hand of a pediatric patient: a case report. Journal of hand surgery. 2008;**33**:266-268

11. Owen LN. The Differential Diagnosis of bone tumours in the dog. Vet. Rec. 1962;**74**:439-446

12. Brodey RS, Abt DA. Results of surgical treatment in 65 dogs with osteosarcoma. J. Am. Vet. Med. Assoc. 1976;**168**:1032–1035

13. Mauldin GN, Matus RE, Withrow SJ, Patnaik AK. Canine osteosarcoma. Treatment by amputation versus amputation and adjuvant chemotherapy using doxorubicin and cisplatin. J. Vet. Intern. Med. 1988;**2**:177–180

14. Selmic LE, Burton JH, Thamm DH, Withrow SJ, Lana SE. Comparison of Carboplatin and Doxorubicin-Based Chemotherapy Protocols in 470 Dogs after Amputation for Treatment of Appendicular Osteosarcoma. J Vet Intern Med 2014;**28**:554–563

15. Bailey D, Erb H, Williams L, Ruslander D, Hauck M. Carboplatin and doxorubicin combination chemotherapy for the treatment of appendicular osteosarcoma in the dog. J. Vet. Intern. Med. 2003;**17**:199–205

16. Bacon N, Ehrhart N, Dernel W, Lafferty M, Withrow S. Use of alternating administration of

- carboplatin and doxorubicin in dogs with microscopic metastases after amputation for appendicular osteosarcoma: 50 cases (1999-2006). J Am Vet Med Assoc 2008;232:1504–1510
- 1
2
3
4
5
6
7
8
9
10
11
12
13
14
15
16
17
18
19
20
21
22
23
24
25
26
27
28
29
30
31
32
33
34
35
36
37
38
39
40
41
42
43
44
45
46
47
48
49
50
51
52
53
54
55
56
57
58
59
60
- 17.** Frimberger A, Chan C, Moore A. Canine Osteosarcoma Treated by Post-Amputation Sequential Accelerated Doxorubicin and Carboplatin Chemotherapy: 38 Cases. J Am Anim Hosp Assoc 2016;**52**:149–156
- 18.** Saam DE, Liptak JM, Stalker MJ, Chun R. Predictors of outcome in dogs treated with adjuvant carboplatin for appendicular osteosarcoma: 65 cases (1996-2006). J. Am. Vet. Med. Assoc. 2011;**238**:195–206
- 19.** Skorupski KA, Uhl JM, Szivek A, Frazier DA, Rebhun BR, Rodriguez CO. Carboplatin versus alternating carboplatin and doxorubicin for the adjuvant treatment of canine appendicular osteosarcoma: a randomized, phase III trial. Vet Comp Oncol 2016;**14**:81–87
- 20.** McMahon M, Mathie T, Stingle N, Romansik E, Vail D, London C. Adjuvant Carboplatin and Gemcitabine Combination Chemotherapy Postamputation in Canine Appendicular Osteosarcoma. J Vet Intern Med 2011;**25**:511–517
- 21.** Jehn C, Lewis D, Farese J, Ferrell E, Conley W, Ehrh N. Transverse Ulnar Bone Transport Osteogenesis: A New Technique for Limb Salvage for the Treatment of Distal Radial Osteosarcoma in Dogs. Vet Surg 2007;**36**:324–334
- 22.** Boston SE, Skinner OT. Limb shortening as a strategy for limb sparing treatment of appendicular osteosarcoma of the distal radius in a dog. Vet Surg 2018;**47**:136–145
- 23.** Liptak JM, Dernel WS, Rizzo SA, Withrow SJ. Partial Foot Amputation in 11 Dogs. J Am Anim Hosp Assoc 2005;**41**:47-55

1
2
3
4
5
6
7
8
9
10
11
12
13
14
15
16
17
18
19
20
21
22
23
24
25
26
27
28
29
30
31
32
33
34
35
36
37
38
39
40
41
42
43
44
45
46
47
48
49
50
51
52
53
54
55
56
57
58
59
60

24. Mitchell KE, Boston SE, Kung M, Dry S, Straw RC, Ehrhart, NP, Ryan SD. Outcomes of Limb-Sparing Surgery Using Two Generations of Metal Endoprosthesis in 45 Dogs With Distal Radial Osteosarcoma. A Veterinary Society of Surgical Oncology Retrospective Study. *Vet Surg* 2016;**45**:36–43

25. Dernell WS, Ehrhart NP, Straw RC, Vail DM. Tumors of the skeletal system. *Withrow and MacEwen's small animal clinical oncology*. St. Louis, Mo.: Elsevier.Saunders; 2013:540-582

26. Liptak JM, Dernell W, Straw R, Jameson VJ, Lafferty MH, Rizzo SA, Withrow SJ. Intercalary bone grafts for joint and limb preservation in 17 dogs with high-grade malignant tumors of the diaphysis. *Vet Surg*. 2004;**33**:457-467

27. Liptak JM, Dernell W, Ehrhart N, Lafferty MH, Monteith GJ. Cortical allograft and endoprosthesis for limb-sparing surgery in dogs with distal radial osteosarcoma: a prospective clinical comparison of two different limb-sparing techniques. *Vet Surg*. 2006;**35**:518-533

28. Morello E, Vasconi E, Martano M, Pieroni B, Buracco P. Pasteurized tumoral autograft and adjuvant chemotherapy for the treatment of canine distal radial osteosarcoma: 13 cases. *Vet Surg*. 2003;**32**:539-544

29. Seguin B, Walsh PJ, Mason D, Wisner ER, Parmenter JL, Dernell WS. Use of an ipsilateral vascularized ulnar transposition autograft for limb-sparing surgery of the distal radius in dogs: an anatomic and clinical study. *Vet Surg*. 2003;**32**:69-79

30. Ehrhart N. Longitudinal bone transport for treatment of primary bone tumors in dogs: technique description and outcome in 9 dogs. *Vet Surg*. 2005;**34**:24-34

31. Lascelles BDX, Dernell WS, Correa MT, Lafferty MH, Devitt CM, Kuntz CA, Straw RC, Withrow SJ. Improved survival associated with postoperative wound infection in dogs treated

with limb-salvage surgery for osteosarcoma. *Annal Surg Oncol.* 2005;**12**:1073-1083

1
2
3
4
5
6
7
8
9
10
11
12
13
14
15
16
17
18
19
20
21
22
23
24
25
26
27
28
29
30
31
32
33
34
35
36
37
38
39
40
41
42
43
44
45
46
47
48
49
50
51
52
53
54
55
56
57
58
59
60

32. Ebeid W, Amin S, Abdelmegid A: Limb salvage management of pathologic fractures of primary malignant bone tumors. *Cancer Contr* 2005;**12**:57–61

33. Kuntz CA, Asselin TL, Dernel WS, Powers BE, Straw RC, Withrow SJ. Limb-salvage surgery for osteosarcoma of the proximal humerus: outcome in 17 dogs. *Vet Surg* 1998;**27**:417–422

34. LaRue SM, Withrow SJ, Powers BE, Wrigley RH, Gillette EL, Schwarz PD, Straw RC, Richter SL. Limb-sparing treatment for osteosarcoma in dogs. *J Am Vet Med Assoc* 1989;**195**:1734–1744

35. Kirpensteijn J, Steinheimer D, Park RD, Powers BE, Straw RC, Endenburg N, Withrow SJ. Comparison of cemented and non-cemented allografts in dogs with osteosarcoma. *Vet Comp Orthop Traumatol* 1998;**11**:178–184

36. Straw RC, Withrow SJ: Limb-sparing surgery versus amputation for dogs with bone tumors. *Vet Clin North Am Small Anim Pract.* 1996;**26**:135–143

37. Funk C, Young G. Subtotal pedal amputations: biomechanical and intraoperative considerations. *J Am Podiatr Med Assoc* 2001;**91**:6-12

38. Pulla RJ, Kaminsky KM. Toe amputations and ray resections. *Clin Podiatr Med Surg* 1997;**14**:691-739

39. Kaufmann KL. Short- and long-term outcomes after digit amputation in dogs: 33 cases (1999–2011). *J Am Vet Med Assoc* 2013;**242**:1249–1254

40. Pisoni L, De Magno S, Cinti F, Dalpozzo B, Bellei E, Cloriti E, Joechler M. Surgical induction

of metacarpal synostosis for treatment of ectrodactyly in a dog. *Vet Comp Orthop Traumatol* 2014;**27**:166–171

41. Selvarajah GT, Kirpensteijn J. Prognostic and predictive biomarkers of canine osteosarcoma. *Vet. J.* 2010;**185**:28–35

42. Schott CR, Tatierysky LJ, Foster RA, Wood GA. Histologic Grade Does Not Predict Outcome in Dogs with Appendicular Osteosarcoma Receiving the Standard of Care. *Vet. Pathol.* 2017;**55**:202-211

FIGURE/VIDEO CAPTIONS *figures should NOT be embedded in this document*

Figure 1. A dorsopalmar radiograph of the left carpus and manus showing severe osteolysis of the distal third of metacarpal III.

Figure 2 a-e. The appearance of the incision immediately postoperatively (3a), five days postoperatively (3b), eight weeks (3c), sixteen weeks (3d) and nineteen weeks (3e) postoperatively

Figure 3. Histology of the mass consistent with osteosarcoma.

Figure 4. A dorsopalmar radiograph of the left manus taken 3.5 months postoperatively.

OWNER'S PERSPECTIVE *Optional*

Copyright Statement

I, *Jon Hall*, The Corresponding Author, has the right to assign on behalf of all authors and does assign on behalf of all authors, a full assignment of all intellectual property rights for all content within the submitted case report (other than as agreed with the BMJ Publishing Group Ltd and the British Veterinary Association) ("BMJ" and "BVA") in any media known now or created in the future, and permits this case report (if accepted) to be published on Veterinary Record Case Reports and to be fully exploited within the remit of the assignment as set out in the assignment which has been read <http://journals.bmj.com/site/misc/vetreccrcopyright.pdf>

Date:8.10.2018

<hr/>
PLEASE SAVE YOUR TEMPLATE WITH THE FOLLOWING FORMAT:
Corresponding author's last name and date of submission, eg, Smith_June_2017.doc

1
2
3
4
5
6
7
8
9
10
11
12
13
14
15
16
17
18
19
20
21
22
23
24
25
26
27
28
29
30
31
32
33
34
35
36
37
38
39
40
41
42
43
44
45
46
47
48
49
50
51
52
53
54
55
56
57
58
59
60