



# THE UNIVERSITY *of* EDINBURGH

## Edinburgh Research Explorer

### Alternative surgical treatment for synovial ganglion cyst of the digital tendon sheath in one horse

**Citation for published version:**

Lipperi, G & Kelly, P 2019, 'Alternative surgical treatment for synovial ganglion cyst of the digital tendon sheath in one horse' *Equine Veterinary Education*. DOI: 10.1111/eve.13041

**Digital Object Identifier (DOI):**

[10.1111/eve.13041](https://doi.org/10.1111/eve.13041)

**Link:**

[Link to publication record in Edinburgh Research Explorer](#)

**Document Version:**

Publisher's PDF, also known as Version of record

**Published In:**

*Equine Veterinary Education*

**Publisher Rights Statement:**

This is an open access article under the terms of the Creative Commons Attribution License, which permits use, distribution and reproduction in any medium, provided the original work is properly cited.

**General rights**

Copyright for the publications made accessible via the Edinburgh Research Explorer is retained by the author(s) and / or other copyright owners and it is a condition of accessing these publications that users recognise and abide by the legal requirements associated with these rights.

**Take down policy**

The University of Edinburgh has made every reasonable effort to ensure that Edinburgh Research Explorer content complies with UK legislation. If you believe that the public display of this file breaches copyright please contact [openaccess@ed.ac.uk](mailto:openaccess@ed.ac.uk) providing details, and we will remove access to the work immediately and investigate your claim.



## Case Report

# Alternative surgical treatment for synovial ganglion cyst of the digital tendon sheath in one horse

G. Lipreri<sup>†\*</sup>  and P. G. Kelly<sup>‡</sup><sup>†</sup>Leahurst Equine Hospital, University of Liverpool, Neston; and <sup>‡</sup>The Dick Vet Equine Hospital, University of Edinburgh, Midlothian, UK

\*Corresponding author email: G.Lipreri@liverpool.ac.uk

**Keywords:** horse; lameness; tendon sheath; synovial cyst; tenoscopy

## Summary

A 6-year-old Highland pony gelding was presented with severe left fore (LF) limb lameness of acute onset. The lameness occurred concomitantly with mild digital flexor tendon sheath (DFTS) effusion and focal painful swelling on the lateral aspect of the LF fetlock region. Clinical examination and diagnostic analgesia localised the lameness to the fetlock region and on ultrasound, a cyst-like structure filled with anechoic fluid was detected just proximal to the lateral sesamoid bone, at the proximo-lateral aspect of the DFTS and adjacent to the lateral neurovascular bundle. Communication between the cyst-like structure and the DFTS was suspected ultrasonographically and then confirmed with contrast tenography. Tenoscopic examination of the LF DFTS was performed and the communication between the fluid-filled structure and the synovial cavity was detected. The defect in the DFTS wall was enlarged tenoscopically and the lining of the cyst-like structure was debrided. The horse recovered well post-operatively and was back in work with no evident lameness 8 months after surgery. This alternative minimally invasive surgical treatment had an excellent outcome and has the advantage of reducing the risk associated with en bloc resection.

## Introduction

Fluid-filled cyst-like structures associated with the digital flexor tendon sheath (DFTS) are uncommon in horses but can cause lameness or be a cosmetic concern (Crawford *et al.* 2011). These structures can be classified as synovial hernia, synovial ganglion or synoviocoele, however debate exists regarding the terminology. A synovial hernia occurs as a result of a defect in the fibrous capsule of the joint or tendon sheath, through which the synovial membrane protrudes (Kawcak 2011). Whereas, a ganglion is described as a small cyst that does not contain synovial lining and that connects to a joint or a tendon sheath through a one-way tract (Pool 1990). Recently, Minshall and Wright (2012) proposed the term synoviocoele to describe a cavity of synovial origin resulting from disruption of both fibrous and synovial layers of a congenital synovial structure.

Crawford *et al.* (2011) reported a case series of fluid-filled masses associated with the DFTS that were treated by surgical excision. Clinical and histological findings were reported and were consistent with ganglion cysts of traumatic origin. Eight of the 10 horses included in the case series were lame and following surgical excision of the cyst, seven of the eight lame horses returned to previous level of work. One

case report described successful, conservative management of a similar clinically significant fluid-filled mass associated with the DFTS in a pony (Smith 2009). The mass was injected with corticosteroids and atropine and the limb was bandaged for 48 h. According to the human literature, conservative management of dorsal wrist ganglion is associated with increased recurrence rate and reduced success rate compared to surgical excision (Kahn and Hayat 2011).

In this report, an alternative minimally invasive surgical management of synovial ganglion cyst associated with DFTS in one horse is described.

## Case history

A 6-year-old Highland pony used for general riding was presented to a referral hospital for further investigation of severe left fore (LF) limb lameness. The pony had reportedly been lame for approximately 1 month before referral. Lameness was acute in onset and the attending veterinary surgeon identified mild effusion of the LF DFTS with moderate swelling on the lateral aspect of the LF fetlock region. When the lameness occurred there were no radiographic abnormalities of the LF fetlock joint but initial conservative management, consisting of box rest and oral NSAIDs, was unsuccessful.

## Clinical findings and diagnosis

On presentation to the referral hospital, the pony was bright and alert and his vital parameters were within normal limits. His body condition score was 5/5 (Carroll and Huntington 1988). The pony was unshod and fully weight bearing on all four limbs. The LF DFTS was mildly effused proximally and distally with a focal swelling on the palmaro-lateral aspect of the LF fetlock, just proximal to the lateral sesamoid bone. The pony strongly resented palpation of the focal swelling. The pony was moderately lame at the walk and 8/10 lame (Wyn-Jones 1988) at the trot in a straight line. The LF lameness remained unchanged following palmar digital nerve block but was abolished by a low four-point nerve block. Diagnostic analgesia of the DFTS was considered but, due to the difficult nature of the horse, it was decided that this could not be accurately or safely achieved without sedation. Therefore, the decision was made to proceed with diagnostic imaging.

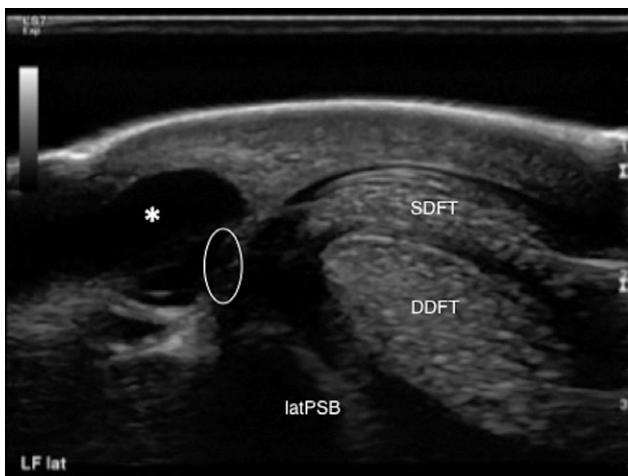
Ultrasonographic examination of the fetlock region and of the palmar aspect of the distal metacarpus was performed. No abnormalities were detected in the lateral branch of the suspensory ligament or in the soft tissue structures within the DFTS. However, moderate effusion of the DFTS was noted.

Ultrasonography of the swelling on the palmaro-lateral aspect of the LF fetlock showed a well circumscribed, subcutaneous, spherical structure filled with anechoic fluid, consistent with a cyst-like lesion. This was located just proximal to the lateral sesamoid bone and to the palmar annular ligament (PAL), adjacent to the proximo-lateral aspect of the DFTS and to the lateral neurovascular bundle. The margin of the cyst-like structure was well demarcated and closely associated with the lateral wall of the DFTS. A circular defect in the medial aspect of the cyst wall was suggestive of an open communication between the two structures (**Fig 1**). To further ascertain the significance of the cyst, it was elected to aseptically aspirate the cyst contents under ultrasonographic guidance. On aspiration of the cyst-like structure, clear yellow, nonviscous fluid was obtained. The fluid contained no protein and total white cell count was  $0.01 \times 10^9/L$ . Decompression of the cyst-like structure resulted in immediate marked improvement of the lameness.

Contrast tenography of the LF DFTS was performed to confirm communication between the two structures. Under aseptic conditions, 5 mL of nonionic radiographic contrast medium (iohexol, Omnipaque 350 mgI/mL<sup>1</sup>) mixed with 5 mL of normal saline, was injected in the DFTS using the distal approach between the proximal and distal digital annular ligaments. The horse was hand-walked and, approximately 5 min after the injection of the contrast medium, a radiographic examination of the fetlock region was performed. Correct injection of the contrast medium in the DFTS was confirmed and both dorsopalmar and dorsolateral-palmaromedial oblique radiographic view showed accumulation of contrast medium in a spherical structure on the palmaro-lateral aspect of the DFTS, at the level of a radiopaque marker previously placed to correspond with the palpable swelling (**Figs 2** and **3**). Diagnosis of a cyst-like structure communicating with the DFTS was confirmed.

### Treatment

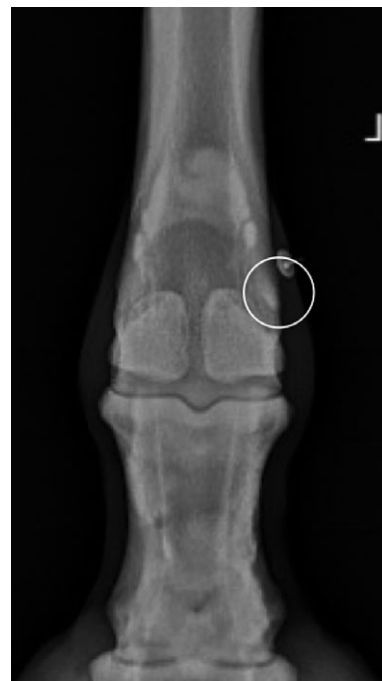Conservative and surgical management were discussed with the owner and it was decided to proceed with surgical



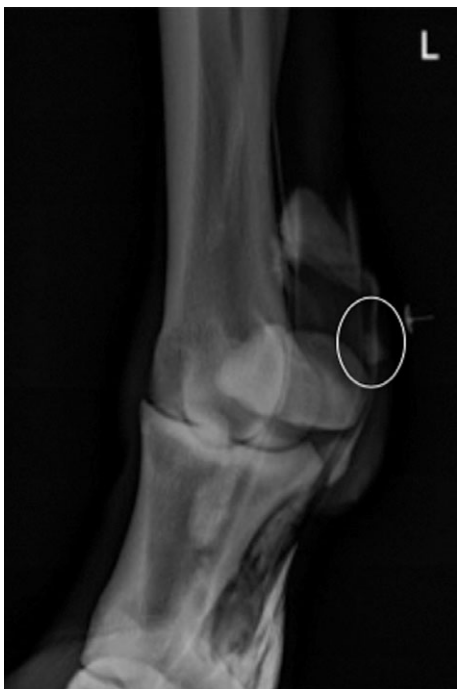**Fig 1:** Transverse ultrasonographic image of the palmaro-lateral aspect of the LF fetlock showing the cyst-like structure filled with anechoic fluid (see asterisk). The communication between the medial edge of the cyst-like structure and the lateral wall of the DFTS can be appreciated (see circled area).

treatment. The horse was anaesthetised and placed in right lateral recumbency. The LF distal limb was aseptically prepared and a tourniquet was applied to the proximal metacarpus. The first tenoscopic portal was made as standard, into the lateral outpouching of the DFTS between the PAL and the proximal digital annular ligament approximately 5 mm palmar to the palmar digital neurovascular bundle (Nixon 1990). The endoscope and cannula were inserted and the DFTS was inspected. No lesions of the SDFT or DDFT were noted and the manica flexoria was intact. A small elliptical defect of the lateral wall of the DFTS, just proximal to the PAL, was identified. On external palpation of the cyst, gas bubbles were noted to emanate from the defect into the DFTS (**Fig 4**). An instrument portal was made proximally in the lateral outpouching of the sheath. In order to facilitate greater manipulation of the instruments within the sheath, a desmotomy of the PAL was performed using a combination of a hook knife and No. 12 blade. The communication between the circular fluid-filled structure and the DFTS was identified and confirmed with an arthroscopic probe. The elliptical defect in the DFTS wall was enlarged and extended to the PAL desmotomy using a hook knife. The incision made to join the two structures was approximately 1 cm long. A motorised synovial resector in oscillating mode with active suction was inserted into the cavity and, without active pressure, any loose soft tissue was debrided.

Following lavage of the DFTS, skin portal incisions were closed with 3 metric polypropylene suture material in a simple interrupted suture pattern. A two-layer bandage was placed



**Fig 2:** Contrast tenography. Dorsopalmar projection of the LF fetlock region showing accumulation of the contrast medium within the DFTS and a small circular structure just proximal to the lateral proximal sesamoid bone (see circled area). The radiopaque marker was placed to correspond with the palpable swelling.



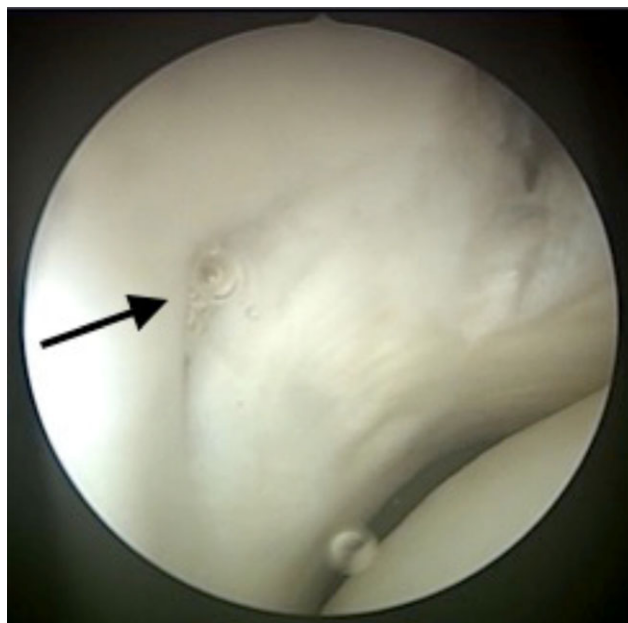
**Fig 3:** Contrast tenography. Dorsolateral-palmaromedial projection of the LF fetlock region showing accumulation of the contrast medium within the DFTS and a small circular structure just proximal to the lateral proximal sesamoid bone (see circled area). The radiopaque marker was placed to correspond with the palpable swelling.

on the distal limb at the end of surgery. The horse recovered uneventfully from the general anaesthetic with the assistance of head and tail ropes.

Immediate improvement of the LF lameness was noted following the surgery. The bandage was changed on Day 2 and 4 post-operatively. The surgical sites remained clean and dry, with minimal distension at the level of the cyst. The horse was discharged home 5 days after surgery and the bandage was changed every 3 days until 7 days after suture removal. The skin sutures were removed 10 days post-operatively. The horse was discharged home with a 9-week rehabilitation program consisting of 1 week of stall rest, 4 weeks of twice daily 15 min hand walking exercise and additional 4 weeks, in which the hand walking exercise was increased by 5 min weekly. At 6 and 9 weeks after surgery the horse was reassessed respectively by the veterinary surgeon who performed the surgery and by the referring veterinarian.

### Outcome

The LF limb lameness improved significantly immediately and the horse was sound at the walk and at the trot in straight line 6 weeks after surgery. At the 6-week follow-up there was a mild thickening of the area but no DFTS effusion. No painful response was elicited on digital palpation. Ultrasonographic examination revealed the cyst-like structure was no longer visible and was replaced with tissue of mixed ultrasonographic echogenicity (Fig 5). Nine weeks after surgery the horse was considered sound and fit to resume ridden exercise. Eight months after surgery the pony was sound and had resumed the previous level of exercise. Mild thickening of the area was still present.

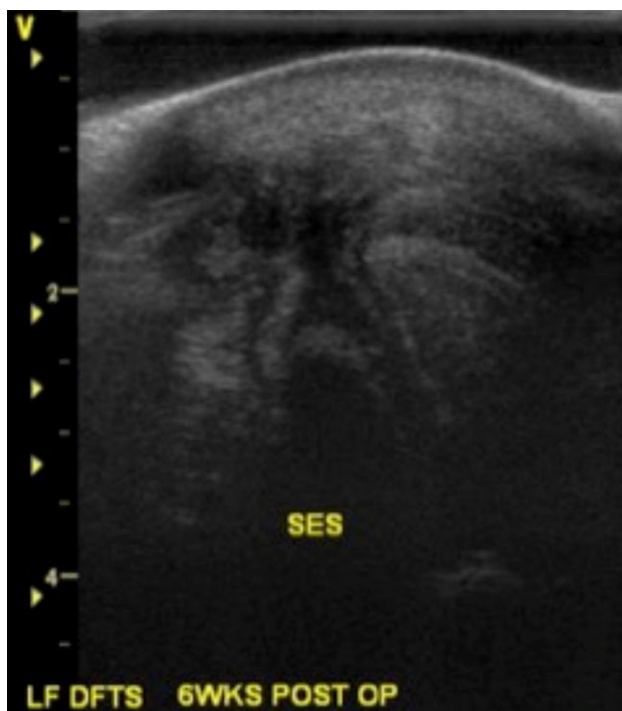


**Fig 4:** Tenoscopic image of the small tear in the wall of the DFTS, just proximal to the PAL. It is possible to note gas bubbles (see black arrow) emanating from the defect into the DFTS when external pressure is applied on the cyst-like lesion.

### Discussion

This case report describes the surgical management of a synovial ganglion cyst associated with the DFTS using a minimally invasive technique. There was immediate improvement of the lameness following surgery, a return to exercise at 2 months with continued resolution 8 months after surgery. The authors elected to use the term synovial ganglion cyst to describe the fluid-filled cyst-like lesion associated with the DFTS based on the definition of ganglion as a fluid-filled structure that connects to a joint or a tendon sheath through a one-way tract into the mass (Pool 1990). Moreover, the location of the fluid-filled cyst-like lesion in the proximal aspect of the DFTS is consistent with that described by Crawford *et al.* (2011). Another possible term that could have been considered is synoviocoele, a cavity originating from disruption of both fibrous and synovial layers of a congenital structure (Minshall and Wright 2012). However, with ultrasonographic and tenoscopic examination, it was not possible to appreciate if both fibrous and synovial layers were disrupted. Histopathologic examination would be necessary to confirm the presence or absence of synovial lining on the cyst wall.

The origin of the lesion is unknown but, considering the acute onset of the lameness, it was likely to be traumatic. This is supported by Laverty (2009), who stated that synovial cyst-type masses are most commonly associated with previous trauma. Considering the likely traumatic origin of the lesion and the relation with the DFTS, it is important not to overlook a possible underlying or secondary cause of lameness that could affect the long-term prognosis. For this reason, a thorough evaluation of the DFTS, both ultrasonographically and tenoscopically is recommended (Laverty 2009; Crawford *et al.* 2011).



**Fig 5: Transverse ultrasonographic image of the palmaro-lateral aspect of the LF fetlock acquired 6 weeks after surgery. The cyst-like structure is no longer visible and was replaced with tissue of mixed ultrasonographic echogenicity.**

In our case, correlation between the cyst-like structure and the lameness was confirmed by clinical examination, diagnostic analgesia and a positive response to surgical treatment. The lameness may be explained by the existence of a one-way valve effect that results in progressive increase in intralesional pressure that in turn causes local pressure and irritation of the surrounding tissues (Kawcak 2011).

Ultrasonographic examination demonstrated close proximity of the lesion to the lateral palmar neurovascular bundle. Impingement of the lateral palmar nerve was also considered a possible cause of the severe lameness.

Intrathecal anaesthesia of the DFTS was not performed because of the pony's temperament. Crawford *et al.* (2011) reported that while not all the horses in their series had a positive response to digital sheath anaesthesia, the lameness was improved or abolished by an abaxial sesamoid or a low four-point nerve block.

The surgical technique used in this case allows the simultaneous assessment of the structures in the DFTS and the debridement of the cyst without the need for a second surgical approach. The rationale behind opening the communication is to convert the unidirectional flow of synovial fluid into a bidirectional flow, which would prevent progressive increase in intralesional pressure. This was first described in human literature by Sansone and De Ponti in 1999 in relation to management of popliteal cyst associated with knee joints. The same technique was successfully used by Minshall and Wright (2012) to treat a synoviocele associated with the tarsal sheath.

A previously described technique for managing DFTS ganglion cyst involves incising directly over the cyst to expose

the communication with the sheath followed by en bloc resection of the cyst, sometimes in proximity of the neurovascular bundle (Crawford *et al.* 2011). Using this technique, a small cuff of synovial capsule is removed together with the cyst and consequent primary closure of the synovial wall of the DFTS is then necessary.

The main advantage in using a minimally invasive technique is that a single-stage tenoscopic procedure avoids the need for a skin incision over the cyst and for primary closure of the DFTS synovial wall. Although no complications were reported in Crawford *et al.* (2011) case series, it is described both in human and veterinary literature that arthroscopic surgery is associated with an overall decrease in morbidity compared with open techniques (Vatistas *et al.* 1995; McIlwraith and Bramlage 1996; Treuting 2000).

There was no difference in outcome between our case and the cases reported by Crawford *et al.* (2011), however the case here described had a slightly earlier return to ridden exercise (10 weeks vs. 12–18 weeks after surgery).

The use of a minimally invasive technique to manage ganglion cysts associated with the DFTS was not previously described and the authors elected to follow a post-operative rehabilitation plan similar to that reported by Crawford *et al.* (2011). However, the authors believe that using this minimally invasive technique would allow reduced intensive aftercare and an earlier return to controlled exercise. Moreover, even if direct comparison of the surgical time of the two described surgical techniques was not possible, a reduced surgical time may be expected using the minimally invasive technique.

One disadvantage of this technique is that, since the mass is not excised, no histological examination can be performed. However, it is unlikely that the post-operative management would be affected by the histology results. Transection of the PAL was included in our case because it was considered to be constricting the fetlock canal, and it allowed greater surgical manoeuvrability minimising the risk of superficial iatrogenic damage to the flexor tendons. We are not aware of any reported increased risk associated with tenoscopic PAL transection, rather this procedure is recommended when instrument movement is restricted in the fetlock canal (Fortier *et al.* 1999; Fortier 2005). This expedites a thorough examination of the tendon sheath contents (Fortier *et al.* 1999). Transection of the PAL can lead to a curved appearance of the palmar aspect of the fetlock and the owner should be informed of this possibility prior to surgery (Nixon 2012). In this case, the pony was feathered and therefore this was not deemed a negative complication of the technique chosen.

In conclusion, we report complete resolution of the lameness associated with a DFTS ganglion cyst following tenoscopic enlargement of the communication between the cavity and the DFTS and debridement of the cavity's lining. This minimally invasive technique has advantages compared to the traditional technique, however a case series describing outcome using this technique on a larger number of horses are necessary to state its superiority.

#### **Authors' declaration of interests**

No conflicts of interest have been declared.

## Ethical animal research

This report describes a clinical experience. No submission to an ethics committee was required. The owner signed a standard consent form.

## Source of funding

None.

## Authorship

G. Lipreri performed the lameness evaluation and diagnostics, contributed to the execution of the surgery and prepared the manuscript. P. G. Kelly performed the surgery and contributed to the preparation of the manuscript.

## Manufacturer's address

<sup>1</sup>GE Healthcare AS, Oslo, Norway.

## References

- Carroll, C.L. and Huntington, P.J. (1988) Body condition scoring and weight estimation of horses. *Equine Vet. J.* **20**, 41-45.
- Crawford, A., O'Donnell, M., Crowe, O., Eliashar, E. and Smith, R.K. (2011) Digital sheath synovial ganglion cysts in horses. *Vet. Surg.* **40**, 66-72.
- Fortier, L.A. (2005) Indications and techniques for tenoscopic surgery of the digital flexor tendon sheath. *Equine Vet. Educ.* **17**, 218-224.
- Fortier, L.A., Nixon, A.J., Ducharme, N.G., Mohammed, H.O. and Yeager, A. (1999) Tenoscopic examination and proximal annular ligament desmotomy for treatment of equine "complex" digital sheath tenosynovitis. *Vet. Surg.* **28**, 429-435.
- Kahn, P.S. and Hayat, H. (2011) Surgical excision versus aspiration combined with intralesional triamcinolone acetonide injection plus wrist immobilization therapy in the treatment of dorsal wrist ganglion; a randomized controlled trial. *J. Hand Microsurg.* **3**, 55-57.
- Kawcak, C.E. (2011) Other joint conditions. In: *Diagnosis and Management of Lameness in the Horse*, 2nd edn., Eds: M.W. Ross and S.J. Dyson, Saunders, Philadelphia. pp 691-693.
- Lavery, S. (2009) Synovial cyst/hernias. *Equine Vet. Educ.* **21**, 375-376.
- McIlwraith, C.W. and Bramlage, L.R. (1996) Surgical treatment of joint injury. In: *Joint Disease in the Horse*, Eds: C.W. McIlwraith and G.W. Trotter, Saunders, Philadelphia. pp 292-317.
- Minshall, G.J. and Wright, I.M. (2012) Synoviociele associated with the tarsal sheath: description of the lesion and treatment in 15 horses. *Equine Vet. J.* **44**, 71-75.
- Nixon, A.J. (1990) Endoscopy of the digital flexor tendon sheath in horses. *Vet. Surg.* **19**, 266-271.
- Nixon, A.J. (2012) Phalanges and the metacarpophalangeal and metatarsophalangeal joints. In: *Equine Surgery*, 4th edn., Eds: J.A. Auer and J.A. Stick, Saunders, St. Louis, Missouri. pp 1300-1325.
- Pool, R. (1990) Tumors and tumor like lesions of joints and adjacent soft tissues. In: *Tumors in Domestic Animals*, 3rd edn., Ed: J.E. Moulton, University of California Press, Berkeley. pp 125-126.
- Sansone, V. and De Ponti, A. (1999) Arthroscopic treatment of popliteal cyst and associated intra-articular knee disorders in adults. *Arthroscopy* **15**, 368-372.
- Smith, L.C.R. (2009) Treatment of a cyst-like synovial hernia associated with the digital flexor tendon sheath of a 17-year-old pony. *J. Equine Vet. Sci.* **29**, 786-790.
- Treuting, R. (2000) Minimally invasive orthopedic surgery: arthroscopy. *Ochsner J.* **2**, 158-163.
- Vatistas, N.J., Wright, I.M. and Dyson, S.J. (1995) Comparison of arthroscopy and arthrotomy for the treatment of osteochondritic lesions in the femoropatellar joint of horses. *Vet. Rec.* **137**, 629-632.
- Wyn-Jones, G. (1988) *Equine Lameness*, Blackwell Scientific, Oxford, UK.