



THE UNIVERSITY *of* EDINBURGH

Edinburgh Research Explorer

An open-label trial of JAK 1/2 blockade in progressive IFIH1-associated neuroinflammation

Citation for published version:

Kothur, K, Bhandokar, S, Chu, S, Wienholt, L, Johnson, A, Barclay, P, Brogan, PA, Rice, GI, Crow, YJ & Dale, RC 2018, 'An open-label trial of JAK 1/2 blockade in progressive IFIH1-associated neuroinflammation' *Neurology*, vol. 90, no. 6, pp. 289-291. DOI: 10.1212/WNL.0000000000004921

Digital Object Identifier (DOI):

[10.1212/WNL.0000000000004921](https://doi.org/10.1212/WNL.0000000000004921)

Link:

[Link to publication record in Edinburgh Research Explorer](#)

Document Version:

Publisher's PDF, also known as Version of record

Published In:

Neurology

General rights

Copyright for the publications made accessible via the Edinburgh Research Explorer is retained by the author(s) and / or other copyright owners and it is a condition of accessing these publications that users recognise and abide by the legal requirements associated with these rights.

Take down policy

The University of Edinburgh has made every reasonable effort to ensure that Edinburgh Research Explorer content complies with UK legislation. If you believe that the public display of this file breaches copyright please contact openaccess@ed.ac.uk providing details, and we will remove access to the work immediately and investigate your claim.



An open-label trial of JAK 1/2 blockade in progressive *IFIH1*-associated neuroinflammation

Kavitha Kothur, FRACP, Sushil Bandodkar, PhD, Stephanie Chu, MScMed, Louise Wienholt, DBA, Alexandra Johnson, MMed, Peter Barclay, BPharm, Paul A. Brogan, PhD, Gillian I. Rice, PhD, Yanick J. Crow, PhD,* and Russell C. Dale, PhD*

Neurology® 2018;90:1-3. doi:10.1212/WNL.0000000000004921

Correspondence

Dr. Dale
russell.dale@health.nsw.gov.au

IFIH1 gain-of-function causes a spectrum of neuroinflammatory phenotypes associated with enhanced type I interferon production and Janus kinase (JAK)/signal transducer and activator of transcription (STAT) pathway activation.^{1,2} Patients most often present in infancy, variably exhibiting spasticity, dystonia, seizures, and acquired microcephaly. We report the use of ruxolitinib, a JAK 1/2 blocker, in the treatment of early-onset, progressive neurologic disease due to an *IFIH1* mutation.

Case report

A 3-year-old boy born to unrelated white European parents developed normally until age 8 months, after which he experienced developmental regression with loss of trunk and head control so that he could no longer sit or hold objects. The following 8 months were characterized by sterile pyrexias, irritability, increasing spasticity, and exaggerated startle responses to sounds (video, links.lww.com/WNL/A107). At age 16 months, he was microcephalic, small, and centrally hypotonic with peripheral spasticity (table e-1, links.lww.com/WNL/A109). CSF was unremarkable except for elevated neopterin. Neuroimaging revealed mildly delayed myelination and no calcification. Genetic testing identified a de novo heterozygous p. Arg779Cys *IFIH1* substitution, as previously reported in a patient dying at age 3.5 years of a fulminant lupus-like syndrome on a background of neonatal-onset severe developmental delay (F376 in Rice et al.¹). There was a marked upregulation of interferon-stimulated gene (ISG) transcripts in blood, a reliable biomarker of *IFIH1*-related disease.³

Oral prednisolone was begun at age 16 months, 2 mg/kg for 2 months, followed by weaning over 6 months, and IV immunoglobulin at age 20 months, 1 g/kg monthly for 3 months, with temporary benefits in head and trunk control and decreased irritability and pyrexias. However, these gains were lost on weaning. Given progressive hypertonia and developmental stagnation, 16 months after disease onset he was begun on ruxolitinib 2.5 mg twice daily, increased to 5 mg twice daily 6 weeks later.⁴ Over the next 19 months, he regained independent sitting and began using a walker (video, links.lww.com/WNL/A107). Hand function improved so that he could finger feed, pick up and throw objects, use an iPad, and turn taps on and off. He could understand multistep sentences, although his expressive language remained limited to 5–6 words. These clinical observations were reflected in improved functional motor scores (table e-1, links.lww.com/WNL/A109; figure e-1, links.lww.com/WNL/A108; and video). Erythrocyte sedimentation rate and platelet count decreased on treatment, and repeat MRI at age 42 months demonstrated progressive, albeit still mildly delayed, myelination, without atrophy or calcification (figures e-2 and e-3).

*These authors contributed equally to this work.

From The Children's Hospital at Westmead (K.K., S.B., P.B., R.C.D.), University of Sydney; Royal Prince Alfred Hospital (S.C., L.W.); Sydney Children's Hospital (A.J.), Australia; University College London (P.A.B.), Great Ormond Street Institute of Child Health; Manchester Academic Health Science Centre (G.I.R., Y.J.C.), University of Manchester, UK; and INSERM UMR1163 (Y.J.C.), Institute Imagine, Paris, France.

Go to Neurology.org/N for full disclosures. Funding information and disclosures deemed relevant by the authors, if any, are provided at the end of the article.

MORE ONLINE

Video

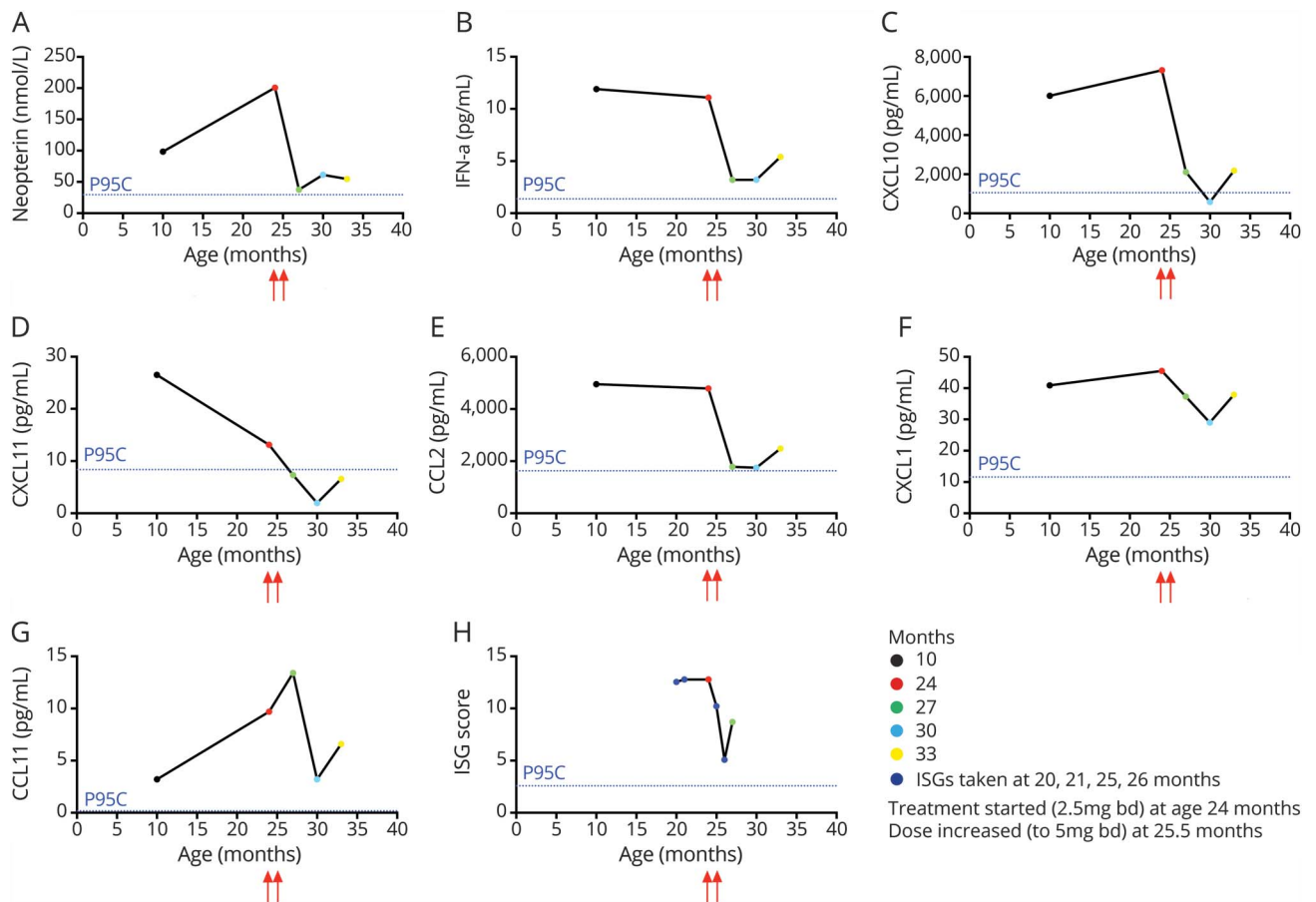
links.lww.com/WNL/A107

Class of evidence

Criteria for rating therapeutic and diagnostic Studies

Npub.org/coe

Figure Inflammatory biomarkers during treatment with ruxolitinib



(A) CSF neopterin, (B–G) CSF cytokine/chemokine during treatment with ruxolitinib. Retrospective testing of CSF collected at ages 10 months and 24 months revealed elevated levels of neopterin and cytokines/chemokines (interferon (IFN)- α , CXCL10, CXCL11, CCL2, CXCL1, and CCL11). Serial CSF measures at 3 further time points (27, 30, and 33 months of age) over a 10-month period after initiation of ruxolitinib demonstrated an overall fall in all of these CSF markers. (H) Similarly, serial blood interferon-stimulated gene (ISG) transcript scores were higher before ruxolitinib (at ages 20, 21, and 24 months) than post ruxolitinib (at ages 25, 26, and 27 months). The 95th centile of 20 noninflammatory controls is presented as a dotted line in each panel (P95C).

CSF samples, all acellular, were tested for 32 cytokines and chemokines and compared with 20 noninflammatory pediatric controls.⁵ CSF collected before ruxolitinib treatment, at ages 10 and 24 months, demonstrated elevated levels of neopterin, interferon- α , CXCL10, CXCL11, CXCL1, CCL2, and CCL11. Serial measures at 3 time points after treatment initiation (age 27, 30, and 33 months) revealed a fall in these markers, albeit not to normal (figure). Ruxolitinib was measured during treatment, showing a trough concentration of 17.5 and 2.64 ng/mL in serum and CSF, respectively, with a CSF penetrance of 15.1%. Treatment was well-tolerated, with normal 3-monthly full blood counts, renal and liver function, CSF and intraocular pressures, growth, consistently negative JC and BK viral titers, and no side effects.

Discussion

Our patient had an *IFIH1* gain-of-function mutation resulting in interferon-mediated inflammation signaling through the

type I interferon receptor and JAK1, as evidenced by an elevation of ISGs in blood and proinflammatory cytokines and chemokines in CSF. Ruxolitinib demonstrates a favorable therapeutic effect in patients with *STING* gain-of-function mutations,⁴ suggesting that JAK inhibition might represent a viable approach to blocking type I interferon signaling in the broader monogenic interferonopathy grouping.⁶ The efficacy of JAK 1/2 blockade in type I interferon-driven neuroinflammation has not been addressed previously. Although our report involves a single patient, and must be considered in the context of a genotype associated with variability in clinical outcome,¹ we observed substantial developmental gains against a background of previous regression and then developmental stagnation, combined with a positive effect on blood and CSF proinflammatory biomarkers. Ruxolitinib was present in CSF, suggesting access to the CNS. No adverse effects occurred at the doses used. However, immunosuppression is a potential risk, and rebound cytokine storm has been described on withdrawal.^{4,7} Given that we describe

a single case (Class IV evidence), this approach requires evaluation in a larger number of patients with sequential developmental and neurologic assessment. JAK inhibition represents a promising approach to the treatment of type I interferon-mediated autoinflammation, possibly including CNS inflammation.

Author contributions

K.K. performed a literature review, CSF cytokine/chemokine testing, and data analysis, and drafted the paper under the supervision of R.C.D. L.W. and S.C. performed CSF cytokine/chemokine testing. S.B. helped with CSF sample storage and the neopterin/ruxolitinib assay. P.B., P.A.B., and A.J. were involved in the clinical management of the case. G.I. R. performed genetic testing, generated interferon stimulated gene data, and was involved in data analysis. Y.J.C. provided expert review of the paper. R.C.D. supervised the project. All authors helped in critical revision of the manuscript and edited the paper.

Acknowledgment

The authors thank the patient's family and Dr. Bénédicte Neven for advice relating to the use of ruxolitinib.

Study funding

This work was supported by a scholarship from Petre Foundation and Australian Postgraduate award. Y.J.C. acknowledges funding from the European Research Council (GA 309449: fellowship to Y.J.C.), ERA-NET Neuron

(MR/M501803/1), and a state subsidy managed by the National Research Agency (France) under the Investments for the Future (ANR-10-IAHU-01).

Disclosure

K. Kothur, S. Bandodkar, S. Chu, L. Wienholt, A. Johnson, and P. Barclay report no disclosures relevant to the manuscript. P. Brogan has institutional grants from Sobi, Roche, and Novartis and receives consultancy fees from Sobi and Roche. G. Rice, Y. Crow, and R. Dale report no disclosures relevant to the manuscript. Go to Neurology.org/N for full disclosures.

Received May 21, 2017. Accepted in final form October 18, 2017.

References

1. Rice GI, del Toro Duany Y, Jenkinson EM, et al. Gain-of-function mutations in *IFIH1* cause a spectrum of human disease phenotypes associated with upregulated type I interferon signaling. *Nat Genet* 2014;46:503–509.
2. Oda H, Nakagawa K, Abe J, et al. Aicardi-Goutieres syndrome is caused by *IFIH1* mutations. *Am J Hum Genet* 2014;95:121–125.
3. Rice GI, Forte GM, Szykiewicz M, et al. Assessment of interferon-related biomarkers in Aicardi-Goutieres syndrome associated with mutations in *TREX1*, *RNASEH2A*, *RNASEH2B*, *RNASEH2C*, *SAMHD1*, and *ADAR*: a case-control study. *Lancet Neurol* 2013;12:1159–1169.
4. Fremont ML, Rodero MP, Jeremiah N, et al. Efficacy of the Janus kinase 1/2 inhibitor ruxolitinib in the treatment of vasculopathy associated with TMEM173-activating mutations in 3 children. *J Allergy Clin Immunol* 2016;138:1752–1755.
5. Kothur K, Wienholt L, Tantsis EM, et al. B Cell, Th17, and neutrophil related cerebrospinal fluid cytokine/chemokines are elevated in MOG antibody associated demyelination. *PLoS One* 2016;11:e0149411.
6. Rodero MP, Crow YJ. Type I interferon-mediated monogenic autoinflammation: the type I interferonopathies, a conceptual overview. *J Exp Med* 2016;213:2527–2538.
7. Tefferi A, Pardanani A. Serious adverse events during ruxolitinib treatment discontinuation in patients with myelofibrosis. *Mayo Clin Proc* 2011;86:1188–1191.