



THE UNIVERSITY *of* EDINBURGH

Edinburgh Research Explorer

Imaging diagnosis – Ultrasound and computed tomography of sacculitis and appendicitis in a rabbit

Citation for published version:

Longo, M, Thierry, F, Eatwell, K, Schwarz, T, Del-Pozo, J & Richardson, J 2018, 'Imaging diagnosis – Ultrasound and computed tomography of sacculitis and appendicitis in a rabbit' *Veterinary Radiology & Ultrasound*, vol. 59, no. 5, pp. E56 - E60. DOI: 10.1111/vru.12602

Digital Object Identifier (DOI):

[10.1111/vru.12602](https://doi.org/10.1111/vru.12602)

Link:

[Link to publication record in Edinburgh Research Explorer](#)

Document Version:

Publisher's PDF, also known as Version of record

Published In:

Veterinary Radiology & Ultrasound

Publisher Rights Statement:

This is an open access article under the terms of the Creative Commons Attribution License, which permits use, distribution and reproduction in any medium, provided the original work is properly cited.

General rights

Copyright for the publications made accessible via the Edinburgh Research Explorer is retained by the author(s) and / or other copyright owners and it is a condition of accessing these publications that users recognise and abide by the legal requirements associated with these rights.

Take down policy

The University of Edinburgh has made every reasonable effort to ensure that Edinburgh Research Explorer content complies with UK legislation. If you believe that the public display of this file breaches copyright please contact openaccess@ed.ac.uk providing details, and we will remove access to the work immediately and investigate your claim.



Ultrasound and computed tomography of sacculitis and appendicitis in a rabbit

Maurizio Longo  | Florence Thierry  | Kevin Eatwell | Tobias Schwarz | Jorge del Pozo | Jenna Richardson

Royal (Dick) School of Veterinary Studies and Roslin Institute, The University of Edinburgh, Roslin, UK

Correspondence

Maurizio Longo, Royal (Dick) School of Veterinary Studies and Roslin Institute, The University of Edinburgh, Roslin, EH25 9RG, UK.
Email: mlongo@exseed.ed.ac.uk

Abstract

A 9-month-old neutered male rabbit was referred for lethargy, anorexia, and gastrointestinal stasis. Routine hematology, serum biochemistry, and diagnostic imaging were performed. Computed tomography revealed a wall thickening of the sacculus rotundus and appendix, which was further confirmed on abdominal ultrasound. Full thickness biopsies were collected with histopathology diagnosing a chronic multifocal heterophilic granulomatous sacculitis and appendicitis. The patient was treated medically and at 6 weeks follow-up, clinical signs and intestinal changes had completely regressed. Inflammation of the sacculus rotundus and appendix should be considered as a cause of gastrointestinal stasis in rabbits.

KEYWORDS

appendix, cecum, sacculus rotundus, typhilitis

1 | SIGNALMENT, HISTORY, AND CLINICAL FINDINGS

A 9-month-old, male neutered, Lionhead rabbit was presented to the Rabbit and Exotic Animal Department at the referral Hospital of the University of Edinburgh for evaluation of a 4-day history of anorexia, lethargy, and decreased fecal production consistent with gastrointestinal stasis. The patient was neutered at 6 months of age by the referring veterinary surgeon and had no previous health concerns. The diet offered included ad-libitum hay, with a small ration of complete commercial pellet and mix of fresh green vegetables each day.

On physical examination, the patient was tachypnoeic, with a heart rate of 200 beats/min and an elevated rectal temperature of 39.9°C. Body condition score was 2/5 and no abnormality was detected on palpation of the abdomen. Gut sounds were absent on abdominal auscultation. Complete blood count findings included a mildly elevated white cell count of $13.1 \times 10^9/l$ (reference range $5.2\text{--}12.5 \times 10^9/l$) with left shift of the neutrophils. The patient was medically managed with supportive care for 24 h including intravenous fluid therapy with compound sodium lactate (Hartmann's solution, Aquapharm, Animalcare Limited, UK) at 4 ml/kg/h divided into slow intravenous boluses. Multimodal analgesia was provided with buprenorphine (Buprecare

0.3 mg/ml, Animalcare Limited, UK) at 0.03 mg/kg subcutaneously every 6 h alongside a nonsteroidal anti-inflammatory drug, meloxicam (Metacam 1.5 mg/ml, Oral Suspension, Boehringer Ingelheim, Germany) at 0.6 mg/kg per every 12 h. Gastrointestinal prokinetic therapy was provided with ranitidine (Zantac 15 mg/ml, GlaxoSmithKline, UK) at 4 mg/kg per os every 12 h and cisapride (Cisapride 5 mg/ml, Summit, UK) at 0.5 mg/kg per os every 12 h. Assisted feeding with an herbivore critical care food (Critical Care Herbivore, Oxbow Animal Health, USA) 25 ml was provided per os every 4 h.

2 | IMAGING FINDINGS, DIAGNOSIS, AND OUTCOME

To investigate causes of gut stasis, a helical-64-slice whole body computed tomographic (CT) study (Somatom Definition AS Siemens, Erlangen, Germany) was performed without sedation, and with restraint provided by a VetMouseTrap (Universal Medical Systems Inc, Solon, USA). Scan settings included a pitch of 1.5, tube potential of 120 kVp, reference tube current of 160 mA, slice thickness of 1.5 mm, matrix 512×512 , and reconstruction with low and high frequency algorithms. Scan tube current was modulated by an automatic

[The copyright line for this article was changed on 5 March 2018 after original online publication.]

This is an open access article under the terms of the Creative Commons Attribution License, which permits use, distribution and reproduction in any medium, provided the original work is properly cited.

© 2018 The Authors. *Veterinary Radiology & Ultrasound* published by Wiley Periodicals, Inc. on behalf of American College of Veterinary Radiology

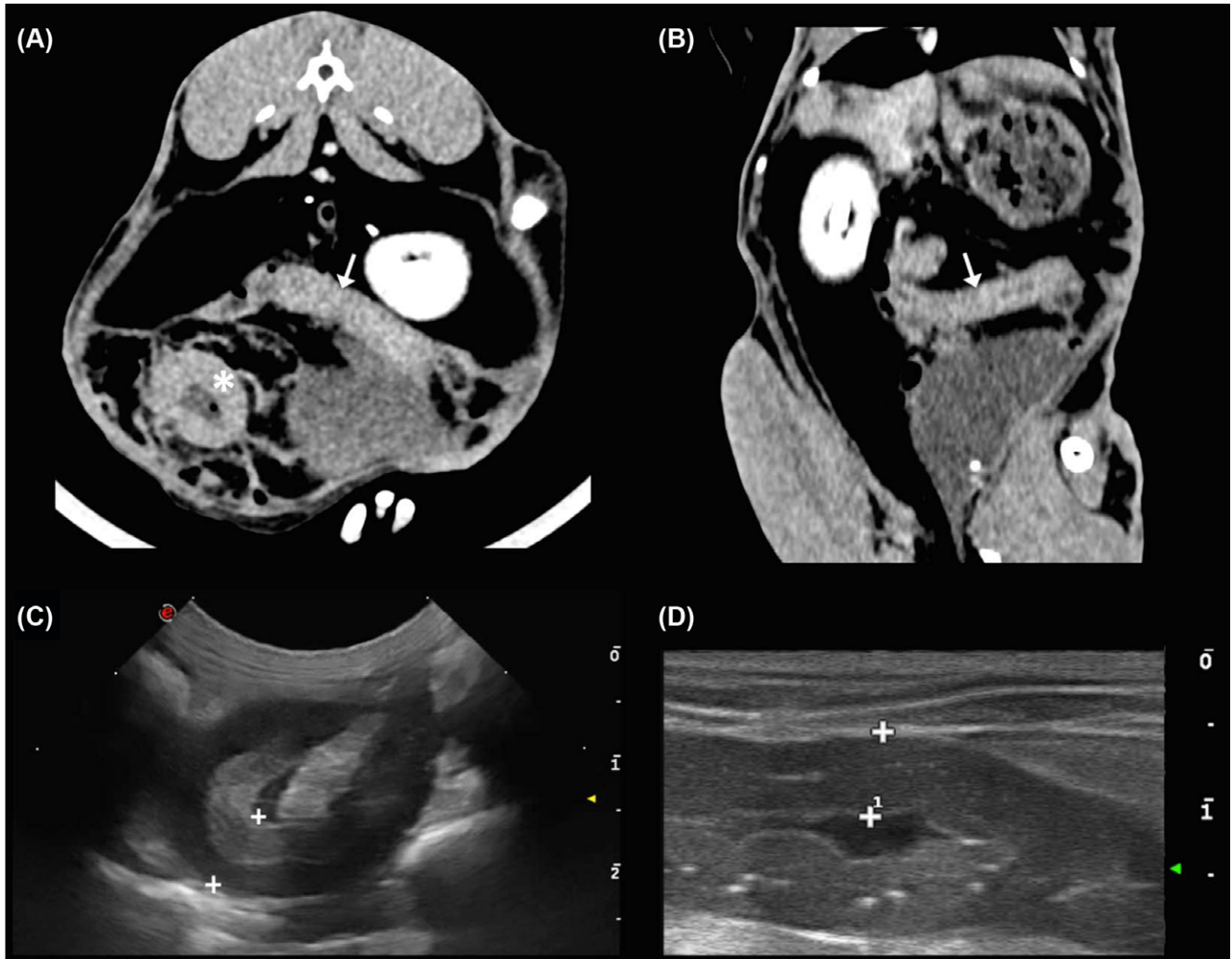


FIGURE 1 Postcontrast computed tomographic image of the sacculus rotundus (*) and appendix (arrowhead) in transverse (A) and dorsal plane (B). B-mode ultrasound image of the sacculus rotundus (C) (8 MHz, wall thickness 0.8 cm), with anechoic and gas content, and of the appendix (D) (14 MHz, wall thickness 0.6 cm) showing multifocal mucosal speckles and thickened wall (between callipers) [Correction added on 5 March 2018 after first online publication: the position of figures 1 and 2 have been reversed in the text. They were originally published out of order and with incorrect captions.]

exposure control system (Care Dose 4D, Siemens Medical Solutions, International). Postcontrast images were acquired within 1 min after contrast injection and reconstructed with a low frequency algorithm. A bolus of 740 mg Iodine/kg of nonionic iodinated contrast medium (Iopamiro, Bracco, Manno, Switzerland) was manually injected through an auricular angiocatheter followed by 1.5 ml of saline solution flush. On postcontrast images, a round fluid-filled structure delineated by a contrast-enhancing wall was detected in the right caudoventral abdomen along the lesser curvature of the cecum (Figure 1A and B). This saccular structure contained a small amount of gas and its lumen projected into the cecal lumen, which was consistent with the location of the sacculus rotundus. Its wall was markedly thickened (0.77 cm). Within the left mid-ventral abdomen, an elongated and thickened (wall thickness 0.4 cm, Figure 1A and B) blind-ending tubular structure was visible connected to the cecum, consistent with the appendix. Mild peritoneal effusion and moderate mesenteric lymphadenopathy (1.2 cm in width) were also identified. The presumptive CT diagnosis

was sacculitis and appendicitis, with associated reactive local lymphadenopathy and mild inflammatory peritoneal effusion. Abdominal B-mode ultrasound was performed (MyLab Twice Esaote, Genova, Italy) with microconvex (SC 3123) and electronic linear (LA 435) array probes, with frequencies ranging between 8–14 MHz. Ultrasound examination confirmed the markedly thickened wall of the sacculus rotundus (0.8 cm) located dorsal to the cecum, without loss of wall layering (Figure 1C). A distinct inner mucosal layer was detected, however heterogeneously hyperechoic and markedly thickened, while the outer layer was hypoechoic (Figure 1C). Moreover, the appendix had a moderately thickened wall (0.6 cm) containing numerous hyperechoic speckles (Figure 1D). At this stage, an inflammatory noninfectious or infectious sacculitis and appendicitis was suspected, while neoplastic infiltration was considered less likely due to the extension of the infiltration and the young age of the animal. Considering the ongoing anorexia, with lack of response to medical treatment and the high risk of dysbiosis, an exploratory laparotomy was recommended.

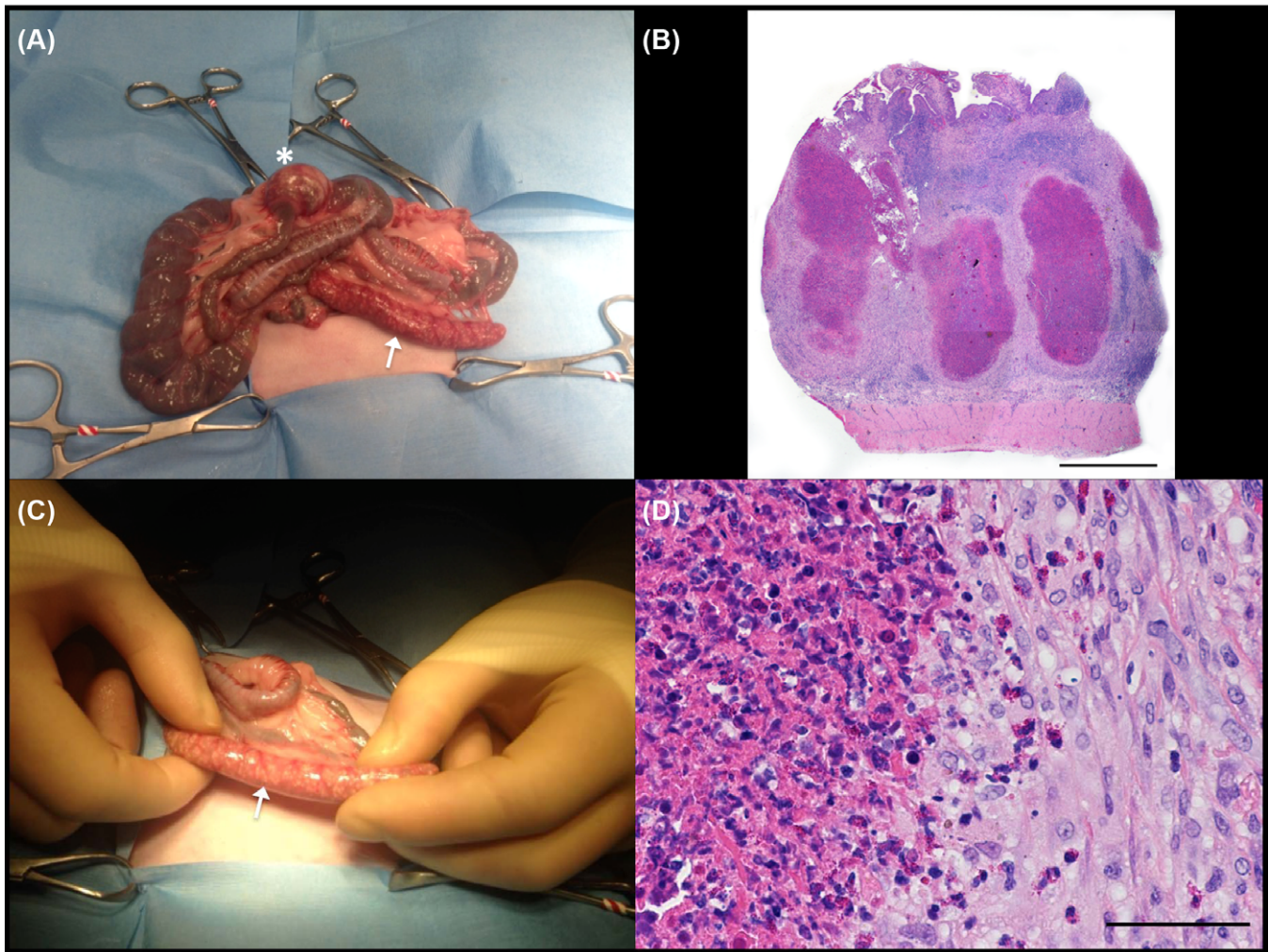


FIGURE 2 Intraoperative picture of the appendix (arrow) and sacculus rotundus (asterisk) (A). Histological presentation of the appendix, with multifocal necrotic granulomas (B, scale bar = 1000 μm , Hematoxylin & Eosin). Intraoperative picture of the multifocal wall microabscesses visible at the level of the appendix (C). Appendix granuloma with necrotic core, a rim of macrophages and neutrophils (D, scale bar = 50 μm , Hematoxylin & Eosin) [Correction added on 5 March 2018 after first online publication: the position of figures 1 and 2 have been reversed in the text. They were originally published out of order and with incorrect captions.]

At surgery, the segmental thickening was confined to both the sacculus rotundus and appendix, with no evidence of wall defect (Figure 2A and C). Multifocal micro-abscesses were spread throughout the wall (Figure 2A and C). Full thickness biopsies were taken from the sacculus rotundus and appendix walls. A firm, pedunculated, irregular nodule extending into the sacculus rotundus lumen was also excised. Samples were sent for bacteriology and histopathology. Culture of the biopsied tissues was negative for specific fungal or bacterial growth, but rather a light, mixed bacterial growth with no predominant organism was identified at the level of the appendix (nonspecific growth). On histopathology, multifocal, 500–2000 μm wide, round to oval lesions were scattered in the submucosa of the sacculus rotundus and appendix (Figure 2B and D). These lesions had a large, central area of lytic necrosis, with loss of cellular detail, hypereosinophilia, and accumulation of cytoplasmic and nuclear debris. Around the necrotic core, there was a poorly defined, thick rim of infiltration by large numbers of macrophages, with very rare bi-nucleated forms and scattered neutrophils. The gut-associated lymphoid tissue was diffusely prominent (lymphoid hyperplasia). There was moderate diffused infiltration

of the lamina propria by lymphocytes and plasma cells, and there was trans-epithelial transmigration of the mucosal epithelium by small to moderate numbers of heterophils. This presentation led to a histological diagnosis of severe, chronic, multifocal granulomatous sacculitis, and appendicitis with necrotic heterophilic granuloma formation. Warthin Starry (silver) and Ziehl Neelsen stains did not reveal specific infectious agents, and bacterial infection was considered a possible differential diagnosis.

Supportive treatment was continued, and additional oral antibiotics with trimethoprim sulphate (Sulfatrim 96 mg/ml, Virbac, UK) at 15 mg/kg per os every 12 h and metronidazole (200 mg/5ml, Lexon, UK) at 20 mg/kg per os every 12 h, were added to the previous medical therapy. The patient recovered uneventfully from surgery, with normal gut sounds within 24 h and was discharged after 48 h. At 5 days postdischarge, the owner reported progressive return to spontaneous eating and normal defecation. At 4 weeks follow-up, complete regression of the clinical signs was obtained and complete blood counts were within normal limits. A follow-up abdominal ultrasound revealed a moderate decrease in wall thickness of the sacculus

rotundus (0.56 cm), although a focal heterogeneous area most likely consistent with the previous biopsy site was detected. The appendix appeared partially evaluable and gas-filled. At 6 weeks ultrasonographic follow-up, the wall of the sacculus rotundus (0.3 cm) and appendix were markedly reduced in thickness, with normal wall layering and echogenicity.

3 | DISCUSSION

This case highlights the important roles of CT and ultrasound as complementary modalities for investigating gut stasis in rabbits. Presumptive sacculitis and appendicitis was diagnosed on CT based on focal wall thickening of a saccular structure connected to the cecum. To the authors' knowledge, the CT appearance of the sacculus rotundus and appendix has never been described in the veterinary literature. Moreover, only a single old reference describing the presence of granulomatous appendicitis in rabbits was found.¹

Further ultrasonographic examination of the abdomen provided important additional information confirming the exact location and nature of the lesion, affecting both the sacculus rotundus and the appendix. In this patient, the wall thickening of the appendix and sacculus rotundus measured more than twice the normal limits reported on ultrasound.² Furthermore the diffuse thickening, preserved layering, and mucosal speckles prompted the presumptive diagnosis of inflammatory or infectious disease. A neoplastic process, such as round cell tumor, was considered less likely because of the young age of the patient and extensive intestinal infiltrative changes without loss of wall layering. As previously reported in cats, abnormalities detected on ultrasonography or endoscopy at the level of the ileoceocolic junction should encourage histology for further evaluation. Histopathology was performed in this case to confirm the imaging diagnosis.³

Due to the lack of information in the literature on the normal CT appearance of the sacculus rotundus and appendix, ultrasonography was a crucial complementary tool to confirm the nature of the lesion. Both structures are small and challenging to detect on B-mode abdominal ultrasound. They can be located in the mid-ventral abdomen at the level of the umbilical region; however, the proximity of the cecum hinders identification of these structures due to the distal acoustic shadowing and gas reverberation from the adjacent cecal content. In a previous study of 21 healthy mixed-breed dwarf rabbits, the sacculus rotundus was detected in 14/21 patients, while the appendix was always visible.² In the authors' experience, the location of the sacculus rotundus on CT is similar in most rabbits in the right caudoventral abdomen along the lesser curvature of the cecum and it remains visible in most of animals, while a normal appendix is often more challenging to identify.

The rabbit cecum is a highly developed and differentiated organ, compared to the cecum of other species, such as dogs and cats.⁴⁻⁷ The sacculus rotundus is an ampullar distension of the intestine representing the distal end of the ileum, located on the first haustral-like pouch of the corpus ceci. The appendix is located at the caudal tip of the cecum, similar to humans.⁸⁻¹¹ In Angora rabbits, the sacculus rotundus is described to have a thick wall with a wide lumen, short thick villi, large amount of crypts, and numerous lymphoid follicles.⁵ Moreover, on histopathology it differed from other parts of the diges-

tive system and was considered a novel lymphoid organ, because of its high dense lymphoid accumulation.^{5,11} The 'vermiform' appendix of the rabbit plays a fundamental role for development of the primary (preimmune) antibody repertoire. It partially atrophies with age in this species however it is fundamental for the immunological development of gut-associated lymphoid tissues.¹¹

Despite representing one of the most common surgical diseases in children, to the authors' knowledge, spontaneous sacculitis and appendicitis in rabbits has only been reported once before.^{12,13} A previous old publication described the histopathological findings in 25 with rabbits affected by granulomatous appendicitis, with similar findings in the sacculus rotundus.¹ In a more recent publication, an experimental model of appendicitis was created by ligating the appendix of rabbits in view of measuring blood markers of acute appendicitis.¹⁴ Medical treatment is commonly included as a suitable alternative in humans in nonacute and nonperforated cases of appendicitis.³ In the rabbit of this case report, the clinical signs of gastrointestinal stasis and anorexia were believed to be secondary to the disease. This was further supported by the prompt response to medical treatment postsurgical diagnostic biopsies and the complete regression of clinical and ultrasonographic abnormalities 6 weeks after diagnosis.

The authors speculate that the presence of intramural microabscesses is supportive of a potential infectious process as the trigger of the inflammation. Despite specific stains, no infectious agents were identified, and culture yielded a light mixed growth, but no specific prominent organism. A bacterial cause was considered a possibility given the biopsy results, pyrexia, and neutrophilia. Clostridiosis was highly unlikely due to the atypical localization of the lesions and lack of necrohemorrhagic lesions.

In conclusion, granulomatous sacculitis and appendicitis should be included among the potential causes of gastrointestinal stasis in rabbits. In the authors' opinion, the sacculus rotundus and appendix should always be assessed during CT or ultrasonographic abdominal examinations of the rabbit, especially in young patients presenting for gastrointestinal stasis.

LIST OF AUTHOR CONTRIBUTIONS

Category 1

- (a) Conception and Design: Longo M, Thierry F, Richardson J, Schwarz T
- (b) Acquisition of Data: Longo M, Thierry F, Richardson J, Eatwell K, Pozo Jd
- (c) Analysis and Interpretation of Data: Longo M, Thierry F, Eatwell K, Schwarz T, Pozo Jd, Richardson J

Category 2

- (a) Drafting the Article: Longo M
- (b) Revising Article for Intellectual Content: Longo M, Thierry F, Eatwell K, Schwarz T, Pozo Jd, Richardson J

Category 3

- (a) Final Approval of the Completed Article: Longo M, Thierry F, Eatwell K, Schwarz T, Pozo Jd, Richardson J

ACKNOWLEDGMENT

The authors would like to thank Dr. Emma Keeble for her kind assistance with the case.

ORCID

Maurizio Longo  <http://orcid.org/0000-0002-6838-8430>

Florence Thierry  <http://orcid.org/0000-0003-4175-4397>

REFERENCES

1. Fujiwara H, Uchida K, Takahashi M. Occurrence of granulomatous appendicitis in rabbits. *Jikken Dobutsu*. 1987;36:277–80.
2. Banzato T, Bellini L, Contiero B, Selleri P, Zotti A. Abdominal ultrasound features and reference values in 21 healthy rabbits. *Vet Rec*. 2015;176:101.
3. Hahn H, Pey P, Baril A, et al. Ultrasonographic, endoscopic and histological appearances of the caecum in cats presenting with chronic clinical signs of caecocolic disease. *J Feline Med Surg*. 2017;19:94–104.
4. Snipes RL. Anatomy of the rabbit cecum. *Anat Embryol (Berl)*. 1978;155:57–80.
5. Besoluk K, Eken E, Sura E. A morphological and morphometrical study on the sacculus rotundus and ileum of the Angora rabbit. *Vet Med*. 2006;51:60–65.
6. Harriet H, Freiche V, Baril A, et al. Ultrasonographic, endoscopic and histological appearance of the caecum in clinically healthy cats. *J Feline Med Surg*. 2017;19:85–93.
7. Barone R. Intestine. In: Barone R, ed. *Comparative Anatomy of Domestic Mammals. Tome 3. Splanchnology*. Paris: Vigot; 1997:385.
8. Snipes RL. Anatomy of the rabbit cecum. *Anat Embryol*. 1978;1:57–80.
9. Lord C, Broadhurst J, Sleight S, McGee S, Wills M. The appendix: A spectrum of benign and malignant disease. *Br J Hosp Med*. 2017;78:82–87.
10. Popesko P, Rajtová V, Horák J. *A Colour Atlas of Anatomy of Small Laboratory Animals*. Vol 1. Philadelphia: Saunders; 2002:p91.
11. Dasso JF, Obiakor H, Bach H, Anderson AO, Mage RG. A morphological and immunohistological study of the human and rabbit appendix for comparison with the avian bursa. *Dev Comp Immunol*. 2000;24:797–814.
12. López JJ, Deans KJ, Minneci PC. Nonoperative management of appendicitis in children. *Curr Opin Pediatr*. 2017;29:358–362.
13. Adolph VR, Falterman KW. Appendicitis in children in the managed care era. *J Pediatr Surg*. 1996;31:1035–1036.
14. Katz E, Hana R, Jurim O, Pisuv G, Gutman A, Durst AL. Experimental model of acute appendicitis in the rabbit with determination of leucine amino peptidase (LAP) and acid phosphatase (acid-P) activities in portal blood samples. *J Surg Res*. 1990;48:230–236.

How to cite this article: Longo M, Thierry F, Eatwell K, Schwarz T, Pozo Jd, Richardson J. Ultrasound and computed tomography of sacculitis and appendicitis in a rabbit. *Vet Radiol Ultrasound*. 2018;1–5. <https://doi.org/10.1111/vru.12602>