

Journal section: Oral Surgery
Publication Types: Research

doi:10.4317/medoral.16.e552
<http://dx.doi.org/doi:10.4317/medoral.16.e552>

Pilomatrixoma. Review of 205 cases

Rosa Guinot-Moya ¹, Eduard Valmaseda-Castellon ², Leonardo Berini-Aytes ³, Cosme Gay-Escoda ⁴

¹ DDS. Master of Oral Surgery and Implantology. Barcelona University Dental School

² DDS, PhD. Professor of Oral Surgery. Professor of the Master of Oral Surgery and Implantology. Barcelona University Dental School. Researcher of the IDIBELL Institute

³ MD, DDS, PhD. Oral and maxillofacial surgeon. Professor of Oral and Maxillofacial Surgery. Professor of the Master of Oral Surgery and Implantology. Barcelona University Dental School. Researcher of the IDIBELL Institute

⁴ MD, DDS, PhD. Oral and maxillofacial surgeon. Chairman of Oral and Maxillofacial Surgery. Director of the Master of Oral Surgery and Implantology. Barcelona University Dental School. Head of the Service of Oral and Maxillofacial Surgery, Teknon Medical Center. Barcelona (Spain). Researcher of the IDIBELL Institute

Correspondence:

Centro Medico Teknon
Vilana 12
08022 – Barcelona (Spain)
cgay@ub.edu

Guinot-Moya R, Valmaseda-Castellon E, Berini-Aytes L, Gay-Escoda C.
Pilomatrixoma. Review of 205 cases. Med Oral Patol Oral Cir Bucal. 2011
Jul 1;16 (4):e552-5.
<http://www.medicinaoral.com/medoralfree01/v16i4/medoralv16i4p552.pdf>

Received: 07/04/2010
Accepted: 10/05/2010

Article Number: 17039 <http://www.medicinaoral.com/>
© Medicina Oral S. L. C.I.F. B 96689336 - pISSN 1698-4447 - eISSN: 1698-6946
eMail: medicina@medicinaoral.com
Indexed in:
Science Citation Index Expanded
Journal Citation Reports
Index Medicus, MEDLINE, PubMed
Scopus, Embase and Emcare
Indice Médico Español

Abstract

Aims: To determine the incidence and clinical features of patients diagnosed with pilomatrixoma.

Patients and Method: A retrospective analysis was made of 205 cases of pilomatrixoma diagnosed according to clinical and histological criteria, with an evaluation of the incidence, patient age at presentation, gender, lesion location and size, single or multiple presentation, differential diagnosis, histopathological and clinical findings and relapses.

Results: Pilomatrixoma was seen to account for 1.04% of all benign skin lesions. It tended to present in pediatric patients – almost 50% corresponding to individuals under 20 years of age – with a slight male predilection (107/98). Approximately 75% of all cases presented as single lesions measuring less than 15 mm in diameter. Multiple presentations were seen in 2.43% of cases. The most frequent locations were the head and orofacial zones (particularly the parotid region), with over 50% of all cases, followed by the upper (23.9%) and lower limbs (12.7%). Only one relapse was documented following simple lesion excision.

Conclusions: The frequency of pilomatrixomas was 1.04% of all benign skin lesions – the lesions being predominantly located in the maxillofacial area. Due to the benign features of this disorder, simple removal of the lesion is considered to be the treatment of choice, and is associated with a very low relapse rate.

Key words: Pilomatrixoma, benign skin tumor, maxillofacial pathology.

Introduction

The term pilomatrixoma was introduced by Forbis and Helwing (1) in 1961, in reference to a hair cell-derived lesion that up until that time had been known as Malherbe’s calcifying epithelioma (2). Following histochemical and electron microscopic studies, the idea that these lesions derived from sebaceous glands was discarded, and the neoplasm was shown to derive from the primitive basal cells of the epidermis. The lesions are posteriorly found in the dermis or in the subcutaneous tissues, and differentiate towards hair matrix cells with uncontrolled tumor-type proliferation (3). Pilomatrixoma is classified as a benign skin appendage tumor belonging to the group of suborganoid tumors with hair differentiation (4). Clinically the tumor is hard, well circumscribed, slow-growing and mobile in the early stages. It is usually covered by skin of normal appearance, though in some cases there may be skin color changes secondary to epithelial thinning, or even ulceration. The lesion usually produces no symptoms, though some patients may experience pain in response to palpation, or itching. Pilomatrixoma may be located in any part of the body except the palms and soles, and shows a predilection for the maxillofacial region. The aim of the present study was to determine the incidence and the clinical and histological characteristics of 205 patients with skin lesions diagnosed as pilomatrixoma.

Patients and Methods

A retrospective review was made of 222,319 histological samples from Vall d’Hebron General University Hospital (Barcelona, Spain), documenting a total of 179 established cases of pilomatrixoma in the period between 1972-1988. In addition, 26 lesions diagnosed as corresponding to pilomatrixoma were prospectively identified in Granollers General Hospital and the Teknon Medical Center (Barcelona, Spain) between the years 1989 and 2005.

The following data were collected from the clinical files: patient age at presentation, gender, lesion location and size, possible etiological parameters, single or multiple presentation, differential diagnosis, histopathological features and relapses.

A descriptive statistical study was made using the Statistical Package for the Social Sciences (SPSS version 12.0; SPSS, Chicago, USA; license of the University of Barcelona).

Results

In order to determine the incidence of this lesion, we limited the analysis to the cases gathered from the retrospective review of the 222.319 histological samples from Vall d’Hebron General Hospital. Of these samples, 17,091 were classified as benign skin tumors. Our series of pilomatrixomas accounted for 0.08% of the global surgical pathology of this hospital center. Focusing only on benign dermatological lesions, the corresponding incidence was 1.04%. The mean patient age was 27 years (range 6 months - 79 years), and in 46.4% of the cases the diagnosis was established in the first two decades of life (Fig. 1).

A total of 201 patients (98%) were caucasians, three were black and one was asian. A slight male predilection was observed in our series: 98 females (47.8%) and 107 males (52.2%).

The lesion diameter at presentation ranged from 1-50 mm, though a full 154 cases (75.1%) were less than 15 mm in size (Fig. 2).

Three patients reported previous insect bites in the affected area, while two had shown intradermoreaction (vaccine), two cases were preceded by traumatisms, and one patient presented a history of alopecia areata.

Of the global 205 cases, 200 represented solitary presentations (97.56%), while 5 (2.43%) consisted of multiple lesions. Among the latter, four patients presented two pilomatrixomas, while only one patient presented three lesions.

The location of the lesions is shown in table 1, and their clinical appearance can be seen in fig. 3.

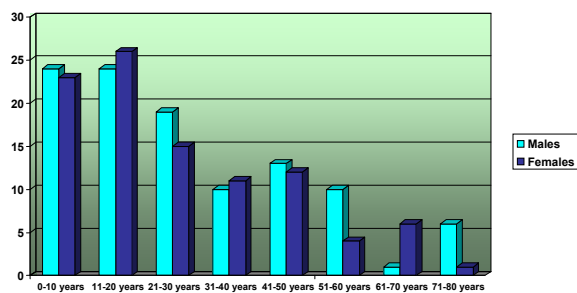


Fig. 1. Patient distribution by age groups and gender.

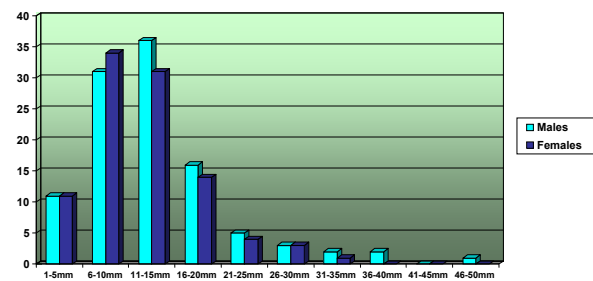


Fig. 2. Lesion size distribution in relation to patient gender.

Table 1. Locations of pilomatrixoma. Note that the total number of lesions is 211, since 4 patients presented multiple pilomatrixomas.

Location		No. of cases	Percentage (%)
Cervico-maxillofacial region	Preauricular	36	17.1
	Nasogenian	19	9.0
	Scalp	9	4.3
	Palpebral	5	2.4
	Other facial zones	4	1.9
	Neck	41	19.4
Limbs	Arms	54	25.6
	Legs	29	13.7
Other areas		14	6.6

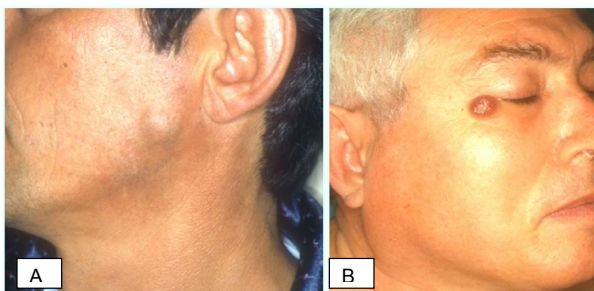

Fig. 3. Clinical appearance of two pilomatrixomas: one in the parotid region (A) and the other in the lower palpebral zone (B).

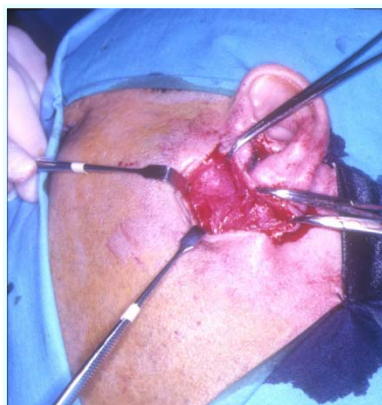


Fig. 4. Resection of a pilomatrixoma in the parotid region.

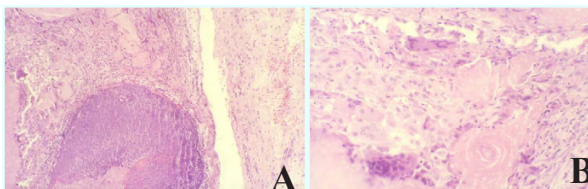


Fig. 5. Histological section of the skin, showing a circumscribed and well delimited subepidermal nodular lesion (A). Under higher magnification (B), intense monomorphic and monolayer basal cell proliferation is seen. No cellular atypias are observed. The basal cell proliferation involves abrupt keratinization, with the appearance of shadow or phantom cells. Surrounding the keratinized zones are epithelioid cells and giant multinucleated cells in the context of a foreign body reaction.

Simple resection was carried out in all cases fig. 4, followed by a single relapse. No malignant transformations were reported.

The histological study showed a generally circumscribed and well delimited subepidermal nodular tumor consisting of a proliferation of monomorphic and monolayered basophilic cells, without atypias. These cells tended to evolve towards phantom cells, and areas of variable keratinization and calcification were observed. Multinucleated cells participating in foreign body reactions were identified surrounding the phantom cells and keratinized zones (Fig. 5).

Discussion

Pilomatrixoma is a relatively infrequent tumor, with a highly variable incidence depending on the literature source. In our series, the incidence was 1.04% of all benign skin tumors, while other authors (5,6) have reported figures of between 0.001% and 0.0031% of all dermatological histology specimens. Such discrepancy reflects the variability of the data sources involved in the different series published to date (5,6).

While pilomatrixoma can develop at any age, two maximum frequency peaks have been identified: one in the pediatric age range and the other in the sixth decade of life (7). Our results are similar to those reported by other investigators (5-8). As to the gender distribution of these tumors, we recorded a slight male predilection, unlike other authors who report a predominance among females (5,6,8,9).

The etiology of pilomatrixoma is subject to controversy. In coincidence with Forbis and Helwing (1), we recorded antecedents of traumatism, insect bites or surgery – though in only a very low proportion of cases (3.9%). Unlike other authors (5), we observed no familial presentations – though the retrospective study design involved would have made it difficult to detect any such pattern.

The most frequent locations were the head and maxillofacial zones (particularly the facial region), in coincidence with the observations of other case series (5,6,8,10). The locations were followed in decreasing or-

der of frequency by the upper limbs, legs and trunk. The most commonly affected facial zone is the preauricular (parotid) region, followed by the nasogenian zone (11). While pilomatrixoma generally manifests as a single lesion, multiple pilomatrixomas in one same individual were observed in 2.43% of our cases – in coincidence with the reports found in the literature (1,6,8).

The diagnosis of pilomatrixoma is fundamentally clinical, though complementary studies are needed to establish a differential diagnosis with other lesions such as dermal and subcutaneous masses (sebaceous cysts, epidermoid cysts, basal cell epitheliomas and neurofibromas), calcified lesions (calcified epidermoid cyst, foreign body reactions or calcified hematomas) and, in the specific case of preauricular lesions, primary and secondary parotid gland tumor pathology (12,13).

The routinely requested diagnostic test is a plain soft-tissue radiographic study, which sometimes reveals tenuous radiopaque and diffusely distributed lesions. Computed tomography (CT) offers important advantages particularly in those cases where tumor exeresis may place other structures at risk – as in the preauricular region. In some cases selective external carotid angiography may be needed to rule out the presence of a vascular tumor in this territory (14). Other authors (15,16) recommend ultrasound for diagnosing pilomatrixoma in children, since it is noninvasive, rapid and inexpensive, and offers reliable imaging that can be of help in planning the treatment strategy.

The treatment of pilomatrixoma comprises simple tumor resection (17). Relapses are probably due to incomplete removal of the lesion, with a rate of 2-6% (1). This range exceeds the relapse rate recorded in our series (0.48%). In some cases, due to the volume of the lesion, or in the presence of adherences to the epidermis, skin grafts may be required to cover the resection defect. Other authors have proposed oral retinoid administration after successfully controlling a case of multiple pilomatrixomas in a dog (18).

The malignization of pilomatrixoma is rare. In the literature some 60 cases of malignant transformation have been documented to date. The principal indicators of malignancy are cellular pleomorphism, frequent mitotic figures and atypias, central necrosis and infiltration of the skin, soft tissues and lymphatic and vascular elements. The malignant version of pilomatrixoma is more frequent in males (with a 3:1 predominance over females) and in elderly individuals (60% are over 40 years of age). The location of malignant pilomatrixoma shows the same distribution as the benign version of the tumor. Once the diagnosis has been confirmed, management consists of radical excision with adequate resection margins, due to the high associated relapse rate (49% of controlled cases) (15,19,20). In our series no malignant variants were diagnosed.

Distant metastases are rare, with only 6 cases described

to date in the literature. Patient survival in such cases has been 3-18 months from the time of diagnosis of metastatic disease (15,20).

Conclusions

The frequency of pilomatrixomas in our series was 1.04% among all benign skin lesions. This entity was predominantly located in the maxillofacial area, it therefore being essential for dentists to be familiarized with these lesions. Due to the benign nature of pilomatrixomas, simple removal of the lesion is considered to be the treatment of choice, with a very low relapse rate.

References

References with links to Crossref- DOI

- Forbis R Jr, Helwig EB. Pilomatrixoma (calcifying epithelioma). *Arch Dermatol.* 1961;83:606-18.
- Malherbe A, Chenantais J. Note sur l'epitheliome calcifié des glandes sebacées. *Prog Med.* 1880;8:826-8.
- O'Grady RB, Spoerl G. Pilomatrixoma (benign calcifying epithelioma of Malherbe). *Ophthalmology.* 1981;88:1196-7.
- Hashimoto K. Calcifying epithelioma of Malherbe: an electron microscopic study. *J Appl Physiol.* 1965;36:2067.
- Moehlenbeck FW. Pilomatrixoma (calcifying epithelioma). A statistical study. *Arch Dermatol.* 1973;108:532-4.
- Hauss H. Epithelioma calcifians (Malherbe). *Dermatol Wschr.* 1962;145:209-23.
- González M, Giner J, Ordóñez V, Maniegas L, Martín-Granizo R. Pilomatrixoma o epitelioma calcificante de Malherbe. *Rev Esp Cirug Oral y Maxilofac.* 2003;25:233-8.
- Geiser JD. [Malherbe's calcified epithelioma]. *Ann Dermatol Syphiligr (Paris).* 1959;86:383-403.
- Danielson-Cohen A, Lin SJ, Hughes CA, An YH, Maddalozzo J. Head and neck pilomatrixoma in children. *Arch Otolaryngol Head Neck Surg.* 2001;127:1481-3.
- Duflo S, Nicollas R, Roman S, Magalon G, Triglia JM. Pilomatrixoma of the head and neck in children: a study of 38 cases and a review of the literature. *Arch Otolaryngol Head Neck Surg.* 1998;124:1239-42.
- Berini-Aytés L, Gay-Escoda C, Ayuso-Ruiz M. Pilomatrixoma de la región parotídea. *Arch Odontostomatol.* 1989;5:145-9.
- Gay Escoda C, Domínguez Rodríguez JR. [Cervical lymph nodes tuberculosis]. *An Otorrinolaringol Ibero Am.* 1979;6:203-15.
- Gay-Escoda C, Costa X, Berini-Aytés L. Patología quirúrgica de la glándula submaxilar. *Rev Esp Estomatol.* 1982;3:197-210.
- Brandner MD, Bunkis J. Pilomatrixoma presenting as a parotid mass. *Plast Reconstr Surg.* 1986;78:518-21.
- Mikhaeel NG, Spittle MF. Malignant pilomatrixoma with multiple local recurrences and distant metastases: a case report and review of the literature. *Clin Oncol (R Coll Radiol).* 2001;13:386-9.
- Hwang JY, Lee SW, Lee SM. The common ultrasonographic features of pilomatrixoma. *J Ultrasound Med.* 2005;24:1397-402.
- Pirouzmanesh A, Reinisch JF, Gonzalez-Gomez I, Smith EM, Meara JG. Pilomatrixoma: a review of 346 cases. *Plast Reconstr Surg.* 2003;112:1784-9.
- Toma S, Noli C. Isotretinoin in the treatment of multiple benign pilomatrixomas in a mixed-breed dog. *Vet Dermatol.* 2005;16:346-50.
- Julian CG, Bowers PW. A clinical review of 209 pilomatrixomas. *J Am Acad Dermatol.* 1998;39:191-5.
- Bremnes RM, Kvamme JM, Stalsberg H, Jacobsen EA. Pilomatrix carcinoma with multiple metastases: report of a case and review of the literature. *Eur J Cancer.* 1999;35:433-7.