

PDF hosted at the Radboud Repository of the Radboud University Nijmegen

The following full text is a publisher's version.

For additional information about this publication click this link.

<http://hdl.handle.net/2066/21359>

Please be advised that this information was generated on 2021-09-19 and may be subject to change.

Poly-(L-Lactic) Acid Membranes in Palatal Surgery in Beagle Dogs: Clinical and Histologic Evaluation

MARCEL M.H. IN DE BRAEKT, D.D.S. PH.D.
JAAP C. MALTHA, PH.D.
ANNE M. KUIJPERS-JAGTMAN, D.D.S., PH.D.

This article reports on the histologic findings from a larger study that was designed to investigate whether the attachment of scar tissue to underlying bone, which is normally found after palatal surgery, can be prevented by using biodegradable poly-(L-lactic) acid membranes. Von Langenbeck's procedure was simulated in 12-week-old beagle dogs without clefts. In one group normal wound healing was allowed. In two groups, membranes were inserted immediately after surgery or 3 weeks thereafter. Sham and control groups were also included. Histologic evaluation was carried out at regular intervals. Reports have been published on other aspects, such as clinical wound healing, contraction and maxillary arch development in beagle dogs following this treatment. After direct implantation of membranes, wound healing was retarded. Disintegration of the membranes started soon after implantation and remaining particles were surrounded by a fibroblastic sheath and a fibrous capsule. At sites where membrane particles persisted, attachment of the scar tissue to the underlying bone by Sharpey's fibers was prevented.

KEY WORDS: *palatal surgery, poly-(L-lactic) acid membrane, scar tissue, wound healing*

Von Langenbeck's technique is widely accepted for the primary closure of palatal clefts. In this technique, bilateral palatal relaxation incisions are made in the mucoperiosteum adjacent to the posterior teeth. The mucoperiosteum is then elevated, mobilized, and moved to the midline region of the palate in order to close the defect. This procedure results in two areas of denuded bone in the lateral regions of the palate (Millard, 1980). Normally these areas are left open to heal by secondary intention. In time, wound contraction, as well as outgrowth of epithelium and connective tissue from the wound margins, decrease the wound surface.

Maxillary growth and dento-alveolar development are found to be impaired after primary palatal surgery. Wound contraction, which occurs predominantly during the first week of wound healing (Olin Jr. et al., 1974; Kahnberg and Thilander, 1982; Kremenak, 1984; Wijdeveld et al., 1987a,b), is considered one of the factors causing this disturbance in maxillary growth (Kremenak, 1984; Wijdeveld et al., 1987a). Myofibroblasts are thought to contribute to this process

(Gabbiani and Ryan, 1971; Dabelsteen and Kremenak, 1978). Later, epithelial cell proliferation is the predominant factor in wound healing. Besides wound contraction, the newly formed scar tissue might also be a principal factor for growth disturbances (Ross, 1987). Collagenous fibers in the scar tissue are mainly oriented in a transverse direction, in contrast to the three-dimensional network in the normal mucoperiosteum. The tissue remains different from normal mucoperiosteum as it lacks elastic fibers (Squier and Kremenak, 1982; Wijdeveld et al., 1991) and it becomes continuous with the periodontal ligament. Scar tissue becomes attached to the underlying bone by Sharpey's fibers (Wijdeveld et al., 1991) and its rigidity might play an important role in the impairment of maxillary growth and dento-alveolar development after palatal surgery (Wijdeveld et al., 1989, 1991). Other authors (Bardach, 1990; Dixit et al., 1992) are of the opinion that lip closure, not palatal surgery, is the main reason for growth disturbances. Wijdeveld et al. (1989) showed, however, that palatal surgery itself is detrimental for the development of the maxillary permanent dental arch.

Our study was designed to evaluate the effect of a biocompatible and biodegradable membrane on the prevention of scar tissue attachment to the palatal bone. The membrane functions as a temporary barrier between the mucoperiosteum and the palatal bone in order to facilitate undisturbed transverse maxillary dental arch development. To achieve this goal, poly-(L-lactic) acid (PLLA) membranes were prepared by an immersion precipitation technique and inserted, either directly after surgery, or 3 weeks later when wound healing was

Dr. In de Braekt is an Orthodontist in private practice in Nijmegen. Dr. Maltha is Associate Professor in Oral Biology, Department of Orthodontics and Oral Histology, University of Nijmegen, The Netherlands. Dr. Kuijpers-Jagtman is Professor in Orthodontics, Department of Orthodontics and Oral Histology, University of Nijmegen, The Netherlands.

Submitted February 1992; Accepted February 1995.

Reprint requests: Dr. Jaap C. Maltha, Department of Orthodontics and Oral Histology, University of Nijmegen, Ph. van Leydenlaan 25, 6525 EX Nijmegen, The Netherlands.

completed. Wound healing and tissue reactions were clinically and histologically evaluated.

MATERIALS AND METHODS

Surgical Procedure

A total of 38 beagle dogs were assigned to five groups: one control group (C, $n = 4$), in which no surgery at all was performed, and four experimental groups (L, $n = 8$; LS, $n = 4$; LMD, $n = 16$; and LMI, $n = 6$). Animals in all groups received a hard diet during the whole experimental period. Palatal surgery according to Von Langenbeck was simulated in all experimental groups at 12 weeks of age, which is approximately 5 weeks after completion of the deciduous dentition, and 6 weeks prior to the transition to the mixed dentition (Kremenak Jr, 1967). The animals of the control group were also 12 weeks of age at the start of the experiment. The design of the study is shown in Table 1.

Prior to surgery, the animals were premedicated with 0.5 mL Thalamonal (fentanyl 0.05 mg/mL + droperidol 2.5 mg/mL) and 0.5 mL Atropine (atropine Sulfate 0.5 mg/mL). Subsequently, they were placed under general anesthesia with an intravenous injection of 15 mg/kg Nesdonal® (thiopental sodium 50 mg/mL). After intubation, anesthesia was maintained with Ethrane®. The dentition and oral mucosa were cleaned with chlorhexidine gluconate 1% in water followed by injections of Xylocaine® (lidocaine hydrochloride 0.4 mg/mL + adrenaline 1:100,000) in the palatal mucoperiosteum to prevent excessive bleeding during surgery.

An elliptical soft tissue defect was made surgically in the midline region of the palate, by incising and removing a mucoperiosteal flap that had a width of one-third of the transverse distance of the first deciduous molars and extended distally from the cuspids to the region of the hard palate distally of the third deciduous molars. Additionally, relaxation incisions were made on both sides of the palate parallel to the posterior dental arch at a distance of 2 to 3 mm from the teeth. With a raspator, the palatal mucoperiosteum was elevated and mobilized, carefully avoiding damage to the major palatine neurovascular bundle. The two mobilized mucoperiosteal flaps were repositioned in the midline region of the palate and sutured with Vicryl 4-0, thus closing the soft tissue defect. Consequently, denuded bony areas were left in the lateral regions of the palate (Fig. 1). For a detailed

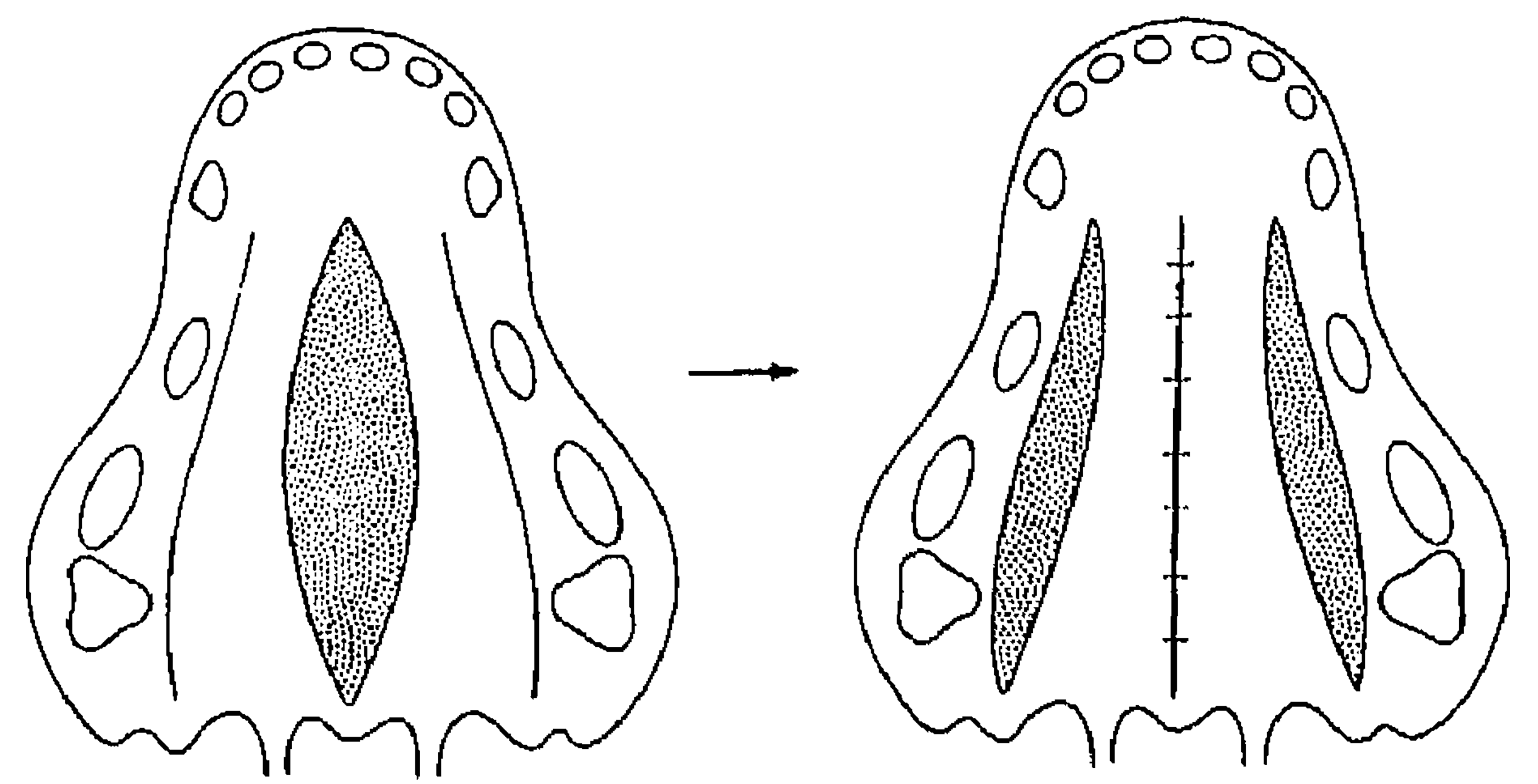


FIGURE 1 Schematic drawing of the palate and the surgical procedure. A mucoperiosteal flap was removed in the midline region of the palate and two relaxation incisions were made. The remaining palatal mucoperiosteum was elevated, repositioned, and sutured in the midline.

description of the surgical procedure see Wijdeveld et al. (1987a). In Group L animals, the denuded bony areas were left open to heal by secondary intention.

Poly-(L-lactic) acid membranes were manufactured by immersion precipitation (Strathmann, 1979; In de Braekt, 1991). In order to prepare flat membranes, a 5% w/w poly-(L-lactic) acid solution in a mixture of chloroform and toluene (60/40 w/w) was prepared at room temperature. From this solution, films with a thickness of 400 μm were cast on a glass plate using a so-called "Doctor's blade," a type of knife like that used to remove excess ink from an engraving. Immediately after casting, the films were immersed into a methanol bath to precipitate the polymer. In this immersion precipitation process, a membrane with a highly porous structure was formed. The mean thickness of the membrane was 110 μm . The pores in the membrane are extensively interconnected and have diameters in the range of 0.5 μm to 1 μm . Prior to use, the poly-(L-lactic) acid membranes were rinsed for half a minute in 1% chlorhexidine gluconate in water for disinfection, followed by half an hour in sterile physiologic saline.

Group LMD animals had poly-(L-lactic) acid membranes implanted directly after surgery. The membranes were cut to shape with a pair of scissors and were placed on the bone and a few millimeters underneath the wound margins. The membranes were glued to the wound margins with Histoacryl (Cyanoacrylate) to prevent shifting during wound healing. The wound defect was left open to heal by secondary intention. Group L was regarded as the sham group for Group LMD to determine the effect of the surgery itself.

In animals of Groups LS and LMI, wound healing was allowed for 3 weeks. Then, under general anesthesia as described above, a transverse incision of approximately 7 mm was made in the cuspid region at both sides of the palate in both groups. With a small raspator, the scar tissue of the former denuded bony areas was elevated from the bone.

TABLE 1 Age in Weeks at Time of Treatment

Group	N	Von Langenbeck	PLLA Membrane	Membrane Sham	Sacrifice*
C	4	—	—	—	18,27
L	8	12	—	—	13,14,19,25
LS	4	12	—	15	19,25
LMD	16	12	12	—	13,14,15,16,17,19,25,37
LMI	6	12	15	—	19,25,37

*The animals were sacrificed in pairs.

In animals of Group LMI, disinfected PLLA membranes, shaped with a pair of scissors, were moved underneath the elevated scar tissue. The incisions were sutured with Vicryl 4-0. In Group LS animals the elevated scar tissue was repositioned and the remaining incision was sutured with Vicryl 4-0. Group LS was used as the sham group for group LMI to evaluate the effect of incising, elevating, and repositioning scar tissue in the former denuded bony areas.

All experimental animals were medicated with 1 mL of Albipen 15% (ampicillin anhydrate 150 mg/mL) immediately after surgery, and maintenance doses of 1 mL Albipen LA (ampicillin anhydrate 100 mg/mL) the second and fourth day postoperatively. Wound healing was observed clinically at regular intervals until completion.

For histologic evaluation, the animals were sacrificed in pairs (see Table 1). The animals of the control group were sacrificed at 18 and 27 weeks of age; the animals of Group L at 13, 14, 19, and 25 weeks of age; the animals in Group LS at 19 and 25 weeks of age; the animals of Group LMD at 13, 14, 15, 16, 17, 19, 25, and 37 weeks of age; and the animals of Group LMI at the age of 19, 25, and 37 weeks.

After premedication with Thalamonal, the animals were placed under general anesthesia using 30 mg/kg Narcovet, after which 0.5 mg/kg heparin (Thromboliquine) was administered. After 3 to 5 minutes, a lethal dose of Narcovet was injected intravenously. The vascular system was perfused with physiologic saline, followed by 4% neutral formaldehyde as a fixative. After perfusion, the maxillae were dissected and immersed in 4% neutral formaldehyde for another 2 weeks. They were then sawed into smaller blocks, which were decalcified in 20% formic acid and 5% sodium citrate, dehydrated, and embedded in Paraplast. Serial frontal sections of 7 μ m were prepared and stained with hematoxylin and eosin for general survey. Selected sections were stained according to Taenzer-Unna, for the study of elastic fibers (Lillie, 1965). A modified Herovici polychrome staining was used for the study of young (Type III) and old (Type I) collagen (Herovici, 1963; Levame and Meyer, 1987).

The other half of the blocks of experimental groups LMD and LMI, in which PLLA membranes were implanted, was left undecalcified. They were dehydrated in graded series of ethanol with 2.5% glycerol, infiltrated with glycol methacrylate in ethanol and 2.5% glycerol and embedded in glycol methacrylate and polyethyleneglycol (Blaauw et al., 1987). Frontal 4 μ m sections were cut using glass knives. The sections were stained with Sudan black and toluidine blue-basic fuchsin (Hoeksma et al., 1988).

RESULTS

Clinical Observations

The wound healing process, in experimental groups L, LS, and LMI in which initially no membrane was placed, was normal and uncomplicated in the first 3 weeks after surgery. Initially, the wound margins were red-colored and a fibrin

clot was evident. After 1 week, the wound surface area had clearly become smaller due to wound contraction and epithelialization. The opposite wound margins fused in the middle, or somewhat medially, to the former denuded bony area after 2 weeks; smooth scar tissue remained without palatal rugae. The midline region of the palate showed a thin line of scar tissue.

In animals of Group LMI, 3 weeks postoperatively (i.e., after wound closure was completed) the scar tissue was incised and elevated from the bone and membranes were implanted. The remaining small transverse incision in the cuspid region closed without complications within 1 week. The same held true for Group LS. The animals of group LMD, in which implantation of the membranes was performed directly after Von Langenbeck's surgery, showed a slower wound healing than the animals of Groups L, LS, and LMI. Postoperatively mild inflammatory reactions were apparent in approximately 80% of the animals of Group LMD. The wound margins were red-colored and somewhat swollen. The membrane was visible through the coagulum. Wound contraction and epithelialization reduced the wound surface area. At the end of the first week, fusion of the wound margins had begun at the caudal and proximal regions of the defect. After 2 to 3 weeks, the epithelium had become continuous over most of the surface of the former wound. Some mild inflammatory signs were still present in most of the animals after 4 weeks.

At the end of the observation period (i.e., 24 weeks postoperatively) all wound defects were closed and smooth scar tissue was present.

Histologic Observations

Group C ($n = 4$)

The superficial layer of the palatal mucoperiosteum consisted of parakeratotic stratified squamous epithelium with many villi protruding into the underlying connective tissue. The connective tissue layer, immediately below the epithelium, consisted mainly of a three-dimensional network of coarse collagen Type I fibers. In deeper layers, sagittally oriented collagenous fibers became more predominant and elastic fibers were randomly distributed, especially near capillaries and larger blood vessels. Throughout the mucoperiosteum, sagittally oriented large blood vessels and sinuses were present in the deeper layers of the connective tissue (Figs. 2 and 3). Between these sinuses, the major palatine arteries and branches of the palatine nerves were located at the lateral aspect of the palate.

In the 18-week-old animals, the periosteal layer was thick and cell rich. Active osteoblasts were found on the whole surfaces and in the midpalatal suture, depositing trabecular bone. In animals 27 weeks of age, the periosteal layer was restricted to a thin cellular layer consisting mainly of resting osteoblasts. The fibrous layer of the periosteum was attached to the underlying bone by thin collagen Type I fibers. The palatal bone was lamellar and bone deposition was not found on the palatal bone nor in the midpalatal suture.

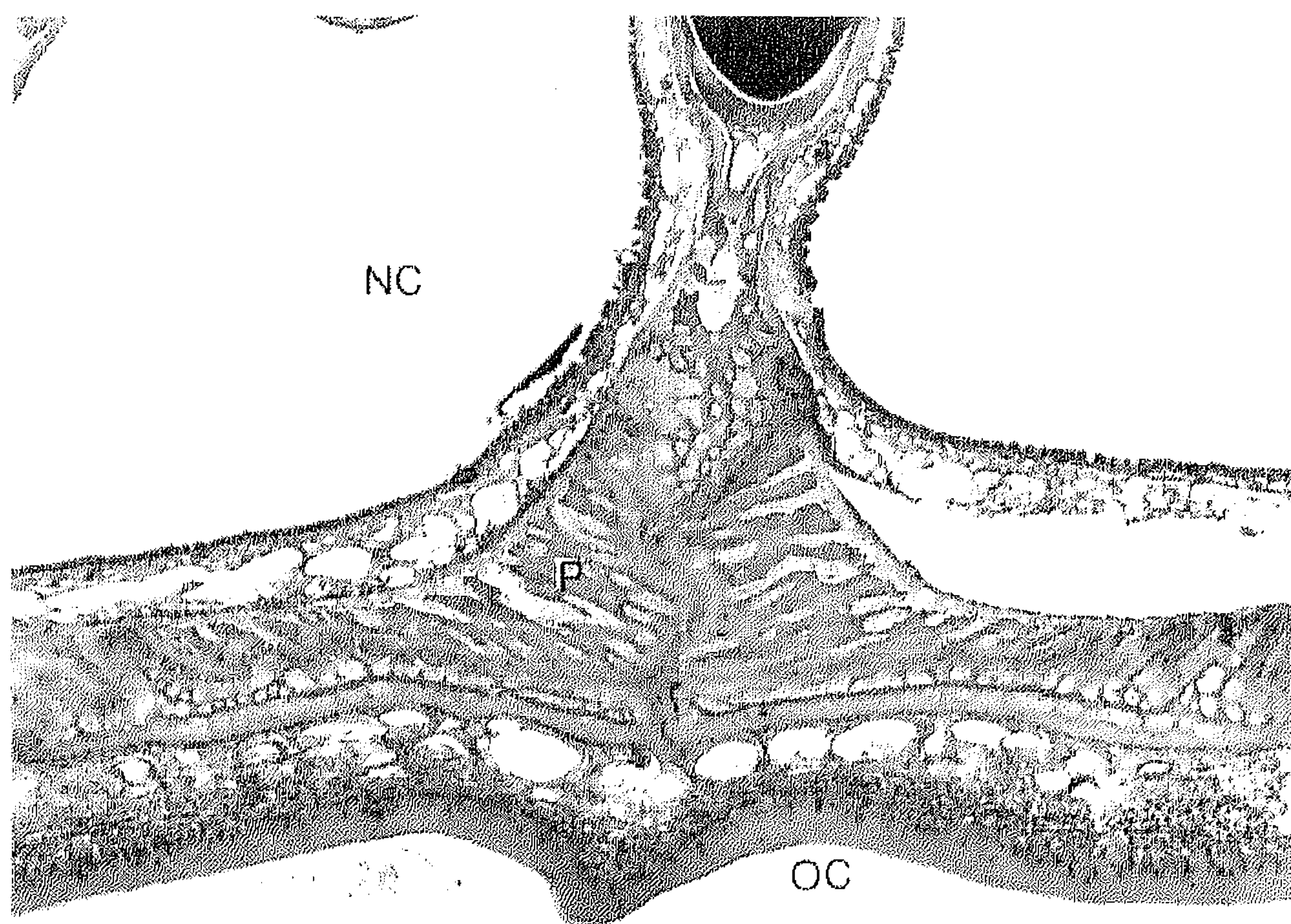


FIGURE 2 Transverse section of the midline region of the normal mucoperiosteum in control animals at 18 weeks of age. OC = oral cavity, P = palatal bone, NC = nasal cavity, H and E staining, magnification 18 \times .

The palatal mucoperiosteum was continuous with the periodontal ligament in all control animals. The cervical periodontal fibers were fanning out into the deeper layers of the palatal connective tissue. In the youngest animals, bone deposition was found on palatal as well as buccal aspects of the alveolar socket, indicating continuing eruptive movements. In the older animals, neither bone deposition nor bone resorption was found.

Group L (n = 8)

One week after surgery, at 13 weeks of age, the epithelium did not completely cover the denuded bony areas. The epithelium

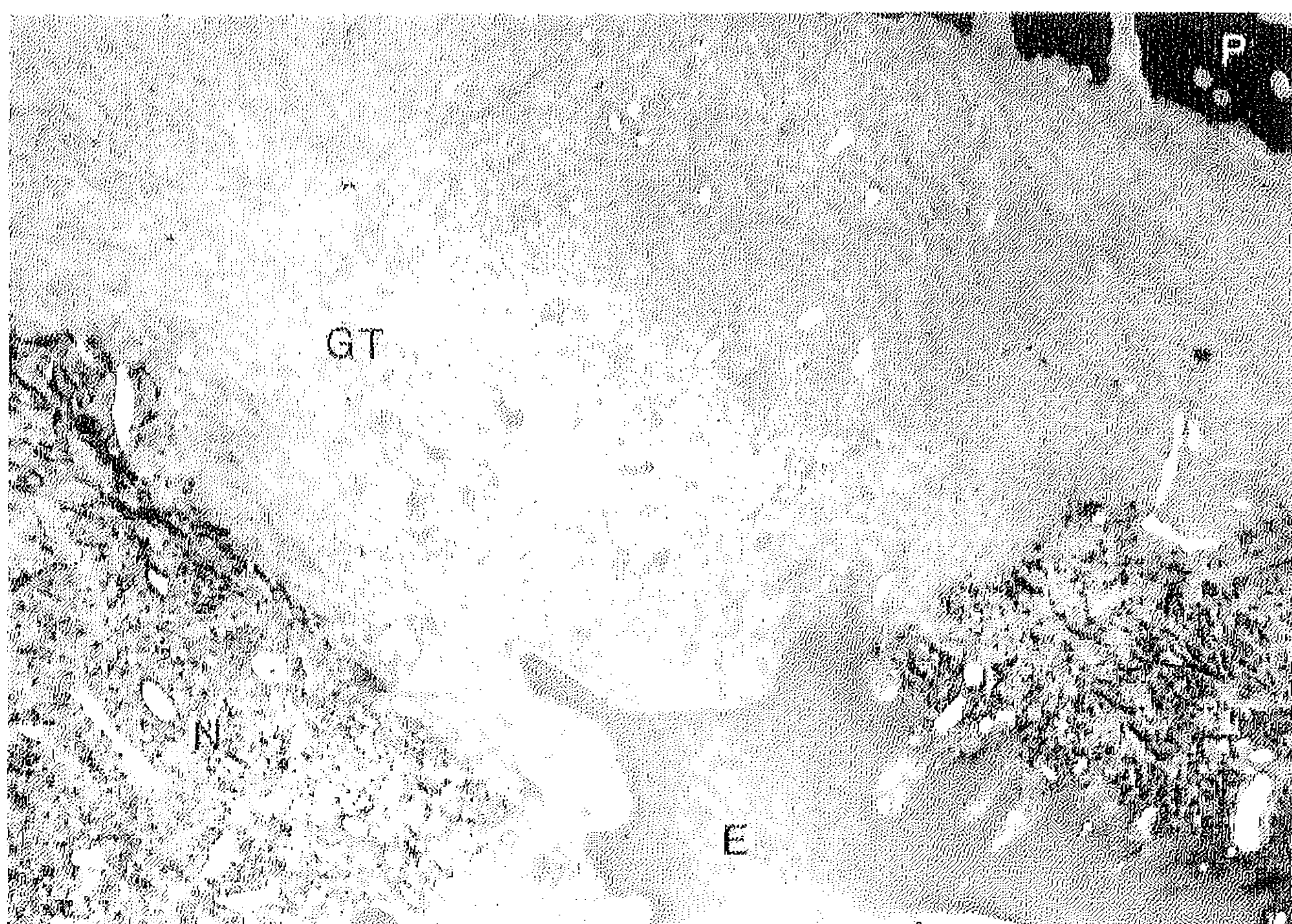


FIGURE 4 Frontal section of the operative area at 1 week after surgery in an animal of Group L. In this area the wound is already completely epithelialized. N = normal mucoperiosteum, GT = granulation tissue at the former denuded bony area, E = epithelium, P = palatal bone, Herovici staining, magnification 45 \times .

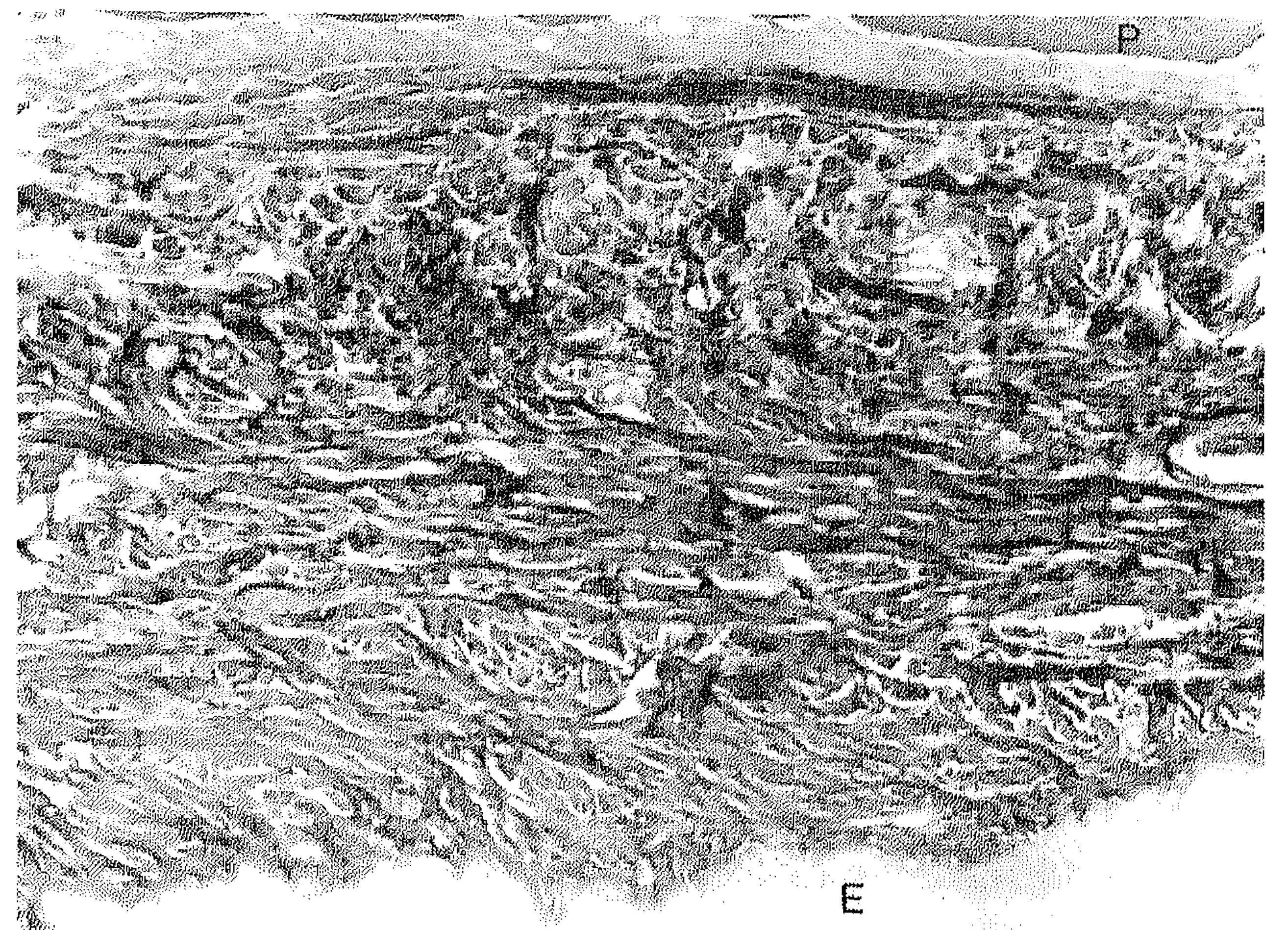


FIGURE 3 Transverse section of the normal mucoperiosteum showing a three-dimensional network of coarse collagenous fibers immediately below the epithelium. In deeper layers, sagittally oriented collagenous fibers are more predominant. E = epithelium, P = palatal bone, Herovici staining, magnification 110 \times .

was proliferating from both wound margins and was not yet keratinized. Hyperemic granulation tissue infiltrated with polymorphonuclear leukocytes, lymphocytes, plasma cells, and macrophages covered the underlying palatal bone. Herovici staining indicated collagen Type III fibers without a distinct orientation. No elastic fibers were present in the healing tissue (Figs. 4 and 5).

The mucoperiosteum that had remained after surgery had normal appearance. The blood sinuses and major palatine arteries and nerves were displaced medially by surgery. The palatal bone was lined with a thick cell-rich periosteum containing few inflammatory cells. Active osteoblasts and trabecular bone deposition were found along the palatal bone, except for

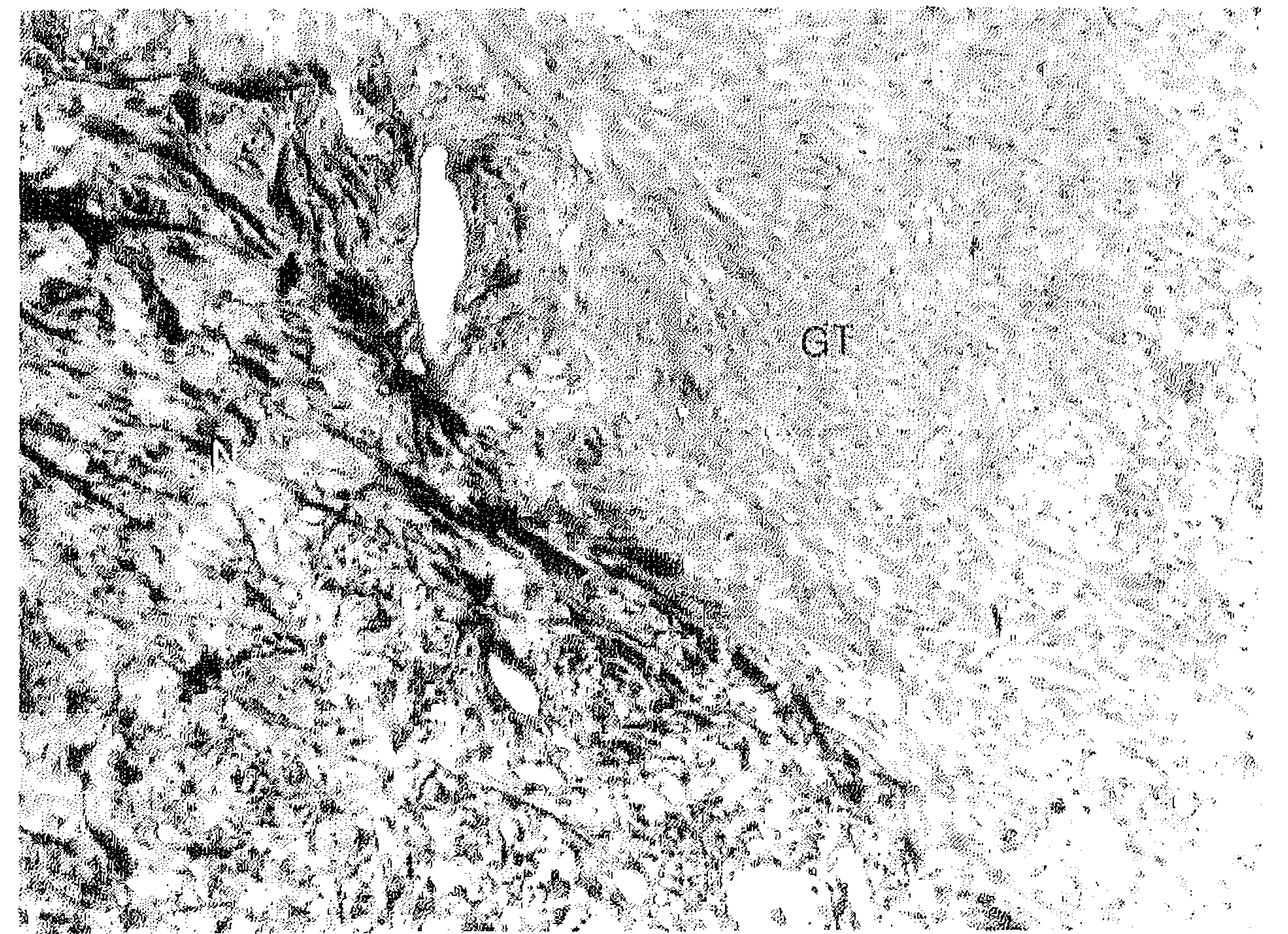


FIGURE 5 Detail of Figure 4 showing the borderline between the normal mucoperiosteum (N) and the granulation tissue (GT). In the granulation tissue Type III collagenous fiber, without a distinct orientation, are predominant, while in the normal mucoperiosteum Type I fibers prevail. Herovici staining, magnification 110 \times .

some lateral parts of the palate where osteoclastic resorption was found. No periodontal fibers were fanning out into the healing tissue.

Two weeks after surgery, at 14 weeks of age, the epithelium at the denuded bony areas was continuous and consisted of parakeratotic stratified squamous epithelium. The epithelium was thinner, however, and showed fewer protruding villi compared with the epithelium covering the normal mucoperiosteum. The granulation tissue underneath the epithelium was still hyperemic, and inflammatory cells were present. Thin collagen Type III fibers were gradually replaced by thicker collagen Type I fibers, starting at the former wound margins. They were mainly oriented mediolaterally. No elastic fibers were found in the healing tissue (Fig. 6).

The former mobilized mucoperiosteal flaps located in the midline region of the palate showed a normal appearance. A thin periosteum covered the bone and trabecular bone deposition was found along a resting line which demarcated the bone surface at the moment of surgery. In the region of the formerly denuded bony areas, however, apart from osteoblastic bone deposition, some osteoclastic resorption was observed. This resulted in differences in the net amount of bone deposited after surgery, demarcated by the resting line, in those regions of the palate. Simultaneously with the bone deposition, thick collagen Type I fibers were embedded in the palatal bone as Sharpey's fibers. Formation of collagenous fibers in the cervical part of the periodontal ligament was observed. These fibers were embedded in the cementum and fanned out into the gingiva and palatal connective tissue. In some cases, osteoclastic bone resorption took place in the cervicopalatal region of the alveolar socket.

Seven weeks after surgery, at 19 weeks of age, the epithelial layer in the former denuded bony areas was somewhat thicker than in earlier stages, but it was still thinner than in

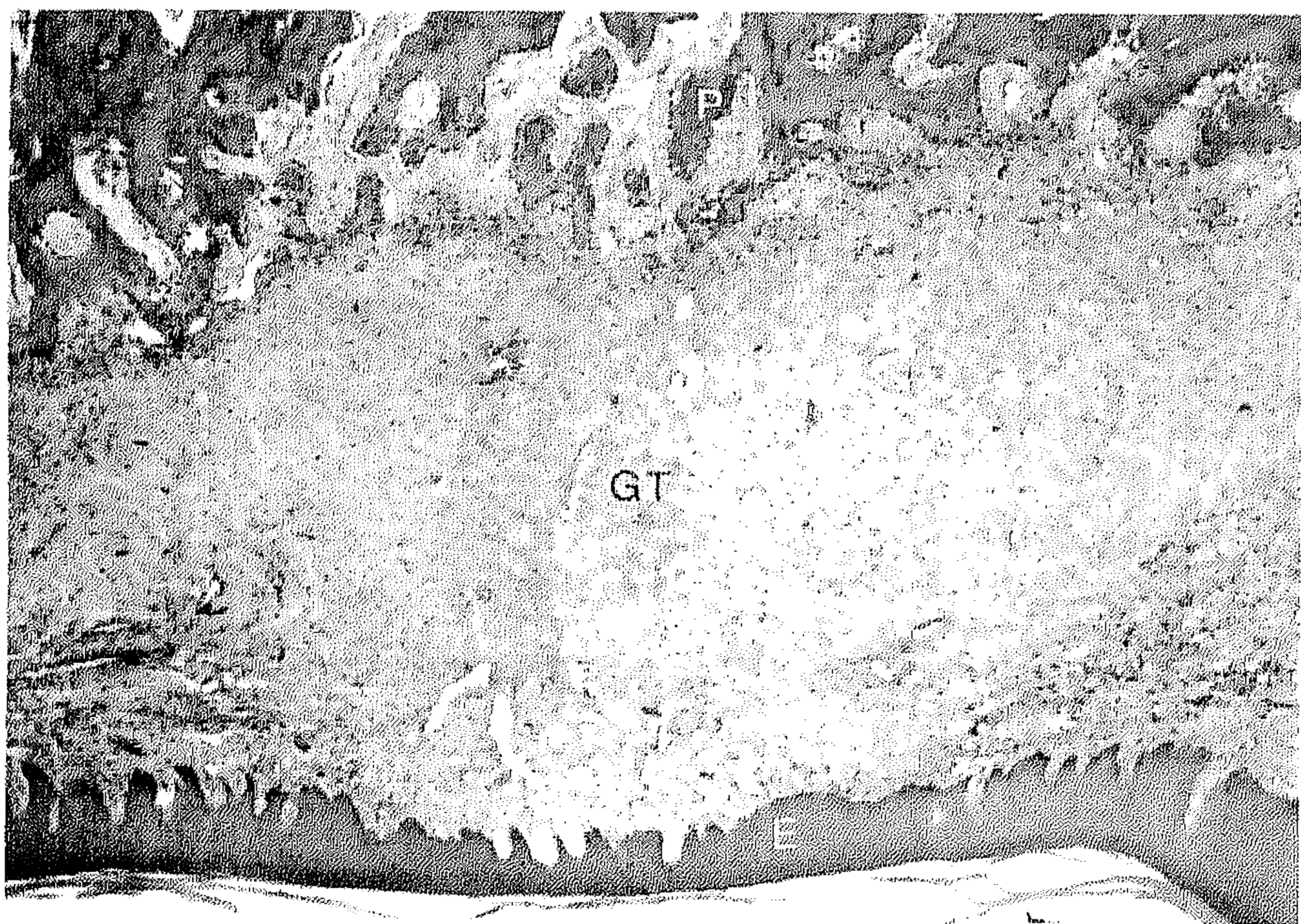


FIGURE 6 Two weeks after surgery, the epithelium over the formerly denuded bony areas was continuous and consisted of parakeratotic, stratified, squamous epithelium (E). The epithelium was thinner and showed fewer protruding villi compared with the epithelium covering the normal mucoperiosteum. GT = granulation tissue, P = palatal bone, H and E staining, magnification 45 \times .

the control animals of that age. The mediolaterally oriented collagenous fibers were gradually replaced by thicker fibers but Type III collagen was still predominant. The rate of trabecular bone deposition had decreased, but some active osteoblasts were still present in marrow spaces. Sharpey's fibers at the formerly denuded bony areas were more predominant than in the earlier stages of wound healing. Cervical periodontal fibers were fanning out into the deeper layers of the mucoperiosteum. The connection of the gingival tissue to the alveolar bone was disturbed by the erupting premolar of which the tip had already emerged from the alveolar bone.

The last stage histologically evaluated, was at 25 weeks of age and was highly comparable with the stage described previously. The epithelial layer was still somewhat thinner in the operated areas than in the normal mucoperiosteum. The underlying connective tissue contained mainly transverse oriented collagenous fibers which resembled in structure the fibers in normal mucoperiosteum, but elastic fibers were still absent. Distinct attachment of the scar tissue to the palatal bone in the region of the former denuded bony areas by means of Sharpey's fibers was evident (Fig. 7). No bone deposition or resorption was found on the entire surface of the palatal bone. Only resting osteoblasts were present. Cervical periodontal fibers were seen fanning out from the cementum of the premolars to the palatal mucoperiosteum and the scar tissue. In some cases, osteoclasts were observed in the cervicopalatal region of the alveolar socket with corresponding bone resorption.

Group LS (n = 4)

At 19 weeks of age, 7 weeks after Von Langenbeck's surgery, and 4 weeks after severance of Sharpey's fibers, the continuous parakeratotic, stratified, squamous epithelium at the formerly denuded bony areas showed few villi penetrating the



FIGURE 7 Attachment of the scar tissue to the palatal bone in the region of the former denuded bony areas by means of Sharpey's fibers. P = palatal bone, M = mucoperiosteum. Polarization microscopy magnification 300 \times .

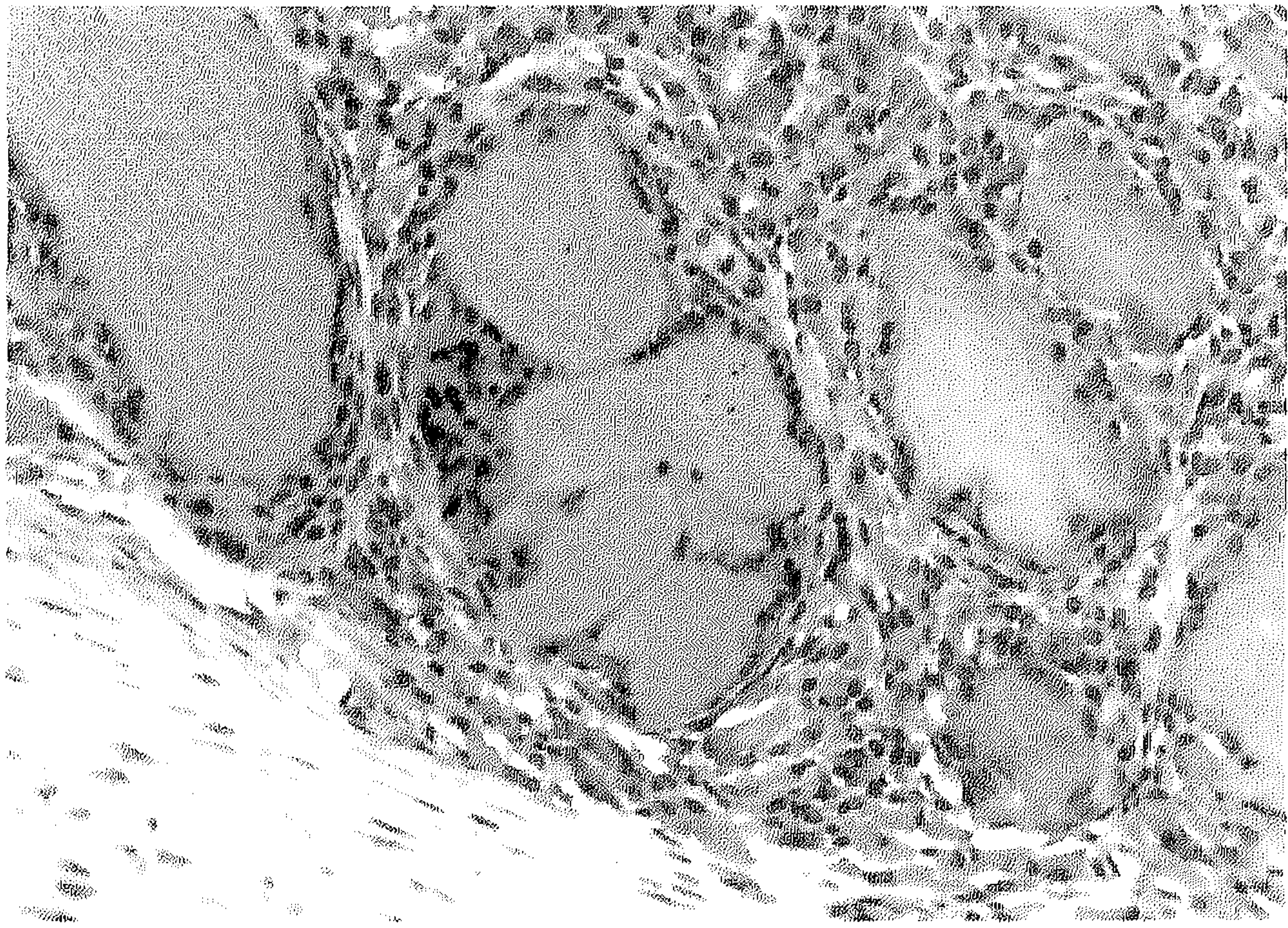


FIGURE 8 Clusters of PLLA fragments surrounded by a sheath of fibroblast-like cells. Outside this sheath, a capsule of fibrous connective tissue was found with circularly arranged collagenous fibers. Sudan black B staining, magnification 300 \times .

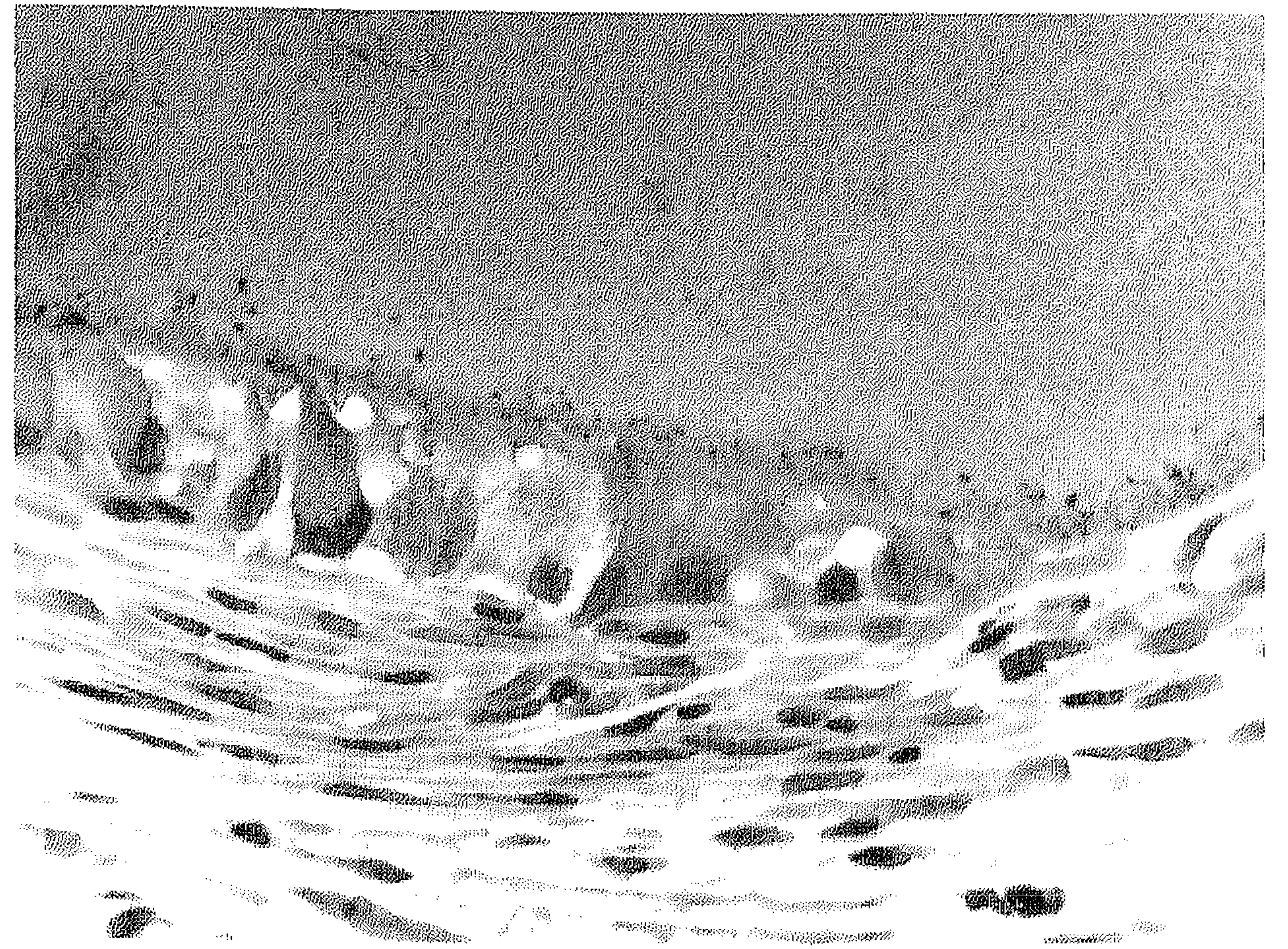


FIGURE 9 Detail of Figure 8 showing PLLA surrounded by fibroblasts and circularly arranged collagenous fibers. The PLLA is partly covered with macrophage-like cells. Sudan black B staining, magnification 750 \times .

underlying connective tissue. The thickness of the epithelial layer was more or less comparable with the epithelial layer of Group L in the same stage. The newly formed connective tissue layer underneath showed predominantly thin collagen Type III fibers with distinct transverse orientation. In some lateral parts of this connective tissue and at the border of the medial mucoperiosteal flaps, mediolateral collagen Type I fibers were found. Also in these areas, collagen Type III was still predominant. No elastic fibers were observed in the healing tissue.

The mucoperiosteal flaps in the midline region of the palate showed mostly the same features as in Group L. However, at the formerly denuded bony areas, no clear periosteal layer could be observed, as was described for the animals in Group L at this stage. Some active osteoblasts were still present in marrow spaces and the rate of trabecular bone deposition had decreased. No Sharpey's fibers were found. A resting line was observed as described for the animals in Group L.

Thirteen weeks after initial surgery, at 25 weeks of age, the histologic findings were comparable with the previous stage. However, between the previous and current stage, bone deposition was evident as demarcated by the resting line. Simultaneously, Sharpey's fiber formation was observed at the former wound edges, which obviously resulted in embedded thick collagenous fibers. In the center of the formerly denuded bony areas, no distinct Sharpey's fibers formation could be observed.

Group LMD (n = 16)

One week after surgery, at 13 weeks of age, the epithelium proliferated from both wound margins and did not completely cover the wounds at the denuded bony areas at this stage. Underneath the epithelial outgrowth, as well as in the wound defect, hyperemic granulation tissue with polymorphonuclear

leukocytes, plasma cells, lymphocytes, and macrophages surrounded the PLLA membrane that showed some cracks. Collagen Type III fiber formation had occurred without a distinct orientation as indicated by the modified Herovici staining. No elastic fibers were observed in the healing tissue.

In some cases, the PLLA membrane was fragmented into parts of 1 to 2 mm, especially in the formerly denuded bony areas. In most samples, however, the part of the membrane that was moved underneath the wound margins for a few millimeters, was still intact. All PLLA fragments were at least partly lined with active cells resembling macrophages, polymorphonuclear leukocytes, or multi-nucleated giant cells. The medially displaced mucoperiosteal flaps that had remained after surgery, showed their normal appearance and were comparable with Group L at the same stage.

Two weeks after surgery, at 14 weeks of age, in most samples the epithelial layer was continuous, although in some cases cellular infiltrates penetrating the wound defect were still observed. Thin collagen Type III fibers were oriented in a mediolaterally direction. No elastic fibers were present.

The PLLA fragments were the same size as in the previous stage, but in most cases, they were displaced medially and grouped together, each cluster being surrounded by a sheath of fibroblast-like cells. In few samples, focal infiltrates mainly consisting of macrophages, lymphocytes, and plasma cells, were found within this fibroblastic sheath. Outside the sheath, a capsule of connective tissue was found with circularly arranged collagenous fibers (Figs. 8 and 9). The collagenous fibers in the sheath were clearly less densely packed than in the capsule. No Sharpey's fibers connecting this capsule to the underlying bone were observed in any of the cases. At sites where membrane fragments were lacking, scar tissue and Sharpey's fibers embedded in the underlying bone were found.

A resting line, where growth was interrupted, demarcated the surface of the palatal bone at the time of surgery. Trabecular

bone deposition was observed on the palatal bone surface in the midline region of the palate. In the region of the formerly denuded bony areas, however, bone deposition had ceased at sites where membrane fragments, surrounded by their sheath, were adjacent to the bone. In a few samples, osteoclastic activity was found near the resting line. This resulted in an indentation of the palatal bone at sites where membrane fragments were located.

Three weeks after surgery, at 15 weeks of age, in most cases the epithelial layer was continuous and a few samples still demonstrated inflammatory reactions with cellular infiltrates containing mostly lymphocytes and plasma cells. The epithelial layer in this stage was thicker than in the previous one and a few villi protruded into the underlying connective tissue. The composition of the scar tissue was comparable to the previous stage except most of the thin collagen Type III fibers were replaced by thicker collagen Type I fibers.

The sizes and location of the PLLA fragments were the same as in the previous stages and the fibroblastic sheath was still present. In some cases, osteoblastic activity within the fibroblastic sheath resulted in bone deposition upon the PLLA fragments. In some samples, bone deposition at the edges of PLLA membrane fragments resulted in gradual incorporation of these fragments in the palatal bone.

Four weeks after surgery, at 16 weeks of age, the tissues were highly comparable with the previous stage. Epithelial continuity was evident in almost all samples and the mediolaterally oriented collagen Type III fibers were almost totally replaced by thicker collagen Type I fibers. From this stage on, the structure of the scar tissue remained essentially the same. The PLLA fragments showed the same features as described for the previous stage. The incorporation of the fragments in the palatal bone, however, had become more prominent since bone deposition was undisturbed in the regions where PLLA membrane fragments were lacking. In these regions with apparent bone deposition, Sharpey's fibers were observed.

Five weeks after surgery, at 17 weeks of age, no distinct differences could be observed regarding the amount, size, location, and fibroblastic sheath of the PLLA membrane fragments compared with the previous stages, but the incorporation of the PLLA fragments into the palatal bone had continued.

Seven weeks after surgery, at 19 weeks of age, not only were PLLA membrane fragments measuring 1 to 2 mm found, but also smaller fragments were present, the smallest ones measuring about 10 μm . The fragments were clustered and located more medially. They were at least partly lined with macrophages and polymorphonuclear leukocytes. It was not clear whether the smallest fragments were surrounded by several macrophages or had been ingested by multinucleated giant cells (Fig. 10). In the vicinity of the larger membrane fragments, many macrophages with ingested particles of PLLA were encountered. No Sharpey's fibers were present in the vicinity of the PLLA fragments. Some samples showed direct contact of the PLLA membrane fragments with the palatal bone. At sites where PLLA membrane fragments were present, no osteoblasts were found on the bone surface. In the

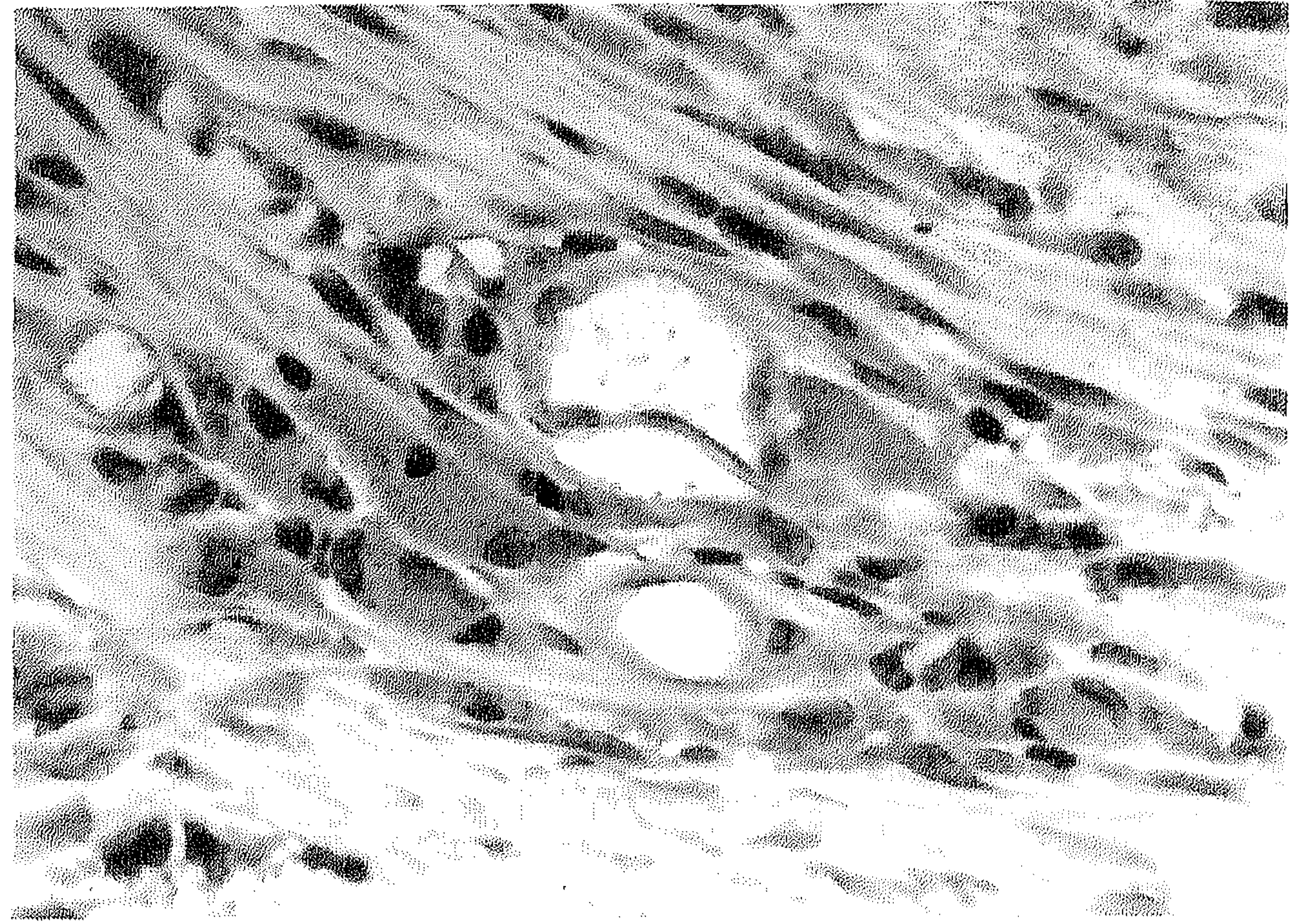


FIGURE 10 The smallest fragments were surrounded by several macrophages or probably ingested by multinucleated giant cells. Sudan black B staining, magnification 750 \times .

adjacent areas, however, active osteoblasts were present and bone deposition took place, resulting in a further embedding of the PLLA membrane fragments into the palatal bone. Direct contact between the bone and the PLLA membrane fragments, generally did not occur at these sites.

Thirteen weeks after surgery, at 25 weeks of age, in all histologic samples the membranes were totally fragmented. The larger fragments had disappeared and advanced disintegration had taken place resulting in fragments of about 10 μm . In all animals, the PLLA membrane fragments and particles were displaced in a medial direction. Bone deposition along the palatal bone had ceased. In a few samples, osteoclastic activity was observed near the fibroblastic sheath of some PLLA membrane particles.

Twenty-five weeks after surgery, at the age of 37 weeks, the samples showed the same features as described for the previous stage. The disintegration of PLLA fragments and particles, however, had proceeded, which resulted in smaller and fewer fragments and particles.

Group LMI (n = 6)

Histologic samples of animals in which the membrane was placed 3 weeks after Von Langenbeck's surgery showed more or less the same features as those described for the animals in Group LMD at the comparable stages of 7, 13, and 25 weeks after surgery. During the entire observation period, however, the PLLA membrane fragments and particles were somewhat larger in size and shifted less to the midline region of the palate than in animals of Group LMD.

DISCUSSION

In this study, PLLA membranes were prepared and implanted after palatal surgery in beagle dogs to create a temporary barrier, preventing scar tissue from attaching to the underlying

bone by means of Sharpey's fibers. In periodontology and in dental implantology, different biocompatible membranes are used in the oral environment (Gottlow et al., 1986, 1987). Teflon membranes (Gore-Tex, Millipore) have the disadvantage of having to be removed in a second surgical procedure, because this material is nonresorbable by the host (Nyman et al., 1987). As each surgical intervention again results in the formation of scar tissue, surgical interventions should be limited. Therefore, it was important to use a biodegradable membrane. Collagen membranes resorb within 2 to 3 weeks (Blumenthal, 1987), which is too fast to have an effect on dentoalveolar development. Comparison of PLLA membranes and Teflon membranes (Millipore) for so-called "guided tissue regeneration" favored the use of PLLA membranes (Magnusson et al., 1988). PLLA membranes can withstand cellular ingrowth by selecting an appropriate porous structure, it is highly biocompatible and it is biodegradable (Fleisher et al., 1988). The resorption period of PLLA membranes can be modified by changing molecular weight, thickness, and by copolymerization (Chawla and Chang, 1986; Gerlach and Eitenmüller, 1988). Appropriate requirements of the PLLA membrane for use in our study had to be defined.

First, from a biocompatibility point of view, it seems favorable that the PLLA membrane contains micropores to adapt to the biologic environment, because lack of micropores might induce the differentiation of tumor like cells (Williams and Roaf, 1973). The micropores should be approximately 1 μm allowing nutrients to pass through, but preventing the transmission of fibroblasts.

Second, disturbances in maxillary arch dimensions after palatal surgery in beagle dogs became apparent during and after the transition of teeth (Wijdeveld et al., 1989). The PLLA membrane should, therefore, remain intact until the transition of teeth is completed, which means that it should take at least 12 weeks before fragmentation of the membrane starts.

A third requirement should be that the membrane is easy to handle. This can be accomplished by choosing a certain combination of molecular weight and thickness (Chawla and Chang, 1986; Gerlach and Eitenmüller, 1988). In vitro, as well as in vivo, disintegration of a PLLA membrane used in the present study, with a molecular weight of 220 kg/mol and a thickness of 110 μm , is considered to proceed slowly (Leenslag et al., 1987; Schakenraad et al., 1988).

Clinical wound healing was found to be somewhat retarded in animals in which the PLLA membrane was placed directly. Obviously, migration of epithelial and connective tissue cells over the PLLA membrane during wound healing is more difficult than migration over a bony surface (In de Braekt et al., 1991). Even after 4 weeks, inflammatory signs were obvious but, later on, wound healing was completed and a smooth scar tissue remained.

Histologic evaluation, in the first week after surgery, showed that some cracks had developed in the PLLA membrane. This might be due to manipulation of the PLLA membrane during the implantation process or because the animals received a hard diet during the whole experimental period, which could

account for additional mechanical fracturing of the membranes. This suggestion is supported by other findings (Leenslag et al., 1987), showing that relatively rapid strength loss occurred in applications that demand a rather high level of load bearing properties during the process of wound healing.

In our study, the fragments remained approximately the same size during the first 5 weeks postoperatively, but smaller fragments and particles were found later, indicating a more rapid disintegration than expected. In vivo observations by Helder (1988) showed that disintegration of glycine/DL-lactic acid copolymers, implanted subcutaneously in rats, could be described in two stages. First, the molecular weight decreased as a result of hydrolysis of ester bonds. As soon as the molecular weight of the polymer chains has sufficiently decreased, weight loss was observed and the degradation products, especially L-lactic acid, were dissolved by cellular metabolism.

After 5 weeks, the PLLA implants started to disintegrate and after 10 weeks, PLLA had almost completely disappeared. These results were highly comparable with our observations, although Helder used a copolymer with a lower molecular weight PLLA than that used in our study. This would probably account for the fact that almost all PLLA had disappeared 10 weeks after implantation, whereas in our study, PLLA fragments were still observed 24 weeks after implantation.

The membrane particles were surrounded by a reactive zone containing mainly macrophages. This is in agreement with the findings of Leenslag et al. (1987) and Schakenraad et al. (1988). Plasma cells, lymphocytes, and multinucleated giant cells, however, were not found in these studies. The presence of these cells, even 25 weeks after implantation of the membranes, indicated a chronic inflammation. The fibroblastic sheath surrounding the PLLA fragments, which was observed 2 weeks postoperatively, was also found by other investigators (Leenslag et al., 1987; Helder, 1988; Schakenraad et al., 1988).

The membrane, or its remnants, did not prevent fibroblasts from migrating between the membrane and the bone surface. No indication was found that those cells passed through the micropores; presumably they migrated from the periphery. The fibroblastic sheath covering the PLLA fragments, however, appeared to influence the fibroblastic activity in the adjacent connective tissue, as formation of Sharpey's fibers was prevented in that area.

In some cases, osteoblastic activity within the fibroblastic sheath was encountered, resulting in bone deposition on PLLA fragments. This condition is also described by others (Hollinger, 1983; Hollinger and Schmitz, 1987).

Severance of Sharpey's fibers resulted in a temporary disruption of the attachment of the scar tissue. No reformation of Sharpey's fibers was observed until 10 weeks after they were severed, indicating that repair of the disrupted collagen fibers is taking place at a slow rate or not at all. Sharpey's fiber formation was only observed at the wound edges. No Sharpey's fiber formation had occurred in the center of the denuded bony areas, which suggests that formation of these fibers starts

from the edges. This study indicated that Sharpey's fiber formation did occur locally in all animals before the transition of teeth had completed, which could account for the fact that no significant differences in dento-alveolar improvement were found after PLLA membrane implantation (In de Braekt et al., 1993).

CONCLUSION

After immediate or delayed implantation, PLLA membranes disintegrated with similar tissue reactions. Despite this premature disintegration, formation of Sharpey's fibers did not occur at sites where PLLA membrane particles remained. This indicated that PLLA has a potential to inhibit Sharpey's fiber formation. Further research is necessary to develop a membrane that is more resistant to mechanical forces and which remains intact for a sufficient period of time.

Acknowledgments. We thank Professor F. Feijen, Dr. P. Dijkstra, and Ir. H. Esselbrugge, Technical University Twente, Enschede, The Netherlands, for their help with the preparation of the poly-(L-lactic) acid membranes.

REFERENCES

- BARDACH J. The influence of cleft lip repair on facial growth. *Cleft Palate J* 1990;27:76-78.
- BLAAUW EH, JONKMAN MF, GERRITS PO. A rapid connective tissue stain for glycol methacrylate embedded tissue. *Acta Morphol Neerl Scand* 1987;25:167-172.
- BLUMENTHAL NM. The use of collagen materials in bone grafted defects to enhance guided tissue regeneration. *Periodont Case Rep* 1987;9:1.
- CHAWLA AS, CHANG TMS. In-vivo degradation of polylactic acid of different molecular weights. *Biomater Mat Dev Art Org* 1986;13:153-162.
- DABELSTEEN E, KREMENAK CR. Demonstration of actin in fibroblasts in healing palatal wounds. *J Plast Reconstr Surg* 1978;62:429-435.
- DIXIT UB, KELLEY KM, HODGONS T, BARDACH J, SQUIER CA. Effect of palatal repair on maxillary growth in beagles. *J Dent Res* 1992;71:273.
- FLEISHER N, DE WAAL H, BLOOM A. Regeneration of lost attachment apparatus in the dog using Vicryl® resorbable mesh. *Int J Periodontol* 1988;2:45-55.
- GABBIANI G, RYAN G. Presence of modified fibroblasts in granulation tissue and their possible role in wound contraction. *Experientia* 1971;27:549-550.
- GERLACH KL, EITENMÜLLER J. Untersuchungen zum biologischen Abbau verschiedener Polymere der α -Hydroxysäuren. *Dtsch Zahnärztl Zsch* 1988;43:41-44.
- GOTTLOW NS, LINDHE J, KARRING T, WENNSTRÖM J. New attachment formation by guided tissue regeneration. *J Periodontol Res* 1987;22:252-254.
- GOTTLOW J, NYMAN S, LINDHE J, KARRING T, WENNSTRÖM J. New attachment formation in the human periodontium by guided tissue regeneration. *J Clin Periodontol* 1986;13:604-616.
- HELDER J. Copolymers of α -amino acids and α -hydroxy acids. Thesis University of Twente. Enschede, The Netherlands, 1988.
- HEROVICI C. A polychrome staining for differentiating precollagen from collagen. *Stain Technol* 1963;38:204-205.
- HOEKSMAN EA, VAN DER LEI B, JONKMAN MF. Sudan Black B as a histological stain for polymeric biomaterials embedded in glycol methacrylate. *Biomaterials* 1988;9:463-465.
- HOLLINGER JO. Preliminary report on the osteogenic potential of a biodegradable copolymer of polylactide (PLA) and polyglycolide (PGA). *J Biomed Mat Res* 1983;17:71-82.
- HOLLINGER JO, SCHMITZ JP. Restoration of bone discontinuities in dogs using a biodegradable implant. *J Oral Maxillofac Surg* 1987;45:594-600.
- IN DE BRAEKT MMH. Manipulation of wound healing after palatal surgery on beagle dogs. PhD Thesis, University of Nijmegen. Nijmegen, The Netherlands, 1991a.
- IN DE BRAEKT MMH, VAN ALPHEN FAM, KUIJPERS-JAGTMAN AM, MALTHA JC. Wound healing and wound contraction after palatal surgery and implantation of poly-(L-lactic) acid membranes in beagle dogs. *J Oral Maxillofac Surg* 1991b;50:359-364.
- IN DE BRAEKT MMH, van ALPHEN FAM, KUIJPERS-JAGTMAN AM, MALTHA JC. Maxillary arch dimensions after palatal surgery and implantation of poly-(L-lactic) acid membranes in beagle dogs. *Cleft Palate Craniofac J* 1993;30:129-134.
- KAHNBERG KE, THILANDER H. Healing of experimental excisional wounds in the rat palate. Histological study of the interphase in wound healing after sharp dissection. *Int J Oral Surg* 1982;11:41-51.
- KREMENAK CR JR. Dental exfoliation and eruption chronology in beagles. *J Dent Res* 1967;46:686-693.
- KREMENAK CR. Physiological aspects of wound healing: contraction and growth. *Otolaryngol Clin North Am* 1984;17:437-453.
- LEENSLAG JW, PENNINGS AJ, BOS RRM, ROZEMA FR, BOERING G. Resorbable materials of poly (L-lactide) VII. In vivo and in vitro degradation. *Biomaterials* 1987;8:311-314.
- LEVAME M, MEYER F. Le picropolychrome de Herovici application à l'identification des collagènes de types I et III. *Path Biol* 1987;35:1183-1188.
- LILLIE RD. Histopathologic technic and practical histopathology. 3rd Ed. New York: McGraw-Hill, 1965.
- MAGNUSSON I, BATICH C, COLLINS BR. New attachment formation following controlled tissue regeneration using biodegradable membranes. *J Periodontol* 1988;59:1-6.
- MILLARD DR. Cleft craft, the evolution of its surgery. III. Alveolar and palatal deformities. Boston: Little, Brown, 1980.
- NYMAN S, GOTTLOW J, LINDHE J, KARRING T, WENNSTRÖM J. New attachment formation by guided tissue regeneration. *J Periodontol Res* 1987;22:252-254.
- OLIN WH JR, MORRIS J, GEIL J, PRATT S, KREMENAK CR. Contraction of mucoperiosteal wounds after palatal surgery in beagle pups. *J Dent Res* 1974;53 (Special Issue):149.
- ROSS RB. Treatment variables affecting facial growth in complete unilateral cleft lip and palate. Part 6. Techniques of palate repair. *Cleft Palate J* 1987;24:64-70.
- SCHAKENRAAD JM, OOSTERBAAN JA, NIEUWENHUIS P, MOLENAAR I, OLIJSLAGER J, POTMAN W, EENINK MJD, FEIJEN J. Biodegradable hollow fibers for the controlled release of drugs. *Biomaterials* 1988;9:116-120.
- STRATHMANN H. Trennung von molekularen Mischungen mit Hilfe synthetischer Membranen. Darmstadt: Steinkopff Verlag, 1979.
- SQUIER C, KREMENAK CR. Quantitation of the healing palatal mucoperiosteal wound in beagle dogs. *Br J Exp Pathol* 1982;63:573-584.
- WIJDEVELD MGMM, GRUPPING EM, KUIJPERS-JAGTMAN AM, MALTHA JC. Wound healing of the palatal mucoperiosteum in beagle dogs after surgery at different ages. *J Craniomaxillofac Surg* 1987a;15:51-57.
- WIJDEVELD MGMM, GRUPPING EM, KUIJPERS-JAGTMAN AM, MALTHA JC. Mucoperiosteal migration after palatal surgery on beagle dogs. A longitudinal radiographic study. *Int J Oral Maxillofac Surg* 1987b;16:729-737.
- WIJDEVELD MGMM, GRUPPING EM, KUIJPERS-JAGTMAN AM, MALTHA JC. Maxillary arch dimensions after palatal surgery at different ages on beagle dogs. *J Dent Res* 1989;68:1105-1109.
- WIJDEVELD MGMM, MALTHA JC, GRUPPING EM, DE JONGE J, KUIJPERS-JAGTMAN AM. A histological study of tissue response to simulated palatal surgery in beagle dogs. *Arch Oral Biol* 1991;36:837-843.
- WILLIAMS DF, ROAF R. Implants in surgery. London: WB Saunders, 1973.