

Atopic Eczema Simulating Mammary Paget's Disease in an Adult

CASE REPORT

Débora Bacellar Cruz Nunes¹,
Adriana Kamilly Leitão Pitman Machado¹,
Michelle Fonseca Goiabeira¹, Samira Oliveira Silveira¹,
Yandra Sherring Einecke¹, Alena Margareth Darwich Mendes¹,
Maria Amélia Lopes dos Santos¹, Miguel Saraty de Oliveira¹,
Walter Refkalefsky Loureiro¹, Leônidas Braga Dias Júnior¹,
Juliana Bacellar Cruz Nunes², Mariana Bacellar Cruz Nunes³,
Francisca Regina Oliveira Carneiro¹

- 1 Serviço de Dermatologia da Universidade do Estado do Pará (UEPA), Pará, Brazil.
- 2 Universidade Federal do Pará (UFPA), Pará, Brazil.
- 3 Universidade do Estado do Pará (UEPA), Pará, Brazil.

Contact information:

Débora Bacellar Cruz Nunes.

Address: Rodovia Mario Covas, número 1455, Biarritz bloco 09 apto 101, CEP 67113330, Ananindeua PA, Brazil.

Tel: +55 91 98281-7054.

✉ debora.bacellar@hotmail.com

Abstract

An atopic breast eczema is usually bilateral, with intense pruritus and good response to corticosteroids. The differential diagnosis with mammary Paget's disease is fundamental, mainly in unilateral clinical manifestations, since it is frequently associated to adjacent breast tumors. The aim of the present report was to present a clinical condition of an atopic breast eczema through an exuberant and unilateral clinical presentation, emphasizing the need of the differential diagnosis for malignant diseases at this location.

Keywords

Eczema; Atopic Eczema; Mammary Paget's Disease; Unilateral.

Introduction

The atopic eczema or atopic dermatitis is a disease of universal distribution and can occur at any age. Most cases occur before the age of five [1] and are characterized by periods of exacerbation and remission. [1, 2]

Reports of nipple eczema are often associated with the hypothesis of atopy [3]. However, the differential diagnosis, with other benign and malignant eczematous diseases, should be performed [4]. The differential diagnosis with the mammary Paget's disease (MPD) is ne-

cessary, since it is presented as an eczematous lesion and is associated with more than 80% of the cases with underlying breast neoplasia [4, 5], and they present aggressive treatment proposals, such as segmental resection followed by radiotherapy or total mastectomy [6].

The biopsy should be performed on the suspicion of the Paget's disease or after therapeutic failure with topical corticosteroids [7]. The histopathological examination is essential to exclude the diagnosis of the mammary Paget's disease [4].

The diagnosis of atopic eczema is essentially clinical and the treatment with topical corticosteroids is indicated [1].

Case Report

The patient was a 43-year-old woman, Fitzpatrick phototype IV, who noted an erythematous pruritic lesion on the left breast which occurred one month earlier and presented progressive growth.

The patient had personal and family history of atopy and reported a previous manifestation of pruritus and eczema which appeared one year earlier in the same breast. However, with less intensity and spontaneous resolution. She presented a result of an ultrasonography of the breasts with areolar and periareolar dermoepidermal thickening classified as BIRADS 4 and absence of ductal dilatation, cysts, or breast nodules.

The initial clinical examination revealed an infiltrated erythemato-purpuric plaque with lamellar scales on the surface and regular margins, measuring 10x11cm and affecting the nipple, areola, and periareolar region of the left breast (**Figures 1 & 2**). There were no skin changes in the opposite breast. At palpation, there were no lumps or adenomegalies in the breasts and underarms.

Considering the clinical presentation and the result of the previous ultrasonography, the patient was submitted to wedge biopsy of the areolar region, sent to histopathological study that showed

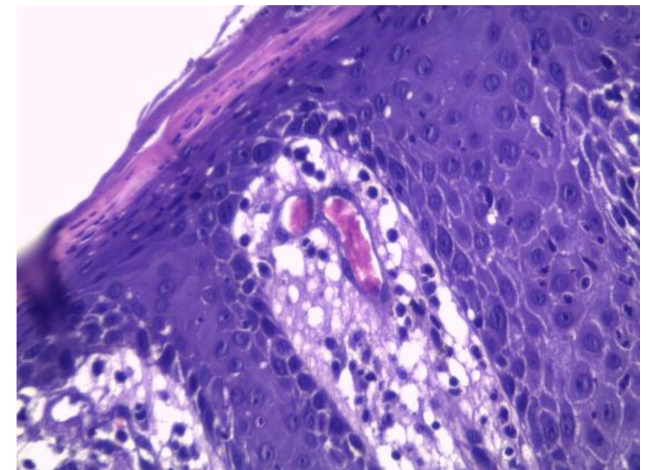
Figure 1: Erythemato-purpuric plaque affecting the nipple, areola, and periareolar region.

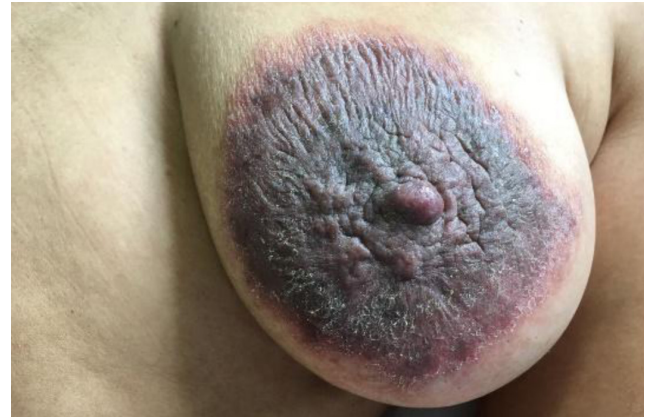

Figure 2: Lamellar scales and infiltration throughout the lesion.

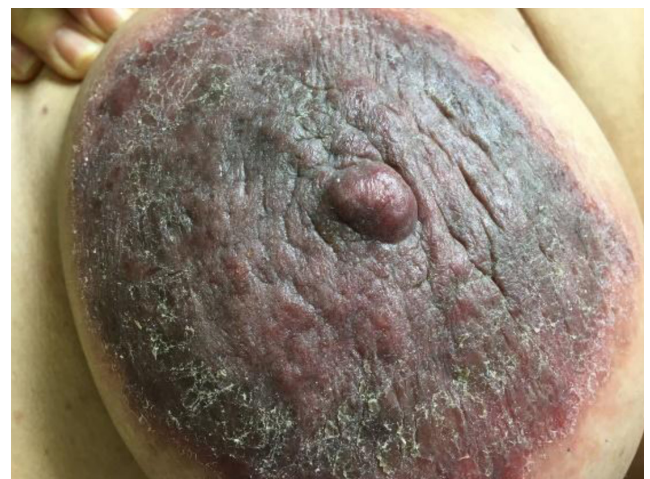

Figure 3: Parakeratosis, spongiosis and exocytosis of inflammatory cells.



epidermis with hyperkeratosis, intercalating ortho and paraceratosis, acantose psoriasiform, spongiosis, and exocytosis of inflammatory cells, congestive capillaries in the dermis surrounded by infiltration of mononuclear, and polymorphonuclear cells. It was detected no evidence of malignancy in the material examined (**Figure 3**).

After the result, it was possible to exclude the diagnosis of Paget's disease and to establish the diagnosis of eczema. The patient was treated with high-potency topical corticosteroids and returned after three weeks without clinical complaints and presenting only post-inflammatory residual hyperchromia at the lesion location.

Discussion

Nipple eczemas are often associated with atopy [3]. However, eczematous lesions of the nipple should be differentiated with benign and malignant conditions, such as contact eczema, psoriasis, nipple adenoma, squamous cell carcinoma, basal cell carcinoma, superficial melanoma, and mammary Paget's disease [4].

The benign eczema is usually bilateral with pruritus of greater intensity and has a good response to corticosteroid therapy [6, 8]. The Paget's disease, an important differential diagnosis, is an intraepithelial adenocarcinoma [9], that represents 1-4% of all cases of breast cancer [4, 9], and, it is presented, in most cases, with unilateral manifestations [4, 10].

Unilateral changes in the nipple and areola of recent onset suggest adjacent breast tumor [7]. This association is present in more than 80% of the cases of Paget's disease [4, 5], being the ductal carcinoma the most common histological type [5].

The mammary Paget's disease presents itself in several ways. At an early stage, the nipple is pruritic, becoming later erythematous and shiny, in the intermediate stage, the nipple becomes more rough and scaly, and, in a late stage erosion, ulceration and even flattening of the nipple arise [5].

The topical application of corticosteroids may result in temporary improvement of the initial eczematous lesion of Paget's disease, which can be misdiagnosed as a benign cutaneous disease [11]. Delayed diagnosis is frequent and may last from 6 to 12 months after the onset of the first symptoms [5].

Recognizing the Paget's disease is critical, since it may be the only clinical manifestation of an underlying carcinoma [11].

In the face of clinical suspicion of benign breast eczema, a topical corticosteroid therapy should be initiated. If the treatment is not effective or whether there is a suspicion of malignancy, the biopsy must be performed [7]. The wedge biopsy provides good results, since a part of the lactiferous duct can be excised together with the rest of the sample to perform the histopathological study [9].

Regarding the patient case reported in this study, she had an exuberant and unilateral cutaneous involvement associated with previous suspected ultrasonography, a fact that justified the biopsy for diagnostic elucidation.

The results of the histopathological examination, although helping to exclude Paget's disease [4], cannot distinguish the various forms of eczemas [12]. As for an atopic eczema, the findings are non-specific and may include spongiosis, acanthosis, parakeratosis, lymphocytic infiltrate, and exocytosis [2].

The diagnosis of the atopic eczema was made based on the clinical manifestation, personal and family history of atopy, and other atopic stigmas that were present in the patient.

The treatment with topical corticosteroids has a dramatic response for eczemas, with improvement of symptoms and aspect of the lesion within a week [7]. In the case of Paget's disease, the proposed treatments are segmental resection followed by radiotherapy or total mastectomy [6].

Conclusion

The differential diagnosis of nipple disorders is fundamental, especially for those with unilateral clinical manifestations. The dermatologist should be able to perform the differential diagnosis of pathologies in this location and indicate complementary diagnostic methods in the presence of suspicious lesions, since some cases may have a worse prognosis.

Conflicts of interest

The authors declare that there are no conflicts of interest.

References

1. Claro C. Eczema atópico na criança e no adulto. *Rev Port Clin Geral*. 2011; 27:78-82
2. Castro APM, Solé D, Rosário Filho NA, Jacob CMA, Rizzo MCFV, Fernandes MFM, et al. Guia Prático para o Manejo da Dermatite Atópica – opinião conjunta de especialistas em alergologia da Associação Brasileira de Alergia e Imunopatologia e da Sociedade Brasileira de Pediatria. *Rev bras alerg imunopatol*. 2006; 29(6): 268-282.
3. Geffroy D, Doutriaux-Dumoulin I, Labbe-Devilliers C, Meingan P, Houdebine S, Sagan C, et al. Maladie de Paget du mamelon et principaux diagnostics différentiels. *J radiol (Paris)*. 2011; 92:889-898
4. Branquinho RPM, Silva C, Ribeiro R, Belo J, Botto I. Doença de Paget da mama: revisão de 12 casos. *Acta Obstet Ginecol Port*. 2013; 7(2):99-102
5. Geffroy D, Doutriaux-Dumoulin I. Clinical abnormalities of the nipple-areolacomplex: The role of imaging. *Diagnostic and Interventional Imaging*. 2015; 96(10): 1033-1044.
6. Lage D, Volpini CA, Sasseron MG, Dalton P, Arruda L. Doença de Paget: a importância do especialista. *An Bras Dermatol*. 2010; 85(3):365-9.
7. Boulanger L, Demetz J. How to explore breast skin lesion?: Guidelines. *J Gynecol Obstet Biol Reprod (Paris)*. 2015 Dec; 44(10):921-6
8. Vieira JO, Reis FP, Secundo MC, Tavares RO, Arruda RS, Menezes TC. A doença de Paget mamária: um relato de caso. *Rev Bras Mastologia*. 2014; 24(1):29-33
9. Challa VR, Deshmane V. Challenges in Diagnosis and Management of Paget's Disease of the Breast-a Retrospective Study. *Indian J Surg*. 2015; 77(3):1083-1087.
10. Cirqueira MB, Soares LR, Moreira MAR, Rosa VDL, Freitas-Junior R. Doença de Paget da mama: experiência de um centro universitário. *Rev Bras Mastologia*. 2015; 25(3):90-96
11. Adams SJ, Kanthan R. Paget's disease of the male breast in the 21st century: A systematic review. *The Breast*. 2016; 29:14-23
12. Motta AA, Aun MV, Kalil J, Giavina-Bianchi P. Dermatite de contato. *Rev Bras Alerg Imunopatol*. 2011; 34:73-82.

Publish in International Archives of Medicine

International Archives of Medicine is an open access journal publishing articles encompassing all aspects of medical science and clinical practice. IAM is considered a megajournal with independent sections on all areas of medicine. IAM is a really international journal with authors and board members from all around the world. The journal is widely indexed and classified Q2 in category Medicine.