

ORIGINAL RESEARCH

Open Access

^{11}C -acetate PET/CT in pre-therapeutic lymph node staging in high-risk prostate cancer patients and its influence on disease management - a retrospective study

Sara Strandberg*, Camilla Thellenberg Karlsson, Torbjörn Sundström, Mattias Ögren, Margareta Ögren, Jan Axelsson and Katrine Riklund

Abstract

Background: Radiation treatment with simultaneous integrated boost against suspected lymph node metastases may be a curative therapeutic option in patients with high-risk prostate cancer (>15% estimated risk of pelvic lymph node metastases according to the Cagiannos nomogram). ^{11}C -acetate positron emission tomography/computed tomography (PET/CT) can be used for primary staging as well as for detection of suspected relapse of prostate cancer. The aims of this study were to evaluate the association between positive ^{11}C -acetate PET/CT findings and the estimated risk of pelvic lymph node metastases and to assess the impact of ^{11}C -acetate PET/CT on patient management in high-risk prostate cancer patients.

Methods: Fifty consecutive prostate cancer patients referred for primary staging with ^{11}C -acetate PET/CT prior to radiotherapy with curative intention were enrolled in this retrospective study.

Results: All patients showed increased ^{11}C -acetate uptake in the prostate. Pelvic lymph node uptake was seen in 42% (21/50) of the patients, with positive external iliac lymph nodes in 71% (15/21) of these. The overall observed proportion of PET/CT-positive pelvic lymph nodes at patient level was higher than the average estimated risk, especially in low-risk groups (<15%). There was a significant association between observed proportion and estimated risk of pelvic lymph node metastases in groups with ≤ 45 and $>45\%$ estimated risk. Treatment strategy was altered due to ^{11}C -acetate PET/CT findings in 43% (20/47) of the patients.

Conclusions: The observed proportion of ^{11}C -acetate PET/CT findings suggestive of locoregional metastases was higher than the estimated risk, suggesting that the Cagiannos nomogram underestimates the risk for metastases. The imaging results with ^{11}C -acetate PET/CT have a considerable impact on patient management.

Keywords: Prostatic neoplasms; PET/CT; ^{11}C -acetate; Neoplasm staging; Lymphatic metastasis

Background

During a lifetime, approximately 15% of men will be diagnosed with prostate cancer, making it the second most common cancer form in males worldwide [1]. According to the Swedish National Prostate Cancer Registry, it is the most common cancer in males in Sweden, with an incidence of approximately 10,000 and a mortality of 2,500 annually [2]. Prostate cancer is a complex heterogeneous disease with highly variable morphological and physiological

characteristics [3]. Staging and risk categorisation is decided from clinical features including T stage, prostate-specific antigen (PSA) and Gleason score. Risk estimation can be facilitated with the use of nomograms such as the Cagiannos nomogram, which is a widely used clinical tool to determine the extent of disease as well as the risk of pelvic lymph node involvement [4]. Prostate cancer with >15% estimated risk of pelvic lymph node metastases is considered as high-risk prostate cancer but still stands a chance to get cured with standard radiotherapy including the prostate and the seminal

* Correspondence: sara.strandberg@vll.se

Department of Radiation Sciences, Umeå University, 90185, Umeå, Sweden

vesicles (78 Gy) [5]. However, a more aggressive treatment approach including the pelvic lymph nodes is under development [5] and is used in the treatment of high-risk prostate cancer in the University Hospital of Umeå. Nomograms will only provide an estimated risk of pelvic lymph node metastasis, and it is necessary to establish a more reliable non-invasive method for staging. Hybrid imaging with positron emission tomography/computed tomography (PET/CT) renders various molecular and morphological information, depending on the radiotracer and the design of the CT protocol. PET/CT is widely used in oncologic imaging for cancer staging and restaging as well as for evaluation of treatment response. The most used radiotracer ^{18}F -FDG (2-deoxy-2- ^{18}F -D-glucose) is an indicator of glucose metabolism, which has proved useful in several malignant tumours due to their increased glycolysis, the Warburg effect [6], but it has limitations in relatively slow-growing malignancies such as prostate cancer. For PET/CT imaging in prostate cancer, ^{11}C -acetate, ^{11}C -choline, and ^{18}F -choline appear to be more suitable tracers [7]. Multiple other promising new tracers are under development for imaging in prostate cancer but still need further investigation [8,9]. Currently, ^{11}C -/ ^{18}F -choline and ^{11}C -acetate are the most commonly used tracers, with comparable results [7,10]. A recent study by Buchegger et al. showed excellent concordance between ^{18}F -choline and ^{11}C -acetate in the detection and localization of positive lymph nodes and skeletal metastases in patients with prostate cancer [10]. ^{11}C -choline-PET/CT has proved valuable mainly for radiotherapy planning in prostate cancer patients with biochemical recurrence after radical treatment [11]. ^{11}C -acetate is a radiotracer that is believed to reflect lipid metabolism, but its exact pharmacodynamic mechanism is still debated [12]. Several studies indicate that ^{11}C -acetate is of value for primary staging of prostate cancer [8,13-15]. Oyama et al. have shown ^{11}C -acetate to be superior to ^{18}F -FDG with higher sensitivity for prostate cancer and its metastases [13]. In 2012, Castellucci and Jadvar suggested in a review of PET/CT in prostate cancer that the main application for ^{11}C -acetate might be to rule out distant metastases in early prostate cancer relapse prior to salvage radiotherapy [8].

The aims of this retrospective study were to evaluate the correlation between ^{11}C -acetate PET/CT findings and the estimated risk of locoregional lymph node metastases as indicated by the Cagiannos nomogram and to assess the impact of ^{11}C -acetate PET/CT examination results on the clinical management of previously untreated high-risk prostate cancer patients.

Methods

Patients and clinical data

Fifty consecutive patients referred for ^{11}C -acetate PET/CT at Nuclear Medicine, Department of Radiology, University

Hospital of Umeå, Sweden, from 2011 July 6 to 2013 March 26 were included. The cause for referral was primary staging of biopsy-verified prostate cancer prior to radiotherapy with curative intention. Patients were referred for ^{11}C -acetate PET/CT if they reached 15% risk in the nomogram or if they exhibited other risk factors such as rapidly increasing PSA. The time interval between biopsy and ^{11}C -acetate PET/CT was at an average of 8 weeks, range 3 to 18 weeks. All patients had a baseline ^{11}C -acetate PET/CT scan, of which 90% (45/50) had a contrast-enhanced CT (CECT) scan in the same session. The remaining five patients had a diagnostic CT scan without intravenous (i.v.) contrast due to either impaired renal function or a previous examination with i.v. iodine contrast media within 4 weeks.

Clinical information regarding pre-treatment status was retrieved from the referral text. Follow-up data were collected from the patients' medical records. Clinical data concerning changes in treatment strategy were missing in three patients referred from regional hospitals, and these patients were excluded from the evaluation of impact of ^{11}C -acetate PET/CT findings on treatment strategy. The study was approved by the regional ethics review board.

The Cagiannos pre-treatment nomogram was used to estimate the risk of pelvic lymph node involvement. Factors taken into account in the nomogram are age, pre-treatment PSA, clinical tumour stage, primary and secondary Gleason grade, and the number of positive and negative biopsy cores [16]. Estimated risk data could be calculated for all patients except one, where clinical data were missing. This patient was excluded from the evaluation of the correlation between ^{11}C -acetate PET/CT findings and the estimated risk of locoregional lymph node metastases. Patient characteristics are shown in detail in Table 1.

PET/CT imaging

All image acquisition was done with a GE Discovery 690 PET/CT scanner (General Electric, Pewaukee, WI, USA). Software and algorithms were supplied with the scanner. The patients were injected with 1- ^{11}C -acetate (5.0 MBq/kg body weight, mean dose 436 MBq, range 304 to 577 MBq)

Table 1 Patient characteristics

	<i>n</i>	Mean	Range
Patients (<i>n</i>)	50		
Age (years)		67	41 to 77
PSA (ng/ml)		37	2.7 to 168
Gleason score		8	6 to 10
Estimated risk of locoregional lymph node metastases (%) ^a		32	3.3 to 80.3

^aAccording to the Cagiannos pre-treatment nomogram, where age, pre-treatment PSA, clinical tumour stage, primary and secondary Gleason grade, and the number of positive and negative biopsy cores influence the estimated risk.

i.v., and a CT scan with low dose for PET attenuation was acquired, followed by a PET scan 10 min post-injection and finally a diagnostic CT with or without i.v. contrast media. The attenuation CT was a helical 0.5-s rotation time scan, employing 120 kV and 30 mA. The PET scan was performed in time-of-flight mode with an acquisition time of 2 min/bed position, including the abdomen, thorax and neck. The PET images were reconstructed with the OSEM-based VuePoint HD (GE Healthcare, Pewaukee, WI, USA) (2 iterations, 24 subsets, 6.4 mm Gaussian filter), to a 128 × 128 pixel matrix with 50-cm field-of-view, giving a voxel size of 5.5 × 5.5 × 3.27 mm³. The diagnostic CT included the neck, thorax and abdomen, using 120 kV, with beam current controlled by the Auto-mA algorithm (noise index 35, current limited to the range 150 to 750 mA). The CECT was done after i.v. injection of iodine contrast (Omnipaque 350 mgI/ml 0.5 g I/kg, rendering a patient mean volume of 137 ml, range 108 to 167 ml).

Evaluation of image data

Two physicians double licensed in radiology and nuclear medicine (one with >10 years' experience from reading PET/CT and one with 2 years' experience) visually evaluated all PET/CT studies. Any exceptional cases of inter-observer disagreement were solved with consensus. The radiologists had access to basic clinical data available in the referral text, typically length of disease, Gleason score and PSA levels. Lesions with acetate uptake visually exceeding the background activity were considered positive. The uptakes were quantified by measurements of the highest standardised uptake value - maximum pixel activity in correlation to body weight and the injected dose, grams per millilitre (standardised uptake value (SUV_{max})). All visually positive uptakes were measured in box regions of interest (ROIs) with PET VCAR software (AW 4.5, General Electric, Pewaukee, WI, USA) to determine SUV_{max}. The mediastinal background was measured in reference ROIs. The ROIs were delineated with a threshold of 42% of maximum signal intensity [17,18].

The morphological criteria for suspected lymph node metastases were round shape, short-axis diameter exceeding 10 mm, lack of fat-containing hilus and visually increased contrast enhancement compared to normal lymph nodes.

Other suspected metastatic sites were skeletal and hepatic lesions. The morphological criteria for suspected bone metastasis on CT were sclerotic, lytic or mixed lesions with destruction of cortical bone. Characteristics consistent with suspected hepatic metastases on CT were hypo- or hyperattenuating hepatic masses with irregular delineation and/or pathologic pattern of contrast enhancement.

The distinction between low, intermediate and high grade of suspicion of lymph node metastasis was based on the combination of the level of SUV_{max}, morphological

changes in size and structure and pathological contrast enhancement, according to generally defined and accepted criteria for evaluation of lymph node involvement in CT as well as in ¹⁸F-FDG PET studies. Low-grade suspicious lesions have been considered non-metastatic. Intermediate- and high-grade suspicious lesions have been evaluated as metastatic. The systematic interpretation of lymph nodes is described in detail in Tables 2 and 3. Depending on the level of SUV_{max}, also normal-appearing lymph nodes can be categorised as intermediate grade, and vice versa, morphologically aberrant lymph nodes with just a slight increase in SUV_{max} are categorised as high grade according to Tables 2 and 3. The high grade of suspicion requires both PET and CT changes, whereas in the intermediate group, the level of the SUV_{max} is the critical parameter. Pelvic locoregional lymph nodes and distant paraaortal lymph nodes were evaluated with slightly different criteria than other distant lymph nodes regarding the impact of the level of SUV_{max}, in order to reduce the number of false-positive reactive lymph nodes in the thorax and the inguinal regions, where prostate cancer metastases are less likely to occur (Tables 2 and 3). Paraaortal lymph node metastases per definition are considered distant metastases. Our division of lymph nodes into pelvic and paraaortal versus other distant lymph node metastases was due to anatomical reasons - the lymphatic drainage from the prostate makes it more likely to find metastases in the pelvic and paraaortal lymph nodes. Also, low-grade uptake in small mediastinal lymph nodes is a relatively common finding of unclear clinical significance, making these lymph nodes more difficult to interpret. The paraaortal lymph nodes were thus treated with higher degree of suspicion than other distant sites, with regard to likelihood of metastasis.

Statistical analysis

Different risk groups regarding the estimated risk of locoregional lymph node metastases versus the observed risk were compared with Pearson's chi-square test. The association between prostate SUV_{max}, PSA and Gleason score, respectively, and the presence of metastatic disease was evaluated with binary logistic regression analysis.

Table 2 Criteria for low, intermediate, and high grade of suspicion of pelvic/paraaortal lymph node metastasis in PET/CT

	SUV _{max} < mediastinal background	SUV _{max} > mediastinal background	Any visually positive uptake on PET	Pathological appearance on CT
Low grade	+			-
Intermediate grade		+		-
High grade			+	+

Table 3 Criteria for low, intermediate, and high grade of suspicion of distant (except for paraaortal) lymph node metastasis in PET/CT

	SUV _{max} <50% higher than mediastinal background	SUV _{max} >50% higher than mediastinal background	Any visually positive uptake on PET	Pathological appearance on CT
Low grade	+			-
Intermediate grade		+		-
High grade			+	+

Correlations between prostate SUV_{max}, PSA and Gleason score were evaluated using linear regression analysis. For more reliable sample sizes, patients were merged into three Gleason score groups: Gleason score 6 to 7, 8 and 9 to 10. The chosen significance level was $p < 0.05$. All statistical analyses were executed in IBM SPSS Statistics 21 (SPSS Inc., Chicago, IL, USA).

Results

Distribution of positive ¹¹C-acetate PET/CT findings

All patients showed increased heterogeneous acetate uptake of the prostate (mean SUV_{max} 7.3 g/ml, range 3.3 to 13.8 g/ml); typical appearance is shown in Figure 1. Suspected lymph node metastases were seen in 105 lymph nodes in 42% (21/50) of the patients, most frequently along the external iliac vessels, which was the case in 71% (15/21) of the patients (typical uptake shown in Figure 2). In 45% (47/105) of the positive lymph nodes, only PET was positive, and in the other 55% (58/105), both PET and CT were pathologic. Distribution and characteristics of suspected locoregional lymph node metastases are shown in detail in Table 4.

Previously unknown distant metastases were found in 28% (14/50) of patients: located in paraaortal lymph nodes in six patients, mediastinal lymph nodes in eight and cervical lymph nodes in one patient (example shown in Figure 3). Among the 14 patients with suspected distant metastases were four with skeletal metastases. Unexpected incidental findings in two patients were biopsy-verified synchronous renal cell carcinoma and hepatocellular carcinoma. Distribution of suspected distant metastases and incidental findings are shown in detail in Table 5.

Low-grade mediastinal lymph node uptake (SUV_{max} range 2.3 to 5.8 g/ml) with low suspicion of lymph node metastasis was seen in 22% (11/50) of the patients with 22 nodal uptakes in total. In 55% (6/11) of these patients, only non-specific mediastinal lymph node uptake was seen and 45% (5/11) of the patients had both non-specific and suspected metastatic mediastinal lymph node uptakes.

Association between ¹¹C-acetate PET/CT findings and the estimated risk of locoregional lymph node metastases

Patients were divided into three groups according to estimated risk of pelvic lymph node metastases, <15% ($n = 12$), 15 to 45% ($n = 24$) and >45% ($n = 13$), respectively. The observed proportions of pelvic lymph node metastases in the three groups were 33, 33 and 69%, respectively. The Pearson chi-square test displayed that there was no significant association between the observed proportion and the estimated nomogram risk of pelvic lymph node metastases in the three original groups ($p = 0.08$). Merging the first and the second groups, those with $\leq 45\%$ estimated risk had positive pelvic lymph nodes in 33% (12/36), and those with >45% risk had positive pelvic lymph

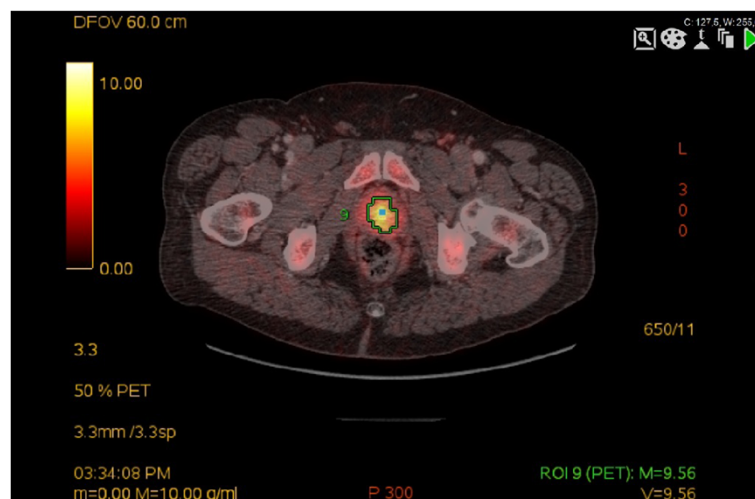


Figure 1 Increased acetate uptake (SUV_{max} 9.6) of the prostate in patient with prostate cancer.

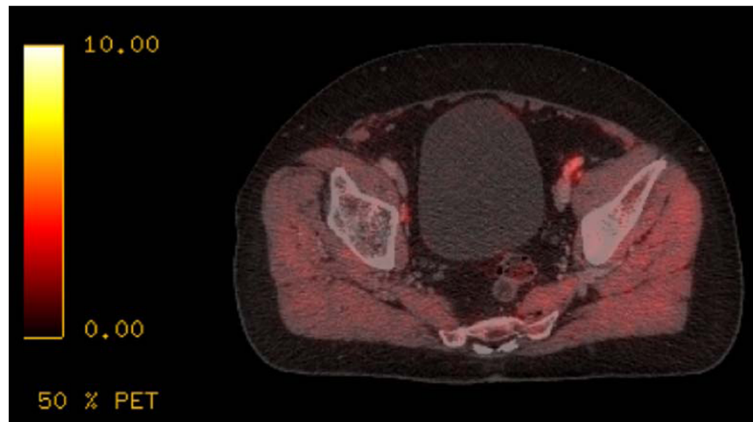


Figure 2 Increased acetate uptake in suspected iliac lymph node metastasis in a prostate cancer patient.

nodes in 69% (9/13), and this association proved to be significant ($p < 0.05$).

The overall estimated mean risk of pelvic lymph node metastases was 32%, while the observed proportion of suspected pelvic lymph node metastases was 43% (21/49). Twelve patients had an estimated risk $< 15\%$. All of these patients had ^{11}C -acetate-positive lesions in the prostate and 3/12 patients (25%) showed suspected pelvic lymph node involvement, two with intermediate and one with high suspicion of metastasis.

Prognostic value of prostate SUV_{max}

Binary logistic regression analysis proved prostate SUV_{max} to be higher in patients with suspected pelvic lymph node spread (odds ratio (OR) 1.45, $p < 0.05$). Neither prostate SUV_{max} , PSA or Gleason score was associated with the presence of suspected distant metastases, nor were PSA or Gleason score associated with suspected pelvic lymph node spread.

There was a significant positive correlation between prostate SUV_{max} and PSA (Pearson correlation coefficient 0.35, $p < 0.05$), but not with Gleason score. PSA and Gleason score were negatively correlated (-0.33 , $p < 0.05$).

Impact of ^{11}C -acetate PET/CT findings on treatment strategy

In 43% (20/47) of the patients, treatment strategy was altered due to ^{11}C -acetate PET/CT findings (Table 6). Eleven of these had an estimated risk of pelvic lymph node metastases $\leq 45\%$ and the remaining nine $> 45\%$, with treatment changes as indicated in Table 7. In 19% (9/47) of the patients, suspected pelvic lymph node metastases (SUV_{max} 2.6 to 11.0 g/ml, short axis 5 to 16 mm) were treated with additional radiotherapy boost (mean additional dose 17 Gy, range 15 to 26 Gy). The nine patients that received additional radiotherapy boost against suspected pelvic lymph node metastases were fully informed of the non-conventional approach in this treatment, and all chose to go forward with it. The selected lymph nodes were irradiated according to the proposed Radiotherapy Oncology Group (RTOG) lymph node template. Lymph nodes were only boosted if they were within this field. Otherwise, the patients were considered to have distant metastases. The disease was far more extensive than expected, and therapeutic options were no longer curative in 21% (11/47) of the patients. The findings were confirmed with conventional examinations such as bone scintigraphy, and occasionally with biopsy,

Table 4 Distribution of total number of intermediate and high-grade suspicious locoregional lymph node uptakes, interpreted as metastatic

Locoregional LN localisation	High-grade suspicious LN metastases (mean SUV_{max} g/ml and mean short axis mm)	Intermediate suspicious LN metastases (mean SUV_{max} g/ml)	Number of patients ($n = 21$)	Σ suspicious LN metastases
Pararectal	6 (5.4 g/ml, 20 mm)	0	4	6
Obturator	6 (5.2 g/ml, 9.7 mm)	2 (2.9 g/ml)	6	8
External iliac	28 (6.6 g/ml, 14 mm)	36 (3.9 g/ml)	15	64
Internal iliac	11 (6.5 g/ml, 14 mm)	4 (4.7 g/ml)	9	15
Common iliac	7 (4.8 g/ml, 13 mm)	5 (4.3 g/ml)	6	12
Σ	58	47	21 ^a	105

^a21 patients with acetate uptakes in multiple locations.

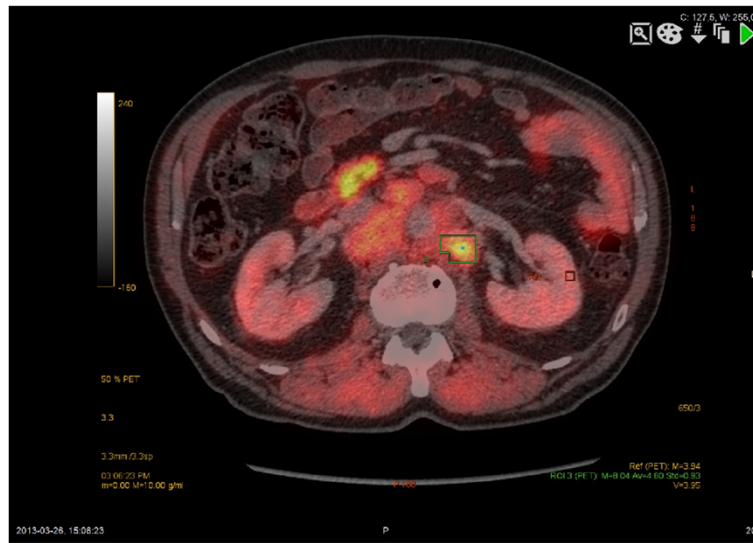


Figure 3 Increased acetate uptake in pathologically enlarged paraaortal lymph nodes in patient with prostate cancer.

according to clinical routine before changing therapy to non-curative. Patients that were switched to palliative treatment received androgen deprivation therapy except for one patient who declined because of a diagnosis of previously unknown synchronous hepatocellular carcinoma accidentally detected on ^{11}C -acetate PET/CT. Three out of the eleven patients also got radiotherapy to the prostate to palliate local symptoms. In 1/11 patients, radiotherapy treatment was cancelled due to comorbidity.

The remaining 57% (27/47) were treated with standard radiotherapy as initially planned. Standard radiotherapy of the prostate gland did not change due to ^{11}C -acetate PET/CT results.

Discussion

There was a statistically significant association between the observed proportions of ^{11}C -acetate PET/CT findings suggestive of pelvic lymph node metastases in merged estimated risk groups ≤ 45 and $>45\%$ according to the established Cagiannos nomogram, which supports the value of ^{11}C -acetate PET/CT in pelvic lymph node staging of primary prostate cancer. The lack of a statistically significant result in the original three risk groups can be explained by inadequate power of the study since the number of patients in each risk group is low. Surprisingly, patients with previously estimated low ($<15\%$) risk of pelvic lymph node metastases were

Table 5 Distribution of suspected distant metastases and incidental findings

Localisation of suspected pathology	Number of PET + lesions	Number of CT + lesions	CT appearance	Pathology unrelated to prostate cancer	Number of patients	Σ distant metastases
Paraaortal LN	6 (mean SUV_{max} 5.8 g/ml)	6 (mean short axis 13 mm)	Oval-rounded shape		6	6 (4 solitary, 2 conglomerates)
Mediastinal/hilar LN	8 (mean SUV_{max} 3.7 g/ml)	8 (mean short axis 10 mm)	Oval-rounded shape		8	8 (6 solitary, 2 conglomerates)
Axillary LN	1 (SUV_{max} 9.0 g/ml)	1 (short axis 10 mm)	Rounded shape		1	1
Cervical LN	2 (mean SUV_{max} 5.6 g/ml)	2 (mean short axis 10 mm)	Rounded shape		1	2 (2 conglomerates)
Skeletal	20 (mean SUV_{max} 7.1 g/ml)	20	Sclerotic		4	20
Liver	1 (SUV_{max} 14.3 g/ml)	1	Hypoattenuating mass	HCC	1	-
Kidney	1 (SUV_{max} 14.2 g/ml)	1	Heterogeneous mass	RCC	1	-
Σ	39	39			22 ^a	37

^aSix patients with multiple sites, in total 14 with suspected distant metastases, and two with incidental findings. HCC, hepatocellular carcinoma; RCC, renal cell carcinoma.

Table 6 ¹¹C-acetate PET/CT findings resulting in altered treatment strategy

Patient number	Localisation pelvic LN metastases	Localisation distant metastases	Synchronous finding	Curative → additional RT	Curative → non-curative RT
1	Iliac int/ext	Paraaortal LN	-	-	Palliative RT
2	Iliac ext	Skeletal	-	-	No RT
3	Iliac int/ext	-	-	RT boost 16 Gy	-
4	Iliac int/ext	-	-	RT boost 16 Gy	-
5	Iliac ext	-	-	RT boost 16 Gy	-
6	Iliac com	-	-	RT boost 16 Gy	-
7	Iliac int/ext	-	-	RT boost 16 Gy	-
8	Obt, iliac int/ext/com	-	-	RT boost 15 Gy	-
9	-	-	HCC with paraaortal LN	-	No RT
10	Iliac ext	-	-	RT boost 20 Gy	-
11	Obt, iliac int/ext/com	Paraaortal LN, skeletal	-	-	No RT
12	Pararectal, iliac ext	-	-	RT boost 26 Gy	-
13	Pararectal, obt, iliac int/ext/com	Paraaortal LN	-	-	Palliative RT
14	Iliac int/ext/com	Paraaortal, thoracic, cervical LN	-	-	No RT
15	-	Skeletal	-	-	No RT
16	Iliac ext	-	-	RT boost 16 Gy	-
17	Iliac ext	Skeletal	-	-	No RT
18	-	-	Aortic aneurysm	-	No RT
19	Pararectal, iliac int/ext/com	Paraaortal, thoracic LN	-	-	No RT
20	Pararectal, obt, iliac ext	-	-	-	Palliative RT
Σ	17	8	2	9	11

HCC, hepatocellular carcinoma; LN, lymph nodes; Obt, obturator; RT, radiotherapy.

found to have PET/CT-positive lymph nodes in 25%. The overall observed proportion of positive PET/CT findings suggestive of pelvic lymph node metastases was higher than the estimated risk, suggesting either that ¹¹C-acetate PET/CT is superior to the clinical prediction tool or that there is a high rate of false-positive findings. It is possible that the inclusion criteria were such that this resulted in higher numbers, and there may be a selection bias especially since ¹¹C-acetate PET/CT was a new method at the time and is still used only in cases with risk of pelvic lymph node involvement and where curative radiotherapy is the intended treatment. That may explain why our results are not comparable with other studies based on low- and intermediate-risk groups, but it does

not explain the difference in the observed proportion of suspected pelvic lymph node metastases versus the expected risk in the Cagiannos nomogram. Since the patients in our study were treated with radiotherapy, there was no possibility to obtain histopathological confirmation of the suspected lymph node metastases. Haseebuddin et al. have shown a sensitivity of 68% and specificity of 78% of ¹¹C-acetate PET/CT for detecting pelvic lymph node metastases [15], but apart from their study, little is published on suspected lymph node metastases with this method. Another possible explanation for the discordance could be that the Cagiannos nomogram underestimates the risk of lymph node metastasis, as has been previously suggested by Walz et al. in 2012 [19]. Schiavina et al. showed in their study on ¹¹C-choline PET/CT in intermediate-risk and high-risk prostate cancer that the specificity and accuracy of PET/CT was better than that of the Kattan and Briganti nomograms, although the results were not statistically significant [20]. Altogether, our conclusion is that the higher proportion of ¹¹C-acetate-positive pelvic lymph nodes is not merely an artefact. The distinction between metastatic and non-metastatic unspecific findings in this study was based on the combination of increased SUV_{max}, morphological changes in size

Table 7 Treatment change due to ¹¹C-acetate PET/CT findings in estimated risk groups according to Cagiannos nomogram

Estimated risk	Addition of RT boost to pelvic LN	Change to no/palliative RT
≤45% (n =11)	4	7
>45% (n =9)	5	4

LN, lymph nodes.

and structure and pathological contrast enhancement, i.e., the established variables for characterising a lesion as benign or malignant. In prostate cancer, however, some data indicate that pelvic lymph nodes may be enlarged not only due to metastatic disease but also because of associated hyperplastic or regressive alterations [21]. On the other hand, it is also well known that normal-sized lymph nodes can harbour metastases.

The relatively common low intense acetate uptake in otherwise normal-appearing mediastinal lymph nodes is considered non-specific, but the mechanism and possible prognostic features remain unclear. The presence of non-specific mediastinal lymph nodes did not influence therapy, and this finding will be followed clinically. Mediastinal lymphadenopathy in prostate cancer is described in several case reports in the literature as a rare symptom of advanced disease [22-24]. This needs further evaluation, especially with the contradictory findings from a post-mortem study on 176 cases describing a distribution of lymph node metastases from prostate cancer to the paraaortal regions most frequently, followed by the external iliac and tracheobronchial regions [25].

Higher prostate SUV_{max} correlates in our study with the presence of suspected pelvic lymph node metastases, in contrast to earlier studies by Kato et al. concluding that prostate SUV measurements in dynamic ¹¹C-acetate PET in known normal prostate and benign prostatic hyperplasia overlap significantly with those for known prostate cancer [26]. The reason for this may be the selection of mainly high-risk prostate cancer patients in our material.

The weaknesses of this study are that two indirect methods to predict metastatic disease in prostate cancer patients are compared and, as before mentioned, that the sample population is relatively small. In future research, the need for histopathologic confirmation is obvious, although one recent study by Haseebuddin et al. shows that the presence of ¹¹C-acetate PET/CT-positive pelvic lymph nodes independently predicts treatment failure, despite negative histopathologic findings [15]. Furthermore, there may be a risk of selection bias as mentioned above, but also in the low-risk group (<15%) in this material, since they have been submitted for ¹¹C-acetate PET/CT despite their low risk of pelvic lymph node metastases and may have some other characteristic in common, of which we are unaware.

¹¹C-acetate is a relatively new tracer for prostate cancer staging with molecular properties reflecting the pattern of lipid metabolism. It could potentially be used for other slow growing cancers apart from prostate cancer such as highly differentiated hepatocellular carcinoma (HCC), renal cell carcinoma (RCC), bladder carcinoma and brain tumours [27,28]. In our material of 50 patients, we found one

histology-verified RCC and one HCC, thus supporting previous studies.

The impact of ¹¹C-acetate PET/CT on treatment strategy is high and in line with a previous report from Kjölhede et al. where 20% of patients examined with combined ¹⁸F-choline PET/CT and ¹⁸F-FDG PET/CT had their treatment plans altered [29]. This result also complies with several other studies on ¹⁸F-FDG PET/CT in various kinds of cancer with changes in treatment in 21 to 62% of the patients [30-32]. In our study, patients with limited pelvic nodal disease received integrated radiotherapy boost to the pelvic lymph nodes. This is a strategy that has been explored and found feasible regarding toxicity and clinical outcome [5].

Our results indicate that ¹¹C-acetate PET/CT might be of value in pelvic lymph node staging in previously untreated high-risk prostate cancer patients, but these results should be interpreted with caution especially since the number of patients was low and histopathological confirmation was absent. However, the prognosis in patients with high-risk prostate cancer is poor, there is no optional treatment, and the risk of negative side effects is low, which makes the possible benefit of added therapy greater than the possible harm. The reason for excluding patients from curative treatment has been unequivocal metastatic disease taken into account the specificity and sensitivity issue. In our ongoing prospective study, survival as well as biochemical response will be assessed.

Conclusions

¹¹C-acetate PET/CT for staging of prostate cancer influences treatment strategy in a substantial way and the use of ¹¹C-acetate PET/CT seems to be of value in clinical practice for previously untreated high-risk patients, although the method needs further validation. The overall observed proportion of ¹¹C-acetate PET/CT-positive pelvic lymph nodes is higher than the estimated pre-treatment nomogram risk, suggesting the nomogram might underestimate the risk. Prostate SUV_{max} is positively correlated to the presence of suspected pelvic lymph node metastases in ¹¹C-acetate PET/CT and to PSA. Further long-term studies are needed to evaluate the impact of ¹¹C-acetate PET/CT findings on patient outcome and survival.

Abbreviations

CECT: contrast-enhanced computed tomography; FDG: fluoro-deoxy-glucose; HCC: hepatocellular carcinoma; i.v.: intravenous; LN: lymph node; OR: odds ratio; PET/CT: positron emission tomography/computed tomography; PSA: prostate-specific antigen; RCC: renal cell carcinoma; ROI: region of interest; RT: radiotherapy; SUV: standardised uptake value.

Competing interests

Parts of this material have previously been published by the authors with the title 'Prostate cancer staging with ¹¹C-acetate-PET/CT' at the electronic poster exhibition EPOS at the European Congress of Radiology 2014. The authors declare that they have no other competing interests.

Authors' contributions

SS performed the reading of the ^{11}C -acetate PET/CT examinations, analysed the material and produced the manuscript. CTk and KR designed the study and helped to draft the manuscript. CTk also collected data from the patients' medical records. MatÖ set up the radiochemistry production of ^{11}C -acetate and critically revised the manuscript. MarÖ, JA and TS revised the manuscript and contributed with important intellectual content. All authors read and approved the final manuscript.

Acknowledgements

This study was supported by Umeå University, Västerbotten County Council (ALF) and Cancer Research Foundation Norrland. We thank Hans Stenlund who provided helpful assistance in the statistical analysis.

Received: 2 June 2014 Accepted: 28 September 2014

Published online: 09 October 2014

References

- SEER Stat Fact Sheets: Prostate Cancer. In [http://seer.cancer.gov/statfacts/html/prost.html]
- Nationella prostatacancerregistret. In [http://www.cancercentrum.se/sv/INCA/kvalitetsregister/Prostatacancer332/]
- Kessler B, Albertsen P: *The natural history of prostate cancer*. Urol. Clin: North Am; 2003.
- Cagiannos I, Karakiewicz P, Eastham JA, Ohori M, Rabbani F, Gerigk C, Reuter V, Graefen M, Hammerer PG, Erbersdobler A, Huland H, Kupelian P, Klein E, Quinn DI, Henshall SM, Grygiel JJ, Sutherland RL, Stricker PD, Morash CG, Scardino PT, Kattan MW: **A preoperative nomogram identifying decreased risk of positive pelvic lymph nodes in patients with prostate cancer**. *J Urol* 2003, **170**:1798–803.
- Fonteyne V, Lumen N, Ost P, Van Praet C, Vandecasteele K, De Gersem IW, Villeirs G, De Neve W, Decaestecker K, De Meerleer G: **Hypofractionated intensity-modulated arc therapy for lymph node metastasized prostate cancer: early late toxicity and 3-year clinical outcome**. *Radiother Oncol* 2013, **109**:229–34.
- Warburg O, Posener K, Negelein E: *On Metabolism of Tumors*. London: Constable; 1930, **152**:319–344
- Jadvar H: **Prostate cancer: PET with 18F-FDG, 18F- or 11C-acetate, and 18F- or 11C-choline**. *J Nucl Med* 2011, **52**:81–9.
- Castellucci P, Jadvar H: **PET/CT in prostate cancer: non-choline radiopharmaceuticals**. *Q J Nucl Med Mol Imag* 2012, **56**:367–74.
- Röthke MC, Afshar-Oromieh A, Schlemmer H-P: **Potential of PET/MRI for diagnosis of prostate cancer**. *Radiologe* 2013, **53**(8):676–81.
- Buchegger F, Garibotto V, Zilli T, Allainmat L, Jorcano S, Veas H, Rager O, Steiner C, Zaidi H, Seimbielle Y, Ratib O, Miralbell R: **First imaging results of an intraindividual comparison of (11)C-acetate and (18)F-fluorocholine PET/CT in patients with prostate cancer at early biochemical first or second relapse after prostatectomy or radiotherapy**. *Eur J Nucl Med Mol Imag* 2014, **41**(1):68–70.
- Picchio M, Berardi G, Fodor A, Busnardo E, Crivellaro C, Giovacchini G, Fiorino C, Kirienko M, Incerti E, Messa C, Gianolli L, Di Muzio N: **(11)C-Choline PET/CT as a guide to radiation treatment planning of lymph-node relapses in prostate cancer patients**. *Eur J Nucl Med Mol Imag* 2014, **41**(7):1270–9.
- Vävere AL, Kridel SJ, Wheeler FB, Lewis JS: **1-11C-acetate as a PET radiopharmaceutical for imaging fatty acid synthase expression in prostate cancer**. *J Nucl Med* 2008, **49**:327–34.
- Oyama N, Akino H, Kanamaru H, Suzuki Y, Muramoto S, Yonekura Y, Sadato N, Yamamoto K, Okada K: **11C-acetate PET imaging of prostate cancer**. *J Nucl Med* 2002, **43**:181–6.
- Czernin J, Benz MR, Allen-Auerbach MS: **PET imaging of prostate cancer using C-acetate**. *PET Clin* 2009, **4**:163–72.
- Haseebuddin M, Dehdashti F, Siegel BA, Liu J, Roth EB, Nepple KG, Siegel CL, Fischer KC, Kibel AS, Andriole GL, Miller TR: **11C-acetate PET/CT before radical prostatectomy: nodal staging and treatment failure prediction**. *J Nucl Med* 2013, **54**:699–706.
- Prostate cancer nomograms: pre-treatment**. [http://nomograms.mskcc.org/Prostate/PreTreatment.aspx]
- Stroom J, Blaauwgeers H, van Baardwijk A, Boersma L, Lebesque J, Theuws J, van Suylen RJ, Klomp H, Liesker K, van Pel R, Siedschlag C, Gilhuijs K: **Feasibility of pathology-correlated lung imaging for accurate target definition of lung tumors**. *Int J Radiat Oncol Biol Phys* 2007, **69**:267–75.
- Biehl KJ, Kong F-M, Dehdashti F, Jin J-Y, Mutic S, El Naqa I, Siegel BA, Bradley JD: **18F-FDG PET definition of gross tumor volume for radiotherapy of non-small cell lung cancer: is a single standardized uptake value threshold approach appropriate?** *J Nucl Med* 2006, **47**:1808–12.
- Walz J, Bladou F, Rousseau B, Laroche J, Salem N, Gravis G, Briganti A, Chun FK, Karakiewicz PI, Fournier G: **Head to head comparison of nomograms predicting probability of lymph node invasion of prostate cancer in patients undergoing extended pelvic lymph node dissection**. *Urology* 2012, **79**:546–51.
- Schiavina R, Scattoni V, Castellucci P, Picchio M, Corti B, Briganti A, Franceschelli A, Sanguedolce F, Bertaccini A, Farsad M, Giovacchini G, Fanti S, Grigioni WF, Fazio F, Montorsi F, Rigatti P, Martorana G: **11C-choline positron emission tomography/computerized tomography for preoperative lymph-node staging in intermediate-risk and high-risk prostate cancer: comparison with clinical staging nomograms**. *Eur Urol* 2008, **54**(2):392–401.
- Weingartner K, Ramaswamy A, Bittinger A, Gerharz EW, Voge D, Riedmiller H: **Anatomical basis for pelvic lymphadenectomy in prostate cancer: results of an autopsy study and implications for the clinic**. *J Urol* 1996, **156**:1969–71.
- Roca Edreira A, Aguilera Tubet C, Villanueva Peña A, Ballester Diego R, Zubillaga Guerrero S: **Mediastinal lymph nodes during the course of a metastatic prostate cancer**. *Actas Urol Esp* 2007, **31**:693–5. discussion 695.
- Tsujino K, Sasada S, Kawahara K, Terada H, Komori C, Suzuki H, Okamoto N, Kobayashi M, Hirashima T, Matsui K, Kawase I: **A case of prostatic adenocarcinoma clinically presenting as supraclavicular and mediastinal lymphadenopathy**. *Nihon Kokyuki Gakkai Zasshi* 2007, **45**:648–53.
- Perez NE, Maryala S, Seren S, Feng J, Pansare V, Dhar R: **Metastatic prostate cancer presenting as mediastinal lymphadenopathy identified by EUS with FNA**. *Gastrointest Endosc* 2007, **65**(6):948–9.
- Arnheim FK: **Carcinoma of the prostate; a study of the postmortem findings in 176 cases**. *J Urol* 1948, **60**:599–603.
- Kato T, Tsukamoto E, Kuge Y, Takei T, Shiga T, Shinohara N, Katoh C, Nakada K, Tamaki N: **Accumulation of [11C]acetate in normal prostate and benign prostatic hyperplasia: comparison with prostate cancer**. *Eur J Nucl Med Mol Imag* 2002, **29**:1492–5.
- Grassi I, Nanni C, Allegri V, Morigi JJ, Montini GC, Castellucci P, Fanti S: **The clinical use of PET with (11)C-acetate**. *Am J Nucl Med Mol Imag* 2012, **2**:33–47.
- Liu RS: **Clinical application of [C-11]acetate in oncology**. *Clin Positron Imag* 2000, **3**(4):185.
- Kjöhede H, Ahlgren G, Almquist H, Liedberg F, Lyttkens K, Ohlsson T, Bratt O: **Combined 18F-fluorocholine and 18F-fluoride positron emission tomography/computed tomography imaging for staging of high-risk prostate cancer**. *BJU Int* 2012, **110**:1501–6.
- Selzner M, Hany TF, Wildbrett P, McCormack L, Kadry Z, Clavien P-A: **Does the novel PET/CT imaging modality impact on the treatment of patients with metastatic colorectal cancer of the liver?** *Ann Surg* 2004, **240**:1027–34. discussion 1035–6.
- Abdelmalik AG, Alenezi S, Muzaffar R, Osman MM: **The incremental added value of including the head in (18)F-FDG PET/CT imaging for cancer patients**. *Front Oncol* 2013, **3**:71.
- Tural D, Selcukbiricik F, Sager S, Akar E, Yildiz O, Serdengecti SH: **PET-CT changes the management and improves outcome in patients with recurrent colorectal cancer**. *J Cancer Res Ther Medknow Publications and Media Pvt Ltd* 2014, **10**:121–6.

doi:10.1186/s13550-014-0055-1

Cite this article as: Strandberg et al.: ^{11}C -acetate PET/CT in pre-therapeutic lymph node staging in high-risk prostate cancer patients and its influence on disease management - a retrospective study. *EJNMMI Research* 2014 4:55.