Radboud Repository

Radboud University Nijmegen

PDF hosted at the Radboud Repository of the Radboud University Nijmegen

The following full text is a publisher's version.

For additional information about this publication click this link.
http://hdl.handle.net/2066/25633

Please be advised that this information was generated on 2021-09-19 and may be subject to change.

Journal of Neuropathology and Experimental Neurology
Copyright © 1997 by the American Association of Neuropathologists
Vol. 56, No. 7
July, 1997
pp. 751–761

Differences between the Pathogenesis of Senile Plaques and Congophilic Angiopathy in Alzheimer Disease

MARCEL M. VERBEEK, PIET EIKELENBOOM, AND ROBERT M. W. DE WAAL

Key Words: Acute phase; Alzheimer disease; Amyloid β protein; Cerebrovascular amyloidosis; Congophilic angiopathy; Pathogenesis; Senile plaques.

PATHOLOGY OF ALZHEIMER DISEASE

Introduction

Neuropathological examination of the brain after autopsy of an Alzheimer disease (AD) patient will reveal a number of characteristic pathological changes comprising senile plaques, neurofibrillary tangles, congophilic angiopathy (CA) of the vessels, neuropil threads and neuronal cell loss. The amyloid β protein (Aβ) is the major component of both senile plaques and CA. Both lesions are found in the brains from patients with AD, Down syndrome or hereditary cerebral hemorrhage with amyloidosis-Dutch type (HCHWA-D).

Two major types of senile plaques have been identified: classic and diffuse senile plaques, which are both abundant in AD brains. It is suggested that diffuse senile plaques gradually transform into the fibril-containing classic senile plaques (1).

CA is found in both cortical and leptomeningeal vessels of AD and Down syndrome brains. In HCHWA-D patients, severe cerebrovascular Aβ deposition leads to small infarcts and to often fatal hemorrhages in the brains of these patients. A mutation at position 22 of the Aβ sequence, substituting a glutamine for a glutamic acid (2), is directly related to the deposition of Aβ in diffuse senile plaques and CA. Another type of Aβ deposition, dyshoric angiopathy (DA), is observed around cortical vessels and is characterized by the infiltration of fine radiating deposits of amyloid into the nearby neuropil, which suggests a vascular origin. The incidence of this type of amyloid deposition is increased proportionally to the severity of CA (3) and is usually found in conjunction with amyloid deposition in pre-capillary arterioles.

Rather than presenting a complete overview of the pathological aspects of these lesions, in this review we will focus on data that support the hypothesis that in AD a different pathogenesis exists for either senile plaques or CA.

From the Department of Pathology, University Hospital Nijmegen, Nijmegen, The Netherlands (MMV, RMWW) and the Department of Psychiatry, Graduate School Neurosciences, Research Institute Neurosciences, Vrije Universiteit Amsterdam, The Netherlands (PE).

Correspondence to: Marcel M. Verbeek, Department of Pathology, University Hospital Nijmegen, P.O. Box 9101, 6500 HB Nijmegen, The Netherlands.

Amyloid Protein

Aβ in Senile Plaques and in Congophilic Angiopathy: Aβ is a fragment of a large protein, designated as the amyloid precursor protein (APP), encoded by a gene on chromosome 21 (see [1] for a review of the cell biology of APP). The Aβ peptide that accumulates in AD brains is heterogeneous at its C-terminus, which results in peptides of 39 to 43 amino acids long. Several studies have been published with regard to the exact length of Aβ in CA and senile plaques using chromatographic and mass spectrometry techniques or by immunohistochemistry using antibodies that specifically recognize either $A\beta_{1-40}$ or $A\beta_{1-42/43}$. Using these C-terminal-specific anti-Aβ antibodies, it was described that diffuse senile plaques in brains from normal individuals and AD patients only contained $A\beta_{1-42/43}$. $A\beta_{1-40}$ was absent from, or present only in a minority of, diffuse senile plaques (4–6). Furthermore, in brains from young Down syndrome patients, HCHWA-D patients, and in the cerebellum of Down syndrome and AD patients, i.e. in conditions in which classic senile plaques are almost completely absent, the diffuse senile plaques were predominantly composed of $A\beta_{1-42/43}$ (6, 7). In contrast, classic senile plaques contained both $A\beta_{1-40}$ and $A\beta_{1-42/43}$ and also shorter Aβ peptides, truncated at the N-terminus, and starting at residue 11 or 17 (5, 6, 8).

The Aβ content of CA differs from that of diffuse senile plaques, but shows similarities to classic senile plaques. Immunohistochemical data indicated that CA in AD and HCHWA-D contained both $A\beta_{1-40}$ and $A\beta_{1-42/43}$ (5, 6, 9, 10), although absence of $A\beta_{1-42}$ from these lesions has been reported as well (4). Therefore, $A\beta_{1-40}$ may be the predominant species deposited in CA (4, 5, 9–11). Similar to CA and classic senile plaques, Aβ in DA was reported to contain both $A\beta_{1-40}$ and $A\beta_{1-42/43}$ (5). CA also contains the N-terminal truncated Aβ peptides starting at residues 11 or 17 (8). However, data from Down syndrome patients of different ages indicated that, whereas $A\beta_{1-42/43}$ deposition precedes $A\beta_{1-40}$ deposition in senile plaques, both isoforms seem to be deposited simultaneously in CA (11). The observation that CA is composed of both $A\beta_{1-40}$ and $A\beta_{1-42/43}$ is confirmed by chemical analysis of amyloid-containing vessels (12).

A number of familial AD cases have been linked to mutations either in the APP gene or in the presenilin

(PS)-1 or PS-2 genes. Similar to cases of sporadic AD, the initial and most abundant Aβ species in these patients is $A\beta_{1-42/43}$ (6, 9, 13, 14). Mutations at APP_{717} or in the PS-1 gene result in an increased Aβ burden in the brain (6, 9, 13, 15), whereas in cases with mutations in the PS-2 gene or at $APP_{670/671}$, the Aβ deposition is comparable to that in sporadic AD (9, 14). Furthermore, in all of these cases of familial AD, the severity and frequency of CA and its Aβ composition were comparable to sporadic AD (6, 9, 13, 14), indicating that neither mutation leads to a predisposition for CA. Apart form the abovementioned HCHWA-D mutation at APP_{693}, which leads to severe CA formation, another mutation at APP_{692} may also lead to increased formation of CA (16). Thus, it is remarkable that mutations within the Aβ region of APP predispose to CA, whereas mutations in APP flanking the Aβ sequence do not lead to increased CA formation.

In conclusion, it is likely that in general $A\beta_{1-42/43}$ is the major component of diffuse senile plaques and that both $A\beta_{1-40}$ and $A\beta_{1-42/43}$ are deposited in classic senile plaques, CA, and DA (4, 6). The differential composition of Aβ in CA and senile plaques and, more importantly, the differences in timing of deposition of Aβ species in these lesions suggest that the Aβ in CA on the one hand, and in senile plaques on the other, is produced by distinct and probably independent mechanisms. This conclusion is supported by observations of cases with familial AD due to mutations in the PS-1 gene or at APP_{717}. Due to these mutations the production of $A\beta_{1-42}$ is increased relative to $A\beta_{1-40}$ (17–19), and, accordingly, parenchymal $A\beta_{1-42}$ deposition is also increased in these patients. However, this is not reflected in changes in the composition of CA, since $A\beta_{1-40}$ remains the predominant isoform in CA of these patients (9, 13), supporting differential effects of these mutations on the pathogenesis of either lesion.

Aβ Fibrillogenesis: Aβ may exist in a soluble form as well as in a β-pleated sheet conformation (20), basically through the β-sheet structure of the residues 14–21 and 29–39/42 (20). $A\beta_{1-42}$ is less soluble and forms fibrils faster than shorter isoforms (21), which indicates that the C-terminal sequence of Aβ is critical in the determination of the solubility of the peptide. The process of amyloid formation in vivo may be seeded or nucleated by trace amounts of amyloid fibrils (21). Progression of amyloid formation may involve the incorporation of potentially soluble Aβ peptides that aggregate onto the initially formed seed. Since $A\beta_{1-42}$ is relatively insoluble compared with $A\beta_{1-40}$, small seeds of $A\beta_{1-42}$ fibrils may grow rapidly by incorporation of $A\beta_{1-40}$, the isoform that is predominantly produced by cultured cells (19). Formation of the fibril seed is, then, the rate-limiting step of amyloidogenesis, an event that apparently does not occur in the diffuse senile plaques of the cerebellar molecular layer because these plaques do not acquire $A\beta_{1-40}$ immunoreactivity or transform into classic senile plaques. Although this "seeding" theory sounds attractive, it cannot explain the differences in physical state of Aβ between CA and diffuse senile plaques. Whereas in the former lesion Aβ mostly assembles into fibrils, in the latter, Aβ is in a nonaggregated form, despite the fact that both lesions contain $A\beta_{1-42/43}$. Therefore, $A\beta_{1-42/43}$ is not the only factor that determines the assembly state of Aβ. Other molecules potentially involved in the formation of amyloid are the amyloidogenic non-Aβ component of amyloid (NAC) (22) or Aβ peptides modified by advanced glycation (23), but both these components are produced in CA as well as in senile plaques. Locally produced Aβ-associated factors, produced either in the vasculature or in the brain parenchyma, may also affect Aβ fibrillogenesis. The role of such factors will be discussed in paragraph 4.

Cells

Cellular Involvement in the Generation of Senile Plaques and Congophilic Angiopathy: In situ hybridization studies demonstrated that mRNA encoding for APP_{695} and $APP_{751/770}$ was predominantly found in cortical pyramidal neurons (24) in both normal and AD brains, but not in glial or endothelial cells. Immunohistochemical staining of brain sections for APP confirmed that neurons of normal and AD brains, but not microglial cells or astrocytes, expressed APP (25). Furthermore, in classic senile plaques, dystrophic neurites are APP positive (25, 26). These data suggest that neurons are the primary producers of APP in the brain parenchyma.

Clusters of activated microglial cells, indicative of an inflammatory response, are associated with classic senile plaques (27, 28). Given the absence of microglial APP expression, it is possible that they have a secondary function, e.g. in processing Aβ into fibrils (29). Alternatively, their expression of Fc and complement receptors (30), and of a marker indicative of an enhanced lysosomal activity (31), suggests that they function as phagocytes and remove Aβ (32). An increased astrocyte reactivity can also be observed around senile plaques, probably following microglial activation (28).

In summary, it is likely that neurons are the major candidates for the production of APP and Aβ in senile plaques, whereas microglial cells and astrocytes may have an accessory function in senile plaque formation. Activated glial cells are presumably involved in generating an inflammatory response to Aβ production that may contribute to the formation of amyloid-containing classic senile plaques and to neuronal pathology (see below) (reviewed in [33]). The observations that cerebellar diffuse senile plaques are not accompanied by activated microglial and astrocytic cells (31, 34) and that these plaques do not mature into classic senile plaques and lack neuronal pathology support this view.

The production of Aβ in CA is likely mediated by different cell types. It has been suggested that Aβ fibrils

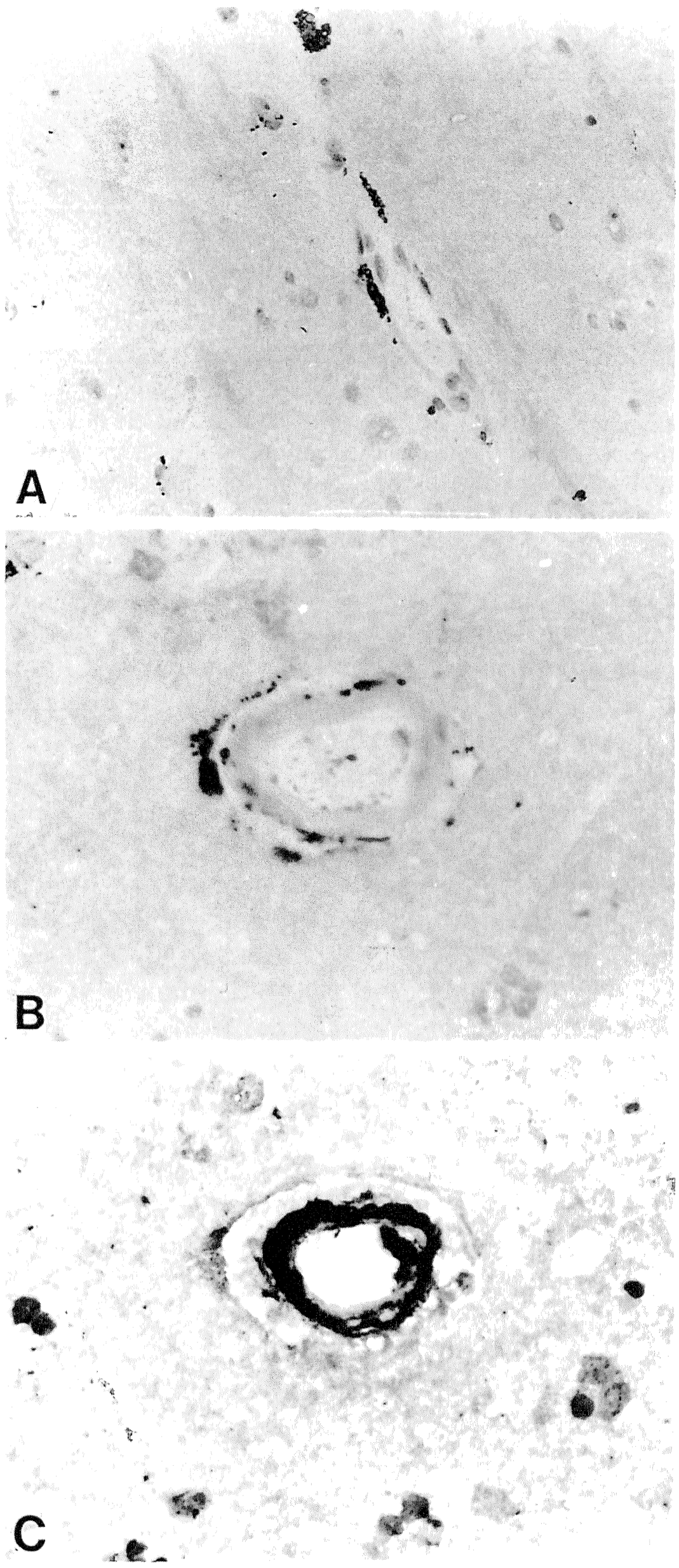

Fig. 1. Immunohistochemical staining of cerebral vessels in control (A) and in serial sections of AD brains (B, C) with a marker of activated microglia/macrophages (Mab 25F9; A, B) and with anti-Aβ (C). The staining of perivascular cells for 25F9 in a noncongophilic vessel (A) is comparable with that in a vessel affected by Aβ deposition (B, C). Panel A is reproduced from (31) with permission of the publisher.

of large vessels are produced by smooth muscle cells, in accordance with their close association with early Aβ deposits in CA (35, 36). In support of this suggestion, smooth muscle cells of the brain—but not endothelial cells—express APP (37). Besides, cultured smooth muscle cells, which are isolated from leptomeninges, produce and secrete APP and Aβ (38), and brain microvessels contain a 22 kDa Aβ-spanning APP fragment (35), which indicates that APP is proteolysed within the cerebral vasculature. Although it can be argued that the Aβ in CA is derived from the circulation, both the absence of Aβ deposits in organs other than the brain and the above-mentioned data suggest a local production. Furthermore, in support of this view, a recent study described that high Aβ levels in plasma do not lead to cerebral deposition of Aβ (39).

A situation comparable to large vessels may apply to capillaries. Pericytes are a prominent and ubiquitous cellular component of the microvasculature, with properties comparable to smooth muscle cells. Pericytes share several antigenic determinants with smooth muscle cells, but they do not express monocyte/macrophage markers (40 and our unpublished observations). In analogy to the putative involvement of smooth muscle cells in Aβ formation in large vessels, the pericyte may be the cell responsible for the production of APP and Aβ in small-sized arterioles and capillaries. Pericytes isolated from human adult brain capillaries (40) produce and secrete APP in vitro, similar to smooth muscle cells (41), but their capacity to produce Aβ or Aβ fibrils remains to be established.

Perivascular microglial cells or so-called perivascular cells that originate from the monocyte lineage (42) may be engaged in the transformation of soluble Aβ into fibrils (43). However, in addition to being involved in the production of Aβ fibrils, perivascular cells and perivascular microglial cells may also be involved in the phagocytosis of Aβ fibrils, a role that is more compatible with their functional relationship with macrophages. However, neither we nor others (31, 44) observed an activation or accumulation of these cells around congophilic vessels in AD brains (Fig. 1). In contrast, a markedly increased monocyte/macrophage marker immunoreactivity was observed in CA in HCHWA-D patients (44).

In summary, it seems likely that different cell types are responsible for the generation of senile plaques and CA. Smooth muscle cells and pericytes on the one hand and neurons on the other may each have their individual machinery to produce Aβ, which leads to the variations observed in chemical and physical state of Aβ in the respective lesions. In the brain parenchyma the production of fibrillar Aβ is associated with an inflammatory response as demonstrated by the activation of microglial cells. In contrast, deposition of fibrillar Aβ in CA of AD patients does not seem to be accompanied by such a response, whereas evidence is emerging for a more robust inflammatory response in CA of HCHWA-D patients, which might be related to a different biological activity of the mutated Aβ in these patients.

There are indications that, depending on the degree of deposition, CA may lead to vascular malfunctioning. In contrast to the relatively mild CA in the majority of AD brains, patients with sporadic and severe CA may occasionally suffer from cerebral hemorrhages due to vessel rupture. In these advanced stages of CA, an increase or activation of monocyte/macrophage lineage cells is observed that, in exceptional cases, may lead to granulomatous angiitis (45).

Cellular Degeneration in Senile Plaques and in Congophilic Angiopathy: The presence of neuronal degeneration in AD brains is represented by the formation of intraneuronal NFTs and dystrophic neurites. Several studies have indicated that neuronal degeneration may be related to the presence of Aβ, but this molecule may also exert protective effects on neuronal cells: soluble Aβ, added in low doses to cultures of freshly isolated neurons, may enhance the rate of survival (46). However, reports describing a toxic effect of Aβ on neuronal cells are more numerous. Injection of isolated human amyloid cores containing aggregated Aβ or synthetic Aβ into rat brains induced neurodegeneration (47), which indicates that the peptide has a direct toxic effect. When administered to cultured neurons, Aβ peptides, especially when aggregated, induced neurotoxicity, loss of presynaptic terminals, and the development of dystrophic neurites (48, 49). The neurotoxic effect of pre-aggregated or soluble Aβ could be blocked by the amyloid-binding dye Congo red (48), which is probably based on the inhibition of fibril formation or binding to preformed fibrils. These in vitro data on Aβ-mediated neuronal toxicity correlate well with the pathology in the AD brain. Diffuse senile plaques that are composed of nonfibrillar Aβ lack any sign of neuronal degeneration, whereas in classic senile plaques, Aβ fibrils and neurodegenerative changes coincide.

Aβ may also cause neurodegeneration via indirect pathways. Neuronal cell death may be mediated by formation of the complement membrane attack complex (C5b-9), which has been demonstrated in dystrophic neurites and neuropil threads (50). Furthermore, Aβ may stimulate microglial cells to produce neurotoxic substances, such as cytokines, proteases, and free radicals (51). Also, astrocytes may contribute to neuronal damage by producing growth inhibitory compounds that impair neurite outgrowth (52).

An important feature of CA is the degeneration of cells of the vascular wall. Several ultrastructural or immunohistochemical studies have demonstrated that endothelial cells, pericytes and smooth muscle cells (43, 53, 54) undergo degeneration in amyloid-laden vessels. Sharply in contrast with the effects of synthetic Aβ peptides on neurons are the effects on cultured vascular cells. Whereas degeneration of cultured neurons can be induced by different Aβ peptides ($A\beta_{1-39}$, $A\beta_{1-40}$ or $A\beta_{1-42}$), especially when aggregated, only $A\beta_{1-42}$—but not $A\beta_{1-40}$—caused degeneration of cultured leptomeningeal smooth muscle cells and pericytes (38, 41). Moreover, only soluble Aβ was found to induce these effects, and pre-aggregation of the peptide completely abolished its effects (55). A remarkable inversed effect was observed when synthetic Aβ peptides carrying the HCHWA-D mutation were applied to these cells in vitro. A robust degenerating effect on cultured smooth muscle cells and pericytes was observed with HCHWA-D $A\beta_{1-40}$, but not with HCHWA-D $A\beta_{1-42}$ (41, 56). This effect could be inhibited by Congo red (41) (Table 1), which suggests that Aβ assembly is a common mechanism in the destructive effects of Aβ on both vascular cells and neurons. The effects of Aβ peptides carrying the HCHWA-D mutation on cultured neurons have not been studied.

TABLE 1

Incubation	Pericytes	Smooth muscle cells
Control	8.39 ± 1.37	3.20 ± 2.17
$A\beta_{1-40}$	2.22 ± 1.10	2.32 ± 1.08
HCHWA-D $A\beta_{1-40}$	34.20 ± 21.35	20.48 ± 1.19
Congo red	6.06 ± 4.84	0.21 ± 0.36
HCHWA-D $A\beta_{1-40}$ Congo red	6.48 ± 4.24	0.25 ± 0.43

Effect of incubation for 6 days with 25 μM nonaggregated synthetic HCHWA-D $A\beta_{1-40}$ and of Congo red on the viability of cultured human brain pericytes and smooth muscle cells (percentage of dead cells of triplicate incubations [mean ± SD]). Reproduced from (41) with permission.

In summary, these studies indicate that the mechanisms that lead to the degeneration of either neuronal or vascular cells may be essentially different and depend on the chemical and physical state of Aβ, which implies that the cellular pathology observed in senile plaques and CA may have an independent etiology. Moreover, inflammatory reactions mediated by microglial cells may significantly contribute to the neuronal damage, whereas vascular degeneration in AD usually proceeds in the virtual absence of an inflammatory response. The severe vascular pathology of HCHWA-D can at least in part be explained by the profound degenerating effects of HCHWA-D $A\beta_{1-40}$ on smooth muscle cells and pericytes, although inflammatory mechanisms may have an additional effect on these cells in HCHWA-D brains.

Aβ-associated Proteins in Senile Plaques and in Congophilic Angiopathy

Apart from Aβ itself, several Aβ-associated proteins have been identified in senile plaques (see Table 2). Although many more proteins have been identified than those mentioned here, this review only focuses on those

TABLE 2
Aβ-associated Components in Various Aβ-containing Lesions in AD Brains

Component	Cerebral cortex		Cerebellar cortex		CA	DA	References
	Diffuse SP	Classic SP	Diffuse SP	Classic SP			
Complement factors							
C1q	+	+	±	+	+	ND	(59, 62, 63, 70, 78, 79)
C3d	+	+	±	+	ND	ND	(59, 62, 63, 70)
C4c	+	+	+	+	+	ND	(59, 62, 78, 79)
C4bp	+	+	+	+	+	ND	(50, 62, 63, 78, 79)
Clusterin	+	+	−	+	ND	ND	(50, 62)
Vitronectin	+	+	ND	ND	ND	ND	(50)
Acute phase proteins							
α_1-ACT	+	+	±	+	±	+	(60, 61, 63, 70)
α_2-macroglobulin	−	+	−	+	−	ND	(61, 62)
Amyloid P	+	+	±	+	+	ND	(62–64, 70)
Miscellaneous							
ICAM-1	+	+	−	+	−	+	(65, 68)
HSPG	+	+	−	+	+	ND	(57, 69)
ApoE	+	+	+	+	+	ND	(58, 62)
APP	−	+[1]	−	ND	+	ND	(26, 37)
NAC	+	+	ND	ND	+	ND	(22)

The presence (+) or absence (−) of expression is listed. When conflicting data have been described, a (±) is indicated. See text for details. SP: senile plaques; CA: congophilic angiopathy, cerebrovascular amyloidosis; DA: dyshoric angiopathy; C4bp: C4-binding protein; α_1-ACT: α_1-antichymotrypsine; ICAM-1: intercellular adhesion molecule-1; HSPG: heparan sulfate proteoglycan; ApoE: apolipoprotein E; APP: amyloid precursor protein; NAC: non-Aβ component of amyloid.
[1] Localized in dystrophic neurites.

components that have been studied in more than one report or in different Aβ-containing lesions. These factors include heparan sulfate proteoglycan (HSPG) (57), ApoE (58), and several inflammatory proteins, which include the complement factors C1q, C3, C4 (59), the complement inhibitors C4-binding protein (C4bp), clusterin (ApoJ) and vitronectin (50), the acute phase proteins α_1-antichymotrypsin (α_1-ACT) (60, 61) and amyloid P component (62–64), and the cytokine-inducible adhesion molecule ICAM-1 (65) (Fig. 2). The presence of all these components has been unequivocally demonstrated in cortical diffuse and classic senile plaques. Also, in cortical brain sections from young Down syndrome and HCHWA-D patients, where usually no classic senile plaques are found, α_1-ACT, complement factors and HSPG can be found (66, 67). The acute phase protein α_2-macroglobulin is only found in classic senile plaques, whereas APP is expressed in dystrophic neurites in this plaque type (26, 61, 62).

Only a limited number of the above-mentioned factors are expressed in cerebellar diffuse senile plaques. In these lesions ApoE has been detected (62), but we did not observe ICAM-1 expression in these lesions (68) (Fig. 2). HSPG, clusterin and α_2-macroglobulin were also absent (62, 69). Reports about early complement factors, α_1-ACT and amyloid P component are conflicting (62, 63, 70), which probably indicates that their expression is low or depends on the pathological state of the tissue. Remarkably, we observed that ICAM-1 is expressed in the rare classic senile plaques of the granular or Purkinje cell layers of the cerebellum (68). Other groups also reported expression of HSPG and α_2-macroglobulin in these classic senile plaques (62, 69).

An explanation for the absence of several Aβ-associated factors from cerebellar diffuse senile plaques may be that they are produced during the transformation of diffuse senile plaques into classic senile plaques and may affect this transformation process. The production of Aβ-associated components may be determined by the cell populations of specific brain regions, e.g. the cerebral cortex vs the cerebellum. Neuronal or glial cells may have a different vulnerability to Aβ and a differential capacity to produce Aβ-associated factors, and there may be diminished interactions between glial and neuronal cells in the cerebellum due to lower cell numbers compared with the cerebral cortex. Although the Aβ of diffuse senile plaques is in a relatively "soluble" form, it is not cleared from the brain parenchyma, which indicates that it is retained in the neuropil via binding to other factors. Several of the Aβ-associated factors, such as ApoE, α_1-ACT, C1q, clusterin, and HSPG, can bind to Aβ (71–75). The Aβ-associated components α_1-ACT, ApoE (76), C1q (73) and HSPG (77) may accelerate Aβ fibril formation, as was observed under various experimental conditions. However, the Aβ-associated protein

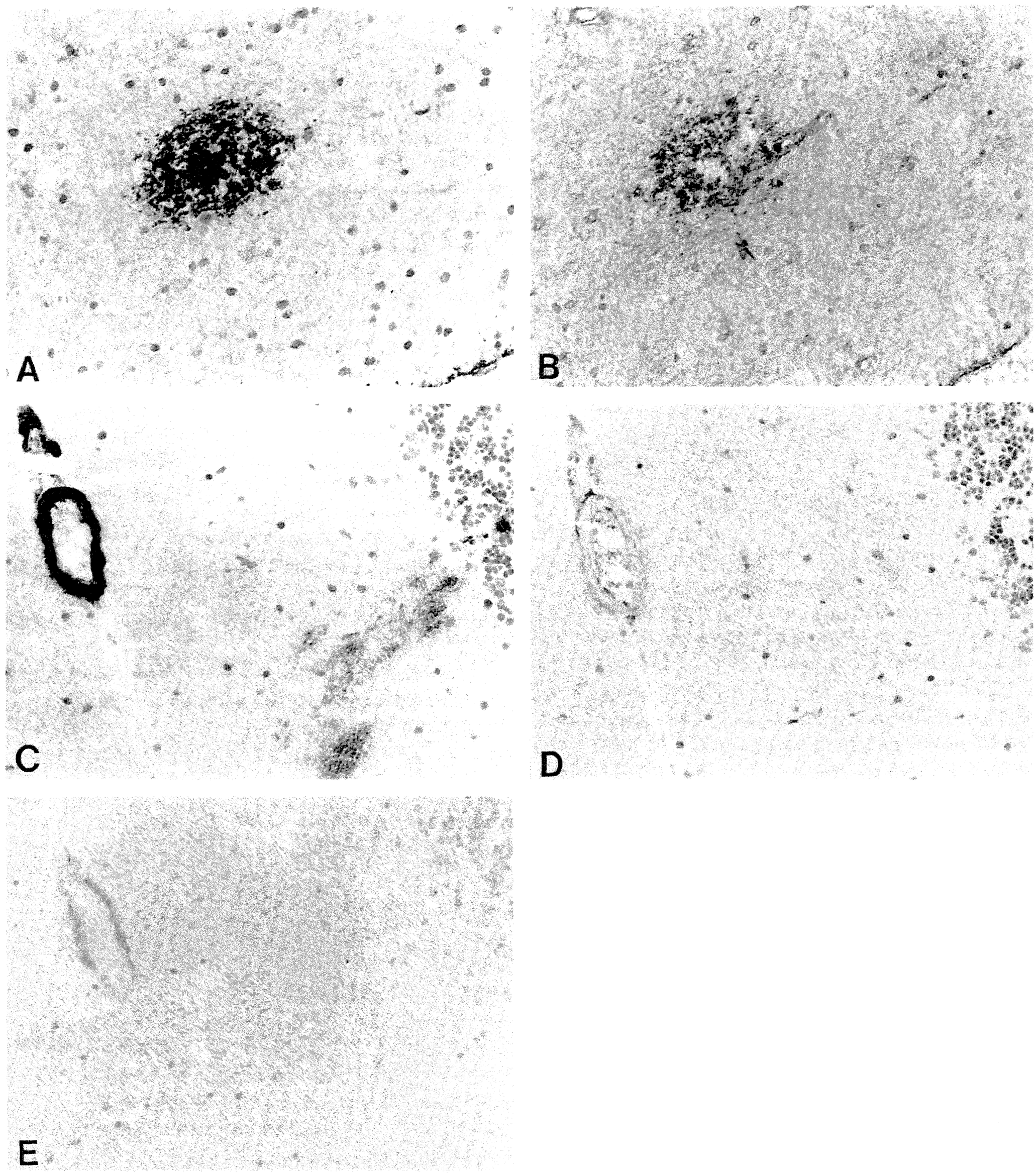

Fig. 2. Immunohistochemical staining of serial sections of AD cerebral cortex (A, B) and cerebellum (C, D, E) for Aβ (A, C), ICAM-1 (B, D), and Congo red (E). Senile plaques in the cerebral cortex are ICAM-1 positive. Diffuse senile plaques in the cerebellum do not stain for ICAM-1. Panels C-E are reproduced from (68) with permission of the publisher.

clusterin and also α_1-ACT may inhibit Aβ fibril formation (72, 74). Therefore, it is likely that Aβ fibrillogenesis is determined by a balance between Aβ fibril-promoting and fibril-preventing factors.

In contrast to senile plaques of the cerebral cortex, a number of inflammation-associated proteins are not expressed in CA. In a study in which a number of different antibodies were used, neither α_1-ACT nor α_2-macroglobulin were detected in CA (61), although another study reported α_1-ACT reactivity in some vessels (60). Also, we found that ICAM-1 is not colocalized with vascular amyloid, although its expression may be increased in cells of Aβ-affected vessels (68) (Fig. 3). The complement factors C1q, C4d and C4bp were identified in CA (78, 79),

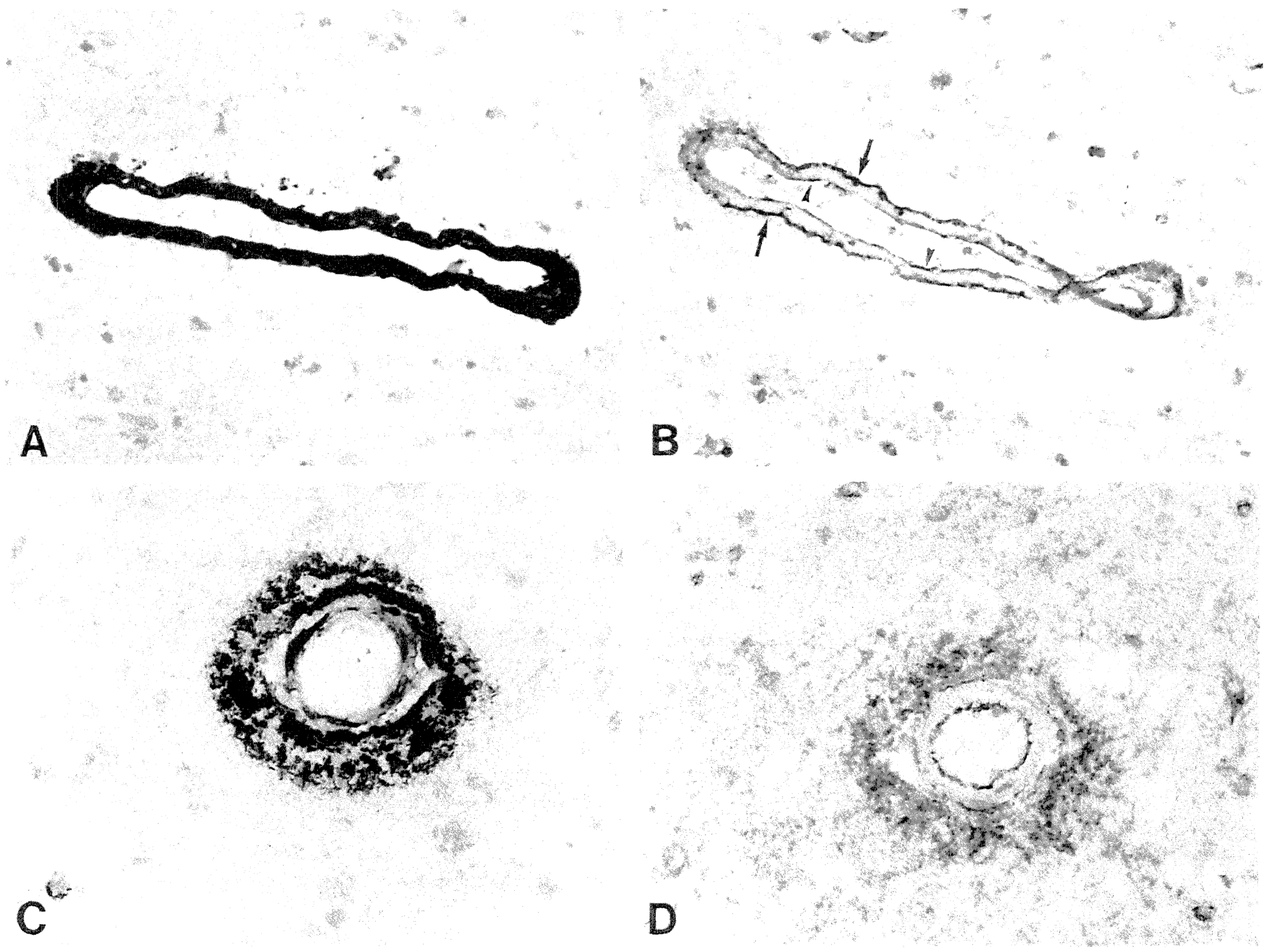

Fig. 3. Immunohistochemical staining of vessels affected by congophilic angiopathy (CA) (A, B) and dyshoric angiopathy (DA) (C, D) in serial sections of AD cerebral cortex for Aβ (A, C) and ICAM-1 (B, D). ICAM-1 does not colocalize with Aβ in CA (A, B), but is clearly expressed by endothelial cells (arrowheads) and cells in a perivascular position (arrows). In DA lesions ICAM-1 staining colocalizes with Aβ staining (C, D). Reproduced from (68) with permission from the publisher.

but late complement components were not detected. Also, HSPG (57), amyloid P component (64), APP (37), NAC (22), and ApoE (58) were found in vessels affected by CA. The number of studies that describe the expression of Aβ-associated factors in DA in the cerebral cortex are scarce. In contrast to the amyloid deposited within the vasculature, our studies indicated that DA lesions were immunopositive for both α_1-ACT and ICAM-1 (61, 68) (Fig. 3).

Considering the absence of several inflammation-associated proteins in CA, ApoE and HSPG may be especially important in the formation of Aβ fibrils in the cerebral vasculature. ApoE is present in meningeal vessels even before Aβ deposition can be observed, and ApoE ϵ4 allele frequency is associated with the severity of CA (80–82). Since both ApoE and HSPG may accelerate Aβ fibril formation, it is very well possible that these factors shift the balance between nonfibrillar and fibrillar Aβ in the cerebral vasculature towards the latter form, which is abundantly present in CA. Besides, since early Aβ deposits in CA have been identified close to the basement membrane (36), an additional mechanism in the formation of CA may be the interaction of components of the basement membrane (83) with APP or Aβ. Some of these components (collagen IV, laminin) have been identified in classic senile plaques (84). Therefore, extracellular matrix components may be involved during the early stages of Aβ deposition in CA, but, in contrast, only during the later phases of senile plaque formation.

The role of ApoE in relation to cerebrovascular pathology is substantiated by observations in a group of patients with cerebral hemorrhage linked to severe CA. These patients—in contrast with AD patients with generally mild CA—demonstrated not only an increased ApoE ϵ4 allele frequency (81), but also an increased ϵ2 allele frequency (85, 86). These data suggest that the ϵ2 allele might protect against the development of AD, but independently may increase the risk of CA-related hemorrhages.

In summary, the production of fibrillar Aβ does not always seem to be accompanied by an inflammatory response. Both CA and classic senile plaques contain fibrillar Aβ, but an inflammatory response is—with the

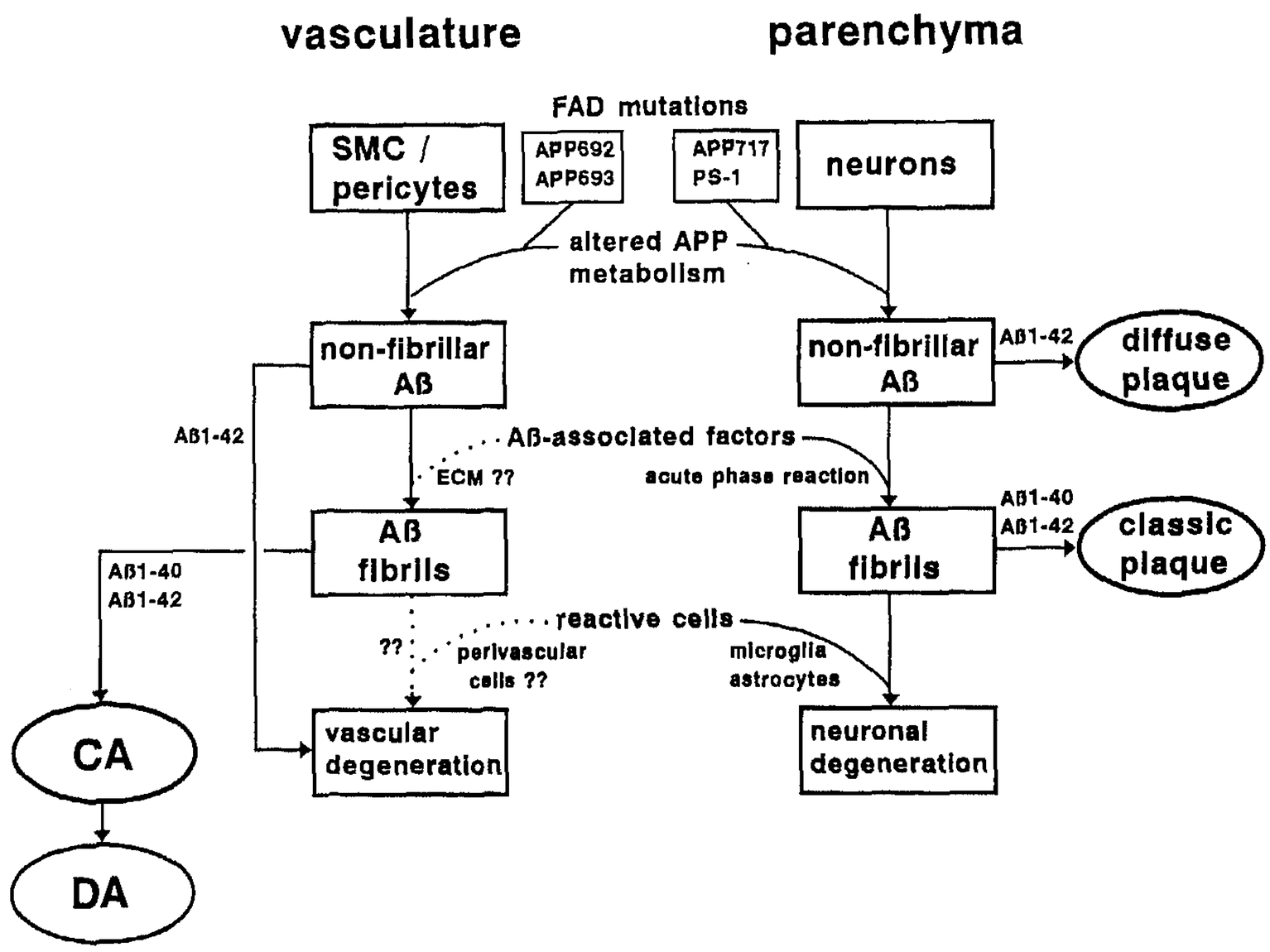

Fig. 4. A model for a different pathogenesis of cerebrovascular amyloidosis and senile plaques. Altered APP metabolism leads to the production of nonfibrillar Aβ by vascular cells and neurons. Mutations at APP_{692} or APP_{693} may lead to increased vascular Aβ production, and mutations in the PS-1 gene or at APP_{717} may lead to increased parenchymal Aβ production. In the brain parenchyma, nonfibrillar Aβ gradually transforms into fibrils, a process that is probably affected by Aβ-associated proteins and an acute phase reaction. The involvement of Aβ-associated proteins and of ECM components in the formation of Aβ fibrils in CA is less clear. Aβ fibrils cause neuronal degeneration. Non-fibrillar Aβ is toxic to smooth muscle cells/pericytes, but a role for aggregated Aβ in this process cannot be entirely excluded. The formation of Aβ fibrils leads to the activation of glial cells that may be engaged in Aβ fibril formation or removal. According to this model, formation of DA follows CA formation. SMC: smooth muscle cells; APP: amyloid precursor protein; Aβ: amyloid β protein; ECM: extracellular matrix; CA: cerebrovascular amyloidosis (congophilic angiopathy); DA: dyshoric angiopathy; PS: presenilin; FAD: familial Alzheimer disease.

exception of rare cases of vasculitis—evoked only in the latter lesion, which contributes significantly to a different pathogenesis of either lesion. The observations on DA clearly illustrate this different response to amyloid because inflammatory products are only generated when the vascular amyloid penetrates the brain parenchyma. Although pericytes and smooth muscle cells are able to produce inflammatory reaction products such as ICAM-1 (40) and α_1-ACT (our unpublished observations), they do not deposit these factors in CA. The physical state of Aβ in senile plaques may be affected by a number of inflammatory proteins. Other factors, such as basement membrane components, may affect Aβ fibrillogenesis in CA, whereas ApoE and HSPG may be involved in Aβ fibril formation in both senile plaques and CA.

CONCLUDING REMARKS

In this review we summarized data from studies in which a variety of analytical approaches were used to demonstrate that the structure, composition and pathogenesis of CA is different from that of senile plaques. The differences in Aβ isoforms that constitute the lesions, the effects of mutations in the APP or PS genes, the expression of Aβ-associated factors, the cell types involved in Aβ production, and the mechanisms of Aβ-mediated cellular degeneration all indicate that the pathogenesis of CA is different from that of senile plaques (Fig. 4). One of the central issues that leads us to speculate that CA and senile plaques have a different pathogenesis is that during the formation of classic senile plaques an inflammatory reaction is generated that may play a significant role in the formation of Aβ fibrils, whereas this does not occur in CA. Since these fibrils are toxic to neurons, inflammatory reactions contribute to neuronal degeneration by direct and indirect mechanisms. In contrast, the relative absence of such reactions in CA and the lack of toxicity of Aβ fibrils for vascular cells point towards alternative cytotoxic mechanisms in the vasculature. Here, our in vitro data and that of others fit in to suggest that it is the non-fibrillar form of Aβ that directly causes vascular degeneration, independent of inflammatory reactions or Aβ fibril formation.

The pathogenesis of CA has received little attention in the past, as CA was thought to be a pathological lesion of minor importance in the AD brain. However, the arguments summarized in this review warrant a more detailed investigation of its pathogenesis. The impact of CA in AD brains may extend beyond vascular pathology

only. Endothelial cells and, to a lesser extent, pericytes, are involved in maintaining the blood-brain barrier (87). Degeneration of these cells in vessels affected by CA may lead to an impaired functioning of the blood-brain barrier in AD patients, which contributes to a disrupted microcirculation and energy supply to the brain (88), which, in turn, will have profound effects on brain metabolism in general.

It will be very important to study suitable and physiologically relevant cell culture models that include human cerebral glial and neuronal cells on the one hand and vascular cells on the other hand to study the specific processes that lead to senile plaque or CA formation, respectively, in order to gain more insight into the pathobiology of AD. Furthermore, transgenic mice specifically developed to study the pathogenesis of CA rather than senile plaques will provide more insight into the specific mechanisms of CA formation and into its impact on brain metabolism. Since the contribution of CA to the development of dementia and its effect on the formation of senile plaques are barely understood, such future studies may unravel the significance of CA for AD.

ACKNOWLEDGMENTS

We thank Irene Otte-Höller for her assistance with the photography. Supported by grant 970-10-010 from the Netherlands Organization for Scientific Research (NWO).

REFERENCES

1. Selkoe DJ. Cell biology of the amyloid β-protein precursor and the mechanism of Alzheimer's disease. Annu Rev Cell Biol 1994;10: 373–403
2. Levy E, Carman MD, Fernandez-Madrid IJ, et al. Mutation of the Alzheimer's disease amyloid gene in hereditary cerebral hemorrhage, Dutch type. Science 1990;248:1124–26
3. Mandybur TI. The incidence of cerebral amyloid angiopathy in Alzheimer's disease. Neurology 1975;25:120–26
4. Murphy GMJ, Forno LS, Higgins L, Scardina JM, Eng FL, Cordell B. Development of a monoclonal antibody specific for the COOH-terminal of β-amyloid 1-42 and its immunohistochemical reactivity in Alzheimer's disease and related disorders. Am J Pathol 1994;144:1082–88
5. Savage MJ, Kawooya JK, Pinsker LR, et al. Elevated Aβ levels in Alzheimer's disease brain are associated with selective accumulation of $A\beta_{42}$ in parenchymal amyloid plaques and both $A\beta_{40}$ and $A\beta_{42}$ in cerebrovascular deposits. Amyloid. Int J Exp Clin Invest 1995;2:234–40
6. Iwatsubo T, Odaka A, Suzuki N, Mizusawa H, Nukina N, Ihara Y. Visualization of Aβ42(43) and Aβ40 in senile plaques with end-specific monoclonals: Evidence that an initially deposited species is Aβ42(43). Neuron 1994;13:45–53
7. Mann DMA, Iwatsubo T. Diffuse plaques in the cerebellum and corpus striatum in Down's syndrome contain amyloid β protein (Aβ) only in the form of $A\beta_{42(43)}$. Neurodegeneration 1996;5:115–20
8. Iwatsubo T, Saido TC, Mann DMA, Lee VM-Y, Trojanowski JQ. Full-length amyloid-β(1-42[43]) and amino-terminally modified and truncated amyloid-β42(43) deposit in diffuse plaques. Am J Pathol 1996;149:1823–30
9. Mann DMA, Iwatsubo T, Ihara Y, et al. Predominant deposition of Amyloid-$\beta_{42(43)}$ in plaques in cases of Alzheimer's disease and hereditary cerebral hemorrhage associated with mutations in the amyloid precursor protein gene. Am J Pathol 1996;148:1257–66
10. Gravina SA, Ho L, Eckman CB, et al. Amyloid protein (Aβ) in Alzheimer's disease brain. J Biol Chem 1995;270:7013–16
11. Iwatsubo T, Mann DMA, Odaka A, Suzuki N, Ihara Y. Amyloid β protein (Aβ) deposition: Aβ42(43) precedes Aβ40 in Down syndrome. Ann Neurol 1995;37:294–99
12. Roher AE, Lowenson JD, Clarke S, et al. β-Amyloid-(1-42) is a major component of cerebrovascular amyloid deposits: Implications for the pathology of Alzheimer disease. Proc Natl Acad Sci USA 1993;90:10836–40
13. Mann DMA, Iwatsubo T, Cairns NJ, et al. Amyloid β protein (Aβ) deposition in chromosome 14-linked Alzheimer's disease: Predominance of $A\beta_{42(43)}$. Ann Neurol 1996;40:149–56
14. Mann DMA, Iwatsubo T, Nochlin D, Sumi SM, Levy-Lahad E, Bird TD. Amyloid (Aβ) deposition in chromosome 1-linked Alzheimer's disease: The Volga German families. Ann Neurol 1997;41:52–57
15. Scheuner D, Eckman C, Jensen M, et al. Secreted amyloid β-protein similar to that in the senile plaques of Alzheimer's disease is increased in vivo by the presenilin 1 and 2 and APP mutations linked to familial Alzheimer's disease. Nature Med 1996;2:864–70
16. Hendriks L, van Duijn CM, Cras P, et al. Presenile dementia and cerebral haemorrhage linked to a mutation at codon 692 of the β-amyloid precursor protein gene. Nature Genet 1992;1:218–21
17. Lemere CA, Lopera F, Kosik KS, et al. The E280Aβ presenilin 1 Alzheimer mutation produces increased Aβ42 deposition and severe cerebellar pathology. Nature Med 1996;2:1146–50
18. Borchelt DR, Thinakaran G, Eckman CB, et al. Familial Alzheimer's disease-linked presenilin 1 variants elevate Aβ1-42/1-40 ration in vitro and in vivo. Neuron 1996;17:1005–13
19. Suzuki N, Cheung TT, Cai X-D, et al. An increased percentage of long amyloid β protein secreted by familial amyloid β protein precursor (APP717) mutants. Science 1994;264:1336–40
20. Barrow CJ, Zagorski MG. Solution structures of β peptide and its constituent fragments: Relation to amyloid deposition. Science 1991;253:179–82
21. Jarrett JT, Berger EP, Lansbury PT. The carboxy terminus of the amyloid protein is critical for the seeding of amyloid formation: Implications for the pathogenesis of Alzheimer's disease. Biochemistry 1993;32:4693–97
22. Uéda K, Fukushima H, Masliah E, et al. Molecular cloning of cDNA encoding an unrecognized component of amyloid in Alzheimer disease. Proc Natl Acad Sci USA 1993;90:11282–86
23. Vitek MP, Bhattacharya K, Glendening JM, et al. Advanced glycation end products contribute to amyloidosis in Alzheimer disease. Proc Natl Acad Sci USA 1994;91:4766–70
24. Johnson SA, McNeill T, Cordell B, Finch CE. Relation of neuronal APP-751/APP-695 mRNA ratio and neuritic plaque density in Alzheimer's disease. Science 1990;248:854–57
25. Tate-Ostroff B, Majocha RE, Marotta CA. Identification of cellular and extracellular sites of amyloid precursor protein extracytoplasmic domain in normal and Alzheimer disease brains. Proc Natl Acad Sci USA 1989;86:745–49
26. Shoji M, Hirai S, Yamaguchi H, Harigaya Y, Kawarabayashi T. Amyloid β-protein precursor accumulates in dystrophic neurites of senile plaques in Alzheimer-type dementia. Brain Res 1990;512: 164–68
27. Haga S, Akai K, Ishii T. Demonstration of microglial cells in and around senile (neuritic) plaques in the Alzheimer brain. Acta Neuropathol 1989;77:569–75
28. Itagaki S, McGeer PL, Akiyama H, Zhu S, Selkoe D. Relationship of microglia and astrocytes to amyloid deposits of Alzheimer disease. J Neuroimmunol 1989;24:173–82

29. Wegiel J, Wisniewski HM. The complex of microglial cells and amyloid star in three-dimensional reconstruction. Acta Neuropathol 1990;81:116–24
30. Akiyama H, McGeer PL. Brain microglia constitutively express β-2 integrins. J Neuroimmunol 1990;30:81–93
31. Verbeek MM, Otte-Höller I, Wesseling P, et al. A lysosomal marker for activated microglial cells involved in Alzheimer classic senile plaques. Acta Neuropathol 1995;90:493–503
32. Shaffer LM, Dority MD, Gupta-Bansal R, Frederickson RCA, Younkin SG, Brunden KR. Amyloid β protein (Aβ) removal by neuroglial cells in culture. Neurobiol Aging 1995;16:737–45
33. Cotman CW, Tenner AJ, Cummings BJ. β-Amyloid converts an acute phase injury response to chronic injury responses. Neurobiol Aging 1996;17:723–31
34. Mattiace LA, Davies P, Yen S-H, Dickson DW. Microglia in cerebellar plaques in Alzheimer's disease. Acta Neuropathol 1990;80: 493–98
35. Frackowiak J, Zoltowska A, Wisniewski HM. Non-fibrillar β-amyloid protein is associated with smooth muscle cells of vessel walls in Alzheimer disease. J Neuropathol Exp Neurol 1994;53: 637–45
36. Yamaguchi H, Yamazaki T, Lemere CA, Frosch MP, Selkoe DJ. Beta amyloid is focally deposited within the outer basement membrane in the amyloid angiopathy of Alzheimer's disease. Am J Pathol 1992;141:249–59
37. Shoji M, Hirai S, Harigaya Y, Kawarabayashi T, Yamaguchi H. The amyloid β-protein precursor is localized in smooth muscle cells of leptomeningeal vessels. Brain Res 1990;530:113–16
38. Davis-Salinas J, Saporito-Irwin SM, Cotman CW, Van Nostrand WE. Amyloid β-protein induces its own production in cultured degenerating cerebrovascular smooth muscle cells. J Neurochem 1995;65:931–34
39. Fukuchi K, Ho L, Younkin SG, et al. High levels of circulating β-amyloid peptide do not cause cerebral β-amyloidosis in transgenic mice. Am J Pathol 1997;149:219–27
40. Verbeek MM, Otte-Höller I, Wesseling P, Ruiter DJ, de Waal RMW. Induction of β-smooth muscle actin expression in cultured human brain pericytes by TGF 1. Am J Pathol 1994;144:372–82
41. Verbeek MM, de Waal RMW, Schipper JJ, Van Nostrand WE. Rapid degeneration of cultured human brain pericytes by amyloid β protein. J Neurochem 1997;68:1135–41
42. Graeber MB, Streit WJ, Büringer D, Sparks L, Kreutzberg GW. Ultrastructural location of major histocompatibility complex (MHC) class II positive perivascular cells in histologically normal human brain. J Neuropathol Exp Neurol 1992;51:303–11
43. Wisniewski HM, Wegiel J, Wang KC, Lach B. Ultrastructural studies of the cells forming amyloid in the cortical vessel wall in Alzheimer's disease. Acta Neuropathol 1992;84:117–27
44. Maat-Schieman MLC, Rozemuller AJ, van Duinen SG, Haan J, Eikelenboom P, Roos RAC. Microglia in diffuse plaques in hereditary cerebral hemorrhage with amyloidosis (Dutch). An immunohistochemical study. J Neuropathol Exp Neurol 1994;53:483–91
45. Yamada M, Itoh Y, Shintaki M, et al. Immune reactions associated with cerebral amyloid angiopathy. Stroke 1996;27:1155–62
46. Yankner BA, Duffy LK, Kirschner DA. Neurotrophic and neurotoxic effects of amyloid protein: Reversal by tachykinin neuropeptides. Science 1990;250:279–82
47. Kowall NW, Beal MF, Busciglio J, Duffy LK, Yankner BA. An in vivo model for the neurodegenerative effects of β amyloid and protection by substance P. Proc Natl Acad Sci USA 1991;88:7247–51
48. Lorenzo A, Yankner BA. β-Amyloid neurotoxicity requires fibril formation and is inhibited by Congo red. Proc Natl Acad Sci USA 1994;91:12243–47
49. Pike CJ, Burdick D, Walencewicz AJ, Glabe CG, Cotman CW. Neurodegeneration induced by β-amyloid peptides in vitro: The role of peptide assembly state. J Neurosci 1993;13:1676–87
50. McGeer PL, Kawamata T, Walker DG. Distribution of clusterin in Alzheimer brain tissue. Brain Res 1992;579:337–41
51. Meda L, Cassatella MA, Szendrei GI, et al. Activation of microglial cells by β-amyloid protein and interferon-γ. Nature 1995;374:647–50
52. Canning DR, McKeon RJ, DeWitt DA, et al. β-Amyloid of Alzheimer's disease induces reactive gliosis that inhibits axonal outgrowth. Exp Neurol 1993;124:289–98
53. Kimura T, Hashimura T, Miyakawa T. Observations of microvessels in the brain with Alzheimer's disease by the scanning electron microscope. Jpn J Psychiatr Neurol 1991;45:671–76
54. Kawai M, Kalaria RN, Cras P, et al. Degeneration of vascular muscle cells in cerebral amyloid angiopathy of Alzheimer disease. Brain Res 1993;623:142–46
55. Davis-Salinas J, Van Nostrand WE. Amyloid beta-protein aggregation nullifies its pathologic properties in cultured cerebrovascular smooth muscle cells. J Biol Chem 1995;270:20887–90
56. Davis J, Van Nostrand WE. Enhanced pathologic properties of Dutch-type mutant amyloid β-protein. Proc Natl Acad Sci USA 1996;93:2996–3000
57. Snow AD, Mar H, Nochlin D, et al. Early accumulation of heparan sulfate in neurons and in the beta-amyloid protein-containing lesions of Alzheimer's disease and Down's syndrome. Am J Pathol 1990;137:1253–70
58. Namba Y, Tomonaga M, Kawasaki H, Otomo E, Ikeda K. Apolipoprotein E immunoreactivity in cerebral amyloid deposits and neurofibrillary tangles in Alzheimer's disease and kuru plaque amyloid in Creutzfeld-Jakob disease. Brain Res 1991;541:163–66
59. Eikelenboom P, Stam FC. Immunoglobulins and complement factors in senile plaques. An immunohistochemical study. Acta Neuropathol 1982;57:239–42
60. Abraham CR, Selkoe DJ, Potter H. Immunochemical identification of the serine protease inhibitor alpha-1-antichymotrypsin in the brain amyloid deposits of Alzheimer's disease. Cell 1988;52:487–501
61. Rozemuller JM, Abbink JJ, Kamp AM, Stam FC, Hack CE, Eikelenboom P. Distribution pattern and functional state of 1-antichymotrypsin in plaques and vascular amyloid in Alzheimer's disease. Acta Neuropathol 1991;82:200–207
62. Zhan S-S, Veerhuis R, Kamphorst W, Eikelenboom P. Distribution of beta amyloid associated proteins in plaques in Alzheimer's disease and in the non-demented elderly. Neurodegeneration 1995;4: 291–97
63. Kalaria RN, Perry G. Amyloid P component and other acute-phase proteins associated with cerebellar Aβ-deposits in Alzheimer's disease. Brain Res 1993;631:151–55
64. Duong T, Pommier EC, Schiebel AB. Immunodetection of the amyloid P component in Alzheimer's disease. Acta Neuropathol 1989;78:429–37
65. Verbeek MM, Otte-Höller I, Westphal JR, Wesseling P, Ruiter DJ, de Waal RMW. Accumulation of intercellular adhesion molecule-1 in senile plaques in brain tissue of patients with Alzheimer's disease. Am J Pathol 1994;144:104–16
66. Rozemuller JM, Bots GTAM, Roos RAC, Eikelenboom P. Acute phase proteins but not activated microglial cells are present in parenchymal β/A4 deposits in the brains of patients with hereditary cerebral hemorrhage with amyloidosis-Dutch type. Neurosci Lett 1992;140:137–40
67. van Duinen SG, Maat-Schieman MLC, Bruijn JA, Haan J, Roos RAC. Cortical tissue of patients with hereditary cerebral hemorrhage with amyloidosis (Dutch) contains various extracellular matrix deposits. Lab Invest 1995;73:183–89
68. Verbeek MM, Otte-Höller I, Wesseling P, Ruiter DJ, de Waal RMW. Differential expression of intercellular adhesion molecule-1 (ICAM-1) in the Aβ-containing lesions in brains of patients with dementia of the Alzheimer type. Acta Neuropathol 1996;91:608–15

69. Snow AD, Sekiguchi RT, Nochlin D, Kalaria RN, Kimata K. Heparan sulfate proteoglycan in diffuse plaques of hippocampus but not of cerebellum in Alzheimer's disease brain. Am J Pathol 1994;144:337–47
70. Rozemuller JM, Stam FC, Eikelenboom P. Acute phase proteins are present in amorphous plaques in the cerebral but not in the cerebellar cortex of patients with Alzheimer's disease. Neurosci Lett 1990;119:75–78
71. Strittmatter WJ, Saunders AM, Schmechel D, et al. Apolipoprotein E: High-avidity binding to β-amyloid and increased frequency of type 4 allele in late-onset familial Alzheimer disease. Proc Natl Acad Sci USA 1993;90:1977–81
72. Ghiso J, Matsubara E, Koudinov A, et al. The cerebrospinal-fluid soluble form of Alzheimer's amyloid beta is complexed to SP40,40 (apolipoprotein J), an inhibitor of the compement membrane attack complex. Biochem J 1993;293:27–30
73. Webster S, O'Barr S, Rogers J. Enhanced aggregation and structure of amyloid β peptide after coincubation with C1q. J Neurosci Res 1994;39:448–56
74. Fraser PE, Nguyen JT, McLachlan DR, Abraham CR, Kirschner DA. 1-Antichymotrypsin binding to Alzheimer Aβ peptides is sequence specific and induces fibril disaggregation in vitro. J Neurochem 1993;61:298–305
75. Snow AD, Kinsella MG, Parks E, et al. Differential binding of vascular cell-derived proteoglycans (perlecan, biglycan, decorin, and versican) to the beta-amyloid protein of Alzheimer's disease. Arch Biochem Biophys 1995;320:84–95
76. Ma J, Yee A, Brewer BJ, Das S, Potter H. Amyloid associated proteins 1-antichymotrypsin and apolipoprotein E promote assembly of Alzheimer β-protein into filaments. Nature 1994;372:92–94
77. Snow AD, Sekiguchi R, Nochlin D, et al. An important role of heparan sulfate proteoglycan (Perlecan) in a model system for the deposition and persistence of fibrillar A beta-amyloid in rat brain. Neuron 1994;12:219–34
78. Eikelenboom P, Veerhuis R. The role of complement and activated microglia in the pathogenesis of Alzheimer's disease. Neurobiol Aging 1996;17:673–80
79. Kalaria RN, Kroon SN. Complement inhibitor C4-binding protein in amyloid deposits containing serum amyloid P in Alzheimer's disease. Biochem Biophys Res Commun 1992;186:461–66
80. Schmechel DE, Saunders AM, Strittmatter WJ, et al. Increased amyloid β-peptide deposition in cerebral cortex as a consequence of apolipoprotein E genotype in late-onset Alzheimer disease. Proc Natl Acad Sci USA 1993;90:9649–53
81. Greenberg SM, Rebeck GW, Vonsattel J-P, Gomez-Isla T, Hyman BT. Apolipoprotein E ϵ4 and cerebral hemorrhage associated with amyloid angiopathy. Ann Neurol 1995;38:254–59
82. Premkumar DRD, Cohen DL, Hedera P, Friedland RP, Kalaria RN. Apolipoprotein E-ϵ4 alleles in cerebral amyloid angiopathy and cerebrovascular pathology associated with Alzheimer's disease. Am J Pathol 1996;148:2083–95
83. Narindrasorasak S, Altman RA, Gonzalez-DeWhitt P, Greenberg BD, Kisilevsky R. An interaction between basement membrane and Alzheimer amyloid precursor proteins suggests a role in the pathogenesis of Alzheimer's disease. Lab Invest 1995;72:272–82
84. Perlmutter LS, Barrón E, Saperia D, Chui HC. Association between vascular basement membrane components and the lesions of Alzheimer's disease. J Neurosci Res 1991;30:673–81
85. Greenberg SM, Briggs ME, Hyman BT, et al. Apolipoprotein E ϵ4 is associated with the presence and earlier onset of hemorrhage in cerebral amyloid angiopathy. Stroke 1996;27:1333–37
86. Nicoll JAR, Burnett C, Love S, Graham DI, Ironside JW, Vinters HV. High frequency of apolipoprotein E ϵ2 in patients with cerebral hemorrhage due to cerebral amyloid angiopathy. Ann Neurol 1996;39:682
87. Risau W, Dingler A, Albrecht U, Dehouck MP, Cecchelli R. Blood-brain barrier pericytes are the main source of β-glutamyl transpeptidase activity in brain capillaries. J Neurochem 1992;98:667–72
88. Kalaria RN. The blood-brain barrier and cerebral microcirculation in Alzheimer's disease. Cerebrovasc Brain Metab Rev 1992;4:226–60

Received February 18, 1997
Revision received April 8, 1997
Accepted April 11, 1997