

# Structural and functional imaging of the hippocampus in young people at familial risk of depression

Z. N. Mannie†, N. Filippini†, C. Williams, J. Near, C. E. Mackay and P. J. Cowen\*

University Department of Psychiatry, Warneford Hospital, Oxford OX3 7JX, UK

**Background.** Major depression is associated with abnormalities in the function and structure of the hippocampus. However, it is unclear whether these abnormalities might also be present in people ‘at risk’ of illness.

**Method.** We studied 62 young people (mean age 18.8 years) at familial risk of depression (FH+) but who had never been depressed themselves. Participants underwent magnetic resonance imaging to assess hippocampal structure and neural responses to a task designed to activate hippocampal memory networks. Magnetic resonance spectroscopy was used to measure levels of a combination of glutamine and glutamate (Glx) in the right hippocampus. A total of 59 matched controls with no history of mood disorder in a first-degree relative underwent the same investigations.

**Results.** Hippocampal volume did not differ between FH+ participants and controls; however, relative to controls, during the memory task, FH+ participants showed increased activation in brain regions encompassing the insular cortices, putamen and pallidum as well as the dorsal anterior cingulate cortex (ACC). FH+ participants also had increased hippocampal levels of Glx.

**Conclusions.** Euthymic individuals with a parental history of depression demonstrate increased activation of hippocampal-related neural networks during a memory task, particularly in brain regions involved in processing the salience of stimuli. Changes in the activity of the ACC replicate previous findings in FH+ participants using different psychological tasks; this suggests that task-related abnormalities in the ACC may be a marker of vulnerability to depression. Increased levels of Glx in the hippocampus might also represent a risk biomarker but follow-up studies will be required to test these various possibilities.

Received 9 November 2013; Revised 13 February 2014; Accepted 14 February 2014; First published online 7 April 2014

**Key words:** At-risk individuals, depression, glutamate, hippocampus, magnetic resonance imaging.

## Introduction

Abnormalities in the function and structure of the hippocampus are often described in patients with major depression. For example, declarative memory deficits consistent with hippocampal impairment are a frequent accompaniment of depressive episodes (Zakzanis *et al.* 1998; MacQueen *et al.* 2003) and the hippocampus is known to show morphological changes in response to stress and excess cortisol secretion, both of which are implicated in the pathophysiology of mood disorders (MacQueen & Frodl, 2011; Moylan *et al.* 2013). Consistent with this, meta-analyses have consistently shown small but significant reductions in hippocampal volume in depressed patients (Campbell *et al.* 2004; Kempton *et al.* 2011). How far

these volume reductions are linked to severe and recurrent illness is controversial (Moylan *et al.* 2013).

There is also some evidence that hippocampal volume may be reduced in people at increased familial risk of depression (Baaré *et al.* 2010; Chen *et al.* 2010; Amico *et al.* 2011), though a history of childhood abuse may be an important moderating factor (de Gues *et al.* 2007; Rao *et al.* 2010; Carballedo *et al.* 2012). In a previous study we found that young women with a depressed parent but no personal history of depression showed impaired declarative memory in a verbal memory task (Mannie *et al.* 2009). In the same subjects we obtained evidence of increased activation of the neural substrate of working memory in a functional magnetic resonance imaging (fMRI) study (Mannie *et al.* 2010).

The aim of the present study was to carry out a multimodal imaging study of hippocampal structure and function in a group of young people at increased familial risk of depression through virtue of having a depressed parent (Beardslee *et al.* 1998). On the basis

\* Address for correspondence: P. J. Cowen, M.D., FRCPsych, University of Oxford, Oxford, UK.  
(Email: phil.cowen@psych.ox.ac.uk)

† These authors contributed equally to this work.

of the above studies we predicted that, relative to controls, participants at increased familial risk of depression would have lower hippocampal volumes and altered functional responses in hippocampal memory networks in an encoding task. It has also been suggested that loss of hippocampal volume in depression might be associated with increased glutamate activity (MacQueen & Frodl, 2011) and in a previous study we found that young people at increased familial risk of depression showed increased cortical levels of glutamate relative to controls (Taylor *et al.* 2011). In the present study, therefore, we also used magnetic resonance spectroscopy (MRS) to obtain a composite measure of glutamate and its precursor glutamine (Glx) in the right hippocampus.

## Method

### Participants

We recruited 62 young people (39 women, 23 men) with a mean age of 18.8 (s.d.=1.0) years (range 16–20 years) who had never personally suffered from depression but who had a biological parent with a history of major depression (FH+). Potential participants were assessed with the Structured Clinical Interview for DSM-IV Axis I Disorders Schedule (SCID-I; First, *et al.* 1997) to exclude a personal current or previous history of major depression. The presence of major depression in a parent was assessed by the family history method using the participant as an informant (Andreassen *et al.* 1986). A history of bipolar disorder in a parent was an exclusion criterion. The criteria used included description of the symptoms of major depression together with the prescription of specific antidepressant treatment, either psychotherapy or medication. This was followed up by direct verification from the affected parent (by telephone or email), and where parental history could not be verified, participants were excluded. The verification was carried out by a psychiatric research nurse who asked the relevant parent specific questions taken from the SCID-I about diagnosis, number of depressive episodes, impact of episodes on functioning, form of treatment (out-patient or in-patient, antidepressants, psychotherapy or counselling) as well as the nature of the professional who had made the diagnosis (psychiatrist or general practitioner). We also recruited 59 controls (35 women and 25 men) with a mean age of 19.1 (s.d.=0.8) years (range 16–20 years) who were determined by the same instruments to have no current or past history of major depression and no history of depression in a biological parent or other first-degree relative.

Current mood and anxiety symptoms were assessed with the self-rated Hospital Anxiety and Depression

Scale (Zigmond & Snaith, 1983) while the Perceived Stress Scale (Cohen *et al.* 1983) was used to provide a measure of subjective stress over the past month. Adverse life events and the impact of these events on emotional well-being were assessed with the Life Events Rating Scale which assesses adverse events at two time points; first, at a distant time point that includes childhood adversity and second, events experienced in the past year (Goodyer *et al.* 1997). We assessed the quality of perceived parenting style for the first 16 years of life with the Parental Bonding Instrument (PBI), obtaining both maternal and paternal PBI scores (Parker, 1979). All participants were right-handed as assessed with the Edinburgh Handedness Inventory (Oldfield, 1971). All subjects gave full informed consent to the study, which was approved by the local ethics committee.

### Structural MRI

Scanning was performed at the University of Oxford, Centre for Clinical Magnetic Resonance Research using a 3 Tesla Siemens Trio scanner with a 12-channel head-coil (Siemens, Germany). The neuroimaging protocol comprised structural and functional MRI sequences and MRS.

Three-dimensional high-resolution T1-weighted MR images were acquired using a MPRAGE (magnetization-prepared rapid acquisition gradient echo) sequence [repetition time (TR)=2040 ms, echo time (TE)=4.7 ms, flip angle=8°, field of view=192 mm, voxel dimension=1 mm isotropic, acquisition time=6 min]. Data analysis was carried out using FSL tools (FMRIB Software Library, [www.fmrib.ox.ac.uk/fsl](http://www.fmrib.ox.ac.uk/fsl)) (Smith *et al.* 2004). Whole-brain analysis was carried out using a voxel-based morphometry (VBM)-style analysis (FSL-VBM) (Douaud *et al.* 2007), using default settings (as described at [www.fmrib.ox.ac.uk/fsl/fslvbm/](http://www.fmrib.ox.ac.uk/fsl/fslvbm/)). In brief, brain extraction and tissue-type segmentation were performed and resulting grey matter (GM) partial volume images were aligned to standard space using first linear (FLIRT) and then nonlinear (FNIRT) registration tools. The resulting images were averaged, modulated and smoothed with an isotropic Gaussian kernel of 4 mm to create a study-specific template. Finally, a voxel-wise general linear model (GLM) was applied using a permutation non-parametric testing (5000 permutations), cluster determined by  $Z > 2.5$  and a family-wise error (FWE)-corrected cluster significance threshold of  $p < 0.001$  was applied to the superthreshold clusters.

Automatic segmentation of the hippocampus was performed with FSL FIRST (Patenaude *et al.* 2011) using the default settings (as described at <http://fsl.fmrib.ox.ac.uk/fsl/fslwiki/FIRST/UserGuide>). Initially,

segmentation was performed with the two-stage affine transformation to Montreal Neurological Institute (MNI) 152 standard space at 1 mm resolution followed by boundary correction to classify the boundary voxels as belonging to the hippocampus. To obtain intracranial volume (ICV), FSL-FAST was used to estimate GM, white matter (WM) and cerebrospinal fluid (CSF) while correcting for spatial intensity variations. ICV was calculated by adding the GM, WM and CSF volumes, and used to normalize for hippocampal volumes.

### Functional MRI

Encoding memory was assessed using a single gradient echo EPI sequence covering the whole brain (TR=3000 ms, TE=28 ms, flip angle=89°, field of view=192 mm, voxel dimension=3 mm isotropic, acquisition time=9 min 6 s). The experimental task was carried out using Presentation software as described in detail elsewhere (Filippini *et al.* 2009). Briefly, a 'novel *versus* familiar' memory-encoding paradigm was used. A set of coloured images (representing animals and landscapes, similar in complexity, brightness and contrast, emotionally neutral and with no persons represented), presented in a 'blocked design' fashion, was shown inside the scanner. Six blocks of 'familiar' (eight images previously learnt outside the scanner, each time presented in a pseudorandom order) and six blocks of 'novel' images (eight new images presented in each block) were presented in an alternated order (image presentation=3250 ms, inter-stimulus interval=500 ms, block duration=30 000 ms). Between each block of images were 15 000 ms of 'rest', during which subjects passively viewed a fixation cross (a total of 12 'rest' blocks). Subjects were instructed to select from a two-button response according to whether the images contained animals. Responses were monitored by the scanner operators to ensure compliance and accuracy and were registered by the software in a text file. Participants were also instructed to try to remember the images for a subsequent memory task. Outside the scanner, approximately 50 min after encoding, 83 images were presented on a computer screen for 4000 ms each (inter-stimulus interval=1000 ms). The 48 'novel' images, the eight 'familiar' images and 27 'distractors' (images never seen before, 13 animals and 14 landscapes) were displayed in pseudorandom order. Subjects had to select between two buttons according to whether the images had been seen inside the scanner or not.

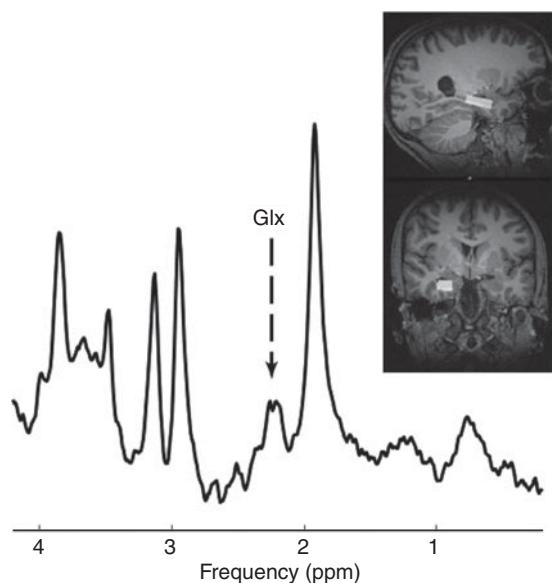
Analysis of fMRI data was carried out using FEAT (fMRI Expert Analysis Tool version 5.98; <http://www.fmrib.ox.ac.uk/fsl/feat5/>) (Woolrich *et al.* 2004). Pre-processing consisted of head motion correction,

brain extraction, spatial smoothing using a Gaussian kernel of full width at half maximum (FWHM) 5 mm, and high-pass temporal filtering equivalent to 130 s. Time-series statistical analysis was carried out with local autocorrelation correction. A boxcar convolved with a  $\gamma$  haemodynamic response function and its temporal derivative was used to model the data. The main contrast of interest for the novelty detection paradigm was 'novel *versus* familiar'. fMRI volumes were registered to the individual's structural scan and standard space images using a nonlinear registration tool (FNIRT). These transformations into standard space were applied to images of contrasts of interest and their variances. Higher-level (group-level) analysis was carried out using FMRI's Local Analysis of Mixed Effect (FLAME) (Woolrich *et al.* 2004). The GLM included the two groups. We tested for group averages and differences between groups for each of the contrasts of interest.  $Z$  (Gaussianized  $T/F$ ) statistic images were thresholded using clusters determined by  $Z > 2.3$  and a FWE threshold of  $p < 0.05$  was applied to the superthreshold clusters. To reduce effects attributable to outliers, an automatic outlier deweighting tool was also applied (Woolrich, 2008). To ensure that any group differences in fMRI data were not attributable to underlying structural differences, GM images of each subject were registered to standard space, smoothed to match the fMRI data, demeaned within each group and added to the model as voxel-wise covariates of no interest.

### MRS

The structural MRI was used to guide placement of an MRS voxel measuring  $30 \times 15 \times 10 \text{ mm}^3$  in the right hippocampus (Fig. 1). The voxel was positioned to avoid overlap with the pons, peduncle or other mid-brain structures that are associated with increased motion. All signal averages were stored individually, which enabled us to reject averages that were corrupted by motion, as well as to correct any frequency and phase drift errors (see Near *et al.* 2014). Single voxel-localized, short echo-time MRS data were acquired from the region of interest using the Point RESolved Spectroscopy (PRESS) sequence with the following sequence parameters: TR=3000 ms, TE=30 ms, flip angle=90°, spectral width=1200 Hz, 1024 points, 128 averages, acquisition time=6.4 min (Bottomley, 1987). Semi-automated processing of spectra was performed in MATLAB (MathWorks, USA) to remove motion-corrupted averages and frequency drift prior to data analysis in LCModel (<http://s-provencher.com/pages/lcmodel.shtml>).

Processed MRS data were analysed using LCModel (Provencher, 1993) and all metabolite concentrations



**Fig. 1.** Sample Point RESolved Spectroscopy (PRESS) spectrum and voxel position in the right hippocampus. Glx, Glutamate/glutamine; ppm, parts per million.

were calculated with reference to total creatine (creatinine+phosphocreatine). Glutamate concentrations were assessed using the composite measure of glutamate+glutamine (Glx). Only Glx values with a Cramér–Rao lower bound uncertainty less than 30% were included in the statistical analyses.

### Statistics

Statistical analyses were carried out using SPSS software (IBM, USA) and *t* tests were used for sociodemographic variables, brain structure volumes, memory performance and reaction times. Exact Fisher's test was used for categorical variables.

## Results

### Participants

The two groups did not significantly differ in age, gender, smoking, state and trait anxiety, perceived stress, anxiety or depression (Table 1). There was also no difference in recent or remote life events or in measures of parental bonding. Similarly, no group-related differences were observed for memory recognition performance or reaction times, both of which were recorded after fMRI task-related acquisition (all *p* values >0.5) (Supplementary Table S1).

### Brain morphology and hippocampal volume

No group differences were observed in whole-brain volume or in segmented GM and WM (Table 2). Similarly, VBM revealed no differences between the

two study groups in GM volume. Normalized hippocampal volumes (i.e. relative to ICV) were computed as the total volume of hippocampal GM ( $\text{mm}^3$ )/ICV ( $\text{mm}^3$ ) $\times$ 1000. We were able to analyse structural data only from 54 FH+ and 52 control participants due to poor image registration in the remaining participants. There was no difference in hippocampal volume (absolute and normalized) between FH+ and controls as established with FSL FIRST (Table 3).

### fMRI

The encoding memory fMRI task successfully activated task-related areas associated with the encoding process by contrasting novel with familiar visual scenes. Group blood oxygen level-dependent (BOLD) fMRI signal intensity changes were observed in the hippocampus, temporal fusiform cortex, and parahippocampal gyrus bilaterally, and in association areas in the frontal, parietal and occipital lobes (See Fig. 2*a*), as previously described (Fleisher *et al.* 2005; Golby *et al.* 2005; Filippini *et al.* 2009).

Fig. 2*b* shows group differences in the novel *versus* familiar contrast. In general, an increased BOLD signal in FH+ participants relative to controls was found in a cluster of regions encompassing the insular cortices: the putamen and pallidum bilaterally (maximum *Z* score 4.15; cluster size 2082 voxels; peak coordinates in standard space 24, 18, -6; and maximum *Z* score -3.78; cluster size 835 voxels; peak coordinates in standard space -28, -14, -6, respectively) and in the dorsal portion of the anterior cingulate cortex (maximum *Z* score 3.45; cluster size 325 voxels; peak coordinates in standard space 16, 20, 30). The addition of GM as a voxel-wise covariate of no interest did not affect BOLD-related group differences, suggesting that any subthreshold differences in brain structure did not influence the fMRI result.

### MRS imaging

Valid scans were available from 57 FH+ participants and 57 controls. There were no group differences in hippocampal voxel contents (GM, WM and CSF, all *p*>0.20) and spectral quality (FWHM, *p*>0.30). The Glx:creatinine ratio in the hippocampus was significantly higher in FH+ subjects (Fig. 3). There was no change in the concentration of any other neuro-metabolites comparing FH+ with controls.

## Discussion

We found that young people at familial risk of depression exhibited overactivity of neural networks involved in memory encoding and higher levels of a composite measure (Glx) of glutamate and glutamine

**Table 1.** Sociodemographic and neuropsychological features of FH+ participants and controls

	FH+ (n=62)	Control (n=59)	p
<b>Sociodemographics</b>			
Age, years	18.8 (1.0)	19.0 (0.8)	0.15
Gender, n			0.69
Male	23	24	
Female	39	35	
Smoker, n			0.72
Yes	11	12	
No	51	47	
<b>Neuropsychological characteristics</b>			
HADS-D	1.6 (2.2)	1.5 (1.5)	0.62
HADS-A	4.4 (3.3)	4.0 (2.7)	0.54
PSS	13.2 (5.6)	13.7 (5.9)	0.64
LERS-recent	0.9 (1.2)	0.7 (1.0)	0.37
LERS-lifetime	0.5 (0.6)	0.4 (0.6)	0.23
MPBI-care	30.5 (6.2)	30.1 (6.3)	0.75
MPBI-overprotection	9.7 (6.5)	10.6 (6.9)	0.46
PPBI-care	27.0 (6.8)	26.4 (7.1)	0.61
PPBI-overprotection	8.1 (5.7)	7.7 (5.9)	0.68

Data are given as mean (standard deviation) or as number of participants.

FH+, Familial risk of depression; HADS-D, Hospital Anxiety and Depression Scale – Depression; HADS-A, Hospital Anxiety and Depression Scale – Anxiety; PSS, Perceived Stress Scale; LERS-recent, Life Events Rating Scale – past year; LERS-lifetime, Life Events Rating Scale – lifetime; MPBI-care, Parental Bonding Instrument – Maternal Care; MPBI-overprotection, Parental Bonding Instrument – Maternal Overprotection; PPBI-care, Parental Bonding Instrument – Paternal Care; PPBI-overprotection, Parental Bonding Instrument – Paternal Overprotection.

**Table 2.** Brain volume measures in FH+ participants and controls

	FH+ (n=62)	Control (n=59)	p
<b>Brain measures, mm<sup>3</sup></b>			
Total intracranial volume	1522.1 (122.5)	1511.2 (105.6)	0.60
Grey matter	637.7 (50.5)	628.9 (40.6)	0.29
White matter	551.7 (49.4)	548.6 (44.5)	0.72

Data are given as mean (standard deviation).

FH+, Familial risk of depression.

in the right hippocampus. However, there was no evidence of structural deficits in the hippocampus and more generally no change in brain morphology between the two participant groups.

As previously described, the fMRI task of memory encoding that we employed produced activation of the hippocampus and parahippocampal regions (Filippini *et al.* 2009). This task has been used successfully to identify overactivity of the hippocampus in carriers of APOE  $\epsilon$ 4 risk alleles, consistent with the increased risk of such individuals in later life for

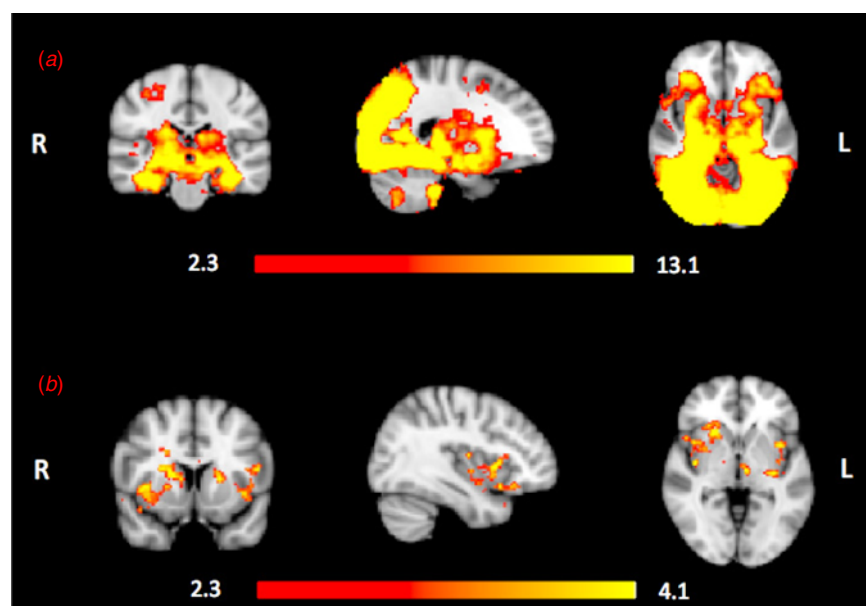
**Table 3.** Hippocampal volumes (absolute and normalized) in FH+ participants and controls

Hippocampal volume, mm <sup>3</sup>	FH+ (n=54)	Control (n=52)	p
<b>Absolute</b>			
Left	4082.06 (475.27)	4027.58 (470.16)	0.55
Right	4143.48 (449.84)	4115.08 (461.52)	0.75
<b>Normalized</b>			
Left	2.68 (0.32)	2.67 (0.31)	0.48
Right	2.73 (0.33)	2.73 (0.29)	0.90

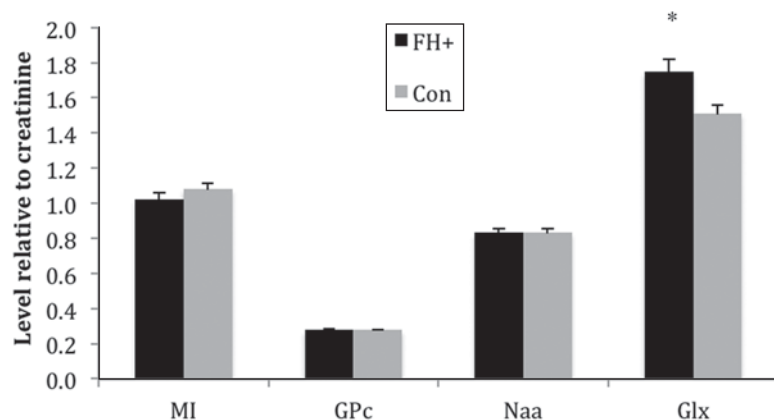
Data are given as mean (standard deviation).

FH+, Familial risk of depression.

hippocampal-based learning deficits (Filippini *et al.* 2009). However, contrary to our hypothesis, we found no evidence of abnormal hippocampal activity in young people at risk of depression during encoding. Studies of hippocampal activity during encoding tasks in depressed patients have tended to report lower hippocampal recruitment (Bremner *et al.* 2004; Milne *et al.*



**Fig. 2.** Functional magnetic resonance imaging results for the 'novel *versus* familiar' contrast in the encoding task. (a) Mean activation for the novel *versus* familiar contrast for all 121 subjects: young people at familial risk of depression (FH+) and controls. Activation was found bilaterally in the primary and secondary visual cortices as well as regions involved in memory processes: the hippocampus, temporal fusiform cortex and parahippocampal gyrus. R, Right hemisphere; L, left hemisphere. Red-to-yellow colours define increases in brain activation. (b) Regions of significantly increased blood oxygen level-dependent (BOLD) signal intensity for FH+ participants relative to controls. Activation in a cluster of brain regions encompassing the insular and putamen regions bilaterally and the posterior portion of the anterior cingulate cortex was greater in the FH+ participants relative to controls ( $p < 0.05$ , corrected for multiple comparisons).



**Fig. 3.** Myoinositol (MI), glycerophosphocholine (GPc), *N*-acetylaspartate (Naa) and glutamate/glutamine (Glx) by group: young people at familial risk of depression (FH+) *versus* controls (Con). Values are means, with standard deviations represented by vertical bars. \* Mean value was significantly different from that of the control group ( $p = 0.01$ ).

2012; Kelly *et al.* 2013), though this is not always the case (Werner *et al.* 2009) and more subtle changes such as a dysregulation of the normal relationship between hippocampal activation and encoding success have also been observed (Fairhall *et al.* 2010). Fairhall *et al.* (2010) point out that numerous methodological factors might influence hippocampal activation in fMRI studies in depressed patients, for example,

stage of disease, the use of psychotropic medication and whether the fMRI analysis is restricted to successful encoding. It is also likely that the emotional valence of the presented material can influence the extent of hippocampal activation, with depressed patients showing relatively less hippocampal response to the encoding of positive word pairs while the reverse is the case with negative words (Toki *et al.* 2014).

We did find overactivity of other brain regions that have been linked to episodic memory such as the putamen, pallidum insula and anterior cingulate cortex (Rottschy *et al.* 2012), suggesting that FH+ participants may need to recruit a wider neural network to maintain task performance during encoding. Interestingly, Yassa & Stark (2008) observed, in healthy participants, a repetition-related decrease in the activation of putamen, insula and cingulate cortex over the time course of a novel episodic memory task. It is possible that FH+ participants do not show adaptation in this way, that is that novel information continues to remain 'salient'. We also found altered neural responses in the anterior cingulate cortex in FH+ participants undertaking an emotional Stroop task and during the experience of reward and punishment (Mannie *et al.* 2008; McCabe *et al.* 2012). This suggests that abnormal activity in the anterior cingulate may characterize neural responses to a variety of cognitive and emotional tasks in FH+ subjects.

To the best of our knowledge, the kind of overactivity that we saw in FH+ participants in brain regions linked to episodic memory has not been reported in patients with established depression or bipolar disorder (see, for example, Fairhall *et al.* 2010; Oertel-Knöchel *et al.* 2013). However, people at familial risk of depression do overactivate subcortical, affect-linked, areas in a task requiring the shifting of attention from negative stimuli. This has been attributed to a compensatory 'protective' strategy in at-risk individuals (Lisiecka *et al.* 2013), and it is possible that a similar effect could underlie the changes seen in our study.

Decrements of hippocampal volume are found fairly reliably in large samples of depressed patients (Campbell *et al.* 2004; Kempton *et al.* 2011), and there is evidence that this abnormality may extend to people at familial risk of depression. For example, using voxel-based morphometry, Chen *et al.* (2010) found smaller hippocampi bilaterally in 23 daughters (aged 9–15 years) of mothers with recurrent depression compared with age-matched controls. Baaré *et al.* (2010) reported smaller hippocampal volumes in 59 high-risk twins where a co-twin suffered from major depression and Amico *et al.* (2011) also found smaller right hippocampi in 30 participants with a first-degree relative with depression. Smaller hippocampal volumes were also found in three other familial risk studies; however, in the latter investigations, the effects of familial vulnerability on the hippocampus were partly dependent on an interaction with early life adversity (de Gussé *et al.* 2007; Rao *et al.* 2010; Carballedo *et al.* 2012). In our study we found relatively low levels of childhood adversity that did not apparently distinguish our two participant groups, at least as measured by adverse

life events and assessments of parental relationships. Our data therefore suggest that familial risk of depression may not by itself be associated with lowered hippocampal volume and that other factors such as childhood maltreatment may be involved in the low hippocampal phenotype.

We employed voxel-based morphometry as well as automatic segmentation of the hippocampus and we therefore think it unlikely that methodological factors can explain the differences between our findings in FH+ participants and the other studies cited here. Moreover, because we added GM maps as a covariate of no interest to the fMRI analyses, we have accounted for potential subthreshold differences that could have influenced our fMRI results. However, it is possible that more detailed structural analyses could have revealed differences in hippocampal subregions not captured by more conventional approaches (Cole *et al.* 2010).

Whether or not patients in a first episode of depression exhibit abnormalities in hippocampal structure has been disputed, but a recent meta-analysis of seven studies found a significant bilateral reduction in hippocampal volume in such participants (Cole *et al.* 2011). If our finding in FH+ participants is correct, one interpretation is that in some 'at-risk' individuals hippocampal volume reduction becomes manifest at first presentation of clinical illness, perhaps as a result of an ongoing neurotoxic process (see below).

We did find increased levels of Glx in the hippocampus in FH+ participants. This is in partial agreement with a previous study in young FH+ subjects where, using a PRESS-J editing technique, we found increased glutamate but not Glx in the occipital cortex (Taylor *et al.* 2011). The PRESS sequence used in the present study does not allow separation of glutamate from glutamine and so the data are presented as Glx. Generally, in acutely depressed patients, Glx levels measured by proton MRS are lowered in anterior brain regions (Yüksel & Ongur, 2010), though the hippocampus has been relatively little investigated, with one study reporting lowered Glx levels in depression while another found no change (Block *et al.* 2008; Milne *et al.* 2009). The hippocampus is a difficult area to image in MRS and it is possible that our voxel involved a contribution from the amygdala as well as the hippocampus. Because of time constraints, our MRS study was restricted to the right hippocampus so it is not clear whether similar changes in Glx might occur bilaterally. In view of our previous finding of raised glutamate in the occipital cortex in FH+ participants (Taylor *et al.* 2011) it will also be important in future studies to examine additional brain regions to determine whether any increases in glutamate and/or Glx are a generalized phenomenon of the at-risk state.

An MRS study in depressed patients at different illness stages reported that Glx levels in the hippocampus were similar to controls in first episodes of depression but then declined over the course of recurrent illness (de Diego-Adelino *et al.* 2013). This raises the possibility that a state of vulnerability to depression might be marked by relatively higher glutamate levels compared with normal, and that these elevated levels then decline with the onset of depression, decreasing further during the course of chronic illness. This is consistent with proposals that increased glutamate levels act as a precursor of neurotoxicity in the hippocampus in depression through a biochemical cascade that inhibits synaptic plasticity and neuronal survival (see MacQueen & Frodl, 2011). Thus, initial high levels of glutamate in the high-risk subject might decline over time with a corresponding loss of hippocampal neurones. Clearly, however, this notion is speculative and needs empirical support from longitudinal studies of high-risk patients.

### Conclusions

In conclusion, we found no deficits in hippocampal structure in young people at increased familial risk of depression. However we did find evidence of abnormally increased neural activity in hippocampal-dependent memory networks during an encoding task as well as increased levels of a composite measure of glutamate and glutamine in the hippocampus. In this respect our data add to other studies suggesting abnormal activity of the anterior cingulate cortex in young FH+ subjects (Mannie *et al.* 2008; McCabe *et al.* 2012). Further longitudinal studies are needed both to confirm these changes and identify their possible value in predicting illness onset and progression.

### Supplementary material

For supplementary material accompanying this paper visit <http://dx.doi.org/10.1017/S0033291714000580>.

### Acknowledgements

The study was sponsored by the UK Medical Research Council (grant no. G0900576). N.F. is funded by the HDH Wills 1965 Charitable Trust. C.E.M. received support from the National Institute for Health Research (NIHR) Oxford Biomedical Research Centre. The authors assert that all procedures contributing to this work comply with the ethical standards of the relevant national and institutional committees on human experimentation and with the Helsinki Declaration of 1975, as revised in 2008.

### Declaration of Interest

P.J.C. is a member of a paid advisory board for Lundbeck.

### References

- Amico F, Meisenzahl E, Koutsouleris N, Resier M, Moller HJ, Frodl T (2011). Structural MRI correlates for vulnerability and resilience to major depressive disorder. *Journal of Psychiatry and Neuroscience* **36**, 15–22.
- Andreasen NC, Rice J, Endicott J, Reich T, Coryell W (1986). The family history approach to diagnosis. How useful is it? *Archives of General Psychiatry* **43**, 421–429.
- Baaré WFC, Vinberg M, Knudsen GM, Paulson OB, Langkilde AR, Jernigan TL, Kessing LV (2010). Hippocampal volume changes in healthy subjects at risk of unipolar depression. *Journal of Psychiatric Research* **44**, 655–662.
- Beardslee WR, Versage EM, Gladstone TR (1998). Children of affectively ill parents: a review of the past 10 years. *American Journal of Child Adolescent Psychiatry* **37**, 1134–1141.
- Block W, Träber F, von Widdern M, Metten H, Schild W, Maier W, Zobel A, Jessen F (2008). Proton MR spectroscopy of the hippocampus at 3 T in patients with unipolar major depressive disorder: correlates and predictors of treatment response. *International Journal of Neuropsychopharmacology* **12**, 415–422.
- Bottomley PA (1987). Spatial localization in NMR spectroscopy *in vivo*. *Annals of the New York Academy of Sciences* **508**, 333–348.
- Bremner JD, Vythilingam M, Vermetten E, Vaccarino V, Charney DS (2004). Deficits in hippocampal and anterior cingulate functioning during verbal declarative memory encoding in midlife major depression. *American Journal of Psychiatry* **161**, 637–645.
- Campbell S, Marriott M, Nahmias C, MacQueen GM (2004). Lower hippocampal volume in patients suffering from depression: a meta-analysis. *American Journal of Psychiatry* **161**, 598–607.
- Carballedo A, Lisiecka D, Fagan A, Saleh K, Ferguson Y, Connolly G, Meaney J, Frodl T (2012). Early life adversity is associated with brain changes in subjects at family risk for depression. *World Journal of Biological Psychiatry* **13**, 569–578.
- Chen MC, Hamilton JP, Gotlib IH (2010). Decreased hippocampal volume in healthy girls at risk of depression. *Archives of General Psychiatry* **67**, 270–276.
- Cohen S, Kamarck T, Mermelstein R (1983). A global measure of perceived stress. *Journal of Health and Social Behaviour* **24**, 386–396.
- Cole J, Costafreda SG, McGuffin P, Fu CHY (2011). Hippocampal atrophy in first episode depression: a meta-analysis of magnetic resonance imaging studies. *Journal of Affective Disorders* **134**, 483–487.
- Cole J, Toga AW, Hojatkashani C, Thompson P, Costafreda SG, Clear AJ, Williams SCR, Bullmore ET, Scott JL, Mitterschiffthaler MT, Walsh ND, Donaldson C,



- Mirza M, Marquand A, Nosarti C, McGuffin P, Fu CHY (2010). Subregional hippocampal deformations in major depressive disorder. *Journal of Affective Disorders* **126**, 272–277.
- de Geus EJC, van't Ent D, Wolfenberger SPA, Heutink P, Hoogendijk WJG, Boomsa DI, Veltman DJ (2007). Intrapair differences in hippocampal volume in monozygotic twins discordant for the risk for anxiety and depression. *Biological Psychiatry* **61**, 1062–1071.
- di Diego-Adelino J, Portella MJ, Gomez-Anson B, Lopez-Moruolo O, Serra BM, Vives Y, Puigdemont D, Perez-Egea R, Alvarez E, Perez V (2013). Hippocampal abnormalities of glutamate/glutamine, N-acetylaspartate and choline in patients with depression are related to past illness and burden. *Journal of Psychiatry and Neuroscience* **38**, 107–116.
- Douaud G, Smith S, Jenkinson M, Behrens T, Johansen-Berg H, Vickers J, James S, Voets N, Watkins K, Matthews PM, James A (2007). Anatomically related grey and white matter abnormalities in adolescent-onset schizophrenia. *Brain* **130**, 2375–2386.
- Fairhall SL, Sharma S, Magnusson J, Murphy B (2010). Memory related dysregulation of hippocampal function in major depressive disorder. *Biological Psychiatry* **85**, 499–503.
- Filippini N, Bradley J, MacIntosh B J, Hough MG, Goodwin GM, Frisoni GB, Smith SM, Matthews PM, Beckmann CF, Mackay CE (2009). Distinct patterns of brain activity in young carriers of the APOE-ε4 allele. *Proceedings of the National Academy of Sciences* **106**, 7209–7214.
- First MB, Spitzer RL, Gibbon M, Williams JB (1997). *Structured Clinical Interview for DSM-IV Axis I Disorders: Clinical Version*. American Psychiatric Association: Washington, DC.
- Fleisher AS, Houston WS, Eyler LT, Frye S, Jenkins C, Thal LJ, Bondi MW (2005). Identification of Alzheimer disease risk by functional magnetic resonance imaging. *Archives of Neurology* **62**, 1881–1888.
- Golby A, Silverberg G, Race E, Gabrieli S, O'Shea J, Knierim K, Stebbins G, Gabrieli J (2005). Memory encoding in Alzheimer's disease: an fMRI study of explicit and implicit memory. *Brain* **128**, 773–778.
- Goodyer IM, Herbert J, Tamplin A, Secher SM, Pearson J (1997). Outcome of major depression, II: life events, family dysfunction and friendship difficulties as predictors of persistent disorder. *Journal of the American Academy of Child and Adolescent Psychiatry* **36**, 474–480.
- Kelly R, Garrett A, Cohen J, Gomez R, Lembke A, Keller J, Reiss AL, Schatzberg A (2013). Altered brain function underlying verbal memory encoding and retrieval in psychotic major depression. *Psychiatry Research-NeuroImaging* **211**, 119–126.
- Kempton MJ, Salvador Z, Munafo MR, Geddes JR, Simmons A, Frangou S, Williams SCR (2011). Structural neuroimaging studies in major depressive disorder: meta-analysis and comparison with bipolar disorder. *Archives of General Psychiatry* **68**, 675–690.
- Lisiecka DM, Carbadello A, Fagan AJ, Ferguson Y, Meaney J, Frodl T (2013). Recruitment of the left hemispheric emotional attention neural network in risk for and protection from depression. *Journal of Psychiatry and Neuroscience* **38**, 117–128.
- MacQueen G, Frodl T (2011). The hippocampus in major depression: evidence for the convergence of the bench and bedside in psychiatric research? *Molecular Psychiatry* **16**, 252–264.
- MacQueen GM, Campbell S, McEwen BS, Macdonald K, Amano S, Joffe RT (2003). Course of illness, hippocampal function, and hippocampal volume in major depression. *Proceedings of the National Academy of Sciences USA* **100**, 1387–1392.
- Mannie ZN, Barnes J, Bristow GC, Harmer CJ, Cowen PJ (2009). Memory impairment in young women at increased risk of depression: influence of cortisol and 5-HTT genotype. *Psychological Medicine* **39**, 757–762.
- Mannie ZN, Harmer CJ, Cowen PJ, Norbury R (2010). A functional magnetic resonance imaging study of verbal working memory in young people at increased familial risk of depression. *Biological Psychiatry* **67**, 471–477.
- Mannie ZN, Norbury R, Murphy SE, Inkster B, Harmer CJ, Cowen PJ (2008). Affective modulation of anterior cingulate cortex in young people at increased familial risk of depression. *British Journal of Psychiatry* **192**, 356–361.
- McCabe C, Wiffindale C, Harmer CJ, Cowen PJ (2012). Neural processing of reward and punishment in young people at increased familial risk of depression. *Biological Psychiatry* **72**, 588–594.
- Milne A, MacQueen GM, Yucel K, Soreni N, Hall GB (2009). Hippocampal metabolic abnormalities at first onset and with recurrent episodes of a major depressive disorder: a proton magnetic resonance spectroscopy study. *NeuroImage* **47**, 36–41.
- Milne AMB, MacQueen GM, Hall GBC (2012). Abnormal hippocampal activation in patients with extensive history of major depression: an fMRI study. *Journal of Psychiatry and Neuroscience* **37**, 28–36.
- Moylan S, Maes M, Wray NR, Berk M (2013). The neuroprogressive nature of major depressive disorder: pathways to disease evolution and resistance, and therapeutic implications. *Molecular Psychiatry* **18**, 595–606.
- Near J, Edden R, Evans CJ, Pacquin R, Harris A, Jezzard P (2014). Frequency and phase drift correction of magnetic resonance spectroscopy data by spectral registration in the time domain. *Magnetic Resonance in Medicine*. Published online 16 January 2014. doi:10.1002/mrm.25094.
- Oertel-Knöchel V, Reinke B, Feddern R, Knake A, Knöchel C, Prvulovic D, Fußer F, Karakaya T, Loellgen D, Freitag C, Pantel J, Linden DEJ (2013). Verbal episodic memory deficits in remitted bipolar patients: a combined behavioural and fMRI study. *Journal of Affective Disorders* **150**, 430–440.
- Oldfield RC (1971). The assessment and analysis of handedness: The Edinburgh Inventory. *Neuropsychologia* **9**, 97–113.
- Parker G (1979). Parental characteristics in relation to depressive disorders. *British Journal of Psychiatry* **134**, 138–147.

- Patenaude B, Smith SM, Kennedy DN, Jenkinson M** (2011). A Bayesian model of shape and appearance for subcortical brain segmentation. *NeuroImage* **56**, 907–922.
- Provencher SW** (1993). Estimation of metabolite concentrations from localized *in vivo* proton NMR spectra. *Magnetic Resonance Medicine* **30**, 672–679.
- Rao U, Chen LA, Bidesi AS, Shad MU, Thomas MA, Hammen CL** (2010). Hippocampal changes associated with early life adversity and vulnerability to depression. *Biological Psychiatry* **67**, 357–364.
- Rottschy C, Langer R, Dogan I, Reetz K, Laird AR, Schultz JB, Fox PT, Eickhoff SB** (2012). Modelling neural correlates of working memory: a coordinate-based meta-analysis. *NeuroImage* **60**, 830–846.
- Smith S, Jenkinson M, Woolrich MW, Beckman CF, Behrens TEJ, Johansen-Berg H, Banister PR, De Luca M, Drobnjak I, Flitney DE, Niazy RK, Saunders J, Vickers J, Zhang Y, De Stefano N, Brady JM, Matthews PM** (2004). Advances in functional and structural MR image analysis and implementation as FSL. *NeuroImage* **23**, S208–S219.
- Taylor MJ, Mannie ZN, Norbury R, Near J, Cowen PJ** (2011). Elevated cortical glutamate in young people at increased familial risk of depression. *International Journal of Neuropsychopharmacology* **14**, 255–259.
- Toki S, Okamoto Y, Onoda K, Matsumoto T, Yoshimura S, Kunisato Y, Okada G, Shishida K, Kobayakawa M, Fukumoto T, Machino A, Inagaki M, Yamawaki S** (2014). Hippocampal activation during associative encoding of word pairs and its relation to symptomatic improvement in depression: a functional and volumetric fMRI study. *Journal of Affective Disorders* **152–154**, 462–467.
- Werner NS, Meindl T, Materne J, Engel R, Huber D, Riedel M, Reiser M, Hennig-Fast K** (2009). Functional MRI study of memory-related brain regions in patients with depressive disorder. *Journal of Affective Disorders* **119**, 124–131.
- Woolrich M** (2008). Robust group analysis using outlier inference. *NeuroImage* **41**, 286–301.
- Woolrich MW, Behrens TE, Beckmann CF, Jenkinson M, Smith SM** (2004). Multilevel linear modeling for fMRI group analysis using Bayesian inference. *NeuroImage* **21**, 1732–1747.
- Yassa MA, Stark CEL** (2008). Multiple signals of recognition memory in the medial temporal lobe. *Hippocampus* **18**, 945–954.
- Yuksel C, Ongur D** (2010). Magnetic resonance spectroscopy studies of glutamate-related abnormalities in mood disorders. *Biological Psychiatry* **68**, 785–794.
- Zakzanis KK, Leach L, Kaplan E** (1998). On the nature and pattern of neurocognitive function in major depressive disorder. *Neuropsychiatry, Neuropsychology and Behavioral Neurology* **11**, 111–119.
- Zigmond AS, Snaith RP** (1983). The Hospital Anxiety and Depression Scale. *Acta Psychiatrica Scandinavica* **67**, 361–370.