

Case Report

Mullerianosis of the Urinary Bladder: A Case Report

Rawan Abdul Razack Amir^a Khalid M. Taheini^b Salwa S. Sheikh^c

^aImam Abdulrahman Bin Faisal University, Dhahran, Saudi Arabia; ^bConsultant Urologist, Johns Hopkins Aramco Healthcare, Dhahran, Saudi Arabia; ^cPathology Services Division, Johns Hopkins Aramco Healthcare, Dhahran, Saudi Arabia

Keywords

Mullerianosis · Bladder · Neoplasm

Abstract

Mullerianosis is a rare entity consisting of an admixture of 2 or more of the following tissues: endometriosis, endocervicosis, and endosalpingiosis. It most commonly affects the urinary bladder and affects females of fertile age. It presents clinically as hematuria, dysuria, and pelvic pain which may be associated with menstruation. Radiologically and macroscopically, it typically presents as a polypoid mass in the dome or posterior wall of the bladder. Histologically, it consists of glands of varying size lined by endometrial, endocervical, or tubal epithelium. Mullerianosis clinically and histologically mimics other benign and malignant lesions. Herein we report a case of mullerianosis of the urinary bladder. This is a rare lesion with less than 20 cases reported in the literature thus far. We believe raising awareness of this poorly recognized entity is of utmost significance in order to avoid misdiagnosis and the following unnecessary radical procedures.

© 2018 The Author(s)
Published by S. Karger AG, Basel

Introduction

The most common site of the urinary tract affected by endometriosis is the urinary bladder. Other lesions including endocervicosis, consisting mainly of endocervical glands, and endosalpingiosis, consisting mainly of tubal epithelium, can also be found in the urinary

bladder. A combination of two or more of these tissues is termed mullerianosis, first coined by Young and Clement in 1996 [1]. This lesion is typically found in females of fertile age and presents clinically as dysuria, pelvic pain, or hematuria which may or may not be associated with menstruation. It is important to understand the features of this lesion well as it clinically, cytologically, and histologically tends to mimic several other benign and malignant lesions of the bladder. Herein we report a case of mullerianosis of the bladder in a 40-year-old female. This is an uncommon entity with only less than 20 cases reported in literature thus far.

Case Presentation

A 40-year-old morbidly obese and hypertensive Saudi female presented with urgency and urge incontinence during menstruation.

She also had a history of several renal stones for which a double J stent was inserted. During this procedure, cystoscopy was done and the bladder walls were visualized. Everything appeared to be normal aside from a small nodular edematous lesion, around 2 cm in size, involving the posteromedial wall near the left ureteric orifice. Less than 1 year later, she presented with the same symptoms of a renal stone and was treated using extracorporeal shock wave lithotripsy. Four years later, she presented with complains of severe gross hematuria. Cystoscopy was preformed and an area of congestion was identified around the left ureteric orifice.

As the patient's urgency continued to progress, an ultrasound of the urinary tract was performed that showed an echogenic mass arising from the left side of the posterior wall of the urinary bladder extending to the base. The lesion measured 3.9 × 2.2 cm, and on Doppler study showed extensive intralesional vascularity suggestive of a neoplastic lesion. A biopsy was taken that showed on microscopy hyperplastic urothelium with underlying Brunns' nests, cystitis cystica, cystitis glandularis, and underlying nonspecific inflammation. No atypia or malignant cells were identified.

MRI of the pelvis was performed which showed the uterus had a bicornis unicollis anomaly and multiple nabothian cysts of the cervix. In addition, there was a neoplastic urinary bladder mass. However, cystoscopy could not confirm the presence of a well-defined bladder tumor. One year later, the patient was referred to another institute for further assessment of this possible bladder tumor. Pelvic and transvaginal ultrasounds were performed, and the pelvic ultrasound confirmed the previous findings of a bicornuate uterus and multiple nabothian cysts. They also showed a soft tissue irregular mass in the left posterolateral wall of the bladder measuring 4 × 3.5 cm. CT of the abdomen and pelvis was done and showed the same mass as described earlier with no further growth of the lesion from previous measurements. The lesion was subsequently excised and histological examination showed presence of inflammation with associated metaplastic changes. In addition, there were deep-seated glands that were lined by endocervical and ciliated tubal type epithelium. Some glands were lined by endometrial epithelium and showed surrounding endometrial stroma. Immunohistochemistry showed strong positivity of stromal cells for estrogen and progesterone receptors and CD10. The presence of these deeply seated benign cystic glandular structures lined by variable epithelial cells was consistent with mullerianosis.

Discussion

Mullerianosis is a rare entity first described in 1996 by Young and Clement [1] as an admixture of two or more mullerian tissues (endometrial, cervical, tubal) in the urinary bladder's lamina propria and muscularis propria. Unlike endometriosis, mullerianosis is found within the organ as opposed to being on the outer surface of an organ. It is of great importance to focus interest on this topic due to its ability to mimic neoplastic lesions from the clinical as well as cytological and histological aspects. To date, less than 20 cases of mullerianosis of the urinary bladder have been reported in the literature. There are a few reports of this lesions' occurrence in other sites including the spinal cord, inguinal lymph nodes, ureter, and mesosalpinx [2].

The exact pathogenesis of mullerianosis is still a topic of debate. There are many theories behind its occurrence, the two main ones being the implantation theory and the metaplastic theory. The implantation theory suggests that mullerian tissue becomes implanted within the bladder during pelvic surgery or caesarian section. However, this theory fails to explain mullerianosis in people with no prior operative history, or mullerianosis in other distant sites. The metaplastic hypothesis explains the presence of multiple types of tissue in the bladder as potentially resulting from the differentiation of mullerian epithelium into endometrial, endocervical, and tubal types. In addition, the location of mullerianosis is exclusive to the bladder's posterior wall, a place that relates to its peritoneal covering and is extremely sensitive to female hormones. Branca and Barresi [2] suggest that the secondary mullerian system, which during development forms the peritoneal mesothelium, may retain its ability to differentiate into different types of tissue including endometrial, endocervical, and tubal [3]. Furthermore, Koren et al. [4] reported a case in which tubular epithelium was in continuity with urothelium in cystitis cystica and cystitis glandularis, and all these cells were positive for estrogen and progesterone receptors, strongly supportive of the metaplastic theory. In general, most authorities favor the metaplastic theory over the implantation theory.

A classic case of mullerianosis would be a female in her fertile age period presenting with nonspecific symptoms such as pelvic pain, hematuria, and lower urinary tract symptoms, mainly dysuria, which may or may not be associated with menstruation. A history of pelvic surgery is obtained in 50% of cases [5]. The age range in which patients are diagnosed with mullerianosis varies from 28 to 55 years [2]. Mullerianosis has not been reported so far in male patients; however, endometriosis by itself can be seen in men with prostate cancer receiving estrogen therapy.

Radiologically, the lesion presents as a polypoid mass. Macroscopically, mullerianosis is seen as a polypoid mass involving the dome or posterior wall of the bladder ranging from 1 to 4.5 cm in size. Rare cases may have internal cystic structures that have the appearance of dark-blue to black cysts [6].

Histologically, they appear as glands of varying size in the lamina propria and muscularis propria which are lined by tubal, endocervical, and endometrial epithelium (Fig. 1, 2). The endometrial type glands are often surrounded by endometrial-like stroma. Sometimes, some urothelium may also be found in the glands along with mullerian tissue. The lesion is typically benign, lacking any indications of malignancy such as atypia or increased mitosis.

On immunohistochemistry, estrogen and progesterone receptors are positive, which make this tumor sensitive to hormones (Fig. 3). The glandular component also stains positive for Ca-125, while stromal endometrial-like tissue is positive for anti-CD10 antibody [2].

Urine cytology has been studied in some cases as it may help distinguish this pseudotumor from other benign and malignant conditions. Results are usually not significant in most cases except for rare occasions in which endometrial glands can be detected in a urine smear. The smears in such cases show groups of cells with scanty cytoplasm, somewhat irregular nuclei, fine chromatin, and slightly visible nucleoli [7]. The most important condition to rule out with urine cytology is malignancy of the urinary bladder. The presence of single epithelial cells with severely atypical nuclei within a necrotic background in a young female is strongly suggestive of neoplasia. Detection of macrophages is also a suggestive feature of mullerianosis, while detection of signet ring cells would suggest adenocarcinoma of the bladder. Another feature which might help differentiate adenocarcinoma from mullerianosis is the presence of tall mucin-rich cells lining the lesion [8].

Other differential diagnoses that could possibly be confused with mullerianosis can be ruled out mainly by histological examination. Examples include cystitis glandularis, cystitis cystica, urachal remnants, and nephrogenic adenoma among others [9].

With mullerianosis of certain sites, such as the spine, pharmacological therapy is considered the first line of management due to the great risks associated with surgical management. However, in cases of urinary bladder mullerianosis, transurethral resection is the recommended line of treatment. Despite the fact that recurrence has only been reported in 1 case in the literature 14 years after resection, continuous follow-up is required due to our limited knowledge of this rare and relatively recently described entity.

Conclusion

Mullerianosis is a recently described rare benign lesion, typically seen in the urinary bladder, in which a combination of two or more of the following are found: endometriosis, endocervicosis, and endosalpingiosis. It often clinically and histologically mimics other benign and malignant entities. Clinically, it presents as dysuria, pelvic pain, and hematuria. Histologically, it is composed of glands lined by various mullerian tissues. It is important to raise awareness of such an entity in order to avoid incorrect diagnosis and unnecessary extreme surgical interventions.

Statement of Ethics

The authors have no ethical conflicts to declare.

Disclosure Statement

There is no conflict of interest, financial acknowledgment, or any other disclosure.

References

- 1 Young R, Clement P. Mullerianosis of the urinary bladder. *Mod Pathol*. 1996 Jul;9(7):731–7.
- 2 Branca G, Barresi V. Müllerianosis of the urinary bladder: a rare tumorlike lesion. *Arch Pathol Lab Med*. 2014 Mar;138(3):432–6.
- 3 Maeda K, Kojima F, Ishida M, Iwai M, Kagotani A, Kawauchi A. Müllerianosis and endosalpingiosis of the urinary bladder: report of two cases with review of the literature. *Int J Clin Exp Pathol*. 2014 Jun;7(7):4408–14.
- 4 Koren J, Mensikova J, Mukensnabl P, Zamecnik M. Mullerianosis of the urinary bladder: report of a case with suggested metaplastic origin. *Virchows Arch*. 2006 Aug;449(2):268–71.
- 5 Young RH. Tumor-like lesions of the urinary bladder. *Mod Pathol*. 2009 Jun;22(S2 Suppl 2):S37–52.
- 6 Guan H, Rosenthal DL, Erozan YS. Mullerianosis of the urinary bladder: report of a case with diagnosis suggested in urine cytology and review of literature. *Diagn Cytopathol*. 2012 Nov;40(11):997–1001.
- 7 Jiménez-Heffernan JA, Sánchez-Piedra D, Bernaldo de Quiros L, Martínez V. Endosalpingiosis (müllerianosis) of the bladder: a potential source of error in urinary cytology. *Cytopathology*. 2000 Oct;11(5):348–53.
- 8 Whitworth SA, Subhawong AP, Rosenthal DL, Ali SZ. Clear cell adenocarcinoma of the lower urinary tract: cytopathologic characteristics and differential diagnoses. *Cancer Cytopathol*. 2012 Oct;120(5):308–12.
- 9 Kudva R, Hegde P. Mullerianosis of the urinary bladder. *Indian J Urol*. 2012 Apr;28(2):206–7.

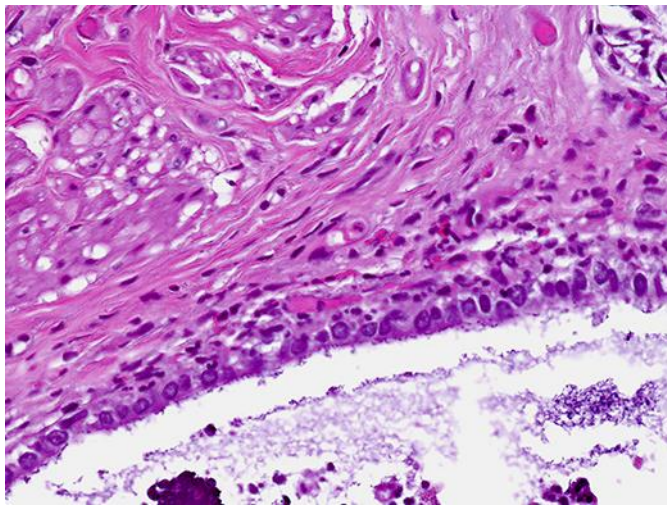


Fig. 1. Cystic structure lined by endocervical epithelium consistent with endosalpingiosis.

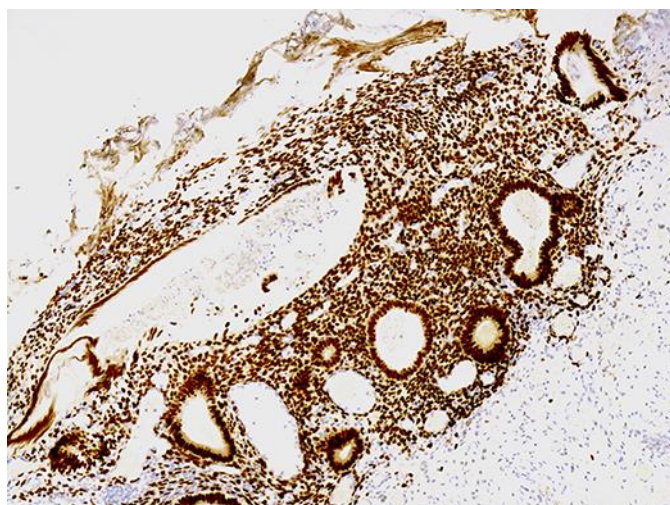


Fig. 2. Endometriosis as evidenced by endometrial glands surrounded by stroma.

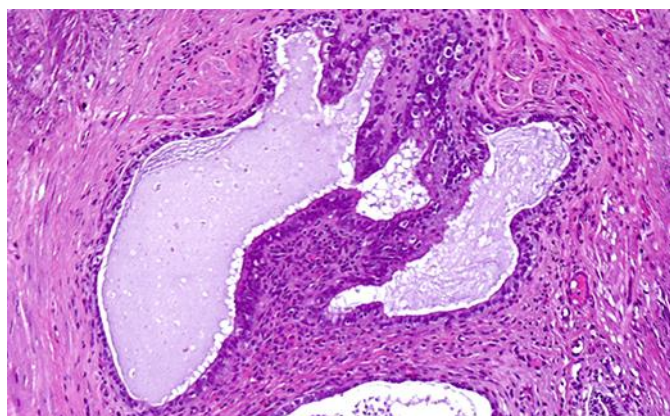


Fig. 3. Estrogen receptor strongly positive in glandular and surrounding endometrial stromal cells.