

Case Report

Successful Long-Term Use of Itraconazole for the Treatment of *Aspergillus* Diskospondylitis in a Dog

Emiko Van Wie,¹ Annie V. Chen,² Stephanie A. Thomovsky,² and Russell L. Tucker²

¹ Texas A&M University College of Veterinary Medicine, 422 Raymond Stotzer Parkway, College Station, TX 77843, USA

² Washington State University College of Veterinary Medicine, P.O. Box 647010, Pullman, WA 99164, USA

Correspondence should be addressed to Annie V. Chen; avchen@vetmed.wsu.edu

Received 1 December 2012; Accepted 30 December 2012

Academic Editors: F. Mutinelli, J. Orós, L. G. Papazoglou, and P. Roccabianca

Copyright © 2013 Emiko Van Wie et al. This is an open access article distributed under the Creative Commons Attribution License, which permits unrestricted use, distribution, and reproduction in any medium, provided the original work is properly cited.

A 5-year-old spayed female German shepherd dog was admitted with a history of generalized stiffness. Neurologic examination revealed mild paraparesis with multifocal spinal pain. Spinal radiographs and magnetic resonance imaging revealed diskospondylitis at L6-7 and multiple sites throughout the thoracolumbar spine. Biopsy of the intervertebral disk at L6-7 revealed a positive culture for *Aspergillus* species, and the dog was placed on itraconazole indefinitely. Clinical signs were significantly improved after two weeks of itraconazole. The dog was reevaluated 8 years later for unrelated reasons. No spinal pain was detected. Spinal radiographs revealed a fused L6-7 disk space and collapsed and sclerotic disk spaces at multiple sites. Itraconazole was tolerated by the dog with normal yearly liver enzyme values. To our knowledge, this is the first reported case of successful long-term use of itraconazole for the treatment of *Aspergillus* diskospondylitis in a dog.

1. Introduction

Diskospondylitis is an infection of the intervertebral disk with concurrent osteomyelitis in adjacent vertebral endplates. The most common cause of diskospondylitis is hematogenous spread of bacteria or fungi from urinary tract infections, dental infections, or endocarditis [1, 2]. Migrating foreign bodies, such as grass awns, have also been incriminated as a source of infection. *Staphylococcus aureus* is the most common cause of canine diskospondylitis.

Aspergillus is a fungus that is ubiquitous in the environment and an opportunistic pathogen. *Aspergillus terreus* is the most common species associated with disseminated aspergillosis [2]. Female German shepherd dogs are the most commonly affected breed with disseminated aspergillosis. It is speculated that German shepherd dogs have a hereditary immune defect that plays a significant role in the pathogenesis [1, 3]. In disseminated cases, it is not uncommon to find radiographic changes consistent with multiple sites of diskospondylitis [3, 4].

Aspergillosis can be localized to the spine only. There have been four published canine cases of *Aspergillus*

diskospondylitis, without the presence of systemic involvement, in the veterinary literature [1, 5, 6]. All four cases were seen in German shepherd dogs; these dogs were euthanized due to poor prognosis or neurologic deterioration. The purpose of this report is to describe a case of nondisseminated *Aspergillus* diskospondylitis in a dog that was successfully treated with long-term itraconazole.

2. Case Presentation

A 5-year-old (41.2-kg) spayed female German shepherd dog was evaluated for a 3-month history of generalized stiffness that was refractory to pain medications. On admission, rectal temperature, heart rate, and respiration rate were within normal limits. Physical examination was unremarkable. Neurologic examination revealed kyphosis, paraparesis, and mild conscious proprioceptive deficits in the pelvic limbs. Spinal reflexes and cranial nerves were normal. Spinal palpation elicited pain in the midthoracic area and lower lumbar spine.

Complete blood count, serum biochemical analysis, and urinalysis were unremarkable. Spinal radiographs revealed

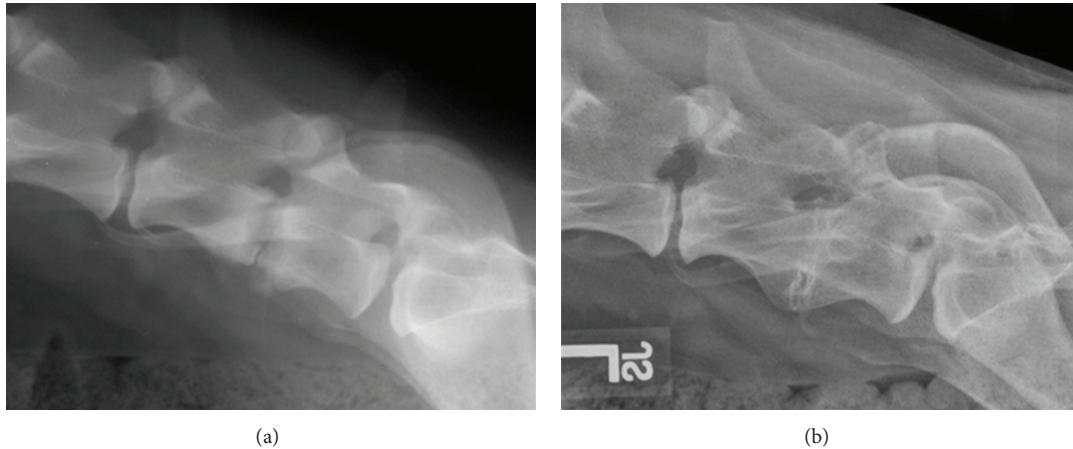


FIGURE 1: Lateral radiographs of the lower lumbar spine prior to (a) and after 8 years (b) of itraconazole treatment. (a) The L6-7 intervertebral disk space is collapsed and there is lysis of the endplates consistent with active diskospondylitis. (b) The L6-7 intervertebral disk space is collapsed and partially fused with smoothly margined osseous proliferation between the ventral aspects of the vertebral bodies suggestive of healed diskospondylitis.

diskospondylitis at L6-7. Lumbar cerebrospinal fluid (CSF) revealed a mildly elevated protein count (55.5 mg/dL, reference <35 mg/dL) with mild blood contamination. Blood, urine, and CSF cultures for aerobic and anaerobic bacteria and fungal organisms were negative. Serum *Brucella* titer was negative via rapid slide agglutination test. Amoxicillin and clavulanic acid (Clavamox, Pfizer) was prescribed at 22 mg/kg orally every 8 hours. There was no improvement after three weeks; antibiotic therapy was changed to clindamycin and ciprofloxacin.

Six weeks later, the dog was re-evaluated for persistent spinal pain. Neurologic examination was unchanged from the initial visit. Spinal radiographs revealed further lysis of endplates and collapse of the disk space at L6-7 consistent with diskospondylitis (Figure 1(a)). Additionally, irregular endplates were found at T3-9 suspicious for diskospondylitis. Magnetic resonance (MR) imaging of the entire spine revealed multiple sites of diskospondylitis. On the T2-weighted images, irregular nucleus pulposus was seen at T2-10, T13-L1, and L6-7. On gadolinium dimeglumine (Magnevist, Bayer Health Care Pharmaceuticals) enhanced T1-weighted images, the intervertebral disk and endplates at L6-7 showed marked contrast enhancement along with moderate nerve root compression bilaterally (Figure 2).

A left-sided hemilaminectomy at L6-7 with a partial discectomy was performed for nerve root decompression and intervertebral disk biopsy. Fungal hyphae were seen in the disk sample histologically and *Aspergillus* species were cultured. The specific species of *Aspergillus* was not available because fungal sequencing was not performed. Oral itraconazole (Sporanox, Janssen Pharmaceutica) was given at 5 mg/kg every 24 hours indefinitely. After 2 weeks of therapy, the dog was significantly improved clinically. By 6 weeks, the dog was 90% back to normal according to the owner.

The dog presented 8 years after the initiation of itraconazole therapy for unrelated reasons. The dog was on 5 mg/kg of itraconazole every 24 hours and tolerated treatment well

with normal yearly liver enzyme values. Physical exam was unremarkable. Neurologic exam revealed mild paraparesis, mild conscious proprioceptive deficits in the pelvic limbs, and no spinal pain.

Spinal radiographs showed collapse and partial fusion of the L6-7 intervertebral disk space with smoothly margined osseous proliferation between the ventral aspects of the vertebral bodies (Figure 1(b)). Additionally, there were collapsed intervertebral disk spaces at T2-T11 and T13-L2. The endplates at T13-L1 and L1-L2 were also very irregular with sclerosis and potential lucency. Ventral bridging spondylosis was seen throughout the thoracic and thoracolumbar spine. Overall, the L6-7 diskospondylitis appeared to be healed; however, it could not be determined radiographically if the other sites were chronically healed or still active. Clinically, the patient had no spinal pain consistent with active diskospondylitis. However, due to the potential lucency noted at the T13-L2 endplates, continual therapy with itraconazole was recommended.

3. Discussion

In general, canine aspergillosis carries a poor prognosis [1, 4–8]. Most cases of disseminated aspergillosis with diskospondylitis are euthanized. A variety of treatments have been tried in several cases including itraconazole, ketoconazole, voriconazole, posaconazole, amphotericin B, and hamycin; however, euthanasia was elected within a year in most of the cases due to progression of disease [1, 4, 9–13]. There has been one reported survival of 4.3 years in a dog with disseminated aspergillosis and diskospondylitis treated with itraconazole alone for 2.7 years [9]. This dog was euthanized due to relapse of clinical signs after treatment was discontinued.

Nondisseminated *Aspergillus* diskospondylitis also carries a poor prognosis in dogs [1, 5, 6]. Of the 4 reported cases, all dogs were euthanized. Two of these dogs were

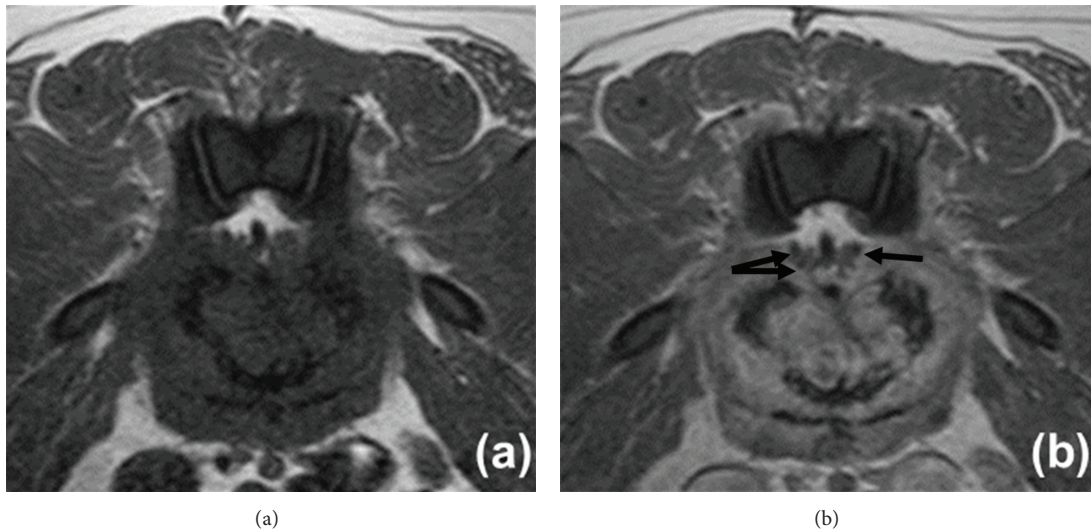


FIGURE 2: Transverse T1-weighted before (a) and after (b) contrast MR imaging of the L6-7 intervertebral disk space. There is strong contrast enhancement of the intervertebral disk and endplates suggestive of active diskospondylitis. Nerve root compression (hypointense circles as indicated by arrows) from the inflamed disk is also noted bilaterally.

euthanized shortly after diagnosis. One dog was treated with ketoconazole for three weeks and was euthanized due to neurologic deterioration. The fourth dog was euthanized after lack of improvement on antibiotics and aspergillosis was diagnosed at necropsy.

In most current studies, azole antifungals were the choice of treatment for aspergillosis. Compared to amphotericin B and ketoconazole, itraconazole was more effective and had fewer side effects [2]. Itraconazole works by inhibiting fungal P450 enzyme necessary for ergosterol synthesis. Treatment with itraconazole alone has shown to extend survival time and improve clinical signs with aspergillosis diskospondylitis [9, 10]. However, long-term survival greater than 1 year has only been reported in one case [9]. Fluconazole has little activity against aspergillosis [2].

The dog in this case report had multiple sites of *Aspergillus* diskospondylitis without any signs of systemic dissemination. Initially, the dog was diagnosed with only one site of diskospondylitis even though multifocal spinal pain was noted. Six weeks later, radiographs and MR imaging revealed multifocal sites of diskospondylitis. It is not uncommon for radiographic evidence of diskospondylitis to lag behind the onset of clinical signs by as much as 2–6 weeks; thus, acutely affected patients can have equivocal or even normal radiographic findings [14, 15]. Follow-up radiographs 8 years later showed 2 additional sites of collapsed disk spaces and sclerotic endplates at T10–11 and L1–2 and potential lucency at the endplates of T13–L2. Because no follow-up radiographs were documented between these two time points, it is unknown when these additional sites became affected in the course of disease. Also, whether these sites were active or actually chronically healed sites could not be determined radiographically. One of the limitations of radiographs is the difficulty of differentiating chronic diskospondylitis from healing lesions or even degenerative changes of the spine [14, 15]. Advanced imaging techniques



such as MR imaging or computed tomography with contrast or nuclear scintigraphy may have been helpful to clarify this [16, 17].

This is the first reported case of nondisseminated *Aspergillus* diskospondylitis successfully treated with long-term itraconazole. The speculated reasons for success in this case may be related to an early surgical diagnosis which allowed for early treatment before dissemination of the disease and/or due to lifelong treatment with itraconazole, despite early resolution of clinical signs. This dog had no long-term side effects from itraconazole. Although the dog had no clinical signs consistent with diskospondylitis, radiographs suggest active aspergillosis may still be present. Indefinite, lifelong treatment with itraconazole should be considered in dogs with *Aspergillus* diskospondylitis, particularly German shepherd dogs with potential immune deficiency, in order to prevent progression of clinical signs or relapse. Treatment until resolution of clinical signs may not be sufficient.

References

- [1] W. L. Berry and A. L. Leisewitz, "Multifocal *Aspergillus terreus* diskospondylitis in two German shepherd dogs," *Journal of the South African Veterinary Association*, vol. 67, no. 4, pp. 222–228, 1996.
- [2] J. Lavelly and D. Lipsitz, "Fungal infections of the central nervous system in the dog and cat," *Clinical Techniques in Small Animal Practice*, vol. 20, no. 4, pp. 212–219, 2005.
- [3] M. J. Day, W. J. Penhale, C. E. Eger et al., "Disseminated aspergillosis in dogs," *Australian Veterinary Journal*, vol. 63, no. 2, pp. 55–59, 1986.
- [4] R. M. Schultz, E. G. Johnson, E. R. Wisner, N. A. Brown, B. A. Byrne, and J. E. Sykes, "Clinicopathologic and diagnostic imaging characteristics of systemic Aspergillosis in 30 dogs," *Journal of Veterinary Internal Medicine*, vol. 22, no. 4, pp. 851–859, 2008.

- [5] R. A. Weitkamp, "Aspergilloma in two dogs," *Journal of the American Animal Hospital Association*, vol. 18, no. 3, pp. 503–506, 1982.
- [6] A. M. Wolf and G. C. Troy, "Deep mycotic disease," in *Textbook of Veterinary Internal Medicine; Diseases of the Dog and Cat*, S. Ettinger and E. C. Feldman, Eds., pp. 439–444, Saunders, Philadelphia, Pa, USA, 4th edition, 1995.
- [7] S. S. Jang, T. E. Dorr, E. L. Biberstein, and A. Wong, "Aspergillus deflectus infection in four dogs," *Journal of Medical and Veterinary Mycology*, vol. 24, no. 2, pp. 95–104, 1986.
- [8] J. Pastor, M. Pumarola, R. Cuenca, and S. Lavin, "Systemic aspergillosis in a dog," *Veterinary Record*, vol. 132, no. 16, pp. 412–413, 1993.
- [9] S. E. Kelly, S. E. Shaw, and W. T. Clark, "Long-term survival of four dogs with disseminated *Aspergillus terreus* infection treated with itraconazole," *Australian Veterinary Journal*, vol. 72, no. 8, pp. 311–313, 1995.
- [10] M. J. Dallman, T. L. Dew, L. Tobias, and R. Doss, "Disseminated aspergillosis in a dog with diskospondylitis and neurologic deficits," *Journal of the American Veterinary Medical Association*, vol. 200, no. 4, pp. 511–513, 1992.
- [11] G. L. Wood, D. C. Hirsh, and R. R. Selcer, "Disseminated aspergillosis in a dog," *Journal of the American Veterinary Medical Association*, vol. 172, no. 6, pp. 704–707, 1978.
- [12] S. J. Butterworth, F. J. Barr, G. R. Pearson, and M. J. Day, "Multiple discospondylitis associated with *Aspergillus* species infection in a dog," *Veterinary Record*, vol. 136, no. 2, pp. 38–41, 1995.
- [13] A. C. Kaufman, C. E. Greene, B. A. Selcer, M. E. Styles, and E. A. Mahaffey, "Systemic aspergillosis in a dog and treatment with hamycin," *Journal of the American Animal Hospital Association*, vol. 30, no. 2, pp. 132–136, 1994.
- [14] L. Hurov, G. Troy, and G. Turnwald, "Diskospondylitis in the dog: 27 cases," *Journal of the American Veterinary Medical Association*, vol. 173, no. 3, pp. 275–281, 1978.
- [15] M. H. Shamir, N. Tavor, and T. Aizenberg, "Radiographic findings during recovery from discospondylitis," *Veterinary Radiology and Ultrasound*, vol. 42, no. 6, pp. 496–503, 2001.
- [16] I. Carrera, M. Sullivan, F. Mcconnell, and R. Gonçalves, "Magnetic resonance imaging features of discospondylitis in dogs," *Veterinary Radiology and Ultrasound*, vol. 52, no. 2, pp. 125–131, 2011.
- [17] L. Stern, R. McCarthy, R. King, and K. Hunt, "Imaging diagnosis—discospondylitis and septic arthritis in a dog," *Veterinary Radiology and Ultrasound*, vol. 48, no. 4, pp. 335–337, 2007.



Hindawi

Submit your manuscripts at
<http://www.hindawi.com>

