

# Six-month treatment with atypical antipsychotic drugs decreased frontal-lobe levels of glutamate plus glutamine in early-stage first-episode schizophrenia

Naoki Goto<sup>1</sup>  
Reiji Yoshimura<sup>1</sup>  
Shingo Kakeda<sup>2</sup>  
Joji Nishimura<sup>2</sup>  
Junji Moriya<sup>2</sup>  
Kenji Hayashi<sup>1</sup>  
Asuka Katsuki<sup>1</sup>  
Hikaru Hori<sup>1</sup>  
Wakako Umene-Nakano<sup>1</sup>  
Atsuko Ikenouchi-Sugita<sup>1</sup>  
Yukunori Korogi<sup>2</sup>  
Jun Nakamura<sup>1</sup>

<sup>1</sup>Department of Psychiatry, University of Occupational and Environmental Health, Kitakyushu, Fukuoka, Japan; <sup>2</sup>Department of Radiology, University of Occupational and Environmental Health, Kitakyushu, Fukuoka, Japan

**Objective:** To study the effects of treatment with atypical antipsychotic drugs on brain levels of glutamate plus glutamine in early-stage first-episode schizophrenia.

**Participants:** Sixteen patients (eight males, eight females; aged  $30 \pm 11$  years) completed the study.

**Methods:** We used administered 6 months of atypical antipsychotic drugs and used proton magnetic resonance spectroscopy to evaluate the results.

**Results:** We found that the administration of atypical antipsychotic drugs for 6 months decreased the glutamate plus glutamine/creatine ratio in the frontal lobe. These results suggest that the administration of atypical antipsychotic drugs for at least 6 months decreased glutamatergic neurotransmissions in the frontal lobe in early-stage first-episode schizophrenia, but there was no difference in frontal-lobe levels between patients and control subjects before administration.

**Conclusion:** Taking these findings into account, the glutamatergic and GABAergic neurons are implicated in early-stage first-episode schizophrenia, but in complex ways.

**Keywords:** Proton magnetic resonance spectroscopy, creatine, frontal lobe, parieto-occipital node, left basal ganglia

## Introduction

Glutamate's role in schizophrenia has been investigated in recent years. Abnormal glutamatergic neurotransmission has been reported in human postmortem studies. Proton magnetic resonance spectroscopy (MRS) allows us to examine brain glutamate and glutamine in vivo. Tibbo et al<sup>1</sup> reported that the glutamate system might play a role in neuroarchitectural abnormalities seen in schizophrenia and that higher-than-normal glutamatergic metabolites at the early stages of schizophrenia might lead to excitotoxicity, which decreases in the chronic state. Olbrich et al<sup>2</sup> also demonstrated that glutamate levels were significantly higher in the left dorsolateral prefrontal cortex in patients with first-episode schizophrenia. In contrast, no difference was found in glutamate plus glutamine between schizophrenia patients and controls in other regions.<sup>3,4</sup> Taking these findings into account, brain glutamate levels in schizophrenia seem inconsistent and controversial. The aim of the present study was to investigate the brain levels of glutamate plus glutamine in early-stage first-episode schizophrenia patients. Another aim was to examine the influence of atypical antipsychotic treatment on brain levels of glutamate plus glutamine in the patients. Therefore, we investigated the effects of treatment with atypical antipsychotic drugs for 6 months

Correspondence: Reiji Yoshimura  
Department of Psychiatry, University of Occupational and Environmental Health, 1-1 Iseigaoka, Yahatanishi-ku, Kitakyushu 8078555, Fukuoka, Japan  
Tel +81 936 917 253  
Fax +81 936 924 894  
Email yoshi621@med.uoeh-u.ac.jp

on brain levels of glutamate plus glutamine in the frontal lobe, left basal ganglia, and the parieto-occipital lobe in early-stage first-episode schizophrenia patients treated with atypical antipsychotics.

## Methods

### Subjects

A total of 23 patients who fulfilled DSM-IV-TR criteria A, B, D, E, and F, but who were within 6 months of disease onset, were recruited for the study, and all underwent MRS evaluation. After 6 months of follow-up, a diagnosis of schizophrenia was established in 20 of 23 patients. Two patients were excluded from the study, one because of the difficulty of performing MRS given his mental condition, and the other because the image quality was impaired by severe artifacts from dental materials. Thus, 18 patients (nine males, nine females; aged  $31 \pm 12$  years) were finally enrolled in the study. All patients were screened using the Structured Clinical Interview for DSM-IV disorders, and exclusion criteria for all groups included current or past serious medical or neurological illness or dependence on alcohol, or illicit substances. The patients' psychopathology was assessed with the Positive and Negative Syndrome Scale (PANSS).<sup>5</sup> Sixteen (eight males, eight females;  $30 \pm 11$  years) of 18 patients were followed for 6 months. Eighteen healthy volunteers (nine males, nine females; age range  $29 \pm 11$  years) with no current or past psychiatric history were also studied by MRS as sex- and age-matched controls. This study was approved by the Ethics Committee of the University of Occupational and Environmental Health. All participants gave written informed consent to participate in the study.

### MRS methodology

All subjects were examined between 4pm and 6pm, by <sup>1</sup>H-MRS using a 3T MR system (Signa EXCITE 3T; GE Medical Systems, Waukesha, WI) with a standard quadrature head coil (GE Medical Systems). The regions of interest (ROIs) for <sup>1</sup>H-MRS were set for the frontal lobe, the left basal ganglia, and the parieto-occipital lobe (ROI size = 3.0 cm × 3.0 cm × 3.0 cm) using two oriented images (axial image and sagittal image) for each region. We put a voxel in the frontal lobe, the left basal ganglia, and the parieto-occipital lobe. All of these ROIs were placed so as to avoid the lateral ventricle and skull.

We previously obtained brain gamma-aminobutyric acid (GABA) measurements in schizophrenic patients using a MEGA-PRESS sequence<sup>9</sup>, and have reported that the reductions in the GABA concentrations were significantly greater in patients at the early stage of schizophrenia than in controls.<sup>6</sup>

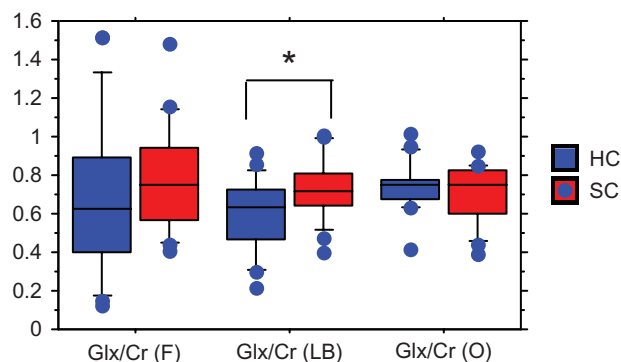
By using a MEGA-PRESS sequence, the spectroscopic measurements of glutamate and glutamine in the same voxel could be obtained. Thus, in the present study, the glutamate and glutamine levels were acquired with the MEGA-PRESS sequence using the following parameters: repetition time (TR) 3 seconds, echo time (TE) 68 milliseconds, and 128 averages. The total acquisition time for each PRESS spectrum was approximately 6 minutes. All spectra were analyzed by an LC model 12 using phantom-generated basis functions for the MEGA-edited spectra. The line width, signal-to-noise ratio, and baseline of each spectrum were checked to ensure the robustness of the data. Eddy-current correction was applied using an unsuppressed water spectrum at the appropriate echo time. The edited spectra were analyzed using LCM-basis functions that were generated from phantom measurements using the MEGA-PRESS sequence with the appropriate acquisition parameters.

### Statistical analysis

The unpaired *t*-test was used to compare differences in the glutamate plus glutamine/creatine (Cr) ratios between the schizophrenia group and the control group. Using nonparametric Wilcoxon and Mann-Whitney tests we analyzed differences in glutamate plus glutamine before and after 6 months' treatment with atypical antipsychotic drugs. The level of significance was set at  $P < 0.05$ .

## Results

There was no significant difference in age or gender between the healthy controls and the patient groups. The scores of positive (PANSS-P), negative (PANSS-N), general psychopathology (PANSS-G), and total (PANSS-T) in the early schizophrenia patients were  $15.9 \pm 4.2$ ,  $17.2 \pm 5.3$ ,  $34.2 \pm 10.1$ , and  $68.1 \pm 17.0$  (mean  $\pm$  standard deviation), respectively. The ratios of glutamate plus glutamine/Cr in the left basal ganglia were significantly higher in the patients than in the controls ( $0.72 \pm 0.16$  vs  $0.60 \pm 0.18$ ,  $z = -1.930$ ,  $P = 0.0496$ ), but no differences were found in the frontal lobe ( $0.79 \pm 0.28$  vs  $0.67 \pm 0.40$ ,  $z = -1.226$ ,  $P = 0.2057$ ) or parieto-occipital lobe ( $0.71 \pm 0.15$  vs  $0.74 \pm 0.13$ ,  $z = -0.142$ ,  $P = 0.8868$ ) (Figure 1). No associations were found between the glutamate plus glutamine/Cr ratios and positive, negative, and general psychopathology scores in PANSS. The administered atypical antipsychotic drugs and mean dosage were as follows: risperidone ( $n = 5$ ), 2.9 mg; olanzapine ( $n = 5$ ), 10.1 mg; aripiprazole ( $n = 4$ ), 16.2 mg; and quetiapine ( $n = 2$ ), 250 mg. The mean reduction of positive, negative, general psychopathology, and total scores of

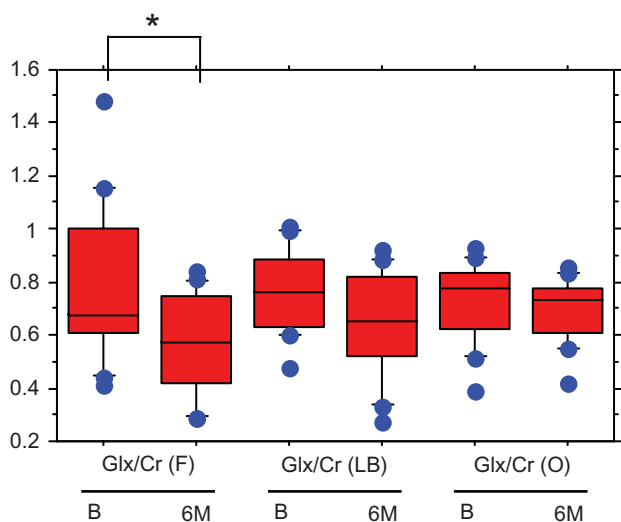


**Figure 1** The ratios of Glx/Cr in the three brain regions.

**Note:** \* $P < 0.05$ .

**Abbreviations:** Glx, glutamate plus glutamine; Cr, creatine; F, frontal lobe; LB, left basal ganglia; O, parieto-occipital lobe; HC, healthy control; SC, early-stage first-episode schizophrenia.

PANSS after 6 months' treatment with atypical antipsychotic drugs were 33.3, 26.3, 31.4, and 25.3%, respectively. Six months' administration of atypical antipsychotic drugs reduced the glutamate plus glutamine/Cr ratio in the frontal lobe (before,  $0.78 \pm 0.28$ ; after 6 months,  $0.57 \pm 0.18$ ;  $z = -2.792$ ,  $P = 0.052$ ), whereas, those in the left basal ganglia (before,  $0.76 \pm 0.15$ ; after 6 months,  $0.65 \pm 0.19$ ;  $z = -1.448$ ,  $P = 0.1477$ ), and parieto-occipital lobe (before,  $0.73 \pm 0.19$ ; after 6 months,  $0.69 \pm 0.11$ ;  $z = -1.008$ ,  $P = 0.3132$ ) were not changed by the medication (Figure 2). No correlation was observed between the changes in any scores of PANSS and the changes in the glutamate plus glutamine/Cr ratios.



**Figure 2** The changes in Glx/Cr before and 6 months after treatment with atypical antipsychotic drugs.

**Note:** \* $P < 0.05$ .

**Abbreviations:** Glx, glutamate plus glutamine; Cr, creatine; F, frontal lobe; LB, left basal ganglia; O, parieto-occipital lobe; B, before treatment with atypical antipsychotic drugs; 6M, 6 months after treatment with atypical antipsychotic drugs.

## Discussion

We found that the glutamate plus glutamine/Cr ratio in the left basal ganglia was significantly higher in early-stage first-episode schizophrenia patients than in control subjects. No differences were observed in the frontal lobe and parieto-occipital lobe between the two groups. Findings regarding glutamatergic metabolites in schizophrenia have been controversial. Stanley et al<sup>7</sup> and Ohrmann et al<sup>8</sup> reported no change in prefrontal glutamate levels in treatment-naïve first-episode schizophrenia patients. Theberge et al<sup>9</sup> found increased glutamine in the left anterior cingulate cortex and thalamus of treatment-naïve first-episode schizophrenia patients. The results in the present study were basically in accordance with the results of Stanley et al,<sup>7</sup> Ohrmann et al,<sup>8</sup> Bustillo et al,<sup>3</sup> and Reid et al.<sup>4</sup> Recently, great attention has been paid to the basal ganglia, which is an important area of interaction between GABAergic and glutamatergic neurons.<sup>10,11</sup> De la Fuente-Sandoval et al<sup>11</sup> first reported that the glutamate/Cr ratio in the dorsal caudate nucleus was higher in drug-naïve schizophrenia patients than in control subjects. The present study's findings of higher glutamate plus glutamine/Cr ratios in the left basal ganglia did not contradict those of De la Fuente-Sandoval et al.<sup>11</sup> To the best of our knowledge, this is the first report demonstrating that treatment with atypical antipsychotic drugs for at least 6 months decreased the glutamate plus glutamine/Cr ratio in the frontal cortex in early-stage first-episode schizophrenia. However, no correlation was observed between the changes in any scores in PANSS and the changes in glutamate plus glutamine/Cr. Theberge et al<sup>9</sup> reported that brain glutamate and glutamine levels were significantly decreased in the anterior cingulate cortex, which belongs to the frontal lobe, in patients with chronic medicated schizophrenia. The authors speculated that the findings might indicate a decrease in the number of glutamatergic synapses in this region. On the other hand, we reported that the brain glutamate plus glutamine/Cr ratio was significantly increased, whereas GABA/Cr was significantly reduced in the left basal ganglia in patients with early-stage first-episode schizophrenia,<sup>6</sup> and treatment with atypical antipsychotic drugs did not change brain GABA levels.<sup>12</sup> It has been reported that glutamatergic and GABAergic neurons might be disturbed in schizophrenia patients, and that these types of neurons interact.<sup>13</sup> Taking these findings into account, glutamatergic neurotransmission might be different in different brain regions and the situation becomes more complicated depending on the stage of schizophrenia. Converging experimental and clinical evidence suggests that dysfunction of proper GABAergic inhibition and

consequently imbalance between excitation and inhibition in the cerebral cortex underlies at least part of the pathophysiological process of schizophrenia.<sup>14</sup> The finding that the brain levels of glutamate plus glutamine at early-stage first-episode schizophrenia were significantly increased in the left basal ganglia, and subsequently decreased in the frontal lobe, but not in the left basal ganglia, suggests that the concentrations and changes in brain GABA and glutamate plus glutamine might vary in different brain regions. In future works, we will measure glutamate and glutamine separately, and in absolute amounts rather than as a Cr ratio, and also use drug-naïve schizophrenia patients as subjects.

## Conclusion

In conclusion, it is possible that the administration of atypical antipsychotic drugs for at least 6 months decreased glutamatergic neurotransmissions in the frontal lobe in early-stage first-episode schizophrenia patients.

## Acknowledgment

We thank Mr Toru Sato for his generous help in measuring the MRS.

## Disclosure

The authors report no conflicts of interest in this work.

## References

1. Tibbo P, Hanstock C, Allen P. 3-T proton MRS investigation of glutamate and glutamine in adolescents at high genetic risk for schizophrenia. *Am J Psychiatry*. 2004;161:1116–1118.
2. Olbrich HM, Valerius G, Rusch N, et al. Frontolimbic glutamate alterations in first episode schizophrenia: evidence from a magnetic resonance spectroscopy study. *World J Biol Psychiatry*. 2008;9:59–63.
3. Bustillo JR, Rowland LM, Mullins P, et al. 1H-MRS at 4 tesla in minimally treated early schizophrenia. *Mol Psychiatry*. 2010;15:629–636.
4. Reid MA, Stoeckel LE, White DM, et al. Assessments of function and biochemistry of the anterior cingulate cortex in schizophrenia. *Biol Psychiatry*. 2010;68:625–633.
5. Kay SR, Fiszbein A, Opler LA. The positive and negative syndrome scale (PANSS) for schizophrenia. *Schizophr Bull*. 1987;13:261–276.
6. Goto N, Yoshimura R, Ueda N, et al. Reduction of brain gamma-aminobutylic acid (GABA) concentrations in early-stage schizophrenia patients: 3T proton MRS study. *Schizophr Res*. 2009;112:192–193.
7. Stanley JA, Williamson PC, Drost DJ, et al. An in vivo proton magnetic resonance spectroscopy study of schizophrenia patients. *Schizophr Bull*. 1996;22:597–609.
8. Ohmann P, Siegmund A, Suslow T, et al. Cognitive impairment and in vivo metabolites in first-episode neuroleptic-naïve and chronic medicated schizophrenic patients: a proton magnetic resonance spectroscopy study. *J Psychiatr Res*. 2007;41:625–634.
9. Theberge J, Al-Semaan Y, Williamson PC, et al. Glutamate and glutamine in anterior cingulate and thalamus of medicated patients with chronic schizophrenia and healthy comparison subjects measured with 4.0-T proton MRS. *Am J Psychiatry*. 2003;160:2231–2233.
10. Benes FM. Amygdalocortical circuitry in schizophrenia: from circuits to molecules. *Neuropsychopharmacology*. 2010;35:239–257.
11. De la Fuente-Sandoval C, Favilla R, Alvarado P, et al. Glutamate increase in the associative striatum in schizophrenia: a longitudinal magnetic resonance spectroscopy preliminary study. *Gac Med Mex*. 2009;145:109–113. Spanish.
12. Goto N, Yoshimura R, Kakeda S, et al. No alteration of brain GABA after 6 months of treatment with atypical antipsychotic drugs in early-stage first-episode schizophrenia. *Prog Neuropsychopharmacol Biol Psychiatry*. 2010;34:1480–1483.
13. Lewis S. Synaptic neurotransmission: a closer look at GABA(B) receptors. *Nat Rev*. 2010;11:664.
14. Levitt P, Eagleson KL, Powell EM. Regulation of neocortical interneuron development and the implications for neurodevelopmental disorders. *Trends Neurosci*. 2004;27:400–406.
15. Mescher M, Merkle H, Kirsh J, Garwood M. Simultaneous in vivo spectral editing and water suppression. *NMR Biomed*. 1998;11:266–272.
16. Provencher SW. Estimation of metabolite concentrations from localized in vivo proton NMR spectra. *Magn Reson Med*. 1993;30:672–679.

### Neuropsychiatric Disease and Treatment

### Publish your work in this journal

Neuropsychiatric Disease and Treatment is an international, peer-reviewed journal of clinical therapeutics and pharmacology focusing on concise rapid reporting of clinical or pre-clinical studies on a range of neuropsychiatric and neurological disorders. This journal is indexed on PubMed Central, the 'PsycINFO' database and CAS.

Submit your manuscript here: <http://www.dovepress.com/neuropsychiatric-disease-and-treatment-journal>

### Dovepress

The manuscript management system is completely online and includes a very quick and fair peer-review system, which is all easy to use. Visit <http://www.dovepress.com/testimonials.php> to read real quotes from published authors.