

This article is licensed under the Creative Commons Attribution-NonCommercial 4.0 International License (CC BY-NC) (<http://www.karger.com/Services/OpenAccessLicense>). Usage and distribution for commercial purposes requires written permission.

Case Report

Lessons Learned from Implantation of Morcher 50D and 96S Artificial Iris Diaphragms

Shawn R. Lin · Kevin M. Miller

Stein Eye Institute, David Geffen School of Medicine, University of California, Los Angeles, CA, USA

Keywords

Artificial iris · Aniridia · Iris defects

Abstract

Purpose: To discuss problems associated with the implantation of two Morcher iris diaphragm models. **Methods:** We describe the history, intraoperative complications, and postoperative complications of 5 patients with specific Morcher iris implants. **Results:** We implanted Morcher 50D devices in 1 patient and Morcher 96S devices in 4 patients. Complications included postoperative rotation, device mis-sizing, difficult intraoperative rotation, zonular dehiscence, and intraoperative hemorrhage. **Conclusion:** Artificial iris implantation has a steep learning curve. With widespread availability on the horizon in the United States, the sharing of surgical experiences is key to achieving the best outcomes for patients.

© 2017 The Author(s)
Published by S. Karger AG, Basel

Introduction

Patients with iris defects often report photophobia, impaired contrast sensitivity, and decreased visual acuity. Today, artificial iris implants give surgeons an assortment of tools to address these defects [1–6]. However, the learning curve for implant placement is steep. Often, positive experiences with these devices are published without thorough discussion of the surgical learning curve and without discussion of device flaws. We seek to share our experiences with two specific implants to enrich the collective literature and make it easier for surgeons to begin implanting aniridia devices (Fig. 1).

This discussion is especially timely, as both the Morcher and HumanOptics devices are under FDA study in the United States. With approval of these devices, we would expect more surgeons to attempt these implants and an increase in the total number of surgeries. The second author is an investigator in both clinical device trials and has extensive experience with artificial iris implantation [7–10].

In this case series, we share our early experiences with the Morcher 50D and 96S artificial iris diaphragms (Fig. 2). Although these particular models have been subsequently updated by Morcher, lessons detailed herein are broadly applicable. These full experiences have never before been published, and each case is selected to highlight an important learning point for this and future generations of artificial iris implants (Table 1, Table 2).

Case Reports

Study Patient 1: Postoperative Rotation (Morcher 50D × 2)

Patient 1 was a 59-year-old male at the time of Morcher 50D implantation in the left eye. He was the first patient enrolled in the Morcher trial, and he had an extensive family history of congenital aniridia with 88 members affected over 6 generations. The patient underwent successful left eye cataract extraction and placement of 2 Morcher 50D devices and an SN60AT lens in the capsular bag. A significant amount of time was spent aligning the paddles of the 2 50D devices intraoperatively, with good alignment and no slits noted at the end of the procedure. However, on postoperative day 1, one ring had rotated such that the resulting overlap covered only 60% of the iris defect. The patient was taken back to the operating room 1 week later to rotate the rings into the correct orientation. This second procedure took 10 min and was performed through the original incision.

Experience Summary

Fifteen minutes were spent after implantation during the initial surgery aligning the occlusive elements of the 2 Morcher 50D diaphragms to ensure complete coverage. Unfortunately, the diaphragms had rotated by postoperative day 1, and the patient required a reoperation at postoperative week 1 to eliminate the slits. This prompted one author (K.M.M.) to work with Morcher GmbH to create the 50F, an artificial iris implant with wider paddles, to increase the margin for error in surgical implantation and postoperative alignment.

Study Patient 2: Sulcus Mis-Sizing (Morcher 96S × 2)

Patient 2 was a 77-year-old man who suffered blunt iris trauma from a tree branch. Five years later, he developed a traumatic cataract and cataract extraction was performed with placement of a Staar AA4203 lens in the capsular bag. A 2 device 96S operation was planned, as the patient's symptoms were unresolved with an opaque-ring contact lens. During placement of the first Morcher 96S ring, zonular weakness was suspected, and several careful reattempts were necessary to safely place the device in the sulcus. The second Morcher 96S ring was placed uneventfully, though uncovered slits at 2 and 8 o'clock remained. On postoperative day 1, the patient was noted to have an intraocular pressure (IOP) of 49 mm Hg. This was thought to be secondary to retention of viscoelastic material, and IOP was subsequently controlled with pressure-lowering drops.

Experience Summary

The desired surgical outcome in this patient was to reduce photophobia by decreasing the size of the pupillary aperture. However, placement of 2 96S implants in the sulcus 180 degrees away from one another was insufficient to fully cover the circumferential iris defect. The problem here was the sizing of the sulcus implant. Given that the sulcus diameter was larger than the outside diameter of the devices, the devices sat too far away from one another to form a circular pupil. Design changes targeting a larger implant outer diameter would have pushed the devices closer together, resulting in the desired pupillary aperture.

Study Patient 3: Difficulty with Rotation (Morcher 96S)

Patient 3 was a 68-year-old man with surgical iris trauma. He was initially myopic after implantation of an Alcon MA30BA lens, leading to anisometropia. This first lens was exchanged for a Staar AQ2010V sulcus lens. Although this corrected his myopia, the 2 operations resulted in 4 clock hours of superior iris atrophy. A single Morcher 96S implant was placed in the sulcus, oriented with the paddle covering the superior iris region. Intraoperatively, the 96S was noted to be very difficult to rotate once it was placed.

Experience Summary

A fine balance exists between movement during implantation and movement postoperatively. The 96S device design does not provide for an anchor point from which to generate rotational torque after implantation. This problem, in addition to ring convexities on the outer edge, likely contributed to difficulty with rotation after placement.

Study Patient 4: IOL Decentration with Recurrent Hemorrhage (Morcher 96S)

Patient 4 was an 80-year-old man with surgical iris trauma. He underwent cataract surgery with placement of a Staar AQ5010V lens. A surgical iridectomy was inadvertently created, involving 2 clock hours of the superior iris. In addition, the patient had a postoperative refraction of $-3.00 +1.00 \times 180$. Intraoperatively, a Staar AQ5010V piggyback lens was placed to correct the myopia, with a Morcher 96S placed in the sulcus to cover the iris defect. The postoperative course was initially uneventful, with good glare reduction and an improvement of corrected distance visual acuity. However, the patient began to experience diplopia, and zonular weakness was soon noted, leading to displacement of both the piggyback and primary intraocular lenses (IOLs). Both IOLs were eventually explanted by the

study monitor, the iris defect was closed with Prolene sutures, and an iris-fixated IOL was placed. Unfortunately, the patient continued to experience recurrent episodes of hyphema, despite the use of a Nd:YAG laser to cauterize the iris and lyse vitreous incarcerated in the superior cataract wound.

Experience Summary

In this case, the original IOL and piggyback lens were placed into an eye with baseline pseudoexfoliation. Difficulty with rotation of the 96S sulcus implant, as described previously, in the setting of baseline zonular weakness likely contributed to zonular dehiscence and IOL decentration.

Study Patient 9: Intraoperative hemorrhage (96S)

Patient 9 was a 76-year-old female with a history of surgical iris trauma. She presented with a large superior iris defect secondary to cataract surgery. A Morcher 96S device was placed in the sulcus, but manipulation of the iris during the procedure resulted in a self-limited iris hemorrhage. The Morcher 96S could not be placed behind the iris remnants, and the implant partially overrode the superior iris in its final position.

Experience Summary

The black PMMA material is useful for creating functional improvement. However, there are often cases when insufficient iris tissue remains to hold a 96S device in place. In this case, an intraoperative hemorrhage resulted from attempts to place the Morcher device behind the atrophic superior iris remnant. The cosmetic appearance of the eye worsened after placement of the 96S, although the glare disability of the eye was improved.

Discussion

These procedures were chosen to highlight important lessons from the senior author's experience with 2 specific Morcher devices, the 50D and 96S. Given the wide variety of aniridia implants available from Morcher and other manufacturers, it is important to chronicle surgical experiences with these devices. We would advise against the use of the 50D and 96S devices, and these devices are no longer available on a compassionate use basis in the United States. The author (K.M.M.) is conducting a self-funded clinical trial to increase availability of both Morcher and HumanOptics devices, and it is expected that FDA approvals will drive an increase in the number of artificial iris devices implanted. This case series highlights our early experiences in artificial iris implantation. We hope our experiences will add to the collective literature on artificial iris implantation and reduce the learning curve and complication rate for other surgeons working with these devices.

Statement of Ethics

The authors have no ethical conflicts to disclose. The Morcher artificial iris study was approved by the Institutional Review Board at the UCLA School of Medicine.

Disclosure Statement

No conflicting relationship exists for either author.

References

- 1 Srinivasan S, Yuen C, Watts M, Prasad S: Endocapsular iris reconstruction implants for acquired iris defects: a clinical study. *Eye (Lond)* 2007;21:1109–1113.
- 2 Karatza EC, Burk SE, Snyder ME, Osher RH: Outcomes of prosthetic iris implantation in patients with albinism. *J Cataract Refract Surg* 2007;33:1763–1769.
- 3 Weissbart SB, Ayres BD: Management of aniridia and iris defects: an update on iris prosthesis options. *Curr Opin Ophthalmol* 2016;27:244–249.
- 4 Srinivasan S, Ting DSJ, Snyder ME, Prasad S: Prosthetic iris devices. *Can J Ophthalmol* 2014;49:6–17.
- 5 Aslam SA, Wong SC, Ficker LA, MacLaren RE: Implantation of the black diaphragm intraocular lens in congenital and traumatic aniridia. *Ophthalmology* 2008;115:1705–1712.
- 6 Date RC, Olson MD, Shah M, Masket S, Miller KM: Outcomes of a modified capsular tension ring with a single black occluder paddle for eyes with congenital and acquired iris defects: report 2. *J Cart Refract Surg* 2015;41:1934–1944.
- 7 Chung MY, Miller KM, Weissman BA: Morcher iris reconstruction lens and rigid contact lens for traumatic aniridia. *Eye Contact Lens* 2009;35:108–110.
- 8 Miller KM, Nicoli CM, Olson MD, Shah M, Masket S: Outcomes of implantation of modified capsule tension rings with multiple black occluder paddles for eyes with congenital and acquired iris defects: report 3. *J Cart Refract Surg* 2016;42:870–878.
- 9 Olson MD, Masket S, Miller KM: Interim results of a compassionate-use clinical trial of Morcher iris diaphragm implantation: report 1. *J Cataract Refract Surg* 2008;34:1674–1680.
- 10 Price MO, Price FW, Chang DF, Kelley K, Olson MD, Miller KM: Ophtec Iris reconstruction lens United States clinical trial phase I. *Ophthalmology* 2004;111:1847–1852.

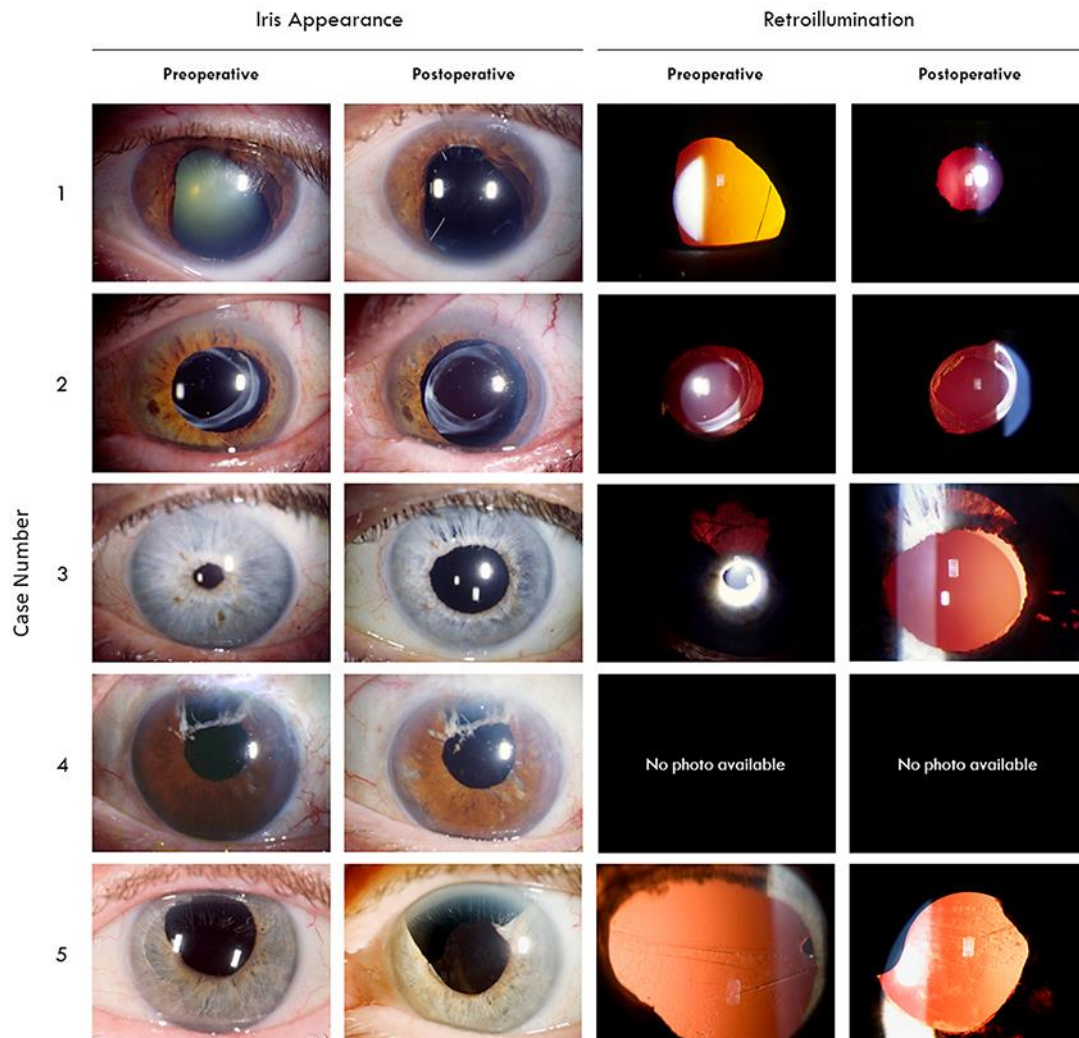


Fig. 1. Preoperative and postoperative appearances of the 5 eyes in this case series. Subject 1 – Morcher 50D (2); subject 2 – 96S (2); subjects 3, 4, and 9 – 96S (1). Eye size, color balance, and lighting were standardized whenever possible.

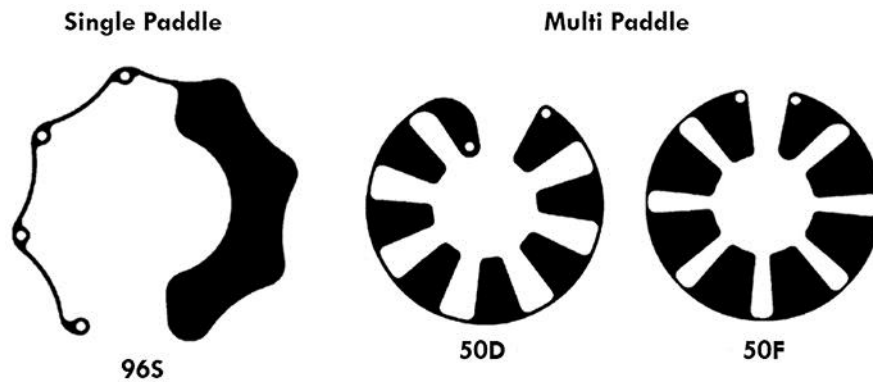


Fig. 2. Single and multi-paddle variants of the Morcher artificial iris diaphragms. Note that the 50D paddle size was enlarged to produce the 50F.

Table 1. Demographic and descriptive information

| Subject | Morcher device | Age, years | Race/ethnicity | Sex/eye | Etiology of iris defects | Lens status | Ocular comorbidities |
|---------|----------------|------------|----------------|---------|--------------------------|--------------------------------|--------------------------------|
| 1 | 50D×2 | 59 | White | M/LE | Congenital aniridia | SA60AT | Amblyopia |
| 2 | 96S×2 | 77 | White | M/LE | Blunt trauma | Staar AA4203 | Orbital proptosis, esotropia |
| 3 | 96S | 68 | White | M/LE | Surgical trauma | Staar AQ2010V | None |
| 4 | 96S | 80 | White | M/LE | Surgical trauma | Staar AQ5010V sulcus piggyback | Pseudoexfoliation |
| 9 | 96S | 76 | White | F/LE | Surgical trauma | Unknown PCIOL | Chronic angle closure glaucoma |

Table 2. Visual outcomes and complications

| Subject | CDVA | | Glare CDVA | | Daytime glare | | Nighttime glare | | Comments | |
|---------|----------|----------|------------|-------|---------------|------|-----------------|------|---------------------------------|--|
| | pre | post | pre | post | pre | post | pre | post | device problem | complication |
| 1 | 20/70 -2 | 20/60 +2 | 20/125 | 20/60 | 10 | 8 | 7 | 6 | Device alignment | Device rotation |
| 2 | 20/25 +3 | 20/25 -2 | 20/50 | 20/25 | 10 | 10 | 0 | 9 | Incomplete coverage | POD1 IOP 49 mm Hg, microhyphema |
| 3 | 20/20 | 20/15 -2 | 20/80 | 20/25 | 5 | 8 | 1 | 2 | Difficult to rotate | None |
| 4 | 20/20 +2 | 20/20 +2 | 20/40 | 20/30 | 8 | 6 | 10 | 10 | Difficult to rotate | IOL/piggyback decentration, recurrent hemorrhage |
| 9 | 20/25 +2 | 20/20 -2 | 20/50 | 20/30 | 10 | 10 | 10 | 7 | Difficult to rotate, discomfort | None |

CDVA, corrected distance visual acuity.