

# Cancer of the esophagus – Endoscopic ultrasound: Selection for cure

Giancarlo Caletti MD, Paolo Bocus MD, Pietro Fusaroli MD, Thomas Togliani MD,  
Gregary Marhefka MD, Enrico Roda MD

G Caletti, P Bocus, P Fusaroli, T Togliani, G Marhefka, E Roda. **Cancer of the esophagus – Endoscopic ultrasound: Selection for cure.** *Can J Gastroenterol* 1998;12(5):341-346. Several treatment options are available to treat esophageal cancer. Ideally, treatment should be individualized, based on the projected treatment outcome for that individual. Accurate staging of the extent of the disease at the time of diagnosis offers the most rational attempt at stratifying patients into categories that can be used to affect treatment choices. Endoscopic ultrasonography (EUS) is the most accurate nonoperative technique for determining the depth of tumour infiltration and thus is accurate in predicting which patients will be able to undergo complete resection. EUS is also being used for tumour staging in order to guide treatment decisions in patients with esophageal cancer.

**Key Words:** *Cancer stage, Endoscopic ultrasonography, Esophageal cancer*

## Cancer de l'œsophage – échographie endoscopique : sélection en vue du traitement

**RÉSUMÉ :** Plusieurs options thérapeutiques sont offertes pour le traitement du cancer de l'œsophage. Idéalement, le traitement doit être individualisé selon l'issue thérapeutique escomptée pour un individu donné. La stadification permet de préciser l'étendue de la maladie au moment du diagnostic et offre la base la plus rationnelle de stratification des patients en diverses catégories qui peuvent ensuite orienter le choix des traitements. L'échographie endoscopique est, à l'heure actuelle, la technique non chirurgicale la plus précise pour déterminer la profondeur de l'infiltration de la tumeur et elle permet donc de prédire avec précision quels patients pourront subir une résection totale. L'échographie endoscopique sert également à la stadification des tumeurs pour orienter les décisions thérapeutiques chez les patients atteints d'un cancer de l'œsophage.

Several treatment options are available to treat esophageal cancer. Ideally, the choice of treatment for an individual patient should be based on the projected outcome of the treatment for that individual. Accurate staging of the extent of the disease at the time of diagnosis offers the most rational attempt at stratifying patients into categories that can be used to affect treatment choices.

In esophageal cancer the results of preoperative staging are relevant because its management comprises not only curative surgery, but also endoscopic mucosectomy, photodynamic therapy, laser photodestruction, primary palliative procedures and particularly neoadjuvant radiochemotherapy (1-3).

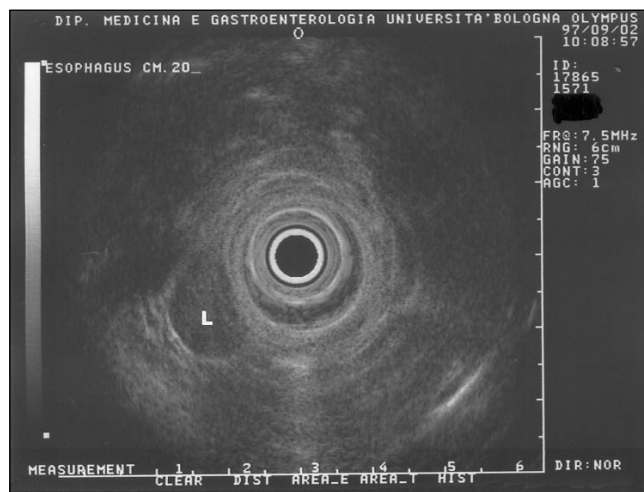
The most important question in making therapeutic decisions in these patients is whether complete tumour removal (RO resection) can be expected. The answer is determined by the T stage and the relation of the tumour to surrounding structures. Adequate lymphadenectomy is essential for accurate postoperative staging and may influence the prognosis.

Computed tomography (CT) should be the first imaging test for the patient with esophageal cancer. If distant metastases are found, local and regional staging is not relevant to treatment planning, and all therapeutic efforts should be directed towards palliation of symptoms.

On the other hand, a large number of papers support the high accuracy (over 80%) of endoscopic ultrasonography

Department of Medicine and Gastroenterology, University of Bologna, Bologna, Italy

Correspondence: Professor Giancarlo Caletti, Department of Medicine and Gastroenterology, University of Bologna, Policlinico S Orsola, Via Massarenti 9, 40138 Bologna, Italy. Telephone 39-51-307-224, fax 39-51-305-430, e-mail [caletti@med.unibo.it](mailto:caletti@med.unibo.it)



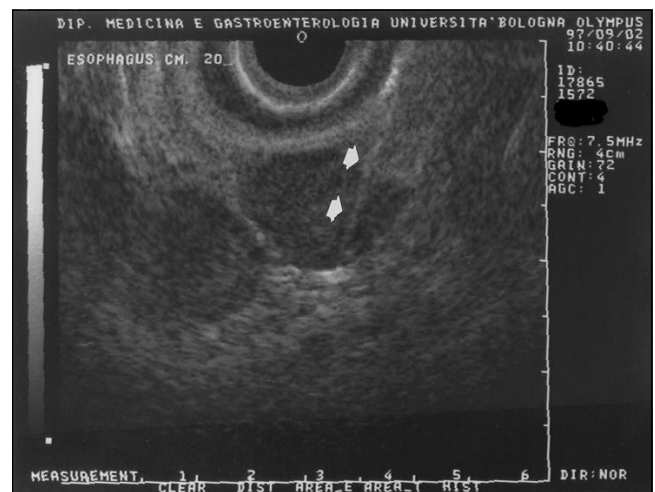**Figure 1)** Endoscopic ultrasonography (EUS) radial scanning at 7.5 MHz of a large lymph node displayed outside the esophageal wall in a patient with esophageal cancer. Olympus GF-UM 20, 7.5/12 MHz

(EUS) in the preoperative locoregional staging of esophageal cancer and its superiority over other procedures such as CT or magnetic resonance imaging (4-6). However, these techniques should be considered complementary rather than competitive because EUS is superior in staging primary tumour and mediastinal lymph node metastases, while CT and magnetic resonance imaging are superior in diagnosing infiltration of other mediastinal organs and distant metastases.

EUS is the most accurate nonoperative technique for determining the depth of tumour infiltration and thus is accurate in predicting which patients will be able to undergo complete resection (7). EUS is also being used for tumour staging in order to guide treatment decisions in patients with esophageal cancer (8). A recent review of studies from 21 centres reported that EUS had an average accuracy of 84% (1154 patients) in determining T stage and of 77% (1035 patients) in determining N stage (9), but few reports dealt with the influence of an accurate staging on the choice of treatment and patient outcome.

#### ADVANCED ESOPHAGEAL CANCER

In a multicentre retrospective cohort study, Chak et al (10) demonstrated that EUS was significantly more accurate than CT scanning in identifying tumour invasion (87.5% versus 43.8%, respectively,  $P=0.0002$ ). In contrast to CT, EUS accurately defined a subgroup of patients with invasive esophageal carcinoma who had a limited survival. The survival of patients with surgically treated esophageal EUS T4 carcinomas was not significantly different from that of those treated by nonsurgical palliation; 59.5% of the surgical group and 64.9% of the nonsurgical group had died at follow-up ( $P=0.65$ ). In addition, the median survival times of the surgical group and the nonsurgical group were similar (5.2 and 7.0 months, respectively,  $P=0.50$ ). Survival curves for the two groups were almost overlapping (log rank test,  $P=0.80$ ). Moreover, even after adjusting for age, histological diagno-

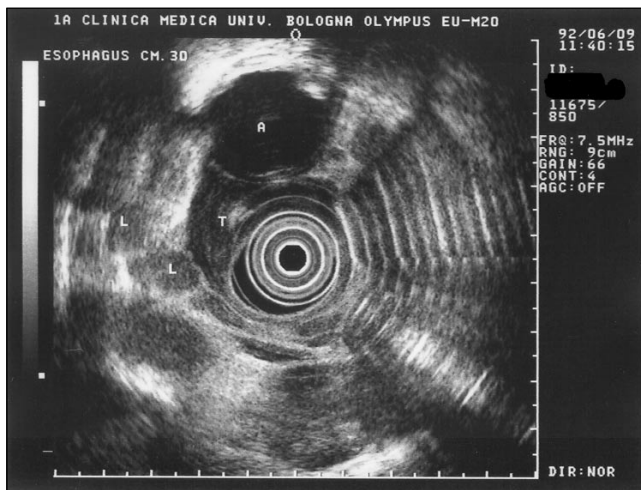

**Figure 2)** Endoscopic ultrasonography (EUS) mechanical sector scanning of the esophageal lymph node displayed in Figure 1. Fine needle biopsy is attempted. The needle is clearly visualized to the right of the probe as a white line (arrows). Olympus GF-UM 30P, 7.5 MHz

sis, tumour location and regional lymph node status, surgical treatment did not significantly influence survival ( $P=0.24$ ).

Finally, Chak et al (10) concluded that EUS is the first nonoperative staging modality that can reliably identify a subset of patients with invasive esophageal carcinoma who have a very poor prognosis. These patients with advanced disease have an almost uniformly dismal outcome, irrespective of the primary treatment. Because surgery is associated with high costs, a mortality rate of 4% to 15% (11-13), a morbidity rate of 25% to 70% (11-14) and prolonged recovery, nonsurgical palliative therapy in patients who have regionally invasive disease identified by EUS should be considered.

A recent study by Hiele et al (15) found that the survival of patients with tumours of the esophagus or esophagogastric junction is strongly related to EUS tumour, node, metastasis (TNM) staging results and that tumour resectability is related to endosonographic findings. In fact, according to their experience, patients who were staged endosonographically as T2 had a median survival of 28 months, those staged as T3 19 months and those staged as T4 only eight months (the difference among the survival curves was statistically significant, log rank test,  $P=0.05$ ) (15). Patients in whom no pathological lymph nodes were detected had a median survival of more than 28 months, whereas patients in whom malignant lymph nodes were suspected had a median survival of only eight months. The influence of EUS N staging on survival was statistically significant (log rank test,  $P=0.02$ ) (15). Moreover, patients with celiac lymph nodes staged as negative had a median survival of 28 months, while patients with EUS-positive celiac lymph nodes had a median survival of only three months. Interestingly, in patients in whom the presence of celiac lymph nodes could not be assessed because of tumoural stenosis or when the results were equivocal, a median survival of eight months was noted (the difference among the three curves is statistically significant, log rank test,  $P=0.0027$ ) (15). Finally, if the tumoural steno-



**Figure 3)** Endoscopic ultrasonography (EUS) radial scanning at 7.5 MHz of a T4 esophageal cancer. A large hypoechoic mass (T) with complete destruction of normal esophageal wall stratification is seen invading the aorta (A). Enlarged lymph nodes are also visualized (L)

sis could be passed with the EUS scope, the median survival amounted to 20 months, whereas if the scope could not be brought beyond the stenosis, median survival was 10 months (the difference between the two groups was statistically significant, log rank test,  $P=0.02$ ) (15).

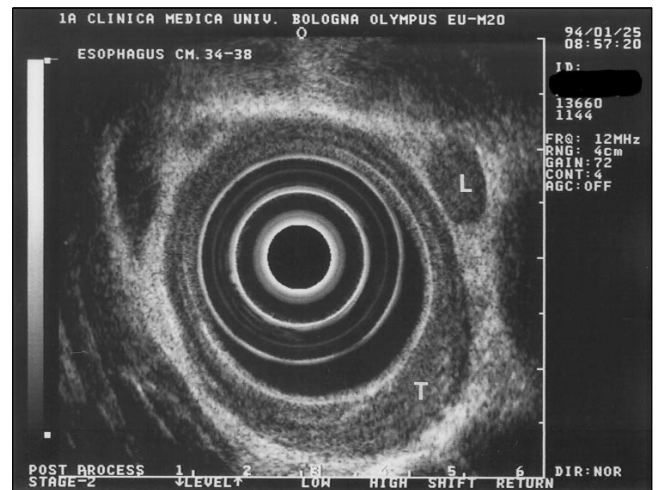
These EUS findings markedly influenced the surgery results because an RO resection was always possible in the 11 patients in whom no pathological regional lymph nodes were detected. If positive celiac axis nodes were detected, an RO resection was possible in only 10% of patients (15).

In light of these important results it is possible to draw some practical conclusions.

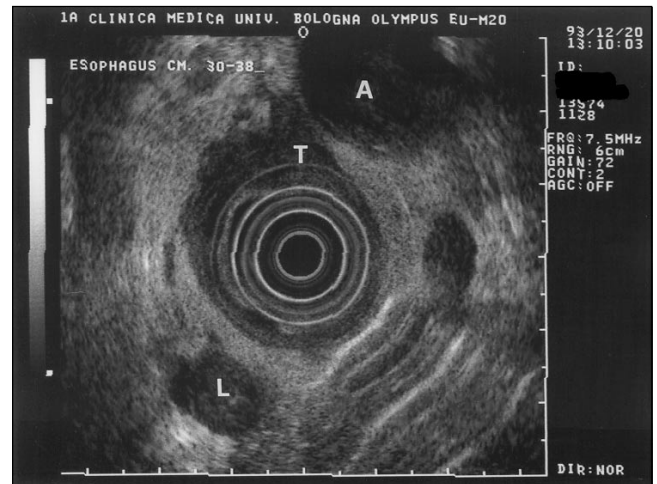
The greatest limitation of EUS in staging esophageal cancer was generally considered to be the inability to pass the EUS scope through the strictures. Because patients with impassable strictures are likely to have advanced disease (16-19), it seems useless in terms of therapeutic decisions to make any particular effort to achieve a complete EUS staging. Thus, dilation of a stenosis should no longer be attempted, nor should expensive dedicated tools be used (20).

There are several published series that document that EUS-guided, real-time fine needle aspiration (FNA) is possible, safe and highly sensitive in diagnosing malignant lesions (21). Whether FNA of mediastinal adenopathy is routinely indicated in the staging of esophageal carcinoma (Figures 1,2) is controversial. FNA is definitely indicated in obtaining biopsy specimens of enlarged celiac nodes in patients with squamous cell carcinoma of the esophagus, where a positive biopsy would dictate medical palliation rather than surgery for possible cure (22).

In an important editorial Kimmey (23) draws some fundamental conclusions about EUS in esophageal cancer. In patients with endosonographic stage T4 cancer (Figure 3), surgery can only offer palliation. Thus, the availability of good endoscopic treatment for the relief of symptoms makes surgery increasingly unnecessary for palliation.



**Figure 4)** Endoscopic ultrasonography (EUS) radial scanning at 12 MHz of a T2 N1 esophageal cancer (T). A large and well demarcated lymph node is displayed outside the esophageal wall (L)

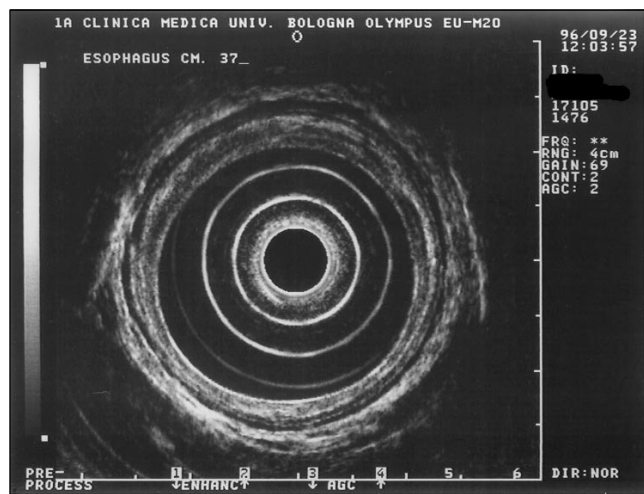


**Figure 5)** Endoscopic ultrasonography (EUS) radial scanning at 12 MHz of a T3 esophageal cancer. The tumour (T) is seen as a hypoechoic mass initially invading the adventitia. A Aorta; L Lymph node

However, the best treatment for patients with intermediate stage cancer (T2 and T3, N0 and N1) (Figures 4,5) is still controversial (23). Surgery with or without prior or subsequent chemotherapy and/or radiation are the most common treatment choices, although some would advocate chemoradiation without surgery (23). Future trials are needed, in which patients should always have endosonographic staging before enrolment, in order to compare patients with similar disease stages.

#### ASSESSMENT OF THE RESPONSE TO RADIOCHEMOTHERAPY

Neoadjuvant therapy given before surgery may reduce the incidence of micrometastases, increase resectability, control systemic disease and allow accurate assessment of the completeness of the pathological response (24). EUS recently



**Figure 6)** Endoscopic ultrasonography (EUS) radial scanning at 20 MHz frequency of a normal esophageal wall. Nine layers are displayed. Olympus GF-UM 20, 7.5/20 MHz

was used to assess the response to neoadjuvant therapy; it was found that complete restoration of the esophageal wall at EUS corresponded to disease-free histology in 78% of cases and corresponded in all cases to either a disease-free esophageal wall or microscopic tumour residues in the mucosa (25).

However, it is not yet clear whether these results can influence the treatment decisions in these patients and whether EUS should be indicated for monitoring patients after radiochemotherapy.

### POSTOPERATIVE RECURRENCE

Local recurrent (anastomotic) esophageal cancer is a major problem in the postoperative management of esophageal cancer patients. Diagnosis of locally recurrent tumour was problematic before the emergence of EUS as the diagnostic modality of choice for upper gastrointestinal tract lesions. Symptoms attributed to locally recurrent carcinoma often suggest extensive, unresectable recurrences or are difficult to distinguish from those observed after surgery because of scarring, fibrosis and inflammation leading to dysmotility disorders. The main problem in these patients is that frequently the recurrence is extramural – thus not detectable by endoscopy (26,27).

Catalano et al (28) demonstrated that the sensitivity of EUS in identifying recurrence of esophageal carcinoma was 100%, compared with 33% for endoscopic diagnosis, while its specificity was 96%. Because only one-third of the patients with recurrence in the asymptomatic group of 30 underwent a second surgical resection, those authors failed to demonstrate that early EUS surveillance leads to an improvement in survival.

Despite these optimistic diagnostic results (28), it is difficult to believe that a second surgical resection in patients with asymptomatic cancer recurrence would change their outcome.

### EARLY ESOPHAGEAL CANCER

When local treatment (local excision, photodynamic therapy, etc) or endoscopic dissection of the esophagus are considered, an important question is whether T1 carcinoma is confined to the mucosa or the submucosa. The accuracy in the differentiation between mucosal and submucosal carcinoma has not been fully evaluated because the TNM staging system does not distinguish mucosal carcinoma invading the lamina propria from submucosal carcinoma, instead classifying both as T1.

Intraepithelial cancer or carcinoma in situ is the earliest stage, followed by invasion through the epithelial basement membrane and then through the muscularis mucosae. Lymphatic invasion, almost never found in patients with intraepithelial cancer, increases up to 30% with submucosal invasion (T1-sm).

Yoshikane et al (29) reported that lymph node metastases or vessel permeation were uncommon with mucosal tumours, whereas in submucosal carcinoma, lymph node metastases were present in 71% of patients, and lymphatic or vascular permeation were present in 58% and 21% of patients, respectively. The same authors reported an accuracy rate of detecting depth invasion by EUS of 67% for mucosal lesions and of 79% for submucosal lesions. It was found that EUS could not detect microinvasion of the submucosa.

Even if there is a continuing accumulation of data to suggest that EUS adds considerably to the accuracy of esophageal cancer staging, EUS has unfortunately been less effective in detecting the earliest stages.

As previously reported, at EUS the normal esophageal wall is imaged as a five- or three-layer structure (30). In the five-layer structure, the first layer is hyperechoic and the second layer is hypoechoic, corresponding with the interface echo and the mucosa, respectively. The third layer is hyperechoic and represents the submucosa, the fourth is hypoechoic and represents the muscularis propria, and the fifth is hyperechoic and represents the adventitia. However, the first three layers often become indistinct and are imaged as one hyperechoic layer, so that the wall is observed as a three-layer structure.

The reason for the imaging instability of the normal esophageal wall is usually that the wall is too close to the transducer, thus not allowing for the best focus. Inflating the balloon with water pushes the wall further from the transducer, but may simultaneously compress the wall, causing poor definition of the first three layers so that a three-layer wall still results (30).

Considering these circumstances, it is difficult always to detect the flat type of mucosal carcinoma. On the basis of the EUS image of a normal esophageal wall, a mucosal carcinoma is diagnosed when the third hyperechoic layer under the lesion is intact, whereas a submucosal carcinoma is diagnosed when the underlying third hyperechoic layer shows any narrowing with an intact fourth layer (29).

Sometimes a submucosal carcinoma does not reveal any narrowing of the third layer and is erroneously diagnosed as a

mucosal carcinoma. However, microinvasion to the submucosa not identified by EUS can be present (29).

Thus, it is our opinion that with the available frequencies (7.5 to 12 MHz), a real mucosal carcinoma can be safely staged only when, first, a five-layer wall is displayed and, second, the EUS shows no abnormal findings of the first and second layer. In fact, with the commercially available frequencies mucosal carcinoma is undetectable. When EUS is positive, there is a great possibility that the carcinoma has already invaded the submucosa.

To overcome this problem, Murata et al (31) employed a small endosonographic probe of 2.6 mm at 15 or 20 MHz in 54 patients after filling the esophagus with water, which was injected through the auxiliary channel of the endoscope. The normal esophageal wall was depicted as having nine layers with alternating echogenicity (Figure 6). The mucosa consists of four layers: the first and second layers (m1 and m2) represent the epithelium, the third (m3) represents the lamina propria and the fourth (m4) represents the muscularis mucosae. The submucosa, the fifth layer, is hyperechoic. The muscularis propria comprises three layers: the sixth layer (p1) is the circular muscle, the seventh layer (p2) is an interface of connective tissue and the eighth layer (p3) is the longitudinal muscle. The ninth layer is hyperechoic and represents the adventitia.

The image of an epithelial cancer was that of a thickened hypoechoic mass within the m3 layer, while the underlying m4 was preserved. Cancer invading the lamina propria (T1-1pm) appeared as a hypoechoic mass protruding into the m3 layer; alternatively, the m3 layer may have been completely occupied by a hypoechoic mass. The underlying m4 layer was intact. The overall accuracy of the probe used by Murata et al (31) was 75%; better accuracy was achieved in predicting cancer limited by the lamina propria, and a distinction between cancer limited to the mucosa and that extending to the submucosal layer was successfully determined in 46 of 49 cases (94%). Neoplastic invasion was overestimated by high frequency EUS small probes in five cases of Tis lesions (cancer limited to the mucosa) (three cases of T1-1pm lesions) and in four cases of T1-sm lesions. The only disadvantage of this technique was its relatively limited level of tissue penetration; in fact, entire margins of large tumours were seldom clearly delineated.

Hasegawa and colleagues (32) compared the usefulness of a 15 MHz, 2.4 mm diameter probe with that of conventional EUS in assessing the depth of invasion and perigastrointestinal lymph node involvement in 22 cases of superficial esophageal cancer. The researchers filled the stomach and the esophagus with water after attaching a balloon just proximal to the tip of the endoscope to prevent reflux of injected water, thus obtaining a nine-layer image of the esophageal wall. The accuracy rates for the ultrasound probe in detecting the depth of invasion were 86% (six of seven) for mucosal carcinoma and 94% (17 of 18) for submucosal carcinoma (total 92%). Using EUS, the accuracy rate was 71% (five of seven) for mucosal carcinoma and 78% (14 of 18) for submucosal carcinoma (total 76%). In the evaluation of lymph node me-

tastasis, the overall accuracy was 56% with the ultrasound probe (sensitivity 25% and specificity 80%) and 67% with EUS (sensitivity 50% and specificity 80%).

Using EUS with the water-filled esophagus technique and a 20 MHz, 2.8 mm probe Yanai et al (33) found an overall accuracy of staging of 64.7% in 16 patients. In all six errors, mucosal cancers were overstaged as submucosal invasion. The diagnostic accuracy was 80% when the muscularis mucosae was visualized. Unfortunately, this happened in only five lesions (29.4%).

When considering all these results, it is possible to conclude that high frequency miniprobes are only slightly better than dedicated EUS instruments. Probes require a complicated and theoretically unsafe technique of filling the esophagus with a large amount of water. The visualization of the muscularis mucosae, which is the main target in this disease, is difficult to obtain and not always achieved. Accurate staging of periesophageal and mediastinal lymph nodes is better made with dedicated EUS instruments; thus, two examinations (one with the miniprobe for T stage and a second one with a dedicated instrument for N stage) are always required. The most positive result of this technique is that failures were always due to overstaging – understaging never happened.

## CONCLUSIONS

The high cost of EUS systems and increasing societal pressure for medical cost containment strengthen the need to evaluate critically the clinical usefulness of this new imaging technology.

In an important study Nickl et al (34) demonstrated that EUS is a clinically relevant technology and that EUS findings can have a major impact on patient management decisions. In their series, EUS findings changed the clinical management in roughly three-quarters of patients. In particular, they found that when dealing with staging a known cancer of the esophagus, EUS findings resulted in a major management change in 24% of 43 patients. Quite often surgery was avoided in patients who would not have benefitted because EUS demonstrated known neoplasms to be more advanced than originally had been suspected.

Similar results were obtained by Jafri et al (35) in 63 patients. They demonstrated that EUS led to a less invasive and less costly course of therapy in an overwhelming majority of patients, resulting in a change of management in 67%. In the few patients in whom EUS resulted in more invasive therapy, it was because either a new diagnosis was suggested or diagnostic certainty was enhanced. In the three of the four cases where EUS led to more invasive therapy, this may have been avoided if a linear array endosonographic probe was available for FNA. Therefore, in esophageal cancer also, it is possible to conclude that endosonography with its capability of FNA can be expected to have additional benefits in patient management.

**Recommendations:** EUS can be used for the preoperative staging and assessment of resectability in operable patients without distant metastases, especially when stage-dependent

treatment protocols are applied. The role of EUS in the detection of anastomotic recurrence, in restaging after radio-chemotherapy and in FNA is still under evaluation (36).

## REFERENCES

- Holscher AH, Dittler HJ, Siewert JR. Staging of squamous esophageal cancer: accuracy and value. *World J Surg* 1994;18:312-20.
- Peters JH, Hoelt SF, Heimbucher J, et al. Selection of patients for curative or palliative resection of esophageal cancer based on preoperative endoscopic ultrasonography. *Arch Surg* 1994;129:534-9.
- Holscher AH, Siewert JR, Fink U. Staging concepts for gastrointestinal malignancies: the importance of preoperative locoregional T and N staging. *Gastrointest Endosc Clin North Am* 1995;5:534-9.
- Rösch T. Endoscopic ultrasonography. *Endoscopy* 1994;26:148-68.
- Koch J, Halvorsen RA Jr. Staging esophageal cancer: computed tomography, magnetic resonance imaging and endoscopic ultrasound. *Semin Roentgenol* 1994;29:364-72.
- Van Dam J. Endosonography of the esophagus. *Gastrointest Endosc Clin North Am* 1994;4:803-26.
- Rösch T, Lorenz R, Zenker K, et al. Local staging and assessment of resectability in carcinoma of the esophagus, stomach, and duodenum by endoscopic ultrasonography. *Gastrointest Endosc* 1992;38:460-7.
- Souquet JC, Napoleon B, Pujol B, Valette PJ, Chollet R, Lambert R. Endosonography-guided treatment of esophageal carcinoma. *Endoscopy* 1992;24:324-8.
- Rösch T. Endosonographic staging of esophageal cancer: a review of literature results. *Gastrointest Endosc Clin North Am* 1995;5:537-47.
- Chak A, Canto M, Gerdes H, et al. Prognosis of esophageal cancers preoperatively staged to be locally invasive (T4) by endoscopic ultrasound (EUS): a multicenter retrospective cohort study. *Gastrointest Endosc* 1995;42:501-6.
- Ellis HF, Gibb SP, Watkins E. Esophagogastrectomy: a safe, widely applicable, and expeditious form of palliation for patients with carcinoma of the esophagus and cardia. *Ann Surg* 1983;198:531-9.
- Gertsch P, Vauthey JN, Lustemberger AA, Friedlander-Klar H. Long-term results of transhiatal esophagectomy for esophageal carcinoma. *Cancer* 1993;72:2312-9.
- Muller JM, Erasmı H, Stelzner M, Zieren U, Pichlmaier H. Surgical therapy of esophageal carcinoma. *Br J Surg* 1990;77:845-57.
- Galandiuk S, Hermann RE, Gassman JJ, Cosgrove DM. Cancer of the esophagus: The Cleveland Clinic experience. *Ann Surg* 1986;203:101-8.
- Hiele M, De Leyn P, Schurmans P, et al. Relation between endoscopic ultrasound and outcome of patients with tumors of the esophagus or esophagogastric junction. *Gastrointest Endosc* 1997;45:381-6.
- Van Dam J, Rice TW, Catalano MF, et al. High-grade malignant stricture is predictive of esophageal tumor stage. *Cancer* 1993;71:2910-7.
- Hordijk ML, Zander H, van Blanckestein M, et al. Influence of tumor stenosis on the accuracy of endosonography. *Endoscopy* 1993;25:171-5.
- Catalano MF, Van Dam J, Sivak MV, et al. Malignant esophageal strictures: staging accuracy of endoscopic ultrasonography. *Gastrointest Endosc* 1995;41:535-9.
- Kallimanis GE, Gupta PK, Al-Kawas FH, et al. Endoscopic ultrasound (EUS) for staging esophageal cancer, with or without dilation, is clinically important and safe. *Gastrointest Endosc* 1995;41:540-6.
- Binmoeller KF, Seifert H, Seitz U, et al. Ultrasonic esophagoscope for TNM staging of highly stenosing esophageal carcinoma. *Gastrointest Endosc* 1995;41:547-52.
- Gress FG, Hawes RH, Savides TJ, Ikenberry SO, Lehman GA. Endoscopic ultrasound-guided fine-needle aspiration biopsy using linear array and radial scanning endosonography. *Gastrointest Endosc* 1997;45:243-50.
- Stotland BR, Kochman ML. Diagnostic and therapeutic endosonography: endoscopic ultrasound-guided fine-needle aspiration in clinical practice. *Gastrointest Endosc* 1997;45:329-31.
- Kimmey MB. Endoscopic ultrasonography for esophageal cancer staging: impact on patient outcome. *Gastrointest Endosc* 1995;42:593-94.
- Wilke H, Fink U. Multimodal therapy for adenocarcinoma of the esophagus and esophagogastric junction. *N Engl J Med* 1996;335:509-10.
- Giovannini M, Seitz JF, Thomas P, et al. Endoscopic ultrasonography for assessment of the response to combined radiation therapy and chemotherapy in patients with esophageal cancer. *Endoscopy* 1997;29:4-9.
- Dancygier H, Classen M. Endoscopic ultrasonography in esophageal disease. *Gastrointest Endosc* 1989;35:220-5.
- Kasai M, Mori S, Watanabe T. Follow-up results after resection of thoracic esophageal carcinoma. *World J Surg* 1978;2:543-50.
- Catalano MF, Sivak MV, Rice TW, Van Dam J. Postoperative screening for anastomotic recurrence of esophageal carcinoma by endoscopic ultrasonography. *Gastrointest Endosc* 1995;42:540-4.
- Yoshikane H, Tsukamoto Y, Niwa Y, et al. Superficial esophageal carcinoma: evaluation by endoscopic ultrasonography. *Am J Gastroenterol* 1994;89:702-7.
- Caletti G, Bolondi L, Barbara L. Instrumentation and scanning technique. In: Kawai K, ed. *Endoscopic Ultrasonography in Gastroenterology*. Tokyo: Igaku Shoin, 1988:1-17.
- Murata Y, Suzuki S, Ohta M, et al. Small ultrasonic probes for determination of the depth of superficial esophageal cancer. *Gastrointest Endosc* 1996;44:23-8.
- Hasegawa N, Niwa Y, Arisawa T, Hase S, Goto H, Hayakawa T. Preoperative staging of superficial esophageal carcinoma: comparison of an ultrasound probe and standard endoscopic ultrasonography. *Gastrointest Endosc* 1996;44:388-93.
- Yanai H, Yoshida T, Harada T, et al. Endoscopic ultrasonography of superficial esophageal cancers using a thin ultrasound probe system equipped with switchable radial and linear scanning modes. *Gastrointest Endosc* 1996;44:578-82.
- Nickl N, Bhutani M, Catalano M, et al. Clinical implications of endoscopic ultrasound: the American Endosonography Club study. *Gastrointest Endosc* 1996;44:371-7.
- Jafri I, Saltzman JR, Colby JM, Krims PE. Evaluation of the clinical impact of endoscopic ultrasonography in gastrointestinal disease. *Gastrointest Endosc* 1996;44:367-70.
- Caletti G, Deviere J, Fockens P, et al. Guidelines of the European Society of Gastrointestinal Endoscopy (ESGE) Endoscopic Ultrasonography. Part I: Technique and upper gastrointestinal tract. *Endoscopy* 1996;28:474-9.





**Hindawi**  
Submit your manuscripts at  
<http://www.hindawi.com>

