



Angiotensin-converting enzyme inhibitors in patients with vascular disease

Bertram Pitt*

University of Michigan School of Medicine, 1500 E. Medical Center Drive, Cardiovascular Center, Ann Arbor, MI 48109, USA

Online publish-ahead-of-print 21 April 2009

This editorial refers to ‘The consistency of the treatment effect of an ACE inhibitor-based treatment regimen in patients with vascular disease or high risk of vascular disease: a combined analysis of individual data of ADVANCE, EUROPA, and PROGRESS trials’[†], by J.J. Brugts et al., on page 1385

Angiotensin-converting enzyme inhibitors (ACEIs) have a beneficial effect on oxidative stress, endothelial function, vascular remodelling, and the progression of atherosclerosis in animal experiments independent of their effect on reducing blood pressure. ACEIs have also been shown to decrease cardiovascular mortality and morbidity in patients with vascular disease.^{1,2} While these results have been adopted into guidelines, there have been doubts as to whether or not these benefits were due to a reduction in blood pressure and therefore possibly any anti-hypertensive strategy might be equally effective or whether they have an effect independent of blood pressure lowering. The answer to this question has important implications. For example, the COURAGE trial³ suggested that optimum medical therapy, including an ACEI, was as effective in preventing cardiovascular events in patients with mild to moderate coronary artery disease as percutaneous coronary angioplasty. The use of ACEIs in patients with coronary artery disease without other clinical indications for their use such as hypertension and/or diabetes mellitus, however, remains suboptimal.

Brugts et al.⁴ have analysed the effect of an ACEI-based regimen using individual patient data from across a wide spectrum of vascular diseases from the ADVANCE, EUROPA, and PROGRESS trials^{2,5,6} which used a perindopril-based regimen that could include the diuretic indapamide. An analysis from these trials involving >29 000 patients showed that the perindopril-based regimen was associated with a significant reduction in all-cause mortality, a reduction in cardiovascular mortality, as well as a reduction in non-fatal myocardial infarction, stroke, and heart failure. Of importance was the finding that these results were consistent in subgroups with different clinical characteristics and across all strata of baseline blood pressure and levels of obtained blood pressure (interaction *P*-value non-significant).

While the perindopril-based regimen in these trials included indapamide in many patients, the authors separately analysed the data with perindopril alone in ~15 000 individual patients, mainly from EUROPA² and part of PROGRESS.⁶ Although in this analysis the results for all-cause mortality and cardiovascular mortality alone were no longer significant, the combination of cardiovascular mortality, non-fatal myocardial infarction, and heart failure were significant, but not stroke, which appeared in large part to depend upon the use of indapamide and a greater degree of blood pressure lowering. These results reinforce the use of ACEIs in patients with vascular disease, especially coronary artery disease.

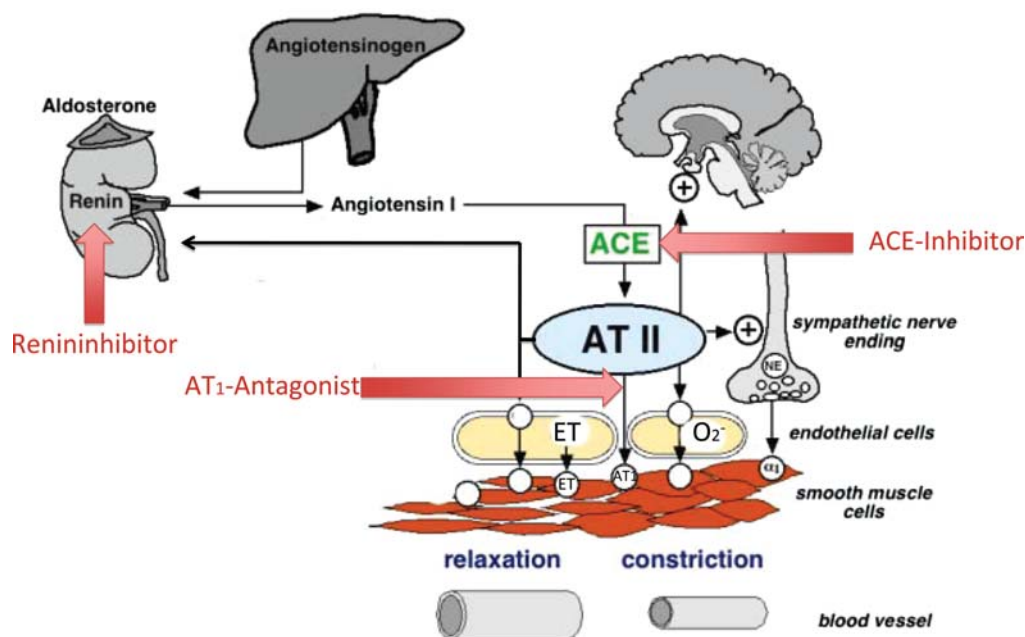
These results also raise several additional questions such as whether or not they apply to all ACEIs or only to perindopril. This question must, however, remain unanswered since we do not have adequately powered prospective comparative trials. While the possibility of a ‘class effect’ exists, there is a risk in this assumption, that in my opinion is unwarranted. It would be prudent to limit the use of ACEIs in patients with vascular disease without manifest hypertension to those shown to be effective in reducing cardiovascular events in patients with vascular disease, such as ramipril at its target dose. Also of importance is the question as to whether or not an angiotensin receptor blocker (ARB) could be substituted for an ACEI since ACEIs have been postulated to have a cardioprotective effect in contrast to an ARB due to the accumulation of bradykinin. The results of ONTARGET⁷ would suggest, however, that the ARB telmesartan was as effective as the ACEI ramipril in reducing cardiovascular events in patients with vascular disease. However, while one would be comfortable in using telmesartan at its target dose in a patient who did not tolerate an ACEI it should be pointed out that although there was no significant difference in cardiovascular outcomes between ramipril and telmesartan over the course of the trial the natural history of vascular disease is far longer. The recent finding that bradykinin is important for homing of endothelial progenitor cells and endothelial repair,⁸ along with the long experience and low cost of ACEIs, would favour preferential use of an ACEI over an ARB in patients with vascular disease.

The opinions expressed in this article are not necessarily those of the Editors of the *European Heart Journal* or of the European Society of Cardiology.

* Corresponding author. Tel: +1 734 9365260, Fax: +1 734 9365256, Email: bpitt@umich.edu

[†] doi:10.1093/eurheartj/ehp103

Published on behalf of the European Society of Cardiology. All rights reserved. © The Author 2009. For permissions please email: journals.permissions@oxfordjournals.org.



Since ACEIs appear to be beneficial in improving cardiovascular outcomes in patients with vascular disease one might also ask whether or not further blockade of the renin–angiotensin–aldosterone system (RAAS) might be even more effective. The results of ONTARGET⁷ suggest that there is little to be gained by adding an ARB to an ACEI, and possibly an increase in the risk of renal dysfunction.⁹ The finding that direct renin inhibitors (DRIs) improve renal blood flow significantly more than an ACEI¹⁰ raises the possibility that adding a DRI to an ACEI might result in a lower risk of renal dysfunction than when adding an ARB. However, until further large-scale prospective randomized trials are available demonstrating the safety and efficacy of this strategy, one should be cautious about adding a DRI to an ACEI in patients with vascular disease without manifest hypertension. There might also be a reason to consider adding an aldosterone blocker to an ACEI in a patient with vascular disease without manifest hypertension since animal experiments show an added benefit on the development of atherosclerosis when both an ACEI and an aldosterone blocker are used.¹¹ However, until these results are duplicated in adequately powered prospective clinical trials, this strategy can also not be recommended.

Thus, while there may be other means of blocking the RAAS in the future, the data of Brugs et al.⁴ are important today in guiding the therapy of patients with vascular disease and should encourage greater use of proven ACEIs at their target doses in patients with vascular disease independent of the occurrence of hypertension.

Conflict of interest: B.P. is a consultant for Pfizer, Merck, Novartis, Astra Zeneca, Schering Plough, Bayer, Takeda, and Bohringer Ingelheim.

References

1. Yusuf S, Sleight P, Pogue J, Bosch J, Davies R, Dagenais G. Effects of an angiotensin-converting-enzyme inhibitor, ramipril, on cardiovascular events in

high-risk patients. The Heart Outcomes Prevention Evaluation Study Investigators. *N Engl J Med* 2000;**342**:145–153.

2. Fox K; EUROpean trial On reduction of cardiac events with Perindopril in stable coronary Artery disease Investigators. Efficacy of perindopril in reduction of cardiovascular events among patients with stable coronary artery disease: randomised, double-blind, placebo-controlled, multicentre trial (the EUROPA study). *Lancet* 2003;**362**:782–788.
3. Boden WE, O'Rourke RA, Teo KK, Hartigan PM, Maron DJ, Kostuk WJ, Knudtson M, Dada M, Casperson P, Harris CL, Chaitman BR, Shaw L, Gosselin G, Nawaz S, Title LM, Gau G, Blaustein AS, Booth DC, Bates ER, Spertus JA, Berman DS, Mancini GB, Weintraub WS. Optimal medical therapy with or without PCI for stable coronary disease. *N Engl J Med* 2007;**356**: 1503–1516.
4. Brugs JJ, Ninomiya T, Boersma E, Remme WJ, Bertrand M, Ferrari R, Fox K, MacMahon S, Chalmers J, Simoon ML. The consistency of the treatment effect of an ACE inhibitor-based treatment regimen in patients with vascular disease or high risk of vascular disease: a combined analysis of individual data of ADVANCE, EUROPA, and PROGRESS trials. *Eur Heart J* 2009;**30**:1385–1394. First published on 4 April 2009. doi:10.1093/eurheartj/ehp103.
5. Patel A, MacMahon S, Chalmers J, Neal B, Woodward M, Billot L, Harrap S, Poulter N, Marre M, Cooper M, Glasziou P, Grobbee DE, Hamet P, Heller S, Liu LS, Mancia G, Mogensen CE, Pan CY, Rodgers A, Williams B. Effects of a fixed combination of perindopril and indapamide on macrovascular and microvascular outcomes in patients with type 2 diabetes mellitus (the ADVANCE trial): a randomised controlled trial. *Lancet* 2007;**370**: 829–840.
6. PROGRESS Collaborative Group. Randomised trial of a perindopril-based blood-pressure lowering regimen among 6,105 individuals with previous stroke or transient ischaemic attack. *Lancet* 2001;**358**:1033–1041.
7. ONTARGET investigators, Yusuf S, Teo KK, Pogue J, Dyal L, Copland I, Schumacher H, Dagenais G, Sleight P, Anderson C. Telmisartan, ramipril, or both in patients at high risk for vascular events. *N Engl J Med* 2008;**358**: 1547–1559.
8. Krankel N, Katare RG, Siragusa M, Barcelos LS, Campagnolo P, Mangialardi G, Fortunato O, Spinetti G, Tran N, Zacharowski K, Wojakowski W, Mroz I, Herman A, Manning Fox JE, MacDonald PE, Schanstra JP, Bascands JL, Ascione R, Angelini G, Emanuelli C, Madeddu P. Role of kinin B2 receptor signaling in the recruitment of circulating progenitor cells with neovascularization potential. *Circ Res* 2008;**103**:1335–1343.
9. Mann JF, Schmieder RE, McQueen M, Dyal L, Schumacher H, Pogue J, Wang X, Maggioni A, Budaj A, Chaithiraphan S, Dickstein K, Keltai M, Metsarinne K, Oto A, Parkhomenko A, Piegas LS, Svendsen TL, Teo KK, Yusuf S. Renal outcomes with telmisartan, ramipril, or both, in people at high vascular risk (the

ONTARGET study): a multicentre, randomised, double-blind, controlled trial. *Lancet* 2008;**372**:547–553.

10. Fisher ND, Hollenberg NK. Renin inhibition: what are the therapeutic opportunities? *J Am Soc Nephrol* 2005;**16**:592–599.

11. Imanishi T, Tsujioka H, Ikejima H, Kuroi A, Takarada S, Kitabata H, Tanimoto T, Muragaki Y, Mochizuki S, Goto M, Yoshida K, Akasaka T. Renin inhibitor aliskiren improves impaired nitric oxide bioavailability and protects against atherosclerotic changes. *Hypertension* 2008;**52**:563–572.

CARDIOVASCULAR FLASHLIGHT

doi:10.1093/eurheartj/ehp017

Online publish-ahead-of-print 24 February 2009

Three aneurysms developed in three different drug-eluting stents

Young-Soo Lee*, Kee-Sik Kim, and Sung-Gug Chang

Division of Cardiology, College of Medicine, Daegu Catholic University Medical Center, 3056-6, Daemyung-4-dong, Nam-gu, Daegu, Republic of Korea

*Corresponding author. Tel: +82 53 650 3041, Fax: +82 53 621 3166. Email: mdleey@cu.ac.kr

A 42-year-old man presented with chest angina. He had exertion chest discomfort 1 month ago. He had no cardiovascular risk factors. Chest X-ray revealed no cardiomegaly. Electrocardiogram revealed ST-segment elevation in lead II, III, and aVF. Echocardiography showed hypokinesia in inferior wall with an ejection fraction of 45%. We diagnosed ST-elevation myocardial infarction in inferior wall. We performed a coronary angiography (CAG) for primary percutaneous coronary intervention. The CAG showed a significant stenosis with plaque rupture at bifurcation portion of postero-lateral branch and postero-descending branch of the right coronary artery (RCA), which is considered as infarct-related artery, and a significant stenosis at proximal portion of the left anterior descending artery (LAD) and the left circumflex artery (LCX).

The RCA lesion was pre-dilated and implanted (zotarolimus-eluting stent 3.5 × 24 mm). After 3 days, we implanted two different stents at two significant lesions of LAD and LCX (LAD: sirolimus-eluting stent 3.5 × 23 mm; LCX: paclitaxel-eluting stent 3.5 × 24 mm) because of product delivery (Panels A, B, and C). We treated with aspirin 100 mg/day and clopidogrel 75 mg/day.

Six months later, he was admitted at our hospital due to atypical chest pain. We performed CAG. Follow-up CAG revealed huge aneurysms around the stents in RCA and LCX and small aneurysm around the stent in LAD (Panels D, E, and F). The aneurysms were clearly visible on intravascular ultrasound (Panels G, H, and I). We decided to treat with medication of three anti-platelet agents (aspirin, clopidogrel, and cilostazol) without additional intervention. He has been free of symptom until now.

Funding

Funding to pay the Open Access publication charges for this article was provided by grant No. RTI04-01-01 from the Regional Technology Innovation Program of the Ministry of Commerce, Industry and Energy (MOCIE).

Published on behalf of the European Society of Cardiology. All rights reserved. © The Author 2009. For permissions please email: journals.permissions@oxfordjournals.org. The online version of this article has been published under an open access model. Users are entitled to use, reproduce, disseminate, or display the open access version of this article for non-commercial purposes provided that the original authorship is properly and fully attributed; the journal, Learned Society and Oxford University Press are attributed as the original place of publication with correct citation details given; if an article is subsequently reproduced or disseminated not in its entirety but only in part or as a derivative work this must be clearly indicated. For commercial re-use, please contact journals.permissions@oxfordjournals.org

