

CURRICULUM IN CARDIOLOGY

Prevention of restenosis after percutaneous transluminal coronary angioplasty: The search for a "magic bullet"

Walter R. M. Hermans, MD, Benno J. Rensing, MD, Bradley H. Strauss, MD,* and Patrick W. Serruys, MD, PhD. *Rotterdam, The Netherlands*

Percutaneous transluminal coronary angioplasty (PTCA) is an accepted treatment for providing relief of angina pectoris in patients with single- and multi-vessel disease. Increased experience and advances in technology have resulted in a high primary success rate (90% to 95%) and a lower complication rate (4% to 5%). Despite the therapeutic success of coronary angioplasty, the exact mechanisms of dilatation remain speculative and involve multiple processes including stretching of the vessel at the site of the dilatation and disruption and fissuring of the plaque.¹ Angiographic renarrowing at the site of PTCA, frequently accompanied by recurrence of symptoms of angina, is a common phenomenon (30%) and has a negative bearing on the long-term results of PTCA. This usually occurs within the first 6 months after PTCA.^{2,3} Although many of the risk factors for restenosis have been identified (Table I),⁴⁻²⁵ most of these are difficult to influence. Until now we have not found a technical or pharmacologic cure, and we are unable to predict which patients or vessel segments will have restenosis. The reason why a clinically significant restenosis occurs in only a minority of the dilated vessels (30%) remains an enigma. Although the typical restenotic lesion differs from the usual atherosclerotic plaque in architecture and lipid content, both contain smooth muscle cells and fibrous tissue,^{26,27} and it is even likely that the factors responsible for restenosis are similar to

those that effect de novo atherosclerosis. In some cases of "restenosis" it is conceivable that it is caused by progression of the preexisting atherosclerotic plaque.

An important step in the restenosis process is activation of the hemostatic system with platelet adhesion, platelet aggregation, and fibrin formation. This is followed by smooth muscle cell proliferation, which is mediated by growth factors produced by cellular constituents in the blood and damaged vessel wall.^{28,29} Each of these steps could be sites of intervention that might halt the restenosis process. The drugs that could reduce or prevent restenosis in the animal model are listed in Table II. Some of these have been investigated in prospective randomized angioplasty trials and although efficacy has not been demonstrated, they continue to be used and prescribed in daily routine. In this review we will concentrate on the drugs (Fig. 1) that have been tested to prevent restenosis in the animal model (Table III) and in postangioplasty patients (Table IV).

Animal models are of limited value in restenosis research because it is impossible to create arterial stenoses in animals (e.g., pigs, rabbits, or dogs) that resemble human coronary artery disease (Table V). Most models use an inflated balloon to "injure" the intimal and medial layers of the vessel wall, although infused air has also been used. Some investigators have performed experiments in iliac or carotid arteries rather than in coronary arteries; others have fed the animals an atherogenic diet for brief periods of time to induce an "atherosclerotic lesion." Several studies in animals have examined the degree of platelet deposition after arterial injury to test the hypothesis that platelet aggregation and platelet-derived substances are responsible for the restenosis process.²⁹⁻³¹ Other studies use angiographic or histologic findings in damaged arteries to assess restenosis (Table IV). Recently a model of human restenosis

From the Catheterization Laboratory, Thoraxcenter, Erasmus University, Rotterdam.

*Dr. Strauss is a recipient of a research fellowship from the Canadian Heart Foundation.

Received for publication Aug. 27, 1990; accepted Oct. 2, 1990.

Reprint requests: Patrick W. Serruys, MD, PhD, Catheterisation Laboratory, Thoraxcenter, Erasmus University, P.O. Box 1738, 3000 DR Rotterdam, The Netherlands.

4/1/29357

Table 1. Variables associated with higher restenosis rates in patients with follow-up angiography

<i>Reference</i>	<i>Year</i>	<i>No. of patients</i>	<i>Clinical</i>
Holmes et al. ⁴	1984	557	Male sex Canadian class III-IV No previous MI Angina onset <2 mo Diabetes mellitus
Cowley et al. ⁵	1985	557	Male sex
Leimgruber et al. ⁶	1986	998	Old age Unstable angina Angina onset <2 mo
Kaltenbach et al. ⁷	1985	333	Medication ?
Levine et al. ⁸	1985	100	
Bertrand et al. ⁹	1986	229	
Uebis et al. ¹⁰	1986	100	
David et al. ¹¹	1984	191	Variant angina
Hollman et al. ¹²	1986	536	Diabetes mellitus
Scholl et al. ¹³	1981	45	Variant angina
Margolis et al. ¹⁴	1984	216	Insulin-dependent diabetes mellitus
Marantz et al. ¹⁵	1984	73	
Mata et al. ¹⁶	1985	63	
Probst et al. ¹⁷	1985	94	
Serruys et al. ¹⁸	1985	28	
Roubin et al. ¹⁹	1986	411	
Shaw et al. ²⁰	1986	97	High cholesterol Current smoker
Clark et al. ²¹	1986	124	
Powelson et al. ²²	1986	50	
Urban et al. ²³	1987	91	
Bertrand et al. ²⁴	1989	437	
Ellis et al. ²⁵	1989	308	

BIP, balloon inflation pressure; CABG, coronary artery bypass graft; DS, diameter stenosis; MI, myocardial infarction; TSG, transstenotic gradient; CWP, coronary wedge pressure.

*In patients with totally occluded vessel.

†Early restenosis (<2 days).

was developed in the domestic crossbred swine fed a standard nonatherogenic diet.³² Metallic foreign bodies were implanted percutaneously in porcine coronary arteries with oversized PTCA balloons inflated to high pressure. Results of histologic exam-

ination of lesions showed a marked proliferation of medial smooth muscle cells. This may be a useful animal model to test drugs used for treatment of restenosis, since it more closely resembles the response in human restenosis.

<i>Hemodynamic or procedure-related</i>	<i>Lesion-related</i>
Pre-PTCA TSG ≥40 mm Hg	Pre-PTCA DS > 70%
Post-PTCA TSG ≥20 mm Hg	PTCA on CABG
Post-PTCA TSG 15 mm Hg	LAD >RCA >LCX Post-PTCA DS >30% Absence of dissection Second PTCA PTCA on CABG
Inflation pressure <8 atm	Post-PTCA DS >30% Relative change <55% "Dynamic" coronary stenosis Length of pre-PTCA stenosis >2 mm Pre-PTCA DS >90% Post-PTCA DS >50% Concentric stenosis Multivessel PTCA Pre-PTCA DS ≥90% Post-PTCA DS >40% Absence of intimal tear Eccentric or calcified lesion
Post-PTCA TSG >18 mm Hg	Irregular lesion pre-PTCA
Maximum balloon pressure >7 atm	Large change in DS at PTCA
Balloon artery ratio ≤0.9	LAD or LCX >RCA Calcified stenosis Post PTCA DS >40%
Collaterals pre-PTCA Occlusion pressure >45 mm Hg	PTCA for total occlusion Multilesion PTCA in one vessel
More inflations* Higher BIP*	Presence of intimal disruption†
CWP ≥30 mm Hg	Presence of ergonovine-induced spasm before and after PTCA Stenosis at bend point of coronary artery

ANTICOAGULANTS AND ANTIPLATELET AGENTS

Platelets play an important role in the development of restenosis after PTCA.³³ Intact endothelium prevents platelet aggregation; however, after superficial injury a thin layer of thrombocytes attach themselves to the endothelium (platelet adhesion). If, however, there is deeper damage to the vessel wall,

blood is exposed to collagen and other substances of the subintima, which is a potent stimulus for platelet aggregation that is mediated by the release of adenosine diphosphate, serotonin, thromboxane A₂, fibrinogen, fibronectin, and von Willebrand factor. These substances activate neighboring platelets via different metabolic pathways (thromboxane A₂, adenosine diphosphate, and a platelet-activating factor) and promote thrombosis. In addition, the release of several growth factors, including platelet-derived growth factor, epidermal growth factor, and transforming growth factor beta from thrombocytes, smooth muscle cells, endothelium, and macrophages, stimulates smooth muscle cells and fibroblasts to proliferate and migrate from the medial layer into the intima of the vessel wall. In some patients this response is excessive and is associated with formation of abundant amounts of connective tissue. This results in hyperplasia of the intima with a reduction in luminal diameter.

To prevent platelet deposition (which occurs within minutes of the procedure) and the associated release of smooth muscle cell mitogenic factors, antiplatelet therapy appears to be a logical approach. Experimental studies have demonstrated that the use of antiplatelet agents can decrease the extent of platelet deposition and acute thrombosis after angioplasty, with some agents reducing the rate of restenosis in the pig model (dipyridamole [2.5 mg/day] + acetylsalicylic acid [20 mg/kg/day], low-dose acetylsalicylic acid [1 mg/kg/day], anagrelide, intravenous nitroglycerin, and intravenous ibuprofen).^{29, 34} Because only one of three pathways of platelet activation is blocked by current platelet-inhibitor therapy, it is not surprising that these agents are insufficient to prevent restenosis when tested in patients (Fig. 1).

Heparin. For many years heparin has been an integral aspect of the PTCA procedure since it binds reversibly with antithrombin, which results in increased activity of antithrombin. The antithrombin-heparin complex then binds with factor Xa and factor IIa resulting in an anticoagulant effect (believed to be the result of its IIa effect) and an antithrombotic effect (through its anti-Xa activity). Early discontinuation of heparin after angioplasty is associated with acute occlusion of the dilated arterial segment, suggesting that anticoagulation is important in the early stages after PTCA. However, the optimum duration of heparin therapy is still unknown.

A prospective trial conducted by the M-HEART study group³⁵ with 209 patients showed an inverse relationship between the duration of heparin therapy and the incidence of restenosis. This was not con-

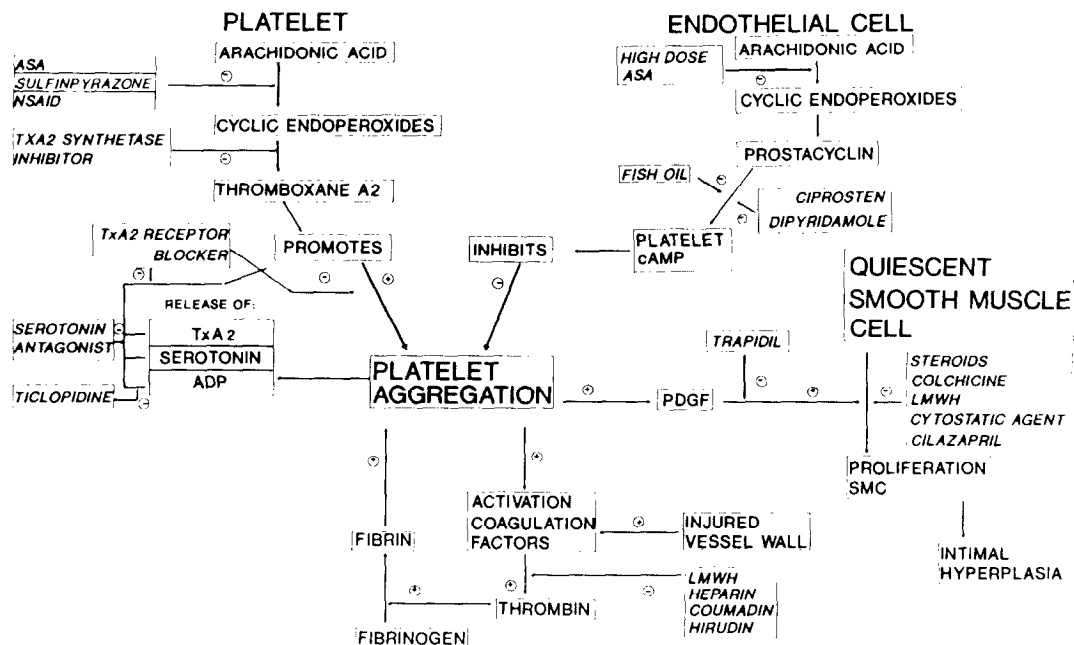


Fig. 1. Simplified schematic presentation of how the different drugs act on the different processes involved in the restenosis process (Modified from Fuster V et al. *Prog Cardiovasc Dis* 1987;22:325-46.) ASA, Acetylsalicylic acid; NSAID, nonsteroidal antiinflammatory drugs; TxA₂, thromboxane A₂; 7E3, antiplatelet glycoprotein receptor 2B/3A; ADP, adenosine diphosphate; LMWH, low molecular weight heparin; cAMP, cyclic adenosine monophosphate; IGF, insulin-like growth factor; FGF, fibroblastic growth factor; SMC, smooth muscle cell.

Table II. Mechanisms to prevent restenosis

Thrombosis
Heparin, hirudin, coumadin, acetylsalicylic acid, dipyridamole, sulfinpyrazone, thromboxane A ₂ synthetase inhibitor, thromboxane A ₂ receptor blocker, ticlopidine, prostacyclin, ciprostone, 7E3, fish oil, NSAID, ridogrel
Cell proliferation
Low-molecular-weight heparin, platelet-derived growth factor antagonist (trapidil), angiotensin-converting enzyme inhibitor (cilazapril), colchicine, cytostatic agents, serotonin antagonist (ketanserin), angiopeptin
Inhibitor of inflammation
Corticosteroids, nonsteroidal antiinflammatory drugs
Coronary vasospasm
Nifedipine, diltiazem
Lipid regulators
Fish oil, lovastatin

firmed in a randomized trial with 416 patients (469 stenoses) in Atlanta.³⁶ No differences in acute closure and restenosis were found in patients (all were without dissection; intimal flap inside or outside the lumen) randomly assigned to placebo or 18 to 24 hours of heparin after PTCA (all patients received acetylsalicylic acid for 6 months). Restenosis was defined as a narrowing of more than 50% of the vessel at the time of follow-up angiography, which was performed

in only 58.4% of the patients treated with heparin and 64.5% of the patients given placebo. More bleeding complications were seen in the group of patients who were treated with heparin (8.2% vs 3.8%). Acute total closure was seen more frequently in the group given placebo (2.4%) than in the group treated with heparin (1.8%), and the restenosis rate was 41.2% with heparin and 36.7% with placebo.

Because *low-molecular-weight heparin* affects platelet aggregation and platelet-dependent thrombin generation to a lesser extent than "regular" heparin, it has fewer side effects and yet both forms are known to inhibit the proliferation of vascular smooth muscle cells (dose dependent) and thrombosis after endothelial injury in the rat.^{37, 38} The mechanism of this inhibition is not clear.³⁹ Recently low-molecular-weight heparin has been used after transluminal angioplasty of rabbit iliac arteries.⁴⁰ Two groups were studied: the first group (n = 9) received low-molecular-weight heparin (10 mg/kg/day subcutaneously) immediately before transluminal angioplasty until follow-up angiography 1 month later, whereas the second group (n = 12) received a placebo. After 4 weeks all rabbits in the placebo group and three of nine rabbits in the group treated with low-molecular-weight heparin had a loss of more than 50% of the gain in diameter after transluminal

angioplasty. Histologic findings showed reduced intimal hyperplasia and no formation of thrombus in the group treated with low-molecular-weight heparin. A multicenter double-blind control trial with low-molecular-weight heparin (Enoxaparin) is currently underway in the United States. Patients without prior PTCA or recent myocardial infarction (within 5 days) are randomly assigned to placebo or low-molecular-weight heparin (30 mg subcutaneously) for 1 month, and all patients will undergo repeat angiography at 6 months. This will provide important information about whether long-term administration of low-molecular-weight heparin can decrease the rate of restenosis.

Hirudin. Newer anticoagulant drugs such as recombinant hirudin are becoming available. Hirudin prevents fibrinogen clotting, thrombin-catalyzed activation of factors V, VIII, and XIII, and thrombin-induced platelet activation. Hirudin has been shown to be more effective in preventing thrombosis than heparin (by quantifying the deposition of platelets and fibrinogen by means of the method of Dewanje in a swine model). This latter effect is probably due to the fact that hirudin is a more potent and specific thrombin antagonist.⁴¹ Trials designed to test the efficacy of hirudin on early and late complications of PTCA are currently in the planning stages in Europe and the United States.

Coumadin. Before Gruentzig began his work at Emory University in Atlanta in 1980, he had been administering coumadin (a vitamin K antagonist responsible for inhibiting thrombin formation) to his patients after balloon dilatation. In Atlanta his view was challenged since there was evidence that antiplatelet drugs were effective in preventing thrombosis in venous bypass grafts. To test this new therapeutic approach a trial was begun⁴² in which 248 patients were randomly assigned to either 325 mg acetylsalicylic acid daily or coumadin at a dose that resulted in a prothrombin time that was 2 to 2.5 times the normal value. In the group treated with acetylsalicylic acid (126 patients) restenosis was angiographically documented in 27% of the patients versus 36% of the patients treated with coumadin. A loss of >50% of the gain achieved at the time of PTCA or an increase in the stenosis of more than 30% (NHLBI IV) or development of positive (for ischemia) exercise test results if no angiogram was available were used as restenosis criteria. The results favored the acetylsalicylic acid strategy, but the difference was only significant for a subgroup of patients with a long history of chest pain (>6 months). In patients with poor compliance restenosis rates were 32% in the group treated with couma-

din versus 20% in the group given acetylsalicylic acid.

In London a more recent randomized trial⁴³ with 110 patients investigated the effect of a combination of coumadin and verapamil compared with verapamil alone. The incidence of restenosis was 25% by lesion and 29% by patient in the group treated with coumadin and 33% and 37% in the control group (NHLBI IV criterion was used). Although the incidence of angiographic restenosis tended to be lower with coumadin, none of the differences were significant. A randomized trial to evaluate the efficacy of coumadin in the prevention of restenosis should be performed that would ensure adequate medication compliance with reliable and safe monitoring of prothrombin time.

Acetylsalicylic acid. Acetylsalicylic acid is a "popular drug" in restenosis prevention trials. In the animal model it reduces platelet-thrombus deposition in a dose of 1 mg/kg/day when given in addition to heparin. Angiographic restenosis has also been shown to be reduced when acetylsalicylic acid is used in addition to dipyridamole.^{29, 44} Acetylsalicylic acid has the ability to inhibit platelet thromboxane A₂ synthetase and subsequent platelet activation by irreversibly blocking the enzyme cyclooxygenase, which is responsible for the conversion of arachidonic acid to thromboxane A₂. At high doses acetylsalicylic acid may be less effective, since it inhibits the production of prostacyclin (which prevents platelet aggregation) by endothelial cells.⁴⁵ However, it only partially inhibits platelet aggregation induced by adenosine diphosphate, collagen, or thrombin. Consequently platelet-derived growth factor and other mitogens may still affect proliferation of smooth muscle cells³³ (Fig. 1).

Acetylsalicylic acid has been studied in several prospective randomized trials. The first trial showed a reduction in the restenosis rate of 25% when acetylsalicylic acid (325 mg) was compared with coumadin.⁴³ Three trials compared different dosages of acetylsalicylic acid.⁴⁶⁻⁴⁸ In a trial in Homburg/Saar, 203 patients were randomly assigned to either 1500 mg/day or 320 mg/day. In a preliminary report 25% of these patients had been restudied (6 months after PTCA). Results of follow-up angiography showed restenosis (>50% diameter stenosis) in 13 of 44 (31%) patients in the group treated with the lower dose compared with 9 of 42 patients (21%) in the group given the higher dose.⁴⁶ However, in a randomized trial in Atlanta with 495 patients, the effectiveness of two doses of acetylsalicylic acid (80 mg vs 1500 mg daily started the day before PTCA) in the prevention of restenosis and acute complications af-

Table III. The effect of drug therapy in the animal model for prevention of restenosis

<i>Reference</i>	<i>Year</i>	<i>Model</i>	<i>Drug</i>	<i>Dose</i>
Clowes and Karnowsky ³⁷	1977	Rat A. carotis	Heparin Placebo	5-14 days
Gordon et al. ³⁹	1987	Rabbit aorta	LMWH Hydrocortisone LMWH + hydrocortisone Placebo	2.5 mg/kg/day 1 mg/kg/day
Pow et al. ⁴⁰	1989	Rabbit A. iliaca	LMWH Placebo	10 mg/kg/day
Heras et al. ⁴¹	1989	Pig A. carotis	Hirudin Heparin	1 mg/kg/hr 6 different doses
Faxon et al. ⁴⁴	1984	Rabbit A. iliaca	ASA + D Sulfinpyrazone Placebo	32-25 mg/day 100 mg/day
Sanborn et al. ⁵⁴	1986	Rabbit A. iliaca	TXA ₂ synthetase inhibitor Heparin ASA	1 mg/kg/hr 500 U/kg 10 mg/kg
Liu et al. ⁶²	1990	Rabbit A. iliaca	Trapidil Placebo	60 mg/kg/day
Currier et al. ⁶⁵	1989	Rabbit A. iliaca	Colchicine Colchicine Placebo	0.2 mg/kg 0.02 mg/kg
Barath et al. ⁶⁶	1989	Rabbit aorta	Vincristine + actinomycin Placebo	0.075 mg/kg + 0.015 mg/kg
Powell et al. ⁶⁷	1989	Rats A. carotis	Cilazapril Placebo	10 mg/kg 5 different durations
Müller et al. ⁶⁸	1990	Rats A. carotis	Captopril Hydralazine Verapamil	100 mg/kg/day 8 mg/kg/day 100 mg/kg/day
Foegh et al. ⁷⁰	1989	Rabbit cardiac transplant	Angiopeptin Placebo	
Faxon et al. ⁷²	1984	Rabbit	Nifedipine Placebo	40 mg/day
Gellman et al. ⁸⁰	1990	Rabbits A. femoralis	Lovastatin Placebo	6 mg/kg/day

ASA, acetylsalicylic acid; D, dipyridamole; LMWH, low-molecular-weight heparin; TXA₂, thromboxane A₂.

ter PTCA was compared.⁴⁷ Results of follow-up angiography were available in only 166 patients (34%). In the group treated with the low dose of acetylsalicylic acid, 47% of the patients had restenosis >50% diameter stenosis in one or more sites) compared with 51% in the group treated with the high dose. There were no differences in success or acute complication rates. Thus restenosis was not influenced favorably by the use of a higher dose of acetylsalicylic acid.

A smaller trial compared the effects of acetylsalicylic acid in doses of 100 mg/day versus 1000 mg/day, started 1 day before PTCA until 6 months after PTCA.⁴⁸ In addition, all patients received calcium channel blockers and long-acting nitrates. Restenosis (clinically significant stenosis requiring repeat PTCA or coronary artery bypass graft) occurred in 7 of the 40 patients in the group treated with 100 mg acetylsalicylic acid (18%) and in 8 of the 39 patients in the

group treated with 1000 mg acetylsalicylic acid (21%). The investigators concluded that restenosis is not favorably influenced by the use of high-dose versus low-dose acetylsalicylic acid. Another trial⁴⁹ designed to compare the effects of 100 mg acetylsalicylic acid with those of placebo was stopped prematurely after 40 patients (single blind) were enrolled because of reports showing the benefit of acetylsalicylic acid (combined with dipyridamole) in preventing acute thrombosis in dilated vessels and the need for urgent bypass surgery.⁵⁰ Results of follow-up angiography at 6 months (95% of the patients) in this particular trial showed an incidence of restenosis (>50% diameter stenosis) that was two times higher in the group treated with acetylsalicylic acid (33%) compared with the group given a placebo (14%). Although the difference seems impressive, it was not statistically significant because of the small numbers.

<i>Animals Total</i>	<i>Follow-up</i>	<i>Method</i>	<i>Effect</i>
45	7 days	Histology	Myointimal thickening less with heparin
16	2 wk	Histology	Ratio intimal/medial thickness in LMWH and hydrocortisone separately and synergistically lower than placebo
21	4 wk	Angiography	Δ Luminal diameter (Post-PTCA)-(follow-up) = 1.1 mm placebo and 0.3 mm LMWH ($p < 0.001$)
55		Histology Platelet deposition	
25	4 wk	Angiography Histology	ASA + D and sulfinpyrazone reduce restenosis
70	30 min	Platelet deposition	Less platelet accumulation with TXA ₂ synthetase inhibitor
17	4 wk	Arteriography Histology	Intimal thickness decreases with trapidil
34	4 wk	Arteriography (QCA) Histology	Δ Luminal diameter (Post-PTCA)-(follow-up) = 0.6 mm = 0.8 mm = 1.1 mm
36	3 days	Electron microscopy	Selective damage of proliferating smooth muscle cells
127	14 days	Histology	Intimal hyperplasia decreased with 70% given -6 → 14 days
43	Not reported	Histology	Captopril superior compared with others in reduction of intimal hyperplasia
20	6 wk	Histology	Intimal hyperplasia decreased by angiopeptin
18	4 wk	Angiography Histology	Δ Luminal diameter (Post-PTCA) (follow-up) = 0.9 mm = 1.2 mm
30	39 days	Arteriography Histology	Intimal hyperplasia decreased with lovastatin

In a well-designed trial at the Montreal Heart Institute and Toronto General Hospital,⁵¹ 376 patients were randomly assigned to a combination of acetylsalicylic acid (990 mg daily) and dipyridamole (225 daily) or to placebo starting the day before PTCA until follow-up angiography 4 to 7 months later. More acute complications were seen in the placebo group, including 13 periprocedural myocardial infarctions in the placebo group versus three in the treated group ($p < 0.05$). However, no differences were observed in the restenosis rate (increase in diameter stenosis from <50% after PTCA to >50% at follow-up): 39% (127 patients) in the placebo group compared with 38% (122 patients) in the treated group. All patients received heparin until 12 hours after the procedure (500 U/hr) and diltiazem until follow-up angiography.

Chesebro et al.⁵² randomly assigned 207 patients

(297 stenoses) to either acetylsalicylic acid (975 mg/day) and dipyridamole (225 mg/day) or to placebo from the day before PTCA until 6 months later. There was no difference in the restenosis rate defined in a linear model based on the minimum lumen diameter obtained by quantitative angiography. There were fewer acute complications (occlusion, myocardial infarction, repeat PTCA, coronary artery bypass graft <48 hours) in the group treated with acetylsalicylic acid and dipyridamole (11% vs 20% in the placebo group) confirming the results of the Montreal/Toronto trial. It is clear from these data that although acetylsalicylic acid does not influence the incidence of restenosis, it definitely has a positive influence on acute complications during or immediately after angioplasty.

Dipyridamole. In a rabbit model treatment with acetylsalicylic acid and dipyridamole decreased

Table IV. The effect of drug therapy on restenosis in patients after successful coronary angioplasty

<i>Reference</i>	<i>Year</i>	<i>Drug</i>	<i>Dose</i>	<i>Patients Total</i>
Hirshfeld et al. ³⁵	1987	Heparin	Different duration	209
Ellis et al. ³⁶	1989	Heparin (18-24 hr) Dextrose	<2.5 normal PTT	416
Thornton et al. ⁴²	1984	Coumadin	2-2.5 normal PTT	248
Urban et al. ⁴³	1988	ASA Coumadin + Verapamil Verapamil	325 mg/day >2.5 normal PTT Not reported	110
Dyckmans et al. ⁴⁶	1988	ASA	1,500 mg/day	203
Mufson et al. ⁴⁷	1988	ASA	320 mg/day	453
Schanzenbacher et al. ⁴⁸	1988	ASA	1,500 mg/day	79
		ASA	80 mg/day	
Finci et al. ⁴⁹	1988	ASA	1,000 mg/day	40
		ASA	100 mg/day	
Schwartz et al. ⁵¹	1988	ASA	100 mg/day	249
		Placebo		
Chesebro et al. ⁵²	1989	ASA + D	990-225 mg/day	207
		Placebo		
White et al. ⁵³	1987	ASA + D	975-225 mg/day	236
		Placebo		
Yabe et al. ⁵⁵	1989	ASA + D	650-225 mg/day	33
		Ticlopidine	750 mg/day	
Kitazume et al. ⁵⁶	1988	Placebo		280
		TXA ₂ synthetase inhibitor	600 mg/day	
Knudtson et al. ⁵⁷	1990	Placebo		270
		ASA	300 mg/day	
		ASA + Ticlopidine	+200 mg/day	
Raizner et al. ⁵⁸	1988	ASA + Ticlopidine + Nicorandil	+30 mg/day	311
		Prostacyclin + ASA + D	5 ng/kg/min	
Klein et al. ⁶⁴	1989	ASA + D	325 + 225 mg/day	43
		Placebo		
Corcos et al. ⁷³	1985	Ciprostone	120 ng/kg/min	92
		Placebo	maximum 48 hr	
Whitworth et al. ⁷⁴	1986	Ketanserin	0.1 mg/min for 24 hr	241
		Not reported		
Slack et al. ⁷⁵	1987	Diltiazem + ASA + D	270 mg/day	162
		ASA + D	650-225 mg/day	
Reis et al. ⁷⁶	1989	Nifedipine + ASA	40 mg/day	186
		ASA		
Milner et al. ⁷⁷	1989	Fish oil	2.4 gm/day	194
		Placebo		
Dehmer et al. ⁷⁸	1988	Fish oil	6.0 gm/day	82
		Placebo		
Grigg et al. ⁷⁹	1989	Fish oil	4.5 gm/day	108
		Placebo		
Sahni et al. ⁸¹	1989	Fish oil	3.2 gm/day	157
		Placebo		
Rose and Beauchamp ⁸⁴	1987	Fish oil	3.0 g/day	66
		Placebo		
Stone et al. ⁸⁵	1989	Lovastatin	20-40 mg/day	102
		Placebo		
Pepine et al. ⁸⁶	1990	Steroid	48 mg/day	722
		Placebo		
		Steroid for restenosis	125 mg methylprednisolone/day 240 mg prednisone/week	
		Steroid	1.0 gm methylprednisolone	
		Placebo		

Fup, follow-up (% of successful PTCA); DS, diameter of stenosis; PTT, prothrombin time; NS, not significant; ASA, acetylsalicylic acid; TXA₂, thromboxane A₂; D, dipyridamole.

Follow-up	Method	Definition	Restenosis (%) Drug vs placebo significance
Not reported	Angiography (4-12 mo)	>50% DS Fup (visual)	Longer heparin, less restenosis
61%	Angiography (3-9 mo)	>50% DS Fup (visual)	41% 37% $p = NS$
72%	Angiography (6-9 mo)	Loss >50% of gain	36% 27% $p = NS$
92%	Clinical	Stress test $- \rightarrow +$	
77%	Angiography (5 mo)	>50% DS Fup	29% 37% Patient $p = NS$
98%	Clinical		25% 33% Site $p = NS$
40%	Angiography (6 mo) (preliminary)	>50% DS Fup	21% 31% $p = NS$
37%	Angiography (3-8 mo)	>50% DS Fup (visual)	51% 47% $p = NS$
100%	Angiography (6 mo)	Clinical	21% 17% $p = NS$
73%	Angiography (6 mo)	>50% DS Fup (visual)	33% 14% $p = NS$
100%	Clinical		
72%	Angiography (4-7 mo)	>50% DS Fup (QCA)	38% 39% $p = NS$
85%	Angiography (5 mo) (QCA)	Minimum diameter (Post-PTCA) (Fup)	$\Delta 0.18$ mm Placebo $p = NS$ $\Delta 0.14$ mm ASA + D
75%	Angiography (6 mo)	>70% DS Fup (visual)	18% $p = NS$ 29% 20%
100%	Angiography (>3 mo)	Loss >50% of gain	22% 53% $p = NS$
100%	Angiography (6 mo)	>50% DS Fup	38% 27% 16% $p = 0.002$
93%	Angiography (6 mo) (caliper)	>50% DS Fup or loss >50% of gain	27% 32% patient $p = NS$ 22% 29% Site $p = NS$
80%	Angiography (6 mo) Clinical (MI, re-PTCA, CABG, Death)	>50% DS Fup (visual)	41% 53% Angiography $p = NS$ 17% 34% Clinical $p < 0.001$
100%	Angiography (4-6 mo)	Not reported (QCA)	33% 29% $p = NS$
100%	Angiography	>70% DS Fup (visual)	15% 22% $p = NS$
82%	Angiography (6 mo)	Loss >50% of gain	29% 33% $p = NS$
91%	Clinical	>50% DS Fup	
85%	Clinical (6 mo)	Stress test $- \rightarrow +$	16% 33% $p < 0.05$ Single vessel 67% 58% $p = NS$ Multivessel
30%	Angiography (6 mo)	>70% DS Fup	34% 23% $p = NS$
100%	Clinical	Stress test $- \rightarrow +$	
23%	Angiography (6 mo)	>50% DS Fup	18% 27% $p = NS$
100%	Clinical	Stress test $- \rightarrow +$	19% 35% $p < 0.01$
100%	Angiography (6 mo)	>50% DS Fup (visual)	16% 36% $p < 0.02$ Site 19% 46% $p < 0.007$ Patient
94%	Angiography (3-5 mo) (caliper)	Loss >50% of gain	34% 33% $p = NS$ Patient 29% 31% $p = NS$ Lesion
50%	Angiography (3 mo)	>50% DS Fup	14% 47% $p < 0.001$
88%	Angiography (3 mo)	>50% DS Fup	33% 33% $p = NS$
53%	Angiography (6 mo)	>50% DS Fup	52% 54% $p = NS$ Angiography
100%	Clinical	Stress test	58% 52% $p = NS$ Clinical
74%	Angiography (4-8 mo) (caliper)	>50% DS Fup	40% 39% $p = NS$ Lesion

Table V. Animal models used to test drugs for prevention of restenosis

<i>Animal</i>	<i>Vessel</i>	<i>Method</i>	<i>Therapy</i>	<i>End point</i>
Rabbit	Artery	1. Balloon denudation of endothelium	Antiplatelet	Platelet deposition (⁵¹ Cr or ¹¹¹ In labeled)
Pig	Coronary	2. Infused air	Anticoagulant	Angiography
Dog	Carotid	1 or 2 with or without diet high in cholesterol	Antiproliferative	Visual
Rat	Iliac	3. Coil implantation	Antiinflammatory	Quantitative
	Aorta	4. Electrical stimulation	Calcium antagonist	Histology
			Lipid lowering	

platelet-thrombus deposition and restenosis after transluminal angioplasty by increasing platelet cyclic adenosine monophosphate.⁴⁴ However, in clinical trials⁵¹⁻⁵³ no effect has been shown on the restenosis rate after angioplasty.

Sulfinpyrazone. In contrast to acetylsalicylic acid, sulfinpyrazone is a competitive (reversible) inhibitor of platelet cyclooxygenase, but the exact mechanism of its antithrombotic activity is not well understood. Faxon et al.⁴⁴ showed a reduction in restenosis with the use of a rabbit model. There is no clinical evidence to date to support a role for sulfinpyrazone in the prevention of restenosis after coronary angioplasty.

Thromboxane A₂ synthetase inhibitor. Thromboxane A₂ is a potent aggregating agent and vasoconstrictor. A specific inhibitor of thromboxane A₂ can antagonize these actions while at the same time leaving prostacyclin production of the vascular endothelium unaffected. In rabbits it was shown that a selective thromboxane synthetase inhibitor was more effective than heparin or acetylsalicylic acid in inhibiting platelet deposition after balloon angioplasty.⁵⁴ Another thromboxane A₂ synthetase inhibitor was tested in a small number of patients to prevent restenosis after PTCA.⁵⁵ It was given a minimum of 5 days before PTCA and was continued until follow-up angiography (>3 months later). Restenosis was defined as a >50% loss of the initial gain in luminal diameter. The results showed that 4 of the 18 patients (22%) given thromboxane A₂ synthetase inhibitor had restenosis versus 8 of the 15 patients (53%) in the placebo group. Besides inhibiting thromboxane A₂ synthetase, it is also possible to block the receptor of thromboxane on the platelet. Soon results will be available from a prospective European trial (Coronary Artery Restenosis Prevention On Repeated Thromboxane Antagonism) involving more than 700 patients treated with either a thromboxane A₂ receptor blocker or placebo until follow-up angiography 6 months after PTCA.

Ticlopidine. The mechanism of action of ticlopidine is not exactly known, but it is a potent platelet

inhibitor. The optimum effect occurs 3 days after the first administration and lasts for at least several days. In a multicenter trial in the United States, patients were randomly assigned to ticlopidine (750 mg/day), to a combination of acetylsalicylic acid (650 mg/day) and dipyridamole (225 mg/day), or to placebo. Restenosis was defined as a diameter stenosis of 70% or more at follow-up angiography (6 months). There was no difference in the restenosis rate; in the 65 patients who received ticlopidine the restenosis rate was 29% compared with 18% in the 57 patients who received acetylsalicylic acid and dipyridamole. Among the 54 patients who received placebo, the restenosis rate was 20%. There was no difference in the acute complication rate.⁵³ In Japan data collected retrospectively showed a lower restenosis rate when patients received a combination of ticlopidine (200 mg/day), nicorandil (30 mg/day), and aspirin (300 mg/day).⁵⁶

Prostacyclin or prostacyclin analogue. Prostacyclin is a potent naturally occurring platelet inhibitor and vasodilator. In a Canadian trial 270 patients were randomly assigned to placebo (136 patients) or prostacyclin (5 to 7 mg/min intravenously) (134 patients) just before PTCA up to 48 hours after PTCA.⁵⁷ All patients received 325 mg acetylsalicylic acid and 225 mg dipyridamole beginning before angioplasty until follow-up angiography 6 months later. Short-term administration of prostacyclin did not significantly lower the risk of restenosis: 27% in the treated group compared with 32% in the placebo group. Restenosis was defined as 50% or more narrowing at follow-up angiography or >50% loss of the immediate gain after angioplasty. Acute vessel closure and ventricular tachyarrhythmias were more common in the control group than in the patients who received prostacyclin.

Ciprostene. Ciprostone is a chemically stable analogue of prostacyclin. To study the effect of ciprostone during PTCA, 311 patients were randomly assigned shortly before PTCA (40 ng/kg/min) to ciprostone until 48 hours after PTCA (120 ng/kg/day) or to placebo. Acute closure occurred in three patients

in the placebo group and none in the ciprostone-treated group. Restenosis, defined as a diameter stenosis of 50% or more at the time of follow-up angiography, was present in 52 of the 126 patients (41%) treated with ciprostone and in 65 of the 122 patients (53%) given placebo. The clinical end points of this trial included death, myocardial infarction, repeat PTCA, or coronary artery bypass graft. In 30 of the 149 patients (20%) treated with ciprostone, one of these clinical end points was observed compared with 55 of the 147 patients (33%) in the placebo group. Although the clinical results were more favorable with ciprostone, there was no effect on the incidence of angiographic restenosis.⁵⁸

Prostaglandin E₁. Inasmuch as the deposition of platelets after angioplasty in porcine carotid arteries was reduced significantly after infusion with prostaglandin E₁ even more than with prostacyclin or dipyridamole, a study was attempted to determine the effect of intracoronary followed by intravenous prostaglandin E₁ on restenosis. Eighty patients were randomly assigned to an infusion of 20 to 40 ng/kg/min 12 hours before PTCA or placebo. Clinical follow-up showed abrupt occlusion in 3 of 40 patients in the placebo group compared with none in the prostaglandin E₁ group. An additional repeat PTCA was necessary in 4 of 40 given placebo compared with none in the group treated with prostaglandin E₁. No angiographic study has assessed the effect of prostaglandin E₁ on restenosis.⁵⁹

ANTIPROLIFERATIVE DRUGS

Restenosis is characterized by migration and proliferation of smooth muscle cells in response to balloon injury. Although the mechanisms responsible for proliferation and migration of smooth muscle cells are not completely understood, it has been postulated that they are controlled by the balance between growth factors and growth inhibitors released from circulating blood cells, at local tissue sites, or both.^{28, 60, 61} Interference with growth factor-mediated cellular hyperplasia may be beneficial in inhibiting smooth muscle cell proliferation and thereby reduce restenosis (Fig. 1).

Platelet-derived growth factor antagonist. Trapidil (triazolopyrimidine) has been shown to inhibit cellular proliferation induced by platelet-derived growth factor in cell culture and intimal thickening in damaged carotid arteries. In a model of atherosclerosis rabbits were assigned to placebo (n = 8) or trapidil (60 mg/kg/day) (n = 9). The medication was started 2 days before balloon dilatation of the external iliac artery and continued for 4 weeks. Follow-up angiography showed a greater luminal reduction in the

control group than in the trapidil group ($p < 0.001$) compared with similar baseline values. Histologic findings showed significantly less intimal hyperplasia in the trapidil group compared with the placebo group.⁶² A clinical trial in angioplasty patients seems warranted.

Serotonin antagonist. Serotonin, similar to platelet-derived growth factor, is released during platelet degranulation at the time of vessel injury and appears to directly stimulate proliferation of smooth muscle cells in addition to potentiating the effects of platelet-derived growth factor.⁶³ Therefore administration of a serotonin antagonist such as ketanserin may inhibit smooth muscle cell proliferation. Klein et al.⁶⁴ studied the effects of ketanserin on the incidence of early and late restenosis. Ketanserin was given intravenously (0.1 mg/min/24 hr) for 24 hours after PTCA to 21 patients. After 24 hours three patients in the placebo group had an occlusion compared with none in the control group. Follow-up angiography 4 to 6 months later showed no difference in restenosis rates: 29% in the control group and 33% in the ketanserin group. A large multicenter interventional trial (Post-Angioplasty Restenosis Ketanserin trial) with ketanserin has recently been started and will elucidate the question of whether a longer administration (6 months) has a beneficial effect on the incidence of restenosis.

Colchicine. Colchicine inhibits the proliferation and migration of smooth muscle cells and the release of chemotactants by leukocytes.⁶⁵ To study the effect of colchicine on restenosis, rabbits with atherosclerosis with >50% diameter stenosis underwent iliac transluminal angioplasty. Colchicine was started 2 days before transluminal angioplasty (0.02 mg/day or 0.2 mg/day) until follow-up angiography at 4 weeks. The high dose of colchicine significantly decreased the diameter stenosis at follow-up, although no effect was seen with the low dose. Clinical trials with colchicine are currently in progress. However, it is likely that the efficacy of the drug will be limited by a high incidence of side effects (abdominal pain, vomiting, diarrhea, and bone marrow depression).

Cytostatic agents. After the disruptive action of balloon dilatation, a change in differentiation of smooth muscle cells (with a shift from the contractile to synthetic phenotype) is observed and accompanied by cell proliferation and extracellular matrix production, which is the basis for the restenosis process. Barath et al.⁶⁶ hypothesized that cytostatic agents may prevent restenosis by selective injury to active and proliferating smooth muscle cells without damaging the normal smooth muscle cells. In their study rabbits were divided into four groups: the first

group was a control group, the second group had only a balloon dilatation of the aorta, the third group received the cytostatic agents (vincristine, 0.075 mg/kg, and actinomycin D, 0.015 mg/kg), and the fourth group underwent balloon dilatation and received cytostatic agents. All rabbits were killed 3 days later. Electron microscopic findings showed that the cytostatic agents prevented smooth muscle cell proliferation without damaging the "normal" smooth muscle cells. The principle concern with these agents is the potential for serious side effects, because they are capable of damaging other rapidly dividing cells, for example, those in the gastrointestinal tract, bone marrow, and reproductive system. Recently it has become possible to administer the drug locally with a specifically designed infusion catheter, which should limit systemic toxicity.

Angiotensin-converting enzyme inhibitors. Several organs contain local angiotensin-converting enzyme (ACE) systems. It appears that both the production of angiotensin II and its interaction with specific angiotensin II receptors may take place in these tissues independent of the plasma renin-angiotensin system.⁶⁷ ACE is a membrane-bound enzyme present in the walls of large arteries and veins. Angiotensin II receptors are present in the smooth muscle cells in the media of the vessel wall. In chronic hypertension it has been shown that long-term administration of an ACE inhibitor can reduce medial hypertrophy. It has been postulated that the local ACE system plays an important role in the remodeling process after arterial injury. There is also evidence to support the role of angiotensin II as a mitogen responsible for intimal hyperplasia after PTCA. In rats, neointima formation was reduced by 80% 14 days after balloon dilatation of the left carotid artery when an ACE inhibitor was given either 6 days before, 1 hour before, or 2 days after angioplasty and continued until 14 days after angioplasty. This effect seems to be dose dependent and is synergistic with the effect of heparin. There was no effect with administration of a single dose or when it was discontinued 2 days after balloon dilatation.⁶⁷ Further study has shown that captopril (100 mg/kg/day) also reduced intimal hyperplasia to almost the same extent. Two other vasodilators, verapamil and hydralazine, demonstrated a lesser effect.⁶⁸ These results indicate that hemodynamic effects on the vascular walls may influence the formation of intimal hyperplasia after balloon catheterization and that ACE inhibitors may reduce intimal hyperplasia through additional mechanisms related to inhibition of the angiotensin sys-

tem. Currently a large multicenter randomized trial in Europe (Multicenter European Research Trial with Cilazapril After Angioplasty to Prevent Transluminal Coronary Obstruction and Restenosis) is underway to determine the effect of cilazapril on the incidence of restenosis. More than 700 patients have been randomly assigned to cilazapril or placebo starting 4 to 6 hours after PTCA, in addition to the standard therapy of 200 mg acetylsalicylic acid. After 6 months (or earlier if indicated by symptoms) follow-up angiography is performed. A similar trial with 1400 patients has recently begun in the United States, but with a different dosage schedule.

Angiopeptin. It has been known for a long time that hypophysectomy inhibits neointimal plaque formation in response to endothelial injury.⁶⁹ This suggests that an endocrine factor may be involved in plaque formation. Recently the effect of a newly synthesized class of pituitary growth hormone-inhibiting agents on vascular smooth muscle cell hyperplasia after endothelial cell injury *in vivo* has been investigated. These compounds are peptide analogues of somatostatin and have a high affinity for somatostatin receptors on pituitary cells and inhibit release of pituitary growth hormone. One of these agents, angiopeptin, was shown to inhibit vascular smooth muscle cell proliferation in response to a variety of vascular injuries. This seems to be due to a local effect directly on smooth muscle cells.⁷⁰ This new group of agents is currently undergoing investigation as an inhibitor of several variants of "accelerated atherosclerosis" (postangioplasty, cardiac transplantation, and coronary bypass surgery).

CALCIUM ANTAGONIST

Coronary spasm is frequently seen during and shortly after PTCA and may have a role in the pathogenesis of restenosis.⁷¹ Calcium antagonists by inhibiting vasospasm may reduce the incidence of restenosis in an animal model,⁷² and in two randomized trials^{73, 74} calcium antagonists have not been shown to influence the incidence of restenosis.

Diltiazem. In a study from the Montreal Heart Institute,⁷³ 92 patients received diltiazem (270 mg) for 3 months, and all underwent recatheterization 5 to 10 months after balloon angioplasty or earlier if symptoms returned. All patients also received acetylsalicylic acid (650 mg) and dipyridamole (225 mg) for 6 months. Patients treated with diltiazem had a restenosis rate of 15% versus 22% in the patients not treated with diltiazem (restenosis was defined as stenosis of 70% or more at the time of the follow-up

angiography). The average decrease in diameter during follow-up was 4% in the diltiazem group and 7% in the control group. It was concluded that diltiazem had no effect on restenosis and that coronary spasm is not a major mechanism of restenosis.

Nifedipine. In a 6-month follow-up trial at Emory University in Atlanta,⁷⁴ 241 patients were randomly assigned to either nifedipine (40 mg/day) or placebo. All patients also received acetylsalicylic acid (325 mg/day). Restenosis was defined as a loss of more than 50% of the gain achieved at the time of PTCA. In patients who were compliant and underwent follow-up angiography (84 patients in both groups) there was no difference in restenosis rates: 29% in the nifedipine group and 33% in the placebo group.

LIPID-LOWERING DRUGS

Epidemiologic trials have shown that a diet rich in (n-3) polyunsaturated fatty acids (present in high concentrations in most salt water fish) may account for the low incidence of coronary disease in Eskimos. Animal research has shown that these polyunsaturated fatty acids inhibit atherosclerosis in general. This can be partly explained through a lowering of serum lipid levels and decreased aggregation of platelets by altering the balance between prostacyclin and thromboxane. In the last few years several trials have studied the effects of n-3 fatty acids in the prevention of restenosis after PTCA.

Slack et al.⁷⁵ showed that adding 2.4 gm of fish oil each day (rich in eicosapentaenoic acid) to the usual post-PTCA regimen of calcium channel blocker, nitrates, acetylsalicylic acid, and dipyridamole could reduce the incidence of clinical restenosis in patients with single-vessel disease (33% in the placebo group vs 16% in the group treated with fish oil). In 49 patients with multivessel disease, no influence could be shown. Reis et al.⁷⁶ showed that supplementing the normal diet with 6.0 gm of fish oil daily starting just before PTCA until 6 months later had no influence on the restenosis rate in 186 patients in whom PTCA was successful. Angiographic restenosis (70% diameter stenosis at a site previously dilated to less than 50%) was present in 34% of the group taking fish oil and 23% of the control group. However, repeat angiography was performed in only 68 patients (37%); almost all patients had a recurrence of chest pain, which contributed to selection bias at follow-up angiography. Milner et al.⁷⁷ found that the addition of 4.5 gm of fish oil each day to a normal diet in 194 patients had a positive influence on the clinical restenosis rate with 19% (16 of 84 patients) in the fish oil group versus 35% (35 of 99 patients) in the pla-

cebo group having a recurrence of chest pain. However, in the first week 11 of 95 patients stopped taking the medication because of side effects.

In Dallas⁷⁸ 82 patients were randomly assigned to acetylsalicylic acid and dipyridamole with and without 3200 mg (18 capsules) of eicosapentaenoic acid. Treatment was started 7 days before PTCA and was discontinued 6 months after PTCA. In all 82 patients a second angiogram (on average 3 to 4 months after PTCA) was obtained. Restenosis was defined as 50% or more narrowing of the dilatation site at follow-up angiography. Restenosis was seen in 46% in the placebo group and 19% in the treatment group. This trial suggests that n-3 fatty acids may effectively reduce restenosis in high-risk patients provided they comply with the treatment and are pretreated starting 7 days before PTCA. In Melbourne⁷⁹ 108 patients were randomly assigned to 10 capsules of fish oil or placebo. Medication was started the day before angioplasty and continued until 4 months after angioplasty. All patients also received acetylsalicylic acid and verapamil. Restenosis was defined as loss of >50% of the gain in luminal diameter at angioplasty (using caliper measurement). No difference in angiographically defined restenosis rates was observed: 34% in the group treated with fish oil versus 33% in the placebo group.

It is clear that a consensus cannot be reached. These conclusions are in part related to differences in the design of the individual studies. Although all studies were randomized, only in two studies were patients and investigators blinded to the n-3 supplement. Different dosages and formulations were used and patient compliance varied in the studies. There were also differences in the timing of initiation of therapy and variable methods (coronary angiography, stress test, or symptoms) for the detection of restenosis.

Cholesterol-lowering drugs. Hypercholesterolemia is a well-known risk factor for ischemic heart disease. Lipid modification is an important goal in secondary prevention in halting the progression of atherosclerosis in general and possibly after angioplasty. Recently it was shown that lovastatin reduces intimal hyperplasia after balloon angioplasty in rabbits with hypercholesterolemia.⁸⁰ However, two trials with postangioplasty patients in which the effects of lipid lowering on the incidence of restenosis^{81, 82} after PTCA were tested yielded conflicting results.

In the first trial⁸¹ 157 patients were randomly assigned to lovastatin or placebo for an unstated period of time. Only 50% of the patients underwent follow-up angiography at an average of 4 months after

PTCA (50 patients in the lovastatin group and 29 patients in the control group). Restenosis was defined as narrowing of 50% or more at follow-up angiography. Restenosis was seen in 14% of the sites in the lovastatin group and in 47% in the placebo group, suggesting a beneficial effect of lovastatin in this select group. In the second trial⁸² aggressive treatment was used in 55 consecutive patients to lower cholesterol levels, including diet, colestipol, and lovastatin, starting on the day of PTCA. After 2 weeks the cholesterol level was reduced by 50%. To date 44 of the 55 patients have been restudied with a restenosis rate of 34%. There was no difference in cholesterol levels between patients with and without restenosis.

INHIBITORS OF INFLAMMATION

Corticosteroids. Corticosteroids have been suggested as a potential restenosis inhibitor.⁸³ Hydrocortisone can inhibit growth of vascular smooth muscle in culture.³⁹ However, in a randomized trial in which patients received placebo or corticosteroids from 48 hours before to 5 days after PTCA, there was no difference in restenosis rates (33% in both groups).⁸⁴ The same results were achieved when steroids were given as treatment to 102 patients with restenosis after PTCA.⁸⁵ In addition to acetylsalicylic acid, dipyridamole, and a calcium antagonist, patients received 125 mg methylprednisolone intramuscularly 1 day before the repeat PTCA and 240 mg prednisone for 1 week. Only the 54 patients undergoing follow-up angiography were analyzed. Restenosis was defined as >50% diameter narrowing at the site. Restenosis was found in 36% of the stenoses in the group treated with steroids compared with 40% in the group receiving standard treatment.

In a recent multicenter trial in the United States,⁸⁶ 850 patients were randomly assigned to methylprednisolone or placebo 2 to 24 hours before PTCA. In 71% of the patients follow-up angiography was performed. There was no difference between the two groups in the incidence of restenosis (defined as >50% diameter stenosis): 43% in the group treated with methylprednisolone versus 43% of the patients in the group given placebo. These trials showed that administration of corticosteroids has no influence on the incidence of restenosis.

Nonsteroidal antiinflammatory drugs. Ibuprofen is known to decrease platelet-thrombus deposition in polytetra fluoroethylene (PTFE)* arterial grafts. In a study of normal porcine common carotid arteries pretreated with heparin, balloon angioplasty was performed and followed by a bolus (12.5 mg/kg) and infusion (75 to 100 µg/kg/min) of ibuprofen or pla-

cebo. Quantitative ¹¹¹In-labeled autologous platelet deposition at the site of angioplasty was significantly reduced by ibuprofen.⁸⁷ Whether this will affect the risk of late restenosis is not known.

FUTURE DEVELOPMENTS

Until now we have not found a drug that prevents restenosis in patients undergoing angioplasty. In the near future the results will be known of currently ongoing multicenter trials with a new ACE-inhibitor (cilazapril), serotonin antagonist (ketanserin), hirudin, low molecular weight heparin, angiopeptin and fish oil. Other promising drugs such as thrombin blockers, antagonists of smooth muscle cells, growth factor blockers, prostacyclin analogues, and monoclonal antibodies against platelet membrane receptors (GP IIb/IIIa) and the von Willebrand factor will be tested in clinical trials and may bring us closer to the solution of the restenosis problem.

CONCLUSION

Despite 13 years of clinical experience and research in the field of restenosis after PTCA, there have been no major breakthroughs in pharmacologic interventions. Assessment of the value of drug trials that have been performed in the past is extremely difficult because of differences in selection of patients, methods of analysis, and definition of restenosis. Recently our group has reviewed the influence of these three factors on the outcome and conclusion of restenosis studies.⁸⁸ Although there is no scientific proof that the tested drugs are effective, many clinicians continue prescribing them to "prevent restenosis."

Clinical and experimental research must continue to look for the elusive "magic bullet" that can prevent aggregation of thrombocytes, spasm, proliferation of smooth muscle cells, and atherosclerosis without any side effects and, if possible, in only one tablet! Moreover, the cost of this potential drug solution must be less expensive than repeating PTCA in 30% of all patients. It is clear that this magic drug has not been found, and in the meantime we will continue (re)diating while we search for a pharmacologic or technical solution to the problem of restenosis.

REFERENCES

1. Waller BF. "Crackers, breakers, stretchers, drillers, scrapers, shavers, burners, welders and melters." The future treatment of atherosclerotic coronary artery disease? A clinical-morphologic assessment. *J Am Coll Cardiol* 1989;13:969-87.
2. Serruys PW, Luijten HE, Beatt KJ, Geuskens R, de Feyter PJ, van den Brand M, Reiber JH, ten Katen HJ, van Es GA, Hugenholtz PG. Incidence of restenosis after successful coronary angioplasty: a time-related phenomenon. A quantitative angiographic study in 342 consecutive patients at 1, 2, 3 and 4 months. *Circulation* 1988;77:361-71.
3. Nobuyoshi M, Kimura H, Nosaka H, Mioka S, Ueno K, Ha-

*Gore-Tex vascular graft, registered trademark of W.L. Gore & Associates, Inc., Elkton, Md.

- masaki N, Horiuchi H, Oshishi H. Restenosis after successful percutaneous transluminal coronary angioplasty: serial angiographic follow-up of 299 patients. *J Am Coll Cardiol* 1988; 12:616-23.
4. Holmes DR, Vlietstra RE, Smith HC, Vetrovec GW, Kent KM, Cowley MJ, Faxon DP, Gruntzig AR, Kelsey SF, Detre KM, Raden MJ van, Mock MB. Restenosis after percutaneous transluminal coronary angioplasty (PTCA): a report from the PTCA Registry of the National Heart, Lung, and Blood Institute. *Am J Cardiol* 1984;53:77-81C.
 5. Cowley MJ, Mullin SM, Kelsey SF, Kent KM, Gruentzig AR, Detre KM, Passamani ER. Sex differences in early and long-term results of coronary angioplasty in the NHLBI PTCA Registry. *Circulation* 1985;71:90-7.
 6. Leimgruber PP, Roubin GS, Hollman J, Cotsonis GA, Meier B, Douglas JS, King III SB, Gruentzig AR. Restenosis after successful coronary angioplasty in patients with single-vessel disease. *Circulation* 1986;73:710-7.
 7. Kaltenbach M, Kober G, Scherer D, Vallbracht C. Recurrence rate after successful coronary angioplasty. *Eur Heart J* 1985;6:276-81.
 8. Levine S, Ewels CJ, Rosing DR, Kent KM. Coronary angioplasty: clinical and angiographic follow-up. *Am J Cardiol* 1985;55:673-6.
 9. Bertrand ME, LaBlanche JM, Thieuleux FA, Fourrier JL, Traisnel G, Asseman P. Comparative results of percutaneous transluminal coronary angioplasty in patients with dynamic versus fixed coronary stenosis. *J Am Coll Cardiol* 1986;8: 504-8.
 10. Uebis R, Essen R von, Dahl J vorn, Schmitz HJ, Seiger K, Effer S. Recurrence rate after PTCA in relationship to the initial length of coronary artery narrowing [Abstract]. *J Am Coll Cardiol* 1986;7(suppl A):62A.
 11. David PR, Renkin J, Moise A, Dangois V, Val PG, Bourassa MG. Can patient selection and optimization of technique reduce the rate of restenosis after percutaneous transluminal coronary angioplasty [Abstract]. *J Am Coll Cardiol* 1984; 3(suppl A):470A.
 12. Hollman J, Galan K, Franco I, Simpfendorfer C, Fatica K, Beck G. Recurrent stenosis after coronary angioplasty [Abstract]. *J Am Coll Cardiol* 1986;7(suppl A):20A.
 13. Scholl JM, David PR, Chaitman BR, Lespérance J, Crépeau J, Dyrda I, Bourassa MG. Recurrence of stenosis following percutaneous transluminal coronary angioplasty [Abstract]. *Circulation* 1981;64(suppl IV):IV-193.
 14. Margolis JR, Krieger R, Glemser E. Coronary angioplasty: increased restenosis rate in insulin-dependent diabetics [Abstract]. *Circulation* 1984;70(suppl II):II-175.
 15. Marantz T, Williams DO, Reinert S, Gewirtz H, Most AS. Predictors of restenosis after successful coronary angioplasty [Abstract]. *Circulation* 1984;70(suppl II):II-176.
 16. Mata LA, Bosch X, David PR, Rapold HJ, Corcos T, Bourassa MG. Clinical and angiographic assessment 6 months after double vessel percutaneous coronary angioplasty. *J Am Coll Cardiol* 1985;6:1239-44.
 17. Probst P, Zangl W, Pachinger O. Relation of coronary arterial occlusion pressure during percutaneous transluminal coronary angioplasty to presence of collaterals. *Am J Cardiol* 1985;55:1264-9.
 18. Serruys PW, Umans V, Heyndrickx GR, Brand M van den, Feyter PJ de, Wijns W, Jaski B, Hugenholtz PG. Elective PTCA of totally occluded coronary arteries not associated with acute myocardial infarction: short-term and long-term results. *Eur Heart J* 1985;6:2-12.
 19. Roubin G, Redd D, Leimgruber P, Abi-Mansour P, Tate J, Gruentzig A. Restenosis after multilesion and multivessel coronary angioplasty (PTCA) [Abstract]. *J Am Coll Cardiol* 1986;7(suppl A):22A.
 20. Shaw RE, Myler RK, Fishman-Rosen J, Murphy MC, Stertz SH, Topol EJ. Clinical and morphologic factors in prediction of restenosis after multiple vessel angioplasty [Abstract]. *J Am Coll Cardiol* 1986;7(suppl A):63A.
 21. Clark DA, Wexman MP, Murphy MC, Fishman-Rosen J, Shaw RE, Stertz SH, Myler RK. Factors predicting recurrence in patients who have had angioplasty (PTCA) of totally occluded vessels [Abstract]. *J Am Coll Cardiol* 1986;7(suppl A):20A.
 22. Powelson S, Roubin G, Whitworth H, Gruentzig A. Incidence of early restenosis after successful percutaneous transluminal coronary angioplasty (PTCA) [Abstract]. *J Am Coll Cardiol* 1986;7:63A.
 23. Urban P, Meier B, Finci L, Steffeninno GP, Rutishauser W. Coronary wedge pressure in relation to spontaneously visible and recruitable collaterals. *Circulation* 1987;75:906-13.
 24. Bertrand ME, LaBlanche JM, Fourrier JL, Gommeux A, Ruel M. Relation to restenosis after percutaneous transluminal coronary angioplasty to vasomotion of the dilated coronary arterial segment. *Am J Cardiol* 1989;63:277-81.
 25. Ellis SG, Roubin GS, King SB, Douglas Jr JS, Cox WR. Importance of stenosis morphology in the estimation of restenosis risk after elective percutaneous transluminal coronary angioplasty. *Am J Cardiol* 1989;63:30-4.
 26. Essed CE, van den Brand M, Becker AE. Transluminal coronary angioplasty and early restenosis: fibrocellular occlusion after wall laceration. *Br Heart J* 1983;49:393-6.
 27. Austin GE, Ratliff NB, Hollman J, Tabei S, Phillips DF. Intimal proliferation of smooth muscle cells as an explanation for recurrent coronary artery stenosis after percutaneous transluminal angioplasty. *J Am Coll Cardiol* 1985;6:369-75.
 28. Liu MW, Roubin GS, King III SB. Restenosis after coronary angioplasty. Potential biologic determinants and role of intimal hyperplasia. *Circulation* 1989;79:6:1374-87.
 29. Chesebro JH, Lam JYT, Badimon L, Fuster V. Restenosis after arterial angioplasty: a hemorrhagic response to injury. *Am J Cardiol* 1987;60:10B-16B.
 30. Faxon DP, Sanborn TA, Haudenschild CC. Mechanism of angioplasty in its relation to restenosis. *Am J Cardiol* 1987;60:5B-9B.
 31. Steele PM, Chesebro JH, Stanson AW, Holmes DR, Dewanjee M, Badimon L, Fuster V. Balloon angioplasty: natural history of the pathophysiological response to injury in a pig model. *Circ Res* 1985;57:105-12.
 32. Schwartz RS, Murphy JG, Edwards WD, Reiter SJ, Vlietstra RE, Holmes DR. A practical porcine model of human coronary artery restenosis post PTCA. [Abstract]. *J Am Coll Cardiol* 1990;15:165A.
 33. Stein B, Fuster V, Israel DH, Cohen M, Badimon L, Badimon JJ, Chesebro JH. Platelet inhibitor agents in cardiovascular disease: an update. *J Am Coll Cardiol* 1989;14:813-36.
 34. O'Gara PT, Guerrero JL, Feldman B, Fallon JT, Block PC. Effect of dextran and aspirin on platelet adherence after transluminal angioplasty of normal canine coronary arteries. *Am J Cardiol* 1984;53:1695-8.
 35. Hirshfeld Jr JW, Goldberg S, MacDonald R, Vetrovec G, Bass T, Taussig A, Margolis J, Jugo R, Pepine C. and the M-HEART Study Group. Lesion and procedure-related variables predictive of restenosis after PTCA—a report from the M-HEART study [Abstract]. *Circulation* 1987;76(suppl IV): IV-215.
 36. Ellis SG, Roubin GS, Wilentz J, Douglas Jr JS, King III SB. Effect of 18-24 hour heparin administration for prevention of restenosis after uncomplicated coronary angioplasty. *AM HEART J* 1989;117:777-82.
 37. Clowes AW, Karnowsky MJ. Suppression by heparin of smooth muscle cell proliferation in injured arteries. *Nature* 1977;265:625-6.
 38. Majesky MW, Schwartz SM, Clowes MM, Clowes AW. Heparin regulates smooth muscle S-phase entry in the injured rat carotid artery. *Circ Res* 1987;61:296-300.
 39. Gordon JB, Berk BC, Bettmann MA, Selwyn AP, Rennke H, Alexander RW. Vascular smooth muscle proliferation following balloon injury in synergistically inhibited by low molecular weight heparin and hydrocortisone [Abstract]. *Circulation* 1987;76(suppl IV):IV-213.

40. Pow TK, Currier JW, Minihan AC, Haudenschild CC, Ryon TJ, Faxon DP. Low molecular weight heparin reduces restenosis after experimental angioplasty [Abstract]. *Circulation* 1989;80:4(suppl II):II-64.
41. Heras M, Chesebro JH, Penny WJ, Bailey KR, Badimon L, Fuster V. Effects of thrombin inhibition on the development of acute platelet-thrombus deposition during angioplasty in pigs. Heparin versus recombinant hirudin, a specific thrombin inhibition. *Circulation* 1989;79:657-65.
42. Thornton MA, Gruentzig AR, Hollman J, King III SB, Douglas JS. Coumadin and aspirin in the prevention of recurrence after transluminal coronary angioplasty: a randomized study. *Circulation* 1984;4:69:721-7.
43. Urban P, Buller N, Fox K, Shapiro L, Bayliss J, Rickards A. Lack of effect of warfarin on the restenosis rate or on clinical outcome after balloon angioplasty. *Br Heart J* 1988;60:485-8.
44. Faxon DP, Sanborn TA, Haudenschild CC, Ryan TJ. Effect of antiplatelet therapy on restenosis after experimental angioplasty. *Am J Cardiol* 1984;53:72C-6C.
45. Oates JA, Fitzgerald GA, Branch RA, Jackson EK, Knapp HR, Roberts LJ. Clinical implications of prostaglandin and thromboxane A₂ formation (part I and II). *N Engl J Med* 1988;319:11:689-98 and 12:761-7.
46. Dyckmans J, Thönes W, Ozbek C, Müller M, Bach R, Schwerdt H, Sen S, Schieffer H, Bette L. High vs low dosage of acetylic salicylic acid for prevention of restenosis after successful PTCA. Preliminary results of a randomized trial [Abstract]. *Eur Heart J* 1988;9(suppl 9):58.
47. Mufson L, Black A, Roubin G, Wilentz J, Mead S, McFarland K, Weintraub W, Douglas Jr JS, King III SB. A randomized trial of aspirin in PTCA: effect of high vs low dose aspirin on major complications and restenosis [Abstract]. *J Am Coll Cardiol* 1988;11:2:236A.
48. Schanzenbacher P, Grimmer M, Maisch B, Kochsiek K. Effect of high dose and low dose aspirin on restenosis after primary successful angioplasty [Abstract]. *Circulation* 1988;78:II-99.
49. Finci L, Meier B, Steffenino G, Rutishauser W. Aspirin versus placebo after coronary angioplasty for prevention of restenosis [Abstract]. *Eur Heart J* 1988;(suppl 9):156.
50. Barnathan ES, Schwartz JS, Taylor L, Laskey WK, Kleveland JP, Kussmaul WG, Hirshfeld Jr JW. Aspirin and dipyridamole in the prevention of acute coronary thrombosis complicating coronary angioplasty. *Circulation* 1987;76:125-34.
51. Schwartz L, Bourassa MG, Lesperance J, Aldridge HE, Kazim F, Salvatori VA, Henderson M, Bonan R, David PR. Aspirin and dipyridamole in the prevention of restenosis after percutaneous transluminal coronary angioplasty. *N Engl J Med* 1988;318:1714-9.
52. Chesebro JH, Webster MWI, Reeder GS, Mock MB, Grill DE, Baily KR, Steichen S, Fuster V. Coronary angioplasty antiplatelet therapy reduces acute complications but not restenosis [Abstract]. *Circulation* 1989;80:4 (suppl II):II-64.
53. White CW, Knudson M, Schmidt D, Chisholm RJ, Vandormael M, Morton B, Roy L, Khaja F, Reitman M, and the Ticlopidine Study Group. Neither ticlopidine nor aspirin-dipyridamole prevents restenosis post PTCA: results from a randomized placebo-controlled multicenter trial [Abstract]. *Circulation* 1987;76(suppl IV):IV-213.
54. Sanborn TA, Ballelli LM, Faxon DP, Haudenschild CC, Valeri CR, Ryan TJ. Inhibition of 51CR-labeled platelet accumulation after balloon angioplasty in rabbits: comparison of heparin, aspirin, and CGS 13080, a selective thromboxane synthetase inhibitor [Abstract]. *J Am Coll Cardiol* 1986;7:213A.
55. Yabe T, Okamoto K, Oosawa H, Miyairi M, Noike H, Aihara M, Muramatu T. Does a thromboxane A₂ synthetase inhibitor prevent restenosis after PTCA [Abstract]. *Circulation* 1989;80:4(suppl II):II-260.
56. Kitazume H, Kubo I, Iwama T, Ageishi Y, Suzuki A. Combined use of aspirin, ticlopidine and nicorandil prevented restenosis after coronary angioplasty [Abstract]. *Circulation* 1988;78:II-633.
57. Knudtson ML, Flintoft VF, Roth DL, Hansen JL, Duff HJ. Effect of short-term prostacyclin administration on restenosis after percutaneous transluminal coronary angioplasty. *J Am Coll Cardiol* 1990;15:691-7.
58. Raizner A, Hollman J, Demke D, Wakefield L, and the ciprostone investigators. Beneficial effects of ciprostone in PTCA: a multicenter, randomized, controlled trial [Abstract]. *Circulation* 1988;78:4(suppl II):II-290.
59. See J, Shell W, Matthews O, Canizales C, Vargas M, Giddings J, Cerrone J. Prostaglandin E₁ infusion after angioplasty in humans inhibits abrupt occlusion and early restenosis. *Adv Prost Thromb Leuk Res* 1987;17:266-70.
60. Libby P, Warner SJC, Salomon RN, Birinyi LK. Production of platelet-derived growth factor like mitogen by smooth muscle cells from human atheroma. *N Engl J Med* 1988;38:1493-8.
61. Schneider MD, Parker TG. Cardiac myocytes as target for the action of peptide growth factors. *Circulation* 1990;81:1443-56.
62. Liu MW, Roubin GS, Robinson KA, Black AJR, Hearn JA, Siegel RJ, King SB. Tropicamide in preventing restenosis after balloon angioplasty in the atherosclerotic rabbit. *Circulation* 1990;81:1089-93.
63. Nemecek GM, Coughlin SR, Handley DA, Moskowitz MA. Stimulation of aortic smooth muscle cell mitogenesis by serotonin. *Proc Natl Acad Sci* 1986;83:674-8.
64. Klein W, Eber B, Fluch N, Dusleag J. Ketanserin prevents acute occlusion but not restenosis after PTCA [Abstract]. *J Am Coll Cardiol* 1989;13:2:44A.
65. Currier JW, Pow TK, Minihan AC, Haudenschild CC, Faxon DP, Ryan TJ. Colchicine inhibits restenosis after iliac angioplasty in the atherosclerotic rabbit [Abstract]. *Circulation* 1989;80:4(suppl II):II-66.
66. Barath P, Arakawa K, Cao J, Fishbein M, Fagin J, Lusis A, Forrester J. Low dose of antitumor agents prevents smooth muscle cell proliferation after endothelial injury [Abstract]. *J Am Coll Cardiol* 1989;13:2:252A.
67. Powell JS, Clozel JP, Müller RKM, Kuhn H, Hefti F, Hosang M, Baumgartner HR. Inhibitors of angiotensin-converting enzyme prevent myointimal proliferation after vascular injury. *Science* 1989;245:186-8.
68. Müller RKM, Kuhn H, Powell JS. Converting enzyme inhibitors reduce intimal hyperplasia after balloon catheter induced vascular injury [Abstract]. *Circulation* 1989;80:4(suppl II):II-63.
69. Tiel ML, Sterman MB, Spaet TH. The influence of the pituitary on arterial intimal proliferation in the rat. *Circ Res* 1978;42:644-9.
70. Foege ML, Khirabadi BS, Chambers E, Amamoo S, Ramwell PW. Inhibition of coronary artery transplant atherosclerosis in rabbits with angiopeptin, an octapeptide. *Atherosclerosis* 1989;78:229-36.
71. David PR, Waters DD, Scholl JM, Crépeau J, Szlachcic J, Lesperance J, Hudon G, Bourassa MG. Percutaneous transluminal coronary angioplasty in patients with variant angina. *Circulation* 1982;66:695-702.
72. Faxon DP, Sanborn TA, Gottsman SB, Ryan TJ. The effect of nifedipine on restenosis following percutaneous transluminal coronary angioplasty [Abstract]. *Circulation* 1984;70:4(suppl III):II-175.
73. Corcos T, David PR, Val PG, Renkin J, Dangoisse V, Rapold HG, Bourassa MG. Failure of diltiazem to prevent restenosis after percutaneous transluminal coronary angioplasty. *AM HEART J* 1985;109:926-31.
74. Whitworth HB, Roubin GS, Hollman J, Meier B, Leimgruber PP, Douglas Jr JS, King III SB, Gruentzig AR. Effect of nifedipine on recurrent stenosis after percutaneous transluminal coronary angioplasty. *J Am Coll Cardiol* 1986;8:1271-6.
75. Slack JD, Pinkerton CA, VanTassel J, Orr CM, Scott M, Allen B, Nasser WK. Can oral fish oil supplement minimize restenosis after percutaneous transluminal coronary angioplasty [Abstract]. *J Am Coll Cardiol* 1987;9:2(suppl):64A.

76. Reis GJ, Boucher TM, Sipperly ME, Silverman DJ, McGabe CH, Baim DS, Sacks FM, Grossman W, Pasternak RC. Randomised trial of fish oil for prevention of restenosis after coronary angioplasty. *Lancet* 1989;2:177-81.
77. Milner MR, Gallino RA, Leffingwell A, Pichard AD, Brooks-Robinson S, Rosenberg J, Little T, Lindsay Jr J. Usefulness of fish oil supplements in preventing clinical evidence of restenosis after percutaneous transluminal coronary angioplasty. *Am J Cardiol* 1989;64:294-9.
78. Dehmer GJ, Popma JJ, van den Berg EK, Eichhorn EJ, Prewitt JB, Campbell WB, Jennings L, Willerson JT, Schmitz JM. Reduction in the rate of early restenosis after coronary angioplasty by a diet supplemented with n-3 fatty acids. *N Engl J Med* 1988;319:733-40.
79. Grigg LE, Kay TWH, Valentine PA, Larkins R, Flower DJ, Manolas EG, O'Dea K, Sinclair AJ, Hopper JL, Hunt D. Determinants of restenosis and lack of effect of dietary supplementation with eicosapentanoic acid on the incidence of coronary artery restenosis after angioplasty. *J Am Coll Cardiol* 1989;13:665-72.
80. Gellman J, Ezekowitz MD, Sarembock IJ, Lerner E, Azrin MA, Nochomovitz LE, Haudenschild C. The effect of lovastatin on intimal hyperplasia following balloon angioplasty: an angiographic and morphometric study of the femoral artery in the atherosclerotic rabbit [Abstract]. *J Am Coll Cardiol* 1990;15:255A.
81. Sahni R, Maniet AR, Voci G, Banka VS. Prevention of restenosis by lovastatin [Abstract]. *Circulation* 1989;80:4(suppl II):II-65.
82. Hollman J, Konrad K, Raymond R, Whitlow P, Michalak M, van Lente F. Lipid lowering for the prevention of recurrent stenosis following coronary angioplasty [Abstract]. *Circulation* 1989;80:4(suppl II):II-65.
83. MacDonald RG, Panush RS, Pepine CJ. Rationale for use of glucocorticoids in modification of restenosis after percutaneous transluminal coronary angioplasty. *Am J Cardiol* 1987;60:56B-60B.
84. Rose TE, Beauchamp BG. Short term high dose steroid treatment to prevent restenosis in PTCA [Abstract]. *Circulation* 1987;76(suppl IV):IV-371.
85. Stone GW, Rutherford BD, McConahay DR, Johnson WL, Giorgi LV, Ligon RW, Hartzler GO. A randomized trial of corticosteroids for the prevention of restenosis in 102 patients undergoing repeat coronary angioplasty. *Cathet Cardiovasc Diagn* 1989;18:227-31.
86. Pepine CJ, Hirshfeld JW, Macdonald RG, Henderson MA, Bass TA, Goldberg S, Savage MP, Vetrovec G, Cowley M, Taussig AS, Whitworth HB, Margolis JR, Hill JA, Bove AA, Jugo R. A controlled trial of corticosteroids to prevent restenosis after coronary angioplasty. *Circulation* 1990;81:1753-61.
87. Lam JYT, Chesebro JH, Dewanjee MK, Badimon L, Fuster V. Ibuprofen: a potent antithrombotic agent for arterial injury after balloon angioplasty [Abstract]. *J Am Coll Cardiol* 1987;9:64A.
88. Beatt KJ, Serruys PW, Hugenholtz PG. Restenosis after coronary angioplasty: new standards for clinical studies. *J Am Coll Cardiol* 1990;15:491-8.