

# **Preservation of the Larynx in Laryngeal and Hypopharyngeal Cancer**

**Aniel Sewnaik**

Printed by Print Partners IPSKAMP  
Cover Design & Layout by Charles Stephan

Copyright © Aniel Sewnaik, 2006

No part of this book may be reproduced, stored in a retrieval system  
or transmitted in any form or by any means, without permission of the author or,  
when appropriate, of the scientific journal in which parts of this book have been published.

**Preservation of the Larynx in Laryngeal and Hypopharyngeal Cancer**

**Behoud van de Larynx bij het Larynx- en Hypofarynxcarcinoom**

**Proefschrift**

ter verkrijging van de graad van doctor aan de  
Erasmus Universiteit Rotterdam  
op gezag van de rector magnificus

Prof.dr. S.W.J. Lamberts

en volgens besluit van het College voor Promoties

De openbare verdediging zal plaatsvinden op  
woensdag 17 Mei 2006 om 11:45 uur

door

Aniel Sewnaik  
geboren te Paramaribo

## PROMOTIECOMMISSIE

Promotor: Prof.dr. L. Feenstra

Overige leden: Dr. P.P.M. Knegt  
Prof.dr. H.W. Tilanus  
Prof.dr. P.C. Levendag

Copromotor: Dr. J.D.F. Kerrebijn

## **Contents**

	<b>Page</b>
Chapter I: Introduction	7
Chapter II: Partial laryngectomy for recurrent glottic carcinoma after radiotherapy	13
Chapter III: Supracricoid partial laryngectomy with Cricohyoidoepiglottopexy for recurrent laryngeal cancer	29
Chapter IV: Surgery for recurrent laryngeal carcinoma after radiotherapy: partial laryngectomy or total laryngectomy for a better quality of life?	45
Chapter V: Treatment of hypopharyngeal carcinoma: analysis of nationwide study in the Netherlands over a 10-year period	57
Chapter VI: The devastation of chemoradiation	75
Chapter VII: General discussion	91
Samenvatting/ Summary	107
Dankwoord	115
Curriculum Vitae	117



# **Chapter I**

## **Introduction**

Adapted from *Kwaadaardige nieuwvormingen*.

D.J.Th. Wagener, J.W.W. Coebergh en A. Sewnaik

*Tabaksgebruik:gevolgen en bestrijding*. 2005

Head and neck cancer accounts for about five percent of all human cancers. In 1998 twenty-three hundred new patients were diagnosed with head and neck cancer in the Netherlands.<sup>1</sup> About ninety percent of all head and neck cancers are squamous cell carcinoma.<sup>2</sup> (Table I) Of these laryngeal carcinoma is the most frequent involved site in males and the third most frequent involved site in females. The incidence in the Netherlands in 1998 for males was 7.6 per 100.000 person-years. For females the incidence was 1.2 per 100.000 person-years. The male-female ratio was 6.3:1. In the period between 1989 and 1998 the incidence decreased for males and increased for females. The incidence for hypopharyngeal carcinoma in the Netherlands in 1998 was 1.8 per 100.000 person-years for males and 0.3 per 100.000 person-years for females. The male-female ratio cancer was 6:1. Since 1998 the incidence of hypopharyngeal cancer both for males and females has increased.<sup>1</sup> Smoking is the most important risk factor for laryngeal cancer both for males and females, while especially the combination of smoking and alcohol abuse is considered to be an important combination in the development of hypopharyngeal cancers.

### *Smoking and squamous cell carcinoma*

Tobacco smoke contains a number of substances which cause genetic mutations leading to DNA-adducts. DNA adducts originate after exposure to polycyclic aromatic hydrocarbon (PAH), nitro hydrocarbon and aromatic amines (all of them found in tobacco smoke).<sup>3,4</sup> It has been demonstrated that there are significant more DNA adducts in malignant tumours than in healthy tissue. Also more DNA adducts are found in tissue of recurrent tumours than in primary tumours.<sup>3</sup> This might be caused by permanent damage to the DNA-repair system. The amount of DNA adducts is higher in males than in females at equal exposure to tobacco which has so far not been explained.<sup>3</sup> Some gene mutations have an effect on the carcinogenesis, such as proto-oncogenes and tumour-suppressor genes. In head and neck cancer mutations in P53- and P16-tumor suppressor genes appear frequently.<sup>3,4</sup> These tumour suppressor genes take care for the negative regulation of cell growth. For head and neck cancer the P53 gene is more important than the P16 gene. A mutation in the P53 gene causes accumulation of the P53 protein. The tumour suppression is lost and uncontrolled cell growth appears. Uncontrolled cell growth also appears because of mutation caused by tobacco smoke in proto-oncogenes. The proto-oncogenes are converted into oncogenes (H-ras), which cause the cell growth.



Glutathione-S- enzyme system causes detoxification in the cells.

Tobacco smoke also causes mutations in this system and the carcinogenic substances cannot be removed from the cell.

Substances in tobacco smoke, which cause degeneration of squamous cell epithelium, deregulate different enzyme systems and cell regulating systems.

Alcohol is also an important risk factor, especially for those sites where it has direct contact with the mucosa (oral cavity, pharynx and- oesophagus).<sup>5</sup>

The tumour promoting effect of alcohol is not cleared.

It seems that the metabolite of alcohol, acetaldehyde, is the toxic factor.<sup>6</sup>

It is suspected that acetaldehyde influences the tumour suppressor cells.

This might cause uncontrollable cell growth.

In the Netherlands, a consensus guideline for treatment of laryngeal cancer has been established in 1999.<sup>7</sup> The primary treatment goal is tumour control. The choice of treatment is however also influenced by other factors, such as the expected quality of life outcome. Preservation of a functional larynx, if possible, is important in the treatment of laryngeal cancer.

The choice of organ preservation therapy does not have a negative effect on life expectancy in most patients. Therefore, the primary treatment for the majority of laryngeal cancers is radiotherapy or minimal invasive surgery. Only in advanced cases (see chapter 7) primary laryngectomy in combination with radiotherapy is indicated. Tumours, however, do recur after radiotherapy in 10-50% of the cases depending on stage of the primary tumour. In case of recurrent laryngeal cancer, the golden standard of treatment is a total laryngectomy.

In chapter 2 it is shown that in selected cases with recurrent laryngeal cancer a functional larynx can be preserved. A partial laryngectomy (endoscopic CO<sub>2</sub>-laser and frontolateral partial laryngectomy) can be a good alternative for a total laryngectomy. A third partial procedure performed in our hospital is the cricohyoideoepiglottopexy. Chapter 3 discusses the cricohyoideoepiglottopexy as organ preservation salvage treatment with good functional outcome. The reason to perform salvage partial laryngectomies is the expected better of quality of life outcome, compared to total laryngectomy. Chapter 4 discusses the QoL after partial laryngectomy versus total laryngectomy .

Squamous cell carcinoma of the hypopharynx is relatively rare and has the worst prognoses of all head and neck cancers. In the 1970s most patients were treated with surgery, radiotherapy or a combination of these two treatment modalities.<sup>8</sup> The 5-year survival rate for combined surgery with radiotherapy varies between 25% and 60%.<sup>8,9</sup> For the purpose of improving survival rates as well as the preservation of the larynx, a third treatment modality, chemotherapy, mostly in combination with radiotherapy, was introduced. Unlike laryngeal cancer, there is no consensus guideline in the Netherlands for treatment of hypopharyngeal cancer yet. An inventory of treatment approaches for hypopharyngeal cancers in eight centres in the Netherlands was initiated by the National Head and Neck tumourboard (NWHHT) in 1984.

The results of this study are summarized in chapter 5. Between 1985 and 1994 most patients were treated with radiotherapy or a combination of surgery and radiotherapy. In the nineties, a new organ preservation approach, radiotherapy combined with chemotherapy became increasingly popular. It was soon recognized that side effects of this kind of treatment can be severe. Also the quality of tissues after chemoradiation is generally poor. This is an important issue in the treatment of recurrent or residual cancers, for the only treatment option is surgery, mostly a total laryngectomy. Chapter 6 addresses quality of life issues and the complications of surgery after chemoradiation.

Table 1 Types malignant head and neck tumours <sup>2</sup>

Histological type	Incidence
Squamous cell carcinoma	± 90%
Undifferentiated carcinoma	± 10%
Lymphepithelioma	
Adenocarcinoma	
Adenoid cystic carcinoma	
Mucoepidermoid carcinoma	
Malignant mengtumor	
Malignant melanoma	
Lymphoma	
Esthesioneuroblastoma	
Sarcoma	

## References

1. Van Dijck JAAM, Coebergh JWW, Siesling S, Visser O. Trends of cancer in the Netherlands 1989-1998. Utrecht: Vereniging van Integrale Kankercentra, 2002
2. Paparella, Shumsick, Gluckman, Meyerhof. Otolaryngology. 1999
3. Szyfter K, Szmeja Z, Szyfter W et al. Molecular and cellular alterations in tobacco smoke-associated larynx cancer. Mutation research. 1999; 445: 259-274
4. W.M. Koch. Molecular biology of head and neck tumours. Otolaryngology – head and neck surgery, 3<sup>rd</sup> edn. 1998
5. Boffeta P, Ye W, Adami HO, Mucci LA, Nyren O. Risk of cancers of the lung, head and neck in patients hospitalised for alcoholism in Sweden. Br J cancer. 2001; 85(5): 678-682
6. Homann N. Alcohol and upper gastrointestinal tract cancer: the role of local acetaldehyde production. Addict Biol. 2001; 6(4): 309-323
7. Nederlands Werkgroep Hoofd-Halstumoren. Richtlijn larynxcarcinoom. 1999
8. Loré JM, Kaufman S, Sundquist N, Chary KK. Carcinoma of the head and neck: A 5- to 20-year experience with preoperative chemotherapy, uncompromised surgery, and selective radiotherapy. Ann. Surg. Oncol. 2003; 10(6): 645-653
9. Lajtmam Z, Manestar D. A comparison of surgery and radiotherapy in the management of advanced pyriform fossa carcinoma. Clin. Otolaryngol. 2001; 26: 59-61



## **Chapter II**

Partial laryngectomy for recurrent glottic carcinoma after radiotherapy

A.Sewnaik, CA Meeuwis, TH van der Kwast, JDF Kerrebijn

Head and Neck. 2005; 27: 101-107

## **Abstract**

**Background:** Early laryngeal cancer is treated with surgery or radiotherapy. A partial laryngectomy instead of a total laryngectomy can be used for treating radiation failures.

**Methods:** Patients were grouped in the two types of partial laryngectomies we perform: group I, endoscopic laser surgery (n = 42); and group II, frontolateral partial laryngectomy (n = 21).

**Results:** With CO<sub>2</sub>-laser treatment, 14 of 24 patients (no involvement of the anterior commissure) and eight of 18 patients (involvement of the anterior commissure) were cured. With the frontolateral partial laryngectomy we achieved local control in 15 of 21 patients.

**Conclusions:** If the surgeon is familiar with the different techniques of, and indications for, partial laryngectomy, this can be a good and satisfying treatment in selected patients radiation failure for glottic cancer.

**Keywords:** glottic recurrent laryngeal cancer, radiotherapy, partial laryngectomy, endoscopic laser surgery and frontolateral partial laryngectomy

## **Introduction**

Early laryngeal cancer is curable with either radiotherapy or surgery.<sup>1</sup> The aim of the treatment is tumour control with maximal preservation of function.<sup>2</sup> In most centres in Northern Europe and North America, radiotherapy is the primary treatment of small laryngeal tumours.<sup>3</sup> The main argument for the choice of this kind of treatment is the supreme post-treatment quality of voice.<sup>1,4,5</sup> Local recurrences after radiotherapy for glottic lesions occur in 5%-20% for T1 tumours and 25%-30% for T2 tumours.<sup>6</sup> Once a recurrence is confirmed by histological examination, a surgical salvage procedure is the only chance of cure. This can be either a total laryngectomy, or a partial laryngectomy, the latter through an external approach or an endoscopic (laser) procedure. A total laryngectomy is often performed because a wide surgical margin can be obtained, while modern speech prostheses allow an adequate functional rehabilitation. However, in selected patients, sufficient surgical margins can be obtained with a partial laryngectomy, so that these patients retain their own, functional larynx. Unlike total laryngectomy, a partial laryngectomy is not a defined operation but merely a common denominator for a variety of procedures all aimed at preserving part of the larynx. These procedures include endoscopic laser resection, horizontal (supraglottic partial procedures), vertical (hemilateral, frontolateral) partial laryngectomy, and supraccricoid procedures (cricohyoidoepiglottopexy, cricothyroidopexy). The goal of this study was to review the oncological and functional results, the indications, and the complications of various partial procedures for glottic recurrences after radiotherapy.

## **Material and methods**

Between 1980 and August 2002, 63 partial laryngectomies were performed at the department of Otolaryngology Head and Neck Surgery of the Erasmus Medical Centre Rotterdam in the Netherlands for recurrent (after previous radiotherapy) or second primary carcinomas of the larynx. Previous treatment had consisted of radiation of 66 to 70 Gy, in 2 Gy fractions, five to six times per week. The patients were grouped according to the 2 types of partial laryngectomies we perform: group I, endoscopic laser surgery (n = 42); and group II, frontolateral partial laryngectomy (n = 21). Before 1997, most patients were treated with laser surgery, because external procedures were not routinely performed during this period. The medical records were studied for oncologic and functional follow up, post-operative complications, length of rehabilitation, and other clinical information. From 1997 forward, both operative reports and information concerning rehabilitation were recorded on standard forms. Patients treated with a frontolateral laryngectomy received a questionnaire to assess swallowing and difficulties with their voice. These questionnaires were sent out at least 3 months after surgery. All recurrent tumours were squamous cell carcinomas except for one undifferentiated carcinoma. Routine work-up prior to salvage surgery consisted of a chest x-ray and an ultrasonography of the neck, if indicated, combined with fine-needle aspiration. CT scans of the larynx were performed only in a minority of patients.

### Group I, CO<sub>2</sub>-laser surgery (n = 42).

The indications for laser surgery are listed in table I. The intent of the procedure was cure of disease in all patients. The group consisted of 40 men and two women, ranging from 45 to 79 years of age. The primary tumour had been classified as Tis in four patients, T1 in 34 patients and T2 in four patients. Thirty-five patients had a recurrent glottic tumour, and seven patients had a second primary glottic laryngeal tumour. The period of recurrence after radiation therapy ranged from 5 months to 14 years. Surgery was carried out under general anaesthesia using high frequency jet ventilation.<sup>7</sup> Face and eyes of the patient are protected from laser reflections with wet gauze. The tumour is excised using laser settings between 5 and 10 Watts at an intermittent or continuous pulse. Frozen sections are not routinely used for reasons to be discussed later. Antibiotics are not given unless a significant amount of cartilage is exposed. Postoperatively, oral feeding is started immediately, and the patient is usually discharged the day after the operation.

### Group II. Frontolateral laryngectomy (n =21)

Indications for frontolateral laryngectomy are listed in table II. All patients were men, with an age range of 48 years to 94 years. The primary tumour had been classified as Tis in two patients, T1 in 12 patients and, T2 in seven patients. Nineteen patients had a recurrent glottic tumour, and two patients had a second primary glottic laryngeal tumour. The period of recurrence after radiation therapy ranged from 4 months to 32 years. The technique of a frontolateral laryngectomy is described by Weinstein and Laccourreye.<sup>8</sup> It must, however, be kept in mind that after radiotherapy, the tissues are more susceptible to oedema and necrosis, and some modifications are necessary. Briefly the procedure is as follows. The patient is started on antibiotics (amoxicillin clavulanate potassium, 1.2 g three times per day for 1 week). Before the operation, an endoscopy is performed. To judge accurately the distal extent of the tumour in relation to the cricoid, which is the caudal limit of the resection, a needle may be brought into the larynx through the skin over the cricoid cartilage. After a tracheostomy, a midline approach of the larynx is made. The outer layer of the perichondrium is elevated from the cartilage on both sides but is left attached to the inner side of the thyrohyoid muscle for in previous radiated patients the perichondrium is useless for reconstruction as a separate layer. A paramedian cartilage cut is made on the lesser-involved side, and the larynx is opened through the paraglottic tissues and vocal cord. The second cartilage cut is made with direct view of the tumour, and the resection is completed. Frozen sections are taken from the wound edges. As much bare cartilage as possible with exception of the arytenoids, to reduce the risk of airway obstruction, is covered. The remaining strap muscles are used to cover the defect and the skin is closed leaving a suction drain. A nasogastric feeding tube is left behind. Postoperatively, oral feeding is started at day 7; the tracheostomy is also removed at that time if this is considered safe.



## *Results*

### Group I, CO<sub>2</sub>-laser surgery.

Results are summarized in table III. Forty-two patients were treated with laser surgery for recurrent disease after radiotherapy. Follow-up after first laser surgery ranged from 17 months to 215 months (average 77 months). Although strictly a contraindication for laser surgery, 18 patients had tumour extending into the anterior commissure. The reason for this was before 1997, an external procedure was not offered, and patients refused a total laryngectomy for relatively small tumours. A total of 42 patients were treated with laser surgery. After first laser surgery, 20 patients developed a recurrence, and 22 patients remained tumour free after one or two laser procedures. In 24 cases, the patients met the criteria (table 1) strictly (no extension of tumour in the anterior commissure). Fourteen patients were cured with one laser treatment and 10 patients developed a recurrence. One patient with a second recurrence was cured with a second laser treatment and, the other nine were managed with a total laryngectomy. One patient had a recurrence after total laryngectomy and died of his disease. The recurrences occurred between 1 to 48 months after laser treatment (average, 13 months). It must be noted, however, that although the criteria for laser surgery were met in this group of patients, a number of them would have currently been treated through an external approach, mostly because of tumour volume.

In the subgroup of patients (n=18) with tumour extending into the anterior commissure, eight patients were cured with one or more laser procedures; 10 patients went on to have a total laryngectomy for a new recurrence

### *Complications*

Two patients with tumour extending in the anterior commissure had a chondritis of the thyroid cartilage develop. One patient was successfully treated with antibiotics and the other required surgical intervention; both patients retained their larynx. No other complications were seen.

### *Functional follow up*

There were no functional problems observed in this group. None of the patients needed a tracheostomy or a nasogastric tube. Most of the patients left the hospital the day after the operation.

## Group 2, Frontolateral partial laryngectomy

Results are summarized in table IV. Twenty-one patients were treated with a frontolateral procedure. Follow up ranged from 16 to 62 months (average, 41 months). One patient was treated with a total laryngectomy 2 weeks after the partial laryngectomy because of residual tumour in the operative margins on final pathologic examination, although peri-operative frozen sections had been negative. Another patient was converted to a cricothyroidoepiglottopexy (CHEP) in the direct postoperative period for the same reason. Another patient was treated with a total laryngectomy after 6 weeks because of a non-functional larynx. Only three patients had a recurrence, 4 to 5 months after surgery. They were successfully treated with a total laryngectomy (10 months - 3 years follow up). Twelve patients are still alive with no evidence of disease after a frontolateral laryngectomy. One patient died of heart failure 1.5 years after the operation, with no evidence of disease at time of death. One patient died 4 weeks after the operation due to heart failure after a period of severe untreated dyspnoea. Two patients had a neck recurrence, one in level 2 and the other in level 6. One patient chose not to be treated and died with the recurrence. The other patient is still alive with no local recurrence.

### *Complications*

In the direct postoperative period, we had one case of postoperative haemorrhage. One patient suffered from a postoperative pulmonary infection, which was treated with antibiotics. Two patients developed a laryngeal-coetaneous fistula, which closed spontaneously within 3 weeks of conservative treatment. The long-term complications (after 3 months) encountered in a total of six patients were persistent dyspnoea (n = 5) and cartilage necrosis (n = 3). Dyspnoea was mainly caused by oedema, and was treated with one or more laser procedures (table V). In two patients, a permanent tracheostomy remains due to secondary fibrosis of the larynx. All cases of cartilage necrosis were successfully treated by minor sequesterostomy and antibiotics.

### *Functional follow-up*

Postoperatively, the tracheostomy was removed after 5 to 26 days (median 10 days). In two patients the period of tracheostomy was prolonged (45 and 58 days) because of a laryngeal coetaneous fistula and dyspnoea. The nasogastric feeding tube was removed after 12 days (range, 1-34 days). All the patients resumed a non-restricted full oral diet within days of removal of the feeding tube. The average length of the hospital stay was twelve days (range, 7-28 days). With a questionnaire, we investigated whether the patients were satisfied with their voice after the operation. Fourteen patients were satisfied with their voice and suffered no social inconvenience. Only one patient with a whispering voice was not satisfied. All patients had a non-restricted full oral diet. (table VI)

## *Discussion*

The standard treatment for recurrent glottic carcinoma after radiotherapy is a total laryngectomy. This study shows, however, that in selected cases, a partial procedure is safe and effective. In our clinic, laser surgery, frontolateral partial laryngectomy, and CHEP are the main partial procedures performed after radiation failure. Selection of patients and choice of the right procedure are the key issues. A guideline is presented in figure I.

In the period of 1980-1996, 42 patients with a glottic recurrence were treated with CO<sub>2</sub>-laser. This is a relatively small group, but recurrences after radiotherapy for T1 or T2 glottic tumours occur in only 5% to 20% and 25% to 30%<sup>6,9</sup> respectively, and only a small portion of these qualify for laser surgery. Although the results of primary treatment of small glottic carcinoma with CO<sub>2</sub>-laser surgery are well documented,<sup>10-13</sup> few reports deal with laser treatment of recurrent glottic carcinoma after radiation therapy. If the criteria were strictly met, in our study more than 52% of the patients retained their larynx when treated by laser surgery. Only one patient in this group died of disease after total laryngectomy for a further recurrence, suggesting that little or no extra risk is involved for the patient. Our results are similar to those of CO<sub>2</sub>-laser treatment of recurrent glottic carcinoma reported in the literature. Blakeslee et al<sup>14</sup> reported a 40% success rate and thinks that extension of the tumour into the anterior commissure is a contraindication for laser surgery. Casiano et al<sup>15</sup> found a 5-year cure rate of 51% in previously irradiated patients, and the success rate was reduced (45% vs. 65%) if the anterior commissure was involved. Outzen and Illum<sup>16</sup> reported similar results. After salvage procedures, a 5-year cure-rate of 98% was achieved. All these reports deal with small a small number of patients, all groups being smaller than 20. Most authors regard extension of the tumour in the anterior commissure a contra-indication to laser surgery. Like Casiano et al<sup>15</sup> we found a higher recurrence rate in anterior commissure involvement (67% vs. 42%) and nearly 60% of these patients finally underwent a total laryngectomy (the others could be salvaged with another partial procedure).

If the tumour extends in the anterior commissure survival is not compromised; however 70% loose their organ due to a new recurrence. These findings firm our opinion that extension into the anterior commissure is a contraindication to laser surgery, and we, therefore, recommend an external procedure. However in patients with poor general health, laser surgery can still offer a good alternative, because of the short surgical time, few complications, and fast rehabilitation. In the frontolateral partial laryngectomy group, we found a control rate of 71%. This is consistent with the literature. Kooper et al<sup>17</sup> found an oncologic control rate of 88%. Other studies report control rates of between 70 and 100%.<sup>5,18-21</sup> Rehabilitation after frontolateral partial laryngectomy was generally rapid; most patients left the hospital within 2 weeks of the operation on a full oral diet with the tracheostomy removed. Complete endolaryngeal wound healing was never completed at that time and was frequently observed to take up to 3 months. Complications were few and well manageable in our series, but the two main concerns after a frontolateral procedure are cartilage necrosis and airway problems. Modification of the surgical technique can mostly prevent these problems.

In the patients that suffered from cartilage necrosis, a substantial area of cartilage had been left uncovered during surgery. Hardillo <sup>22</sup> has shown that healing of bare cartilage has a risk of forming granulation tissue and scar tissue. Therefore, covering the bare cartilage is strongly recommended. For this purpose we prefer to fold the thyro-hyoid muscle with the outer layer of perichondrium attached to it around the remaining cartilage. If all the cartilage cannot be covered, the cartilage may serve as a stent and can easily be removed at a later stage if necessary, but repeat endoscopies may be required to remove granulations and assess tumour control in the meantime. As in supraglottic laryngectomy,<sup>23</sup> denuded cartilage of the arytenoids should however not be covered, because local oedema at the widest part of the larynx will compromise the main airflow. A false vocal cord may be used to reconstruct a vocal cord and/or cover cartilage. For the reason mentioned above this should only be carried out unilaterally.

We investigated the subjective feelings of the patients about the voice and swallowing by means of a questionnaire. Except for one patient, all were satisfied with their voice. They did not have any social inconvenience of their voices. All our patients have a normal diet without any restrictions. Other authors <sup>18,19</sup> also report satisfactory speech and swallowing. An alternative for recurrent laryngeal cancer is a CHEP. This procedure is performed in patients with a bulky tumour or extension in one of the arytenoids. We have performed 11 CHEPs with satisfactory functional results, but these are not reported due to short follow up. In partial laryngectomy procedures, the resection margins cannot be as wide as in total laryngectomy. The use of intraoperative frozen sections is the key to maximum safety. It must be kept in mind that a frozen section of post-irradiation tissue is difficult to examine, and stellate shaped growth or perineural growth may be missed. The pathologist should be aware that a good orientation of the resection margin in the frozen section is of utmost importance, allowing the microscopic examination of the full length of the surface lining epithelium. Failure to achieve this may lead to a false-negative outcome. Diagnostic pitfalls can be squamous cell metaplasia of subepithelial laryngeal glands and ducts. Particularly, necrotizing sialoadenitis may be confused with squamous cell carcinoma leading to a false-positive report. Distinguishing between dysplasia and carcinoma in situ from irradiation related atypia of the lining epithelium might also be difficult in frozen sections. Furthermore, inflammation caused by previous radiotherapy makes the interpretation of frozen sections of the margins difficult. It is extremely important to prepare the patient beforehand, not only for conversion to a total laryngectomy during surgery, but also for the possibility of a re-operation in the direct postoperative phase. Because of the often tight resection margins and to facilitate maximum orientation, frozen sections should be taken from the wound, not from the specimen. The difficult interpretation of the frozen margins is one of the reasons surgeons may decide not to perform partial laryngectomy in radiation failures.<sup>17, 24</sup> The main reasons for us not to routinely perform frozen sections during laser surgery are that the laser evaporates the margin and adds a factor of heat damage. It is also more difficult to obtain adequate tissue from the wound for frozen section.

### *Conclusion*

In conclusion, if the surgeon is familiar with the different techniques of, and indications for, partial laryngectomy, this can be a good and very satisfying treatment in selected patients with glottic cancer who had radiation fail. On the other hand, if the patient or procedure is not selected carefully, this may lead to disaster, and patients should be mentally capable of coping with a possible conversion to total laryngectomy perioperatively or postoperatively.

### *Acknowledgement*

We thank Professor L. Feenstra, MD, PhD, and J. Borgstein, MD, for their kind support.

## References

1. Toma M, Nibu K, Nakao K et al. Partial laryngectomy to treat early glottic cancer after failure of radiation therapy. *Arch Otolaryngol Head Neck Surg.* 2002; 128: 909-912
2. Ferlito A, Silver CE, Howard DJ, Laccourreye O, Rinaldo A, Owen R. The role of partial laryngeal resection in current management of laryngeal cancer: a Collective review. *Acta Otolaryngol.* 2000; 120: 456-465
3. Groome PA, Macckillop WJ, Rothwell DM et al. Management and outcome of glottic cancer: a population-based comparison between Ontario, Canada and the SEER areas of the United States. *Surveillance, Epidemiology and end results.* 2000; 29(2): 67-77
4. Honocodeevar-Boltežar I, Žargi M. Voice quality after radiation therapy for early glottic cancer. *Arch Otolaryngol Head and Neck Surg.* 2000; 126: 1097-1100
5. Nibu K, Kamata S, Kawabata K, Nakamizo M, Nigauri T, Hoki K. Partial laryngectomy in the treatment of radiation-failure of early glottic carcinoma. *Head Neck.* 1997; 19(2): 116-120
6. Moose BD, Greven KM. Definitive radiation management for carcinoma of the glottic larynx. *Otolaryngol Clin North Am.* 1997; 30(1): 131-143
7. Scheck PA, Mallios C, Knegt P, van der Schans EJ. High frequency ventilation in laser surgery of the larynx. *Clin Otolaryngol.* 1984; 9: 203-207
8. Weinstein GS, Laccourreye O. Vertical partial laryngectomys. In: *Organ preservation surgery for laryngeal cancer.* San Diego, California: Singular publishing group, 2000. 59-71
9. Nichols RD, Stine PH, Greenawald KJ. Partial vertical after radiation failure. *Laryngoscope.* 1980; 90(4): 571-575
10. Hirano M, Hirade Y. CO2 laser for treating glottic carcinoma. *Acta Otolaryngol.* 1988; 458: 154-157
11. Mc. Guirt FW, Koufman JA. Endoscopic laser surgery. An alternative in laryngeal cancer treatment. *Arch Otolaryngol Head Neck Surg.* 1987; 113: 501-505
12. Motta G, Esposito E, Cassiano B, Motta S. T1-T2-T3 Glottic tumours : Fifteen years experience with CO2 laser. *Acta Otolaryngol.* 1997; 527: 155-159
13. Wetmore J, Key JM, Suen JY. Laser therapy for T1 glottic carcinoma of the larynx. *Arch Otolaryngol Head Neck Surg.* 1986; 112: 853-855
14. Blakeslee D, Vaughan CW, Shapshay SM, Simpson GT, Strong MS. Excisional biopsy in selective management of T1 glottic cancer: a three-year follow-up study. *Laryngoscope.* 1984; 94: 488-494
15. Casiano RR, Cooper JD, Lundy DS, Chandler JR. Laser cordectomy for T1 glottic carcinoma: A 10-year experience and videostroboscopic findings. *Otolaryngol Head Neck Surg.* 1991; 104: 831-837

16. Outzen KE, Illum P. CO<sub>2</sub>-laser therapy for carcinoma of the larynx. *J Laryngol Otolaryngol*. 1995; 109: 111-113
17. Kooper DP, van den Broek P, Manni JJ, Tiwari RM, Snow GB. Partial vertical laryngectomy for recurrent glottic carcinoma. *Clin Otolaryngol*. 1995; 20: 167-170
18. Watters GW, Patel SG, Rhys-Evans PH. Partial laryngectomy for recurrent laryngeal carcinoma. *Clin Otolaryngol*. 2000; 25(2): 146-152
19. Rodriguez- Cuevas S, Labastida S, Gonzalez D, Briseno L, Cortes H. Partial laryngectomy as salvage surgery for radiation failures in T1-T2 laryngeal cancer. *Head Neck*. 1998; 20(7): 630-633
20. Schwaab G, Mamelle G, Lartigau E, Parise O Jr, Wibault P, Luboinski B. Surgical salvage treatment of T1/T2 glottic carcinoma after failure of radiotherapy. *Am J Surg*. 1994; 168(5): 474-475
21. Nichols RD, Mickelson SA. Partial laryngectomy after irradiation failure. *Ann Otol Laryngol*. 1991; 100(3): 176-180
22. Hardillo J. Tracheal repair: from wound healing research to prefabricated reconstruction. Katholiek Universiteit Leuven, Leuven Belgium. Thesis. 2001
23. Herranz J, Martinez-Vidal J, Gavilan J. Horizontal supraglottic laryngectomy: modifications to Alonso's technique. *Operative techniques in otolaryngology-head and neck surgery*. 1993; 4(4): 252-257
24. Lavey RS, Calcatera TC. Partial laryngectomy for glottic cancer after high-dose radiotherapy. *Am J Surg*. 1991; 162(4): 341-344

## Table I

### Indications for CO<sub>2</sub>-laser surgery.

- Limitation of the tumour to the glottis
- Limited supraglottic extension
- No subglottic extension
- Normal mobility of both vocal cords
- No extension in the anterior commissure
- Complete endoscopic tumour visualization

## Table II

### Indications for the frontolateral partial laryngectomy

- Tumour limited to the glottis
  - Limited supraglottic extension
  - Limited subglottic extension (1cm)
- Extension in the anterior commissure
- Normal vocal cord mobility
- No cartilage involvement
- No arytenoids involvement



**Table III Results of CO<sub>2</sub>-laser treatment**

Involvement of anterior commissure	N	CO <sub>2</sub> -laser successful	Salvage total laryngectomy after CO <sub>2</sub> -laser failure	Failure of salvage total laryngectomy
No involvement	24	14	9	1
Involvement	18	8	8	2

**Table IV Oncologic follow-up frontolateral partial laryngectomy**

Disease free	15
Post-operatively converted	3
Recurrence	3

\*: In 3 patients there was no evidence of disease at time of death.

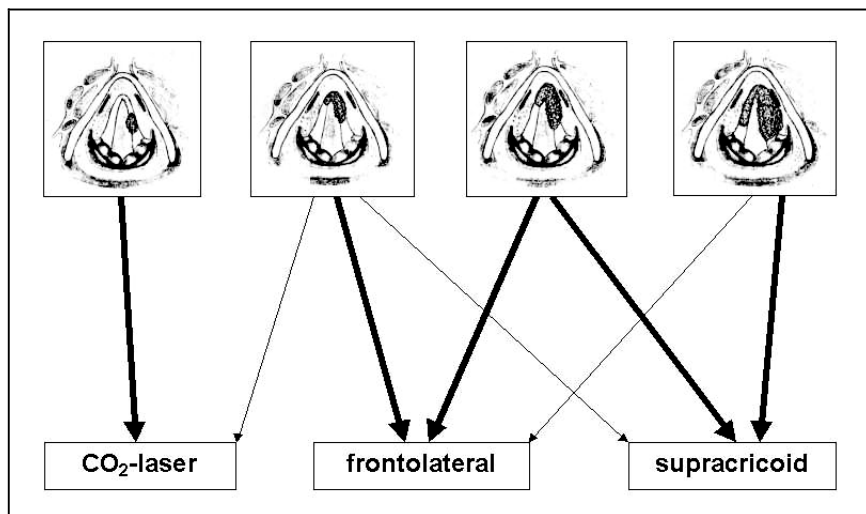
**Table V**            **Number of and the reason for endoscopies frontolateral partial laryngectomy**

Dyspnoea	8
Granulation tissue	3
Recurrent	3

**Table VI**            **Functional results after frontolateral partial laryngectomy**

Airway	N=13 no airway problems N= 2 permanent tracheostomy
Swallowing	All patients (N=15) have a non-restricted full oral diet
Speech	N=14 satisfied with their speech N=1 whispering voice

Figure 1



Guideline for selection of patients and choice of the right procedure.



## **Chapter III**

Supracricoid partial laryngectomy with Cricohyoidoepiglottopexy for recurrent laryngeal cancer

A.Sewnaik, M. Hakkesteegt, CA Meeuwis, HHW de Gier, JDF Kerrebijn

Accepted for publication: *Annals of Otolaryngology, Rhinology & Laryngology*

## **Abstract**

**Background:** Recurrent laryngeal cancer can either be treated with a total laryngectomy or in selected cases with a supracricoid laryngectomy with cricothyroidopiglottopexy (CHEP).

**Objective:** To analyze the functional and oncological results of the supracricoid laryngectomy with CHEP.

**Study design:** Retrospective study

**Methods:** Fourteen patients were treated with a supracricoid laryngectomy with CHEP. In 8 patients a flexible endoscopic evaluation of swallowing was performed. Pre-and post-operative voice evaluation was performed in 5 patients. Oncologic and functional follow up, post-operative complications, and data concerning rehabilitation were recorded on standard forms

**Results:** After the supracricoid laryngectomy with CHEP, 11 out of 14 patients are alive and disease free. No local recurrences were found, but 2 had regional recurrences. The voice is worse after the operation; however, most patients are satisfied. Swallowing was uncompromised.

**Conclusion:** Supracricoid laryngectomy with Cricothyroidopiglottopexy (CHEP) for recurrent glottic laryngeal cancer after radiotherapy appears to be oncologically safe and functional.

**Keywords:** cricothyroidopiglottopexy, recurrent glottic cancer, voice, swallowing

## **Introduction**

Recurrent laryngeal cancer can either be treated with a total laryngectomy or in selected cases with a partial laryngectomy. A partial laryngectomy is unlike a total laryngectomy, not a well-defined operation but a term nominating a variety of procedures all aimed at preserving part of the larynx. These procedures include endoscopic laser resection; horizontal partial laryngectomy (supraglottic partial procedures); vertical (hemi-, fronto-lateral) partial laryngectomy; and supracricoid procedures (cricohyoidoepiglottopexy, cricohyoidopexy). The three techniques most commonly used by us in case of recurrent laryngeal cancer are CO<sub>2</sub> laser surgery, frontolateral partial laryngectomy and supracricoid laryngectomy with cricohyoidoepiglottopexy (CHEP). The first two procedures were reported in an earlier paper.<sup>1</sup> This paper addresses the third technique, the supracricoid partial laryngectomy with cricohyoidoepiglottopexy (CHEP).

The supracricoid laryngectomy with CHEP is mostly used for treatment for selected primary glottic laryngeal cancers.<sup>2-5</sup> The goal of this technique is a total removal of the tumour, while creating a new functional larynx, which is adequate for swallowing and speaking.

The oncologic results after the supracricoid laryngectomy for primary laryngeal cancer are good. The reported 5-year survival in the literature varies from 84% to 96%.<sup>2,4,6,7</sup> There are not many studies<sup>8,9,10</sup> reporting results of the supracricoid laryngectomy for treatment of recurrent laryngeal cancer. However, in these studies the reported oncologic results are good. The 3-year survival rate in these studies varied from 83% to 100%.

With this technique the function of the larynx, swallowing and speaking are preserved. However, at least some impairment of especially the voice cannot be avoided.

The voice after the supracricoid laryngectomy with CHEP is always hoarse compared to normal speakers. The vocal cords, which are routinely removed during the operation, are critical for a high quality of voice.<sup>5</sup> The quality of the voice after the supracricoid laryngectomy with CHEP also depends on preservation of either one or two arytenoids. Swallowing after CHEP treatment for primary carcinoma is generally reported to be normal. However, Dworkin et al<sup>11</sup> pointed out that patients who had supracricoid laryngectomy required specific swallowing exercises, before the feeding tube safely could be removed. There are no data available for patients who had previous radiotherapy. This study presents the functional and oncological results of patients treated with a supracricoid laryngectomy with cricohyoidoepiglottopexy after radiation failure.

## **Material and methods**

Between 2000 and 2004, 14 patients were treated with a supracricoid laryngectomy with cricohyoidoepiglottopexy (CHEP) at the department of Otolaryngology Head and Neck Surgery of the Erasmus Medical Centre Rotterdam in the Netherlands for recurrent glottic carcinoma. None of the patients were treated with a supracricoid laryngectomy with cricohyoidopexy (CHP). In all cases the primary tumour had been treated with

radiotherapy (66 Gy, in 2-Gy fractions, 5 or 6 times per week). The group consisted of 12 men and 2 women. Ages ranged from 49 to 79 years.

Oncologic and functional follow up, post-operative complications, and data concerning rehabilitation (duration of tracheostomy and nasogastric tube) were recorded on standard forms. Information concerning location, TNM classification and radiation dose of the primary tumours are listed in table I. Routine work-up prior to salvage surgery consisted of a chest X-ray and an ultrasound of the neck, if indicated, combined with fine-needle aspiration. Only in selected cases a CT scan was performed.

### *Supracricoid laryngectomy with Cricohyoidoepiglottopexy*

Indications for supracricoid laryngectomy with CHEP after previous radiotherapy are listed in table II. If the recurrent tumour is limited to the vocal cords with little supra- or subglottic extension, normal vocal cord mobility and extension in the anterior commissure an external frontolateral partial laryngectomy can be performed. A supracricoid laryngectomy is treatment of choice if extension into the paraglottic space is suspected or there is tumour spread onto the mucosa of one of the arytenoids. Another reason to consider a supracricoid laryngectomy is a pre existent narrow airway due to anatomy (females) or oedema.

The procedure has extensively been described elsewhere,<sup>12</sup> and differs in previously irradiated patients only in a few details different from primary procedures. After an endoscopy the supracricoid laryngectomy is started with an apron like incision of the skin after which skin-platysma flaps are raised. The strap muscles are divided in the midline, detached from the hyoid bone and retracted laterally. The superior laryngeal arteries and veins are ligated, but the nerves are preserved. The thyroid isthmus is then divided and the thyroid lobes are partially separated from the trachea, taking care not to damage the recurrent nerves. A downward blunt dissection of the trachea is performed to permit upward displacement at the time of closure. This part of the operation is different for irradiated patients. In previous irradiated patients, there is more fibrosis and the trachea must be mobilized deeper into the thorax, however in some cases this might not even be enough for a tensionless closure of the pexie. The constrictor muscles are separated from the thyroid cartilage and the pyriform sinuses are mobilized. The larynx is entered between the thyroid cartilage and hyoid bone, going through the base of the epiglottis and through the pre-epiglottic space. A second entrance is made by an incision through the cricothyroid membrane. At this time the orotracheal tube is removed and inserted through the inferior incision. The thyroid is mobilized from the cricoid by disarticulation from the thyrocricoid joints, or by cutting the inferior horns of the thyroid cartilage, which reduces the chance of damaging the recurrent laryngeal nerves. From superiorly and with the tumour in view, the entire thyroid cartilage with both vocal cords, including the tumour, are removed. At least one, but preferably both, innervated arytenoid complexes are left. Frozen sections are taken from the wound edges. After approximation of the cricoid and hyoid, the level of the tracheotomy can be established and a tracheotomy is performed. To facilitate swallowing, the bases of the arytenoids are sutured downwards and medially, and a suspension suture is put through the pyriform sinus on either side that will be cross-tied after final approximation of the



cricoid to the hyoid. Three zero silk or vicryl sutures are placed around the cricoid and hyoid, one in the midline and the others 1cm to either side. These are used to bring these structures together. Coming around the hyoid, the sutures should also be looped through the base of tongue for better positioning of the larynx. If the cricoid and hyoid cannot be brought together tensionless, which is essential in irradiated patients, partial release of the hyoid bone from the muscles of the floor of the mouth and especially detachment of the stylohyoid ligament can be performed. This is usually not necessary, and even contraindicated in primary procedures. The strap muscles are sutured together and the skin is closed leaving a suction drain. Contrary to primary supraccricoid procedures, in previously irradiated patients we prefer to continue antibiotics (Amoxicilline Clavulanate Potassium, 3 daily doses of 1.2 g for 1 week, followed by 3 daily doses of 625 mg) post-operatively for 4-6 weeks, because of delayed wound healing.

### *Flexible endoscopic evaluation of swallowing (FEES) <sup>13</sup>*

At least 3 months after the operation swallowing was evaluated in 8 patients. A thorough history of swallowing was obtained and a FEES was performed. A speech pathologist and the author performed the FEES. Equipment necessary to perform a FEES includes a flexible fiberoptic endoscope (Pentax Medical Company, Montvale, New Jersey) attached to Alphascope 2000 (Alphascope Medical Systems, Rotterdam), which consist of a light source, a digital camera and a monitor and was used for recording. For the endoscopic evaluation, the patient was positioned seated upright in a chair. The flexible endoscope was inserted via the nose and advanced until the tip was in the oropharynx. From this point, the management of colored water, yoghurt and crackers was assessed. The items scored with the FEES were: premature spillage of material, pharyngeal residue of material, penetration and aspiration. After the FEES a form with the above mentioned points were filled in.

#### *Evaluation of the voice*

Five patients underwent pre- and post-operative voice evaluation. This was performed by the speech pathologist.

Recordings were made in a quiet room on a Sony Digital Audio Tape recorder (DTC-57ES) (Tokyo, Japan) with a Sennheiser microphone (BG 2.0 dynamic) (Wedemark, Germany). The distance between the patient (mouth) and microphone was 30 cm. Intensity and frequency measurements were obtained with an automatically recording phonetograph (Pabon/Laryngograph 1997, London, England). The Multi-Speech program (Kay Pentax, Lincoln Park, New Jersey) was used for calculating Harmonics to Noise Ratio (HNR). A stopwatch was used for measuring the maximum phonation time.

The following measurements of the voice were performed:

1. *Perceptual Voice Analysis*

Recordings were made of a short reading text and a short sample of conversational speech. The samples were evaluated by another, independent, speech pathologist. The pre- and postoperative samples of one patient were played in random order. The hoarseness of the voice quality was evaluated and the voices were compared and judged as better, worse or the same.

2. *Maximum Phonation Time (MPT)*

The subjects were asked to inhale deeply and sustain an /a/ for as long as possible at a comfortable pitch and loudness. This was recorded three times; the longest phonation time was used.

3. *Harmonics to Noise Ratio (HNR)*

The subjects phonated on /a/ at a comfortable pitch and loudness during approximately 3 seconds. The HNR were calculated on a sample of one second, starting half a second post voice onset.

4. *Intensity and frequency measurements*

If possible a phonetogram was made.<sup>14</sup>

## *Results*

Fourteen patients were treated with a supracricoid laryngectomy with cricohyoidoepiglottopexy. Six patients also underwent a selective neck dissection (levels 2,3,4).

The follow-up period is on average sixteen months (range 3-41 months). In total eleven patients are still alive and are disease-free. (Table III) Local recurrences have not occurred in any of the patients so far. Two patients developed a regional recurrence in the neck. The first patient had a neck recurrence 8 months after the operation. He chose not to be treated and died 3 months later. The second patient had the recurrence after 3 months and a neck dissection was performed. In the same patient a pulmonary metastasis was discovered 9 months after the supracricoid laryngectomy with CHEP and died 3 months later.

One patient died 5 months after the operation due to heart failure.

At time of death, he was disease free.

The average length of the hospital stay was eighteen days (range 11-35 days).

Postoperatively, the tracheostomy was removed after 12 to 365 days (median 74 days).

The reason for this is that in previous irradiated patients the wound healing is delayed sometimes resulting in late airway obstruction due to oedema or infection. We experienced this in patients treated with the fronto-lateral partial laryngectomy.<sup>1</sup> The canula is mostly corked after one week. On average, the nasogastric feeding tube was removed after forty-five days (range 10-120 days). During this period the patients followed an intensive swallowing rehabilitation program supervised by an experienced speech-swallowing pathologist. However, all patients went on to a non-restricted full oral diet before removal of the feeding tube.

In the direct postoperative period, we had one case of postoperative haemorrhage. One patient suffered from a postoperative pulmonary infection, which was treated with antibiotics. One patient, who also had a poor pulmonary status and did not understand the rehabilitation instructions, had a total laryngectomy because of severe aspiration after three months. Long-term complications were seen in three patients. Two patients suffered of dyspnoea due to oedema. Both patients were treated with laser surgery. Both patients had a prolonged temporary tracheotomy. The tracheostomies were removed after 12 months. In one patient granulation tissue imposing as tumour was seen at the pexie. This was felt to be due to the use of PDS sutures instead of vicryl for the pexie site.

Eight patients were evaluated for post-operative swallowing function. The period between the operation and the evaluation ranged from 2 to 40 months (average 18 months). One patient had recently undergone hip surgery and was not able to visit our clinic during the study. The other patient recently had CO2 laser surgery (see above) of the larynx for oedema.

All patients questioned were on a non-restricted oral diet. Two patients mentioned regular aspiration. Four patients had aspiration sometimes, and 2 patients say they never aspirated. Of the patients aspirating, 3 aspirated while drinking fluids and 3 after eating solids. With the FEES, we could not confirm aspiration of solids or fluid in any of the patients. After swallowing colored water, 1 patient had residual in the pharynx. This was gone after swallowing once more. After eating yoghurt residual in the pharynx was

seen in 4 patients. Also after swallowing once more, the residual was gone in all patients. After eating a cracker, only in 1 patient had residue in the pharynx. In none of the patients was penetration or aspiration seen after ingestion of water, yoghurt or crackers. These results are shown in table IV.

Eight patients are subjectively satisfied with their voice. Two patients with a whispering voice are dissatisfied. Five patients had pre- and post-operative evaluation of the voice. The results are listed in table V. One patient had such a poor voice after the operation that the measurements could not be performed.

The harmonics noise ratio was also worse in three patients after the operation.

The perceptual voice analysis was worse after the operation in all the patients.

The maximum phonation time was worse in 2 patients. Intensity and frequency measurements (phonetograms) were not possible because of the poor voice quality.

## *Discussion*

The gold standard treatment for recurrent glottic carcinoma after radiotherapy is a total laryngectomy, however in selected patients a partial laryngectomy may be considered. Besides CO<sub>2</sub>-laser resection and fronto-lateral partial laryngectomy,<sup>1</sup> supracricoid laryngectomy with cricohyoidoepiglottopexy (CHEP) was shown to be a reliable treatment method as long as the indications are respected. Besides the criteria as listed before, other factors especially pulmonary status and diabetes play an important role in the decision if a supracricoid laryngectomy with CHEP may be performed. The patients should have a relatively good general condition. Prior to the operation all patients are informed about the relatively long rehabilitation period. Before the operation it should also be discussed with the patient that during the procedure a conversion to a total laryngectomy may be necessary if the tumour turns out to be too extensive or if the frozen section of the margins are positive. It is very important is that the patients understand and agree with this.

The follow up in our study is relatively short but so far we have seen no local recurrences. The disease free survival in the literature of the supracricoid laryngectomy with CHEP after radiotherapy vary from 83-100%.<sup>8-10</sup> But also in these studies the follow-up period is also relatively short ( 36 months<sup>10</sup>) and the patient groups are small. The largest group was fifteen patients.<sup>10</sup> This is understandable because the selection criteria for the supracricoid laryngectomy after irradiation failure are strict and should be followed without concessions.

The technique<sup>12</sup> of the supracricoid laryngectomy is not very different in case of previous radiotherapy. The main difference lies in the superior relaxation of the hyoid bone, which may be necessary to obtain tensionless closure and a long continuation of antibiotics. In this study decannulation was performed on average after 45 days. In most studies decannulation was performed earlier. We left the tracheostomy for a longer period of time for safety purposes, because of the delayed wound healing and the vulnerability to infections after radiotherapy.<sup>9</sup> Lacourreye et al<sup>9</sup> described increased duration of tracheostomy after supracricoid laryngectomy in previous irradiated patients. The increased duration was related to significant postoperative oedema at the level of the remaining arytenoids cartilage and the healing delay induced by radiotherapy.

The canula is closed off generally after one week but left in situ to minimize the risk of acute airway obstruction due to oedema caused by inflammation. A rule of thumb is that 80% of wound healing is completed before the tracheotomy is removed.

After supracricoid laryngectomy with CHEP patients retain all normal laryngeal functions. However the quality of voice is negatively affected by the operation. After the supracricoid laryngectomy vibrating mucosa on the anterior surface of the arytenoids generates the voice. If one arytenoid is present, the mucosal wave can be seen between the mucosa of the arytenoids and the epiglottis. If both arytenoids are present, the mucosal wave is seen between the arytenoids and between the arytenoids and the epiglottis.<sup>5</sup> The voice is evaluated with questionnaires and objectified with measurements such as maximum phonation time. Spriano et al<sup>10</sup> evaluated the voice by measuring the maximum phonation time ( 3 to 18 s; mean: 8,3 s) and found this to be shorter comparing it to normal adult speakers.

We have made an attempt to qualify loss of voice in this study. Our study, using perceptual voice analysis, confirms that the quality of the voice is worse than before after supracricoid laryngectomy with CHEP in most cases. However, the perceptual voice analysis is limited with one evaluator and this might be a potential weakness of this study. The maximum phonation time we found varies from 6 to 16s (normal: 19s);<sup>15</sup> which was also found by Spriano.<sup>10</sup> The negative value of the harmonics to noise ratio (more noise than harmonics) also indicates a relatively poor voice. One could expect that most patients experience difficulties while speaking and would therefore be dissatisfied with their voice, however most patients in this study are subjectively satisfied with their voice. An explanation could be that most patients are elderly and do not use their voice professionally. None of our patients complain problems of swallowing. At the time of assessment all patients were on a non-restricted oral diet. However, all but one patient had a long swallowing rehabilitation period after the operation. The nasogastric tube was removed after an average of 45 days. Most studies addressing supracricoid laryngectomy with CHEP as primary treatment<sup>11,16</sup> reports an earlier removal of the nasogastric tube (average 23 days). However, all patients needed an extensive swallowing rehabilitation program supervised by a speech pathologist. The longer after the operation, the better the swallowing gets. None of the patients mentioned aspiration on a regular base, which was confirmed by FEES. This is an encouraging fact, but we should keep in mind that most patients were studied after a relatively long period postoperatively. Dworkin et al<sup>11</sup> also performed FEES after the supracricoid laryngectomy with CHEP with worse results. He found a moderate degree of premature spillage into the valleculae, chronic pooling of food residuals and mucous secretions within the hypopharynx that leaked into the larynx. This caused excessive throat clearing and coughing episodes. The reason for this might be that they performed the FEES earlier after the operation. Also, patients are probably more concentrated on swallowing during FEES and therefore a good result might underestimate the reality. Other studies<sup>16,17</sup> also find good swallowing after CHEP. However, these studies were performed by questionnaires and were performed in non-irradiated patients.

In conclusion, supracricoid laryngectomy with cricohyoidoepiglottopexy for recurrent glottic laryngeal cancer after radiotherapy appears to be oncologically safe and functional. However, all patients have a prolonged, intensive rehabilitation period and therefore not only tumour characteristics, also patient characteristics, should be considered before deciding to perform a supracricoid laryngectomy with CHEP after radiotherapy.

### *Acknowledgments*

The authors thank Professor L. Feenstra, MD, PhD for his helpful comments in preparing this paper

## References

1. Sewnaik A, Meeuwis CA, van der Kwast TH, Kerrebijn JDF. Partial laryngectomy for recurrent glottic carcinoma after radiotherapy. *Head Neck*. 2005; 27(2): 101-107
2. Bron L, Brossard E, Monnier P, Pasche P. Supracricoid partial laryngectomy with cricothyroidopexy and cricothyroidopexy for glottic and supraglottic carcinomas. *Laryngoscope*. 2000; 110: 627-634
3. Bron L, Pasche P, Brossard E, Monnier P, Schweitzer V. Functional analysis after supracricoid partial laryngectomy with cricothyroidopexy. *Laryngoscope*. 2002; 112: 1289-1293
4. Karasalioglu AR, Yagiz R, Tas A, Uzun C, Adalli MK, Korten M. Supracricoid partial laryngectomy with cricothyroidopexy and cricothyroidopexy: functional and oncological results. *J Laryngol and Otol*. 2004; 118: 671-675
5. Weinstein GS, Laccoureye O, Ruiz C, Dooley P, Challian A, Mirza N. Larynx preservation with supracricoid partial laryngectomy with cricothyroidopexy. Correlation of videostroboscopic findings and voice parameters. *Ann Otol Rhinol Laryngol*. 2002; 111: 1-7
6. Piquet JJ, Chevalier D. Subtotal laryngectomy with cricothyroidopexy for the treatment of extended glottic carcinomas. *Am J Surg*. 1991; 162: 357-361
7. Chevalier D, Laccoureye O, Brasnu D, Laccoureye H, Piquet JJ. Cricothyroidopexy for glottic carcinoma with fixation or impaired motion of the true vocal cord: 5-year oncologic result with 112 patients. *Ann Otol Rhinol Laryngol*. 1997; 106: 364-369
8. Schwaab G, Mamelle G, Lartigau E, Parise O Jr, Wibault P, Lubinski B. Surgical salvage treatment of T1/T2 glottic carcinoma after failure of radiotherapy. *Am J Surg*. 1994; 168(5): 474-475
9. Laccoureye O, Weinstein GS, Naudo P, Cauchois R, Laccoureye H, Brasnu D. Supracricoid partial laryngectomy after failed laryngeal radiation therapy. *Laryngoscope*. 1996; 106(4): 495-498
10. Spriano G, Pellini R, Romano G, Muscatello L, Roselli R. Supracricoid partial laryngectomy as salvage surgery after radiation failure. *Head Neck*. 2002; 24(8): 759-764
11. Dworkin JP, Meleca RJ, Zacharek MA et al. Voice and deglutition functions after the supracricoid and total laryngectomy procedures for advanced stage laryngeal carcinoma. *Otolaryngol head neck surg*. 2003; 129(4): 311-320
12. Laccoureye O, Laccoureye H, El-Sawy M, Weinstein GS. Supracricoid partial laryngectomy with cricothyroidopexy. In: *Organ preservation surgery for laryngeal cancer*. San Diego, California: Singular publishing group, 2000; 53-94
13. Langmore SE. *Endoscopic evaluation and treatment of swallowing disorders*. New York: Thieme medical Publishers, Inc; 2001; 73-143
14. Schutte HK, Seidner W. Recommendation by the Union of European Phoniaticians (UEP): standardizing voice area measurement-/phonetography. *Folia Phoniatr (Basel)*. 1983; 35(6): 286-288.

15. Wuyts FL, De Bodt MS, Molenberghs G, et al. The dysphonia severity index: an objective measure of vocal quality based on a multiparameter approach. *J Speech Lang Hear Res.* 2000; 43(3): 796-809
16. Luna-Ortiz K, Nunez-Valencia ER, Tamez-Velarde M, Granados-Garcia M. Quality of life and functional evaluation after supracricoid partial laryngectomy with cricohyoidoepiglottopexy in Mexican patients. *J Laryngol Otol.* 2004; 118: 284-288
17. De Vincentiis M, Minni A, Gallo A, Di Nardo A. Supracricoid partial laryngectomies: oncological and functional results. *Head Neck.* 1998; 20:504-509
18. Ferrand CT. Harmonics-to-noise ratio: an index of vocal aging. *J Voice.* 2002; 16(4): 480-87



**Table I**                      **Patient characteristics (N = 14)**

<b>Localization</b>	<b>T stage</b>	<b>N stage</b>	<b>Radiotherapy</b>
<b>Glottic: 14</b>	<b>Tis: 1</b> <b>T1: 6</b> <b>T2: 7</b>	<b>N0: 14</b>	<b>66Gy: 14</b>

**Table II**                      **Indications for the supracricoid laryngectomy with cricohyoidoepiglottopexy (CHEP)**

- Tumour limited to the glottis**
  - Limited supraglottic extension**
  - Limited subglottic extension (1cm)**
- Extension in the anterior commissure**
- Normal vocal cord mobility**
- Extension into the paraglottic space**
- Extension onto mucosa of one of the arytenoids possible**

**Table III**                      **Oncologic follow up supracricoid laryngectomy  
with cricohyoidoepiglottopexy (CHEP)**

Disease free and alive	10
Post-operatively converted	1
Recurrence	local: 0 regional: 2 distant: 1

**Table IV**                      **Result of Flexible Endoscopic Evaluation of Swallowing  
(FEES)  
N = 8**

	Water N =	Yoghurt N =	Cracker N =
Premature spillage	0	0	0
Pharyngeal residue	1	4	1
Penetration	0	0	0
Aspiration	0	0	0

Table V                      Voice Measurements  
N = 5

Patie nt	HNR (dB)		MPT (s)		Perceptual	
	pre	Post	pre	post	Pre	Post
1	-3.14	-0.76	11	16	Moderate to severe hoarseness	Worse, softer, weaker
2	-9.05	*	5	*	Moderate to severe hoarseness	Worse, aphonic
3	-5.14	-7.65	10	6	Moderate to severe hoarseness	Worse, weaker
4	-7.75	-11.12	8	8	Severe hoarseness	Worse, more effort,
5	-3.83	-11.36	8	10	Severe hoarseness	Worse, weaker

\* Measurements not possible

Normal values:

HNR: > 7,3 dB <sup>18</sup>

MPT: 19s <sup>15</sup>



## **Chapter IV**

Surgery for recurrent laryngeal carcinoma after radiotherapy:  
Partial laryngectomy or total laryngectomy for a better quality of life?

A. Sewnaik, J.L. van den Brink, M.H. Wieringa, C.A. Meeuwis, JDF. Kerrebijn,

Otolaryngology Head and Neck Surgery. 2005; 132: 95-98

## **Abstract**

**Objective:** To investigate the quality of life after partial laryngectomy versus total laryngectomy for recurrent laryngeal carcinomas after radiotherapy.

**Study design and setting:** A retrospective study performed at least one year after treatment. This study was performed in a university hospital.

**Results:** Twenty-three patients (N=12 partial laryngectomy, N=11 total laryngectomy) with recurrent laryngeal cancer after radiotherapy were included in the study. Three different questionnaires: (1) EORTC Quality of Life Questionnaire (QLQ) – C30 Dutch version 3.0, (2) EORTC – H & N 35 and (3) the Voice Handicap Index, were sent to all patients. The only major difference in quality of life of patients after partial laryngectomy versus total laryngectomy was found to be smell and taste related. No other differences were found.

**Conclusion:** We did not find much difference in quality of life after treatment with a partial laryngectomy or a total laryngectomy in patients with recurrent laryngeal cancer after radiotherapy.

## Introduction

Cancer of the larynx is the most common of the cancers of the head and neck carcinomas in the Netherlands. The primary treatment of T1-T3 laryngeal carcinomas is radiotherapy, while for T4 carcinomas treatment may either be accelerated radiotherapy or surgery combined with radiotherapy, depending on the extent of the tumor.<sup>1</sup> The rate of recurrences after radiotherapy ranges from 11% to 73% and is strongly dependent on the T stage of the primary tumor.<sup>2</sup> The gold standard for treatment of recurrent laryngeal carcinoma of the glottis after radiotherapy is a total laryngectomy. However in selected cases a partial laryngectomy can be performed. In our clinic three different partial procedures (endoscopic laser surgery, frontolateral partial laryngectomy, and supracricoid partial laryngectomy) are performed as salvage surgery after radiotherapy failure.

The treatment of laryngeal cancer has a great impact on a person's life. In particular, total laryngectomy affects crucial functions such as breathing, swallowing, and speaking.<sup>3</sup>

Relic et al<sup>4</sup> described that reactions to illness and treatment not only depend on the patient's physical situation but also vary according to factors such as personality, profession, age, cultural environment, and social status, even when patients undergo the same treatment and gain similar functional outcome. Patients can show a positive attitude towards their illness, while they can suffer greatly from the slightest change in their voice. Individuals who use their voice frequently, for example for work, are more affected than others after a total laryngectomy. Another aspect that changes after a total laryngectomy is the presence of a permanent tracheostoma with mucus visible. There is a cosmetic aspect and some activities, such as swimming (*and smoking!!*), cannot easily be done. Furthermore, after a total laryngectomy the sense of smell is lost. This is different after a partial procedure. However, in our experience a partial procedure, especially in case of cricohyoidoepiglottopexy requires a longer rehabilitation period, compared to total laryngectomy.<sup>5,6</sup>

If another treatment modality than the "gold standard" is chosen, the initial debate focuses on oncological results of this treatment. Our results<sup>7</sup>, and those of others,<sup>2,8,9</sup> after a partial procedure for recurrent carcinomas are oncologically satisfactory. Several studies<sup>10-12</sup> address the quality of life in patients with primary laryngeal cancer. In these studies the quality of life (QoL) after various treatment modalities for primary laryngeal cancers, such as radiotherapy, partial laryngectomy and total laryngectomy are compared. A better QoL after a partial procedure is found compared to a total laryngectomy. Müller et al<sup>10</sup> also found a better QoL both after a partial procedure, and after radiotherapy. The patients had a significant better global health status, role and social functioning. They did, however, compare QoL between partial laryngectomy and other treatment modalities in patients with primary laryngeal cancer. To our knowledge, our study is the first that investigates the quality of life after partial laryngectomy versus total laryngectomy for recurrent cancer of the larynx.

## Material and methods

A questionnaire was sent to 34 patients who had been treated for recurrent cancer of the larynx. Twenty-three questionnaires were filled in and returned. This group consisted of 12 patients treated with a partial procedure and 11 patients after a total laryngectomy. In the group of partial procedures 7 patients were treated with a frontolateral partial laryngectomy and 5 patients with supracricoid partial laryngectomy. Patients were treated with a total laryngectomy because they did not meet our selection criteria for a partial laryngectomy. These selection criteria are described in another paper.<sup>7</sup>

Three different questionnaires were sent to all patients: 1) EORTC Quality of Life Questionnaire (QLQ) – C30 Dutch version 3.0,<sup>13,14</sup> 2) EORTC – Head & Neck (H & N 35)<sup>15</sup> and 3) the Voice Handicap Index.<sup>16</sup>

The EORTC QLQ – C 30<sup>13,14</sup> consisted of five functional scales: physical (five items), role (two items), emotional (four items), cognitive (two items) and global health status (two items); three symptoms scales: fatigue (three items), nausea/vomiting (two items) and pain (two items); and six single items: dyspnoea, insomnia, appetite loss, constipation, diarrhea and financial difficulties. In total, there were 30 questions. The patients had to answer the questions by indicating one of four categories (1 = not at all, 2 = not much, 3 = moderate, 4 = very much). Two questions had to be answered on a 7-point scale (1 = very bad – 7 = excellent). Higher scores for functional scales represent better quality of life. For the symptom oriented scales and items, a higher score corresponds to a worse condition.

The EORTC QLQ – H & N 35<sup>15</sup> is a diagnosis-specific questionnaire for patients with head and neck cancer. It consisted of 35 questions concerning problems that are attributable to the head and neck cancer and side effects of the treatment. The patients had to answer the questions by indicating one of four categories (1 = not at all, 2 = not much, 3 = moderate, 4 = very much) as in the EORTC QLQ – C30.<sup>13,14</sup> A higher score corresponds to a worse Quality of Life.

The third questionnaire, the Voice Handicap Index,<sup>16</sup> was included to investigate speech-related problems. The goal of the Voice Handicap Index<sup>15</sup> is to investigate psychosocial problems caused by speech disorders. The Voice Handicap Index<sup>16</sup> consisted of three scales: functional (10 items), emotional (10 items) and physical (10 items). The patients had to answer the questions by indicating one of five categories (1 = never, 2 = nearly never, 3 = sometime, 4 = almost always, 5 = always). A higher score corresponds to a more difficulties with the speech.

Statistical analysis was performed using SPSS.



## *Results*

The partial laryngectomy group consisted of ten men and two women. In the total laryngectomy group, 9 patients were men and 2 were women. The age ranged from 54 years to 82 years. The questionnaires were sent a minimum of one year after the operation.

Table I shows the results of the EORTC QLQ – C30 <sup>13,14</sup> for the two groups. There are no statistically significant differences found between the two groups in the several subscales. Table II shows the results for the EORTC QLQ – H & N 35 <sup>15</sup> for the two groups. A statistically significant difference ( $p = 0.002$ ) was demonstrated between the 2 groups for smell and taste related problems in favor of patients after partial laryngectomy (median partial 1.0 vs. median in total laryngectomy group 2.5). In Table III the result of the Voice Handicap Index <sup>16</sup> is shown. The functional subscale after a total laryngectomy (median = 29) did not differ significantly with the group of partial procedures (median = 22). The same results were found for the other subscales: emotional (median total 24 vs. median partial 21.5) and physical (median total 23.5 vs. median partial 24.0).

## *Discussion*

In this study the only major difference in quality of life of patients after partial laryngectomy versus total laryngectomy was found to be smell and taste related. We believe that loss of smell has a negative impact on the quality of life, because patients enjoy their meal less. However, in this study this does not necessarily mean a loss of appetite (Table I). Other studies <sup>10,11</sup> found that patients after a total laryngectomy experienced more trouble with eating. However, both studies do not specify the problems.

We had expected a difference in acceptance of someone's appearance between the two groups, but this could not be demonstrated. An explanation might be that patients have accepted their new appearance with passing of time, surgery being at least one year previously. Also, no difference could be demonstrated with regard to speech related problems, as analyzed with the Voice Handicap Index. <sup>16</sup> All patients were reasonably satisfied with their speech after the operation. In other studies <sup>11</sup> a better voice-related quality of life after a partial procedure was found.

Several studies <sup>10,11</sup> found a significant better quality of life (voice related, physical, mental) in patients with a preserved larynx. Müller et al <sup>10</sup> compared five different treatment modalities (chordectomy, partial laryngectomy, radiotherapy, total laryngectomy and total laryngectomy with radiotherapy) in patients with a primary cancer of the larynx. They found a poor quality of life after total laryngectomy (with or without radiotherapy) compared to radiotherapy alone or a partial procedure. However, selection bias might have influenced their results, but they did not mention the disease stages of the different groups. One could expect that disease stage might influence outcome. Weinstein et al <sup>11</sup> found a better quality of life after a supracricoid partial laryngectomy compared to a total laryngectomy as primary treatment. Here also, a difference in disease stage might cause a bias in the results, for most patients treated with a supracricoid partial laryngectomy were staged as T1 or T2, while in the total

laryngectomy group most patients were staged as T3 or T4. Smith et al <sup>12</sup> found no difference in quality of life after radiotherapy or surgery (mostly endoscopic laser surgery) for early glottic cancer. In this study the patient groups were comparable (Tis and T1).

This is the first study addressing quality of life after a partial laryngectomy versus a total laryngectomy for recurrent disease. Initial stage of disease is therefore not a factor-influencing outcome. However, we should keep in mind that the results might underestimate reality. As mentioned before there are some advantages, such being able to swim and shower without precautions, after a partial laryngectomy. Also the patient might not appreciate the fact that the speech prosthesis must be changed regularly. These are only a few examples, which might give a difference in quality of life. These, larynx-specific problems could not be investigated, because validated questionnaires especially addressing laryngeal problems do not exist.

In conclusion, we could not confirm our clinical impression that patients with a partial laryngectomy are much better off than patients after a total laryngectomy. Those studies that do find a difference in QoL cannot make a valid comparison, because of selection bias. Because of the good oncological results <sup>7</sup> and the thought of a possible under-appreciation of the quality of life after a partial procedure in this study, we continue to advocate a partial procedure in suitable patients; however, we do stress even more the importance of a very careful patient selection. For future research in this particular area, laryngeal-specific questionnaires are mandatory.

Table I Results from EORTC QLQ – C30 questionnaire <sup>13,14</sup>

	Partial laryngectomy median	Total laryngectomy median
Global health status	5.5	6.0
Functional scales		
Physical functioning	1.4	1.4
Role functioning	1.0	1.5
Emotional functioning	1.2	1.0
Cognitive functioning	1.0	1.0
Social functioning	1.0	1.0
Symptoms scales		
Fatigue	1.3	1.2
Nausea and vomiting	1.0	1.0
Pain	1.0	1.0
Dyspnoea	2.0	2.0
Insomnia	1.0	1.0
Appetite loss	1.0	1.0
Constipation	1.0	1.0
Diarrhea	1.0	1.0
Financial difficulties	1.0	1.0

There are no significant differences between the two groups.

Table II Results from EORTC QLQ – H & N 35 questionnaire <sup>15</sup>

	Partial laryngectomy median	Total laryngectomy median
Pain	1.0	1.0
Swallowing	1.3	1.3
Senses problems	1.0*	2.5*
Speech problems	1.8	1.7
Trouble with social eating	1.0	1.0
Trouble with social contact	1.0	1.0
Less sexuality	2.5	2.3
Teeth	1.0	1.0
Opening mouth	1.0	1.0
Dry mouth	1.0	1.0
Sticky saliva	2.0	1.0
Coughing	2.0	2.0
Felt ill	1.0	1.0
Pain killers	1.0	1.0
Nutritional supplements	1.0	1.0
Feeding tube	1.0	1.0
Weight loss	1.0	1.0
Weight gain	1.0	1.0

\*: There is a significant difference ( $p=0.002$ ) in problems with senses between the two groups.

Table III Results from the Voice Handicap index <sup>16</sup>

	Partial laryngectomy median	Total laryngectomy median
Functional	22.0	29.0
Emotional	21.5	24.0
Physical	24.0	23.5

There are no significant differences between the two groups.

#### *Acknowledgments*

The authors thank Professor L. Feenstra, MD, PhD, Professor J.F.A. Pruyn, PhD and M.F. de Boer, MD, PhD for their helpful comments in preparing this paper.

## References

1. Nederlandse Werkgroep Hoofd-Halstumoren. Richtlijn larynx-carcinoom. 1999.
2. Nibu K, Kamata S, Kawabata K, et al. Partial laryngectomy in the treatment of radiation-failure of early glottic carcinoma. *Head Neck*. 1997; 19(2): 116-120
3. Hilgers FJM, Ackerstaff AH. Comprehensive rehabilitation after total laryngectomy is more than voice alone. *Folia Phoniatr Logop*. 2000; 52: 65-73
4. Relic A, Mazemda P, Arens C, Koller M, Glanz H. Investigating quality of life and coping resources after laryngectomy. *Eur Arch Otorhinolaryngol*. 2001; 258: 514-517
5. Spriano G, Pellini R, Romano G, Muscatello L, Roselli R. Supracricoid partial laryngectomy as salvage surgery after radiation failure. *Head Neck*. 2002; 24(8): 759-765
6. Bron L, Pasche P, Brossard E, Monnier P, Schweizer V. Functional analysis after supracricoid partial laryngectomy with cricohyoïdoepiglottopexy. *Laryngoscope*. 2002; 112: 1289-1293
7. Sewnaik A, Meeuwis CA, van der Kwast Th, Kerrebijn JDF. Partial laryngectomy for recurrent glottic carcinoma after radiotherapy. *Head Neck*. Accepted for publication.
8. Kooper DP, van den Broek P, Manni JJ, Tiwari RM, Snow GB. Partial vertical laryngectomy for recurrent glottic carcinoma. *Clin Otolaryngol*. 1995; 20: 167-17
9. Nichols RD, Mickelson SA. Partial laryngectomy after irradiation failure. *Ann Otol Laryngol*. 1991; 100(3): 176-180
10. Müller R, Paneff J, Köllner V, Koch R. Quality of life of patients with laryngeal carcinoma: a post-treatment study. *Eur Arch Otorhinolaryngol*. 2001; 258: 276-280
11. Weinstein GS, El-Sawy MM, Ruiz C, et al. Laryngeal preservation with supracricoid partial laryngectomy results in improved quality of life when compared with total laryngectomy. *Laryngoscope*. 2001; 111: 191-199
12. Smith JC, Johnson JT, Coggnetti DM, et al. Quality of life, functional outcome, and costs of early glottic cancer. *Laryngoscope*. 2003; 113: 68-76
13. Aaronson NK, Ahmedzai S, Bergman B, et al. The European Organization for Research and Treatment of Cancer QLQ-C30: a quality of life instrument for use in international clinical trials in oncology. *J Natl Cancer Instr*. 1993; 85: 365-376
14. Bjordal K, Ahlner-Elmqvist M, Tolleson E, et al. Development of a European Organization for Research and Treatment of Cancer (EORTC) questionnaire module to be used in quality of life assessments in head and neck cancer patients: EORTC Quality of Life Study Group. *Acta Oncol*. 1994; 33: 879-885

15. Bjordal K, Hammerlid E, Ahlner-Elmqvist M, et al. Quality of life in head and neck cancer patients: validation of the European Organization for Research and Treatment of Cancer Quality of life Questionnaire – H & N 35. *J Clin Oncol.* 1999; 17: 1008-1019
16. Jacobson BH, Johnson A, Grywalski C, Silbergleit A, Jacobson G, benninger MS. The Voice Handicap Index (VHI): development and validation. *Am J of speech-language pathology.* 1997; 6: 66-70





## **Chapter V**

Treatment of hypopharyngeal carcinoma: Analysis of nation wide study in the  
Netherlands over a 10-year period

A. Sewnaik, JJ. Hoorweg, PP. Knegt, MH. Wieringa, JMH. van der Beek, JDF.  
Kerrebijn

Clinical Otolaryngology. 2005; 30; 52-57

## **Abstract**

**Objective:** To analysed different treatment strategies and treatment results of hypopharyngeal carcinoma in the Netherlands.

**Design:** Retrospective study.

**Setting:** Eight head and neck centres in the Netherlands.

**Participants:** A total of 893 patients were treated between 1985 and 1994.

Patients were mostly treated with radiotherapy alone, combined surgery and radiotherapy and surgery alone.

**Results:** The 5-year survival for the whole group was 26%.

The 5-year survival for patients treated with curative intention was 32% and treated with palliative intention was 5%. The 5-year disease free survival after radiotherapy alone was 37%, after surgery alone 41% and after combined therapy 47%. The role of chemotherapy could not be investigated due to a small number of patients treated with chemotherapy in this period.

**Conclusion:** Combined therapy with surgery and radiotherapy has a better survival for patients with a hypopharyngeal carcinoma in comparison with radiotherapy alone. The N-stage is more important for the prognosis than the T-stage.

**Keywords:** hypopharyngeal carcinoma, radiotherapy, surgery, survival

## **Introduction**

Squamous cell carcinoma of the hypopharynx is relatively rare and has the worst prognoses of all head and neck cancers, particularly tumours arising in the pyriform sinus, the most frequent site of hypopharyngeal origin.<sup>1,2</sup> Patients usually present with late stage disease often thought to be a result of the larger cross-sectional area permitting food to pass until late stage disease.<sup>3</sup> In the 1970s most patients were treated with surgery, radiotherapy or combination of these two treatment modalities.<sup>4</sup> The 5-year survival rate for combined surgery with radiotherapy varies between 25% and 60%.<sup>3,4</sup> For the purpose of improving survival rates and preserving organ function a third treatment modality, chemotherapy in combination with radiotherapy, was introduced. There are not many randomised studies available to answer the question which therapy has better oncological and functional results.<sup>5</sup> Several studies<sup>2,6</sup> described that neoadjuvant chemotherapy and radiotherapy is a more effective treatment strategy compared to radiotherapy alone. Organ preservation is achieved without compromising survival. However, both studies had a small number of patients and do not mention functional outcome. For small tumours radiotherapy or surgery alone can be effective.<sup>7</sup> A nation wide study was set up to evaluate the results of treatment of patients with hypopharyngeal carcinoma in the Netherlands between 1985 and 1994. This retrospective study reports methods of treatment and treatment results of patients presenting with a hypopharyngeal carcinoma.

## **Methods**

The eight head and neck centres of the Dutch Cooperative Head and Neck Group participated in this nationwide retrospective study analysing all patients treated for a hypopharyngeal carcinoma between 1985-1994. Generally over 90% of patients with hypopharyngeal cancer in the Netherlands will be treated in or under supervision of one of the head and neck centres (Table 1). In each centre records of patients with hypopharyngeal carcinoma were reviewed and a standardised questionnaire for each patient was completed. The items scored for each patient are presented in Table 2. A total of 930 patients were diagnosed with hypopharyngeal carcinoma. Eight patients were excluded because they had a non-squamous cell carcinoma. Three patients were left out of the study because of incidence before 1985 or incomplete data. Twenty-six patients were registered twice. In total 893 patients with squamous cell carcinoma of the hypopharynx were included in the study. The population consisted 716 men and 177 women. The ages of the patients ranged from 33-91 years (average age for males was 61.9 years and for females 63.3 years) (Fig. 1).

### **Data analysis:**

Survival rates were calculated using Kaplan Meier method and compared using the log-rank test.

The disease-free survival is calculated as the period from the moment of diagnosis until a recurrence occurs.

## *Results*

### **Tumour stage**

The tumours were staged according to the UICC 1987 criteria (Table 3). Distribution by UICC is as follows: Stage I: 38 patients (4.2 %), Stage II: 88 patients (9.9%), Stage III: 155 patients (17.3%) and Stage IV: 612 patients (68.5%).

### **Treatment**

A total of 704 patients (78.9%) were treated with curative intent. Curative treatment consisted mostly of surgery combined with radiotherapy (N = 381) and radiotherapy (N = 224). The other treatment modalities were surgery (N = 57), chemotherapy combined with radiotherapy (N = 36) and chemotherapy in combination with surgery and radiotherapy (N = 6). Palliative treatment was given to 140 patients (15.8%) and 49 patients (5.4%) received no treatment at all.

### **Survival**

The overall survival after 5 years for the whole group was 26%. The overall 5-year survival for patients treated with curative intent was 32% and for patients treated with palliative intent was 5%. In the group of patients who did not receive any treatment, all patients died within 6 months. The 5-year disease-free survival for patients treated with curative intent was 42%. For patients treated with palliative intent this was 5.6%. The 5-year disease-free survival for patients in the curative group is significantly different for T-stage ( $p < 0,01$ ) (Fig. 2) and for N-stage ( $p < 0,01$ ) (Fig. 3). T-stage and N-stage, after correction for age, are independent prognostic factors. Difference in N-stage had more impact on survival than a difference in T-stage (Table 4). The 5-year disease-free survival for patients in the curative group is also significantly different for UICC stages ( $p < 0,01$ ) (Fig. 4).

In the group of patients treated with curative intent, the 5-year disease-free survival significantly differs ( $p < 0.01$ ) between the treatment modalities. The 5-year disease-free survival after combined surgery and radiotherapy was 47%, after surgery alone 41% and after radiotherapy 37%. Because of the small number of patients treated with combined radiotherapy and chemotherapy, we were not able to calculate a survival rate.

After treatment with radiotherapy alone, 56% developed recurrent disease (local, regional or distant). Forty-nine percent of patients treated with surgery and radiotherapy and 54% after treatment with surgery alone developed a recurrence (Table 5).

The 5-year disease-free survival for stage IV disease is significantly better ( $p < 0,01$ ) after surgery in combination with radiotherapy. In the other disease stages we also found a trend that the 5-year disease-free survival is better after combination therapy (Table 6).

Patients and treatment differences between different institutes

One institute had a different distribution of tumour stage for patients at first presentation with 77% of these patients having stage IV disease. The average distribution for stage IV disease for all other institutes ranged between 22 and 49%. Most institutes treated patients with combined surgery and radiotherapy (Table 7). Only in two centres more patients were treated with radiotherapy.

## *Discussion*

This study presents the results of all patients treated for hypopharyngeal carcinoma in the Netherlands over a 10-year period. Carcinoma of the hypopharynx has one of the worst prognoses of all head and neck cancers. Symptoms of this disease occur late; therefore most patients are diagnosed with advanced stage. In our study 86 % of the patients presented with stage III or IV disease. This is comparable with Pingree <sup>1</sup>, who reported 71 % I stages III and IV.

The overall 5-year survival of the whole group of patients with hypopharyngeal carcinoma was 26%. This is comparable to other studies which reported survival ratios varying between 15 and 47%.<sup>1,6,8</sup> The disease-free 5-year survival found in this study between radiotherapy (37%) and combined surgery and radiotherapy (47%) or surgery (41%) is significantly different. This is similar to other studies,<sup>1,6</sup> which also reported a worse survival after radiotherapy alone. This is especially reported for late stage disease.<sup>6</sup> Similar to Kim <sup>6</sup> we also found that for stage IV hypopharyngeal carcinoma treatment with combined therapy is significantly better. For all other stages we found a trend that combined therapy is better, but because of the number of patients in these groups no statistical significance could not be established. In the Netherlands, most patients are treated with combined therapy. Only in two institutes more patients were treated with radiotherapy alone in the study period. In our study, a small number of patients were treated with chemotherapy and radiotherapy. Therefore, we could not analyse this treatment modality. However, in the literature several studies describe the benefit of chemotherapy in combination with radiotherapy for head and neck cancer. A large meta-analysis <sup>5</sup> revealed that the survival rate increased significantly when chemotherapy was added to loco regional treatment. However, this study included all head and neck cancers. Another study addressing combined chemotherapy and radiotherapy of laryngeal cancer showed that organ preservation can be achieved without a difference in survival compared to combined surgery and radiotherapy.<sup>9</sup>

A randomized trial <sup>10</sup> in Europe for treatment of hypopharyngeal carcinoma showed no difference in survival after treatment with chemotherapy and radiotherapy compared with surgery and radiotherapy. However, with combined chemotherapy and radiotherapy the larynx can be preserved in the majority of patients.<sup>2,6,10,12</sup> In these studies function of the larynx is not evaluated. In a recent study <sup>13</sup> it was found that patients with advanced stage laryngeal or hypopharyngeal cancer, laryngeal function was impaired after combined treatment with chemotherapy and radiotherapy, which has also been our personal experience.

We therefore suggest that patients with advanced hypopharyngeal cancer without neck metastasis should be treated with combined surgery and radiotherapy; for all other stages combined surgery and radiotherapy or chemotherapy and radiotherapy appear to be equally effective.

### *Acknowledgements*

The authors would like to thank all the Head and Neck centres in the Netherlands for collecting data

Table 1: Head and Neck centres in the Netherlands.

University hospital of Groningen  
University hospital of Leiden  
University hospital of Utrecht  
University hospital of Nijmegen  
University hospital of Maastricht in combination with the  
Radiotherapeutic Institute of Limburg  
University hospital of Rotterdam  
University hospital of Amsterdam  
Netherlands Cancer Institute

Table 2: Items scored for each patient:

**Institute**

**Date of birth**

Gender

Date of first histological diagnosis

Localisation in the hypopharynx

TNM-classification

Histological diagnosis

Intent of primary treatment

Date of first treatment

Primary according to institute's protocol

Reason for non-protocollar treatment

Combination of surgical, radiotherapeutic and or chemotherapeutic treatment

Surgical treatment:

Date of operation

Resection with surgery

Larynx

Pharynx

Neck

Oesophagus

Kind of reconstruction

Radiotherapeutic treatment:

Date of start radiotherapy

Doses of radiotherapy

Total dose at tumour site

Elective dose on neck

Fraction dose

Chemotherapeutic treatment:

Date of start chemotherapy

Intention of chemotherapy

Number of chemotherapeutic treatments



Complications from any kind of treatment  
Date of recurrence or residual tumour  
Intention treatment of recurrence  
Combination of surgical, radiotherapeutic and or chemotherapeutic treatment for  
recurrence  
Second recurrence  
Date of second recurrence  
Second primary tumour  
    Date of second primary tumour  
    Localisation of second primary tumour  
Date last follow-up  
Tumour status at date last follow-up  
Date of death  
Tumour status at date of death

**Table 3: Tumour stage.**

		T1	T2	T3	T4	Tx	Total
M0	N0	38	88	61	88	2	277
	N1	10	52	32	73	0	167
	N2	13	62	63	131	0	269
	N3	11	12	20	56	1	100
	Nx	0	0	0	1	0	1
	Subtotal	72	214	176	349	3	817
M1	N0	0	0	0	3	0	3
	N1	0	1	2	1	0	4
	N2	1	0	1	8	1	11
	N3	1	2	1	4	0	8
	Nx	1	0	0	0	0	1
	Subtotal	3	3	4	16	1	27
Mx	N0	2	3	4	4	0	13
	N1	0	5	1	4	0	10
	N2	2	0	5	12	0	19
	N3	0	2	1	3	0	6
	Nx	0	0	0	1	3	4
	Subtotal	4	10	11	24	3	52
Total		79	227	191	389	7	893

**Table 4: Odds ratio for T-stage and N-stage.**

T-stage	N-Stage
Odds Ratio (95% CI)	
T2: 1.06 (0.70 – 1.60)	N1: 1.28 (0.93 – 1.75)
T3: 1.31 (0.86 – 1.99)	N2: 1.80 (1.37 – 2.37)
T4: 1.60 (1.08 – 2.37)	N3: 3.59 (2.48 – 5.20)

T-stage: Odds ratio calculated for T2, T3 and T4 tumours compared with T1

N-stage: Odds ratio calculated for N1, N2 and N3 tumours compared with N0

**Table 5: Recurrence in the group treated with curative intent.**

	No recurrence	Local	Regional	Loco regional	Distant metastases
	N (%)	N (%)	N (%)	N (%)	N (%)
Radiotherapy N=216	95 (44%)	65 (30%)	34 (16%)	1 (0.5%)	21 (9.7%)
Radiotherapy and surgery N=370	189 (51%)	37 (10%)	50 (14%)	1 (0%)	93 (25%)
Surgery N=52	24 (46%)	10 (19%)	11 (21%)	0	7 (14%)

**Table 6: Five-year disease free survival in different stages of disease after different treatment.**

	Treatment	5-year disease free survival
Stage I	R: N=27	54%
	RS: N=4	75%
	S: N=6	60%
Stage II	R: N=49	51%
	RS: N=25	79%
	S: N=8	63%
Stage III	R: N=63	37%
	RS: N=62	47%
	S: N=14	62%
Stage IV	R: N=83	22%
	RS: N=287	43% *
	S: N=27	22%

**R: Radiotherapy**

**RS: Combination therapy radiotherapy and surgery**

**S: Surgery**

**\*: Significantly different (p<0.01)**

**Table 7: Treatment modalities in different institutes in the group patients treated with curative intent.**

	Radiotherapy N (%)	Radiotherapy and surgery N (%)	Surgery N (%)
Institute 1 N=57	24 (42%)	32 (56%)	1 (2%)
Institute 2 * N=75	27 (36%)	38 (51%)	8 (11%)
Institute 3 * N=77	9 (12%)	60 (78%)	5 (7%)
Institute 4 * N=56	22 (39%)	15 (27%)	7 (13%)
Institute 5 * N=148	33 (22%)	99 (67%)	7 (5%)
Institute 6 * N=107	63 (59%)	29 (27%)	4 (4%)
Institute 7 * N=106	29 (27%)	57 (54%)	16 (15%)
Institute 8 * N=78	17 (22%)	51 (65%)	9 (12%)

\*: Other treatment modalities were performed. Therefore a total of 100 % is not reached.

Figure 1. Age distribution by gender

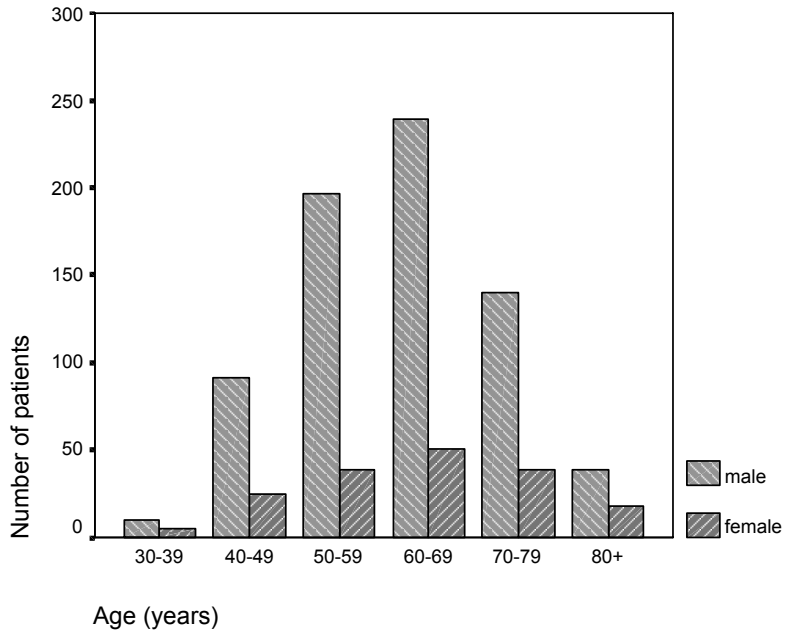
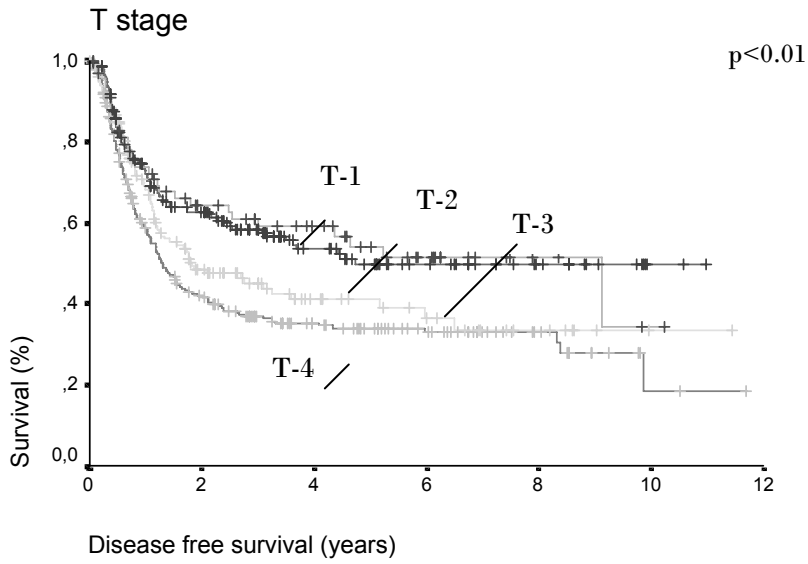


Figure 2

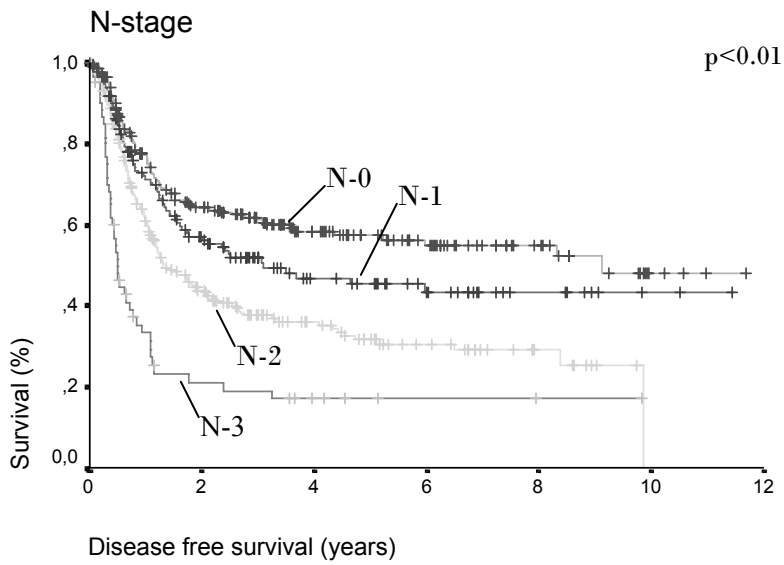
### Survival in curative patients



The survival is significantly different for T-stage.

Figure 3

### Survival in curative patients



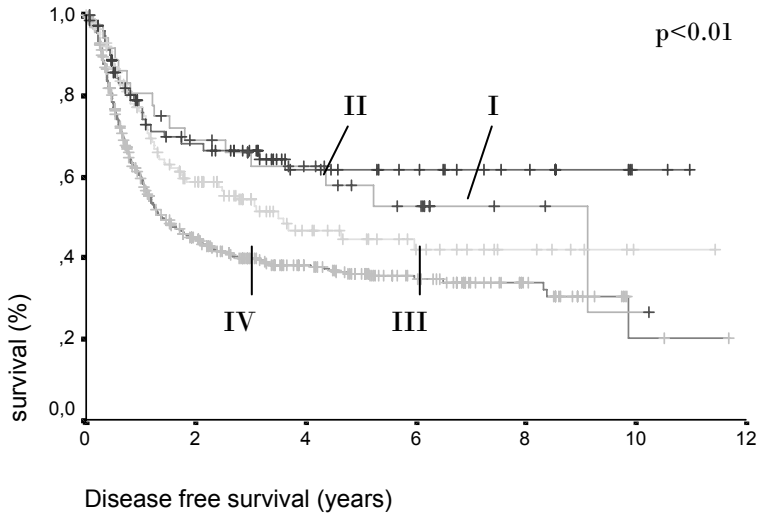
The survival is significantly different for N-stage.



Figure 4

### Survival in curative patients

UICC 1987 stages



The survival is significantly different for UICC stages.

## References

1. Pingree TF, Davis RK, Reichman O, Derrick L. Treatment of hypofaryngeal carcinoma: a 10-year review of 1,362 cases. *Laryngoscope*. 1987; 97: 901-904
2. Prades JM, Schmitt TM, Timoshenko AP et al. Concomitant chemoradiotherapy in pyriform sinus carcinoma. *Arch Otolaryngol Head Neck Surg*. 2002; 128: 384-388
3. Lajtmam Z, Manestar D. A comparison of surgery and radiotherapy in the management of advanced pyriform fossa carcinoma. *Clin Otolaryngol*. 2001; 26(1): 59-61
4. Loré JM, Kaufman S, Sundquist N, Chary KK. Carcinoma of the head and neck: A 5- to 20-year experience with preoperative chemotherapy, uncompromised surgery, and selective radiotherapy. *Ann Surg Oncol*. 2003; 10(6): 645-653
5. Pignon JP, Bourhis J, Domenge C, Designé L. Chemotherapy added to locoregional treatment for head and neck squamous-cell carcinoma: three meta-analyses of updated individual data. *Lancet*. 2000; 355: 949-955
6. Kim S, Wu HG, Heo DS, Kim KH, Sung MW, Park CI. Advanced hypopharyngeal carcinoma treatment results according to treatment modalities. *Head Neck*. 2001; 23: 713-717
7. Sasaki CT, Jassin B. Cancer of the pharynx and larynx. *Am J Med*. 2001; 111(8a): 118s-123s
8. Kraus DH, Zelefsky MJ, Brock HA et al. Combined surgery and radiation therapy in the management of postcricoid carcinoma. *Clin Otolaryngol*. 1997; 22: 370-374
9. Wolf GT, Hong WK, Fisher SG. Induction chemotherapy plus radiation compared with surgery plus radiation in patients with advanced laryngeal cancer. The department of veterans affairs laryngeal cancer study group. *N Engl J Med*. 1991; 324(24): 1685-1690
10. Wei WI. The dilemma of treating hypopharyngeal carcinoma: more or less. *Arch Otolaryngol Head Neck Surg*. 2002; 128: 229-232
11. Lefebvre JL, Chevalier D, Luboinski B, Kirkpatrick A, Collette L, Sahmoud T. Larynx preservation in pyriform sinus cancer : preliminary results of a European Organization for Research and Treatment of Cancer phase III trial. EORTC Head and Neck Cancer Cooperative Group. *J Nat Cancer Inst*. 1996; 88(13): 890-899
12. Adelstein DJ, Lavertu P, Saxton JP et al. Mature results of a phase III randomized trial comparing concurrent chemoradiotherapy with radiation therapy alone in patients with stage II and IV squamous cell carcinoma of the head and neck. *Cancer*. 2000; 88 (4): 876-893
13. Carrara-de Angelis E, Feher O, Brandao Barros AP, Nishimoto IN, Kowalski LP. Voice and swallowing in patients enrolled in a larynx preservation trial. *Arch Otolaryngol Head Neck Surg*. 2003; 129: 733-738

## **Chapter VI**

The devastation of chemoradiation

A. Sewnaik, R.J. Baatenburg de Jong, M.H. Wieringa, C.A. Meeuwis, JDF. Kerrebijn

Submitted

## **Abstract**

**Background:** Salvage surgery is a treatment option for patients with residual or recurrent disease after chemoradiation. However, salvage surgery in this group of patients has a high complication-rate. The aim of this study was to determine the rate of complications associated with salvage surgery after chemoradiation in comparison to salvage surgery after radiotherapy alone for laryngeal and pharyngeal cancers.

**Methods:** Twenty-four patients with salvage surgery after chemoradiation were compared to patients who were salvaged after radiotherapy.

**Results:** The complication rate in the direct post-operative period was significantly higher (92% vs. 50%) in the chemoradiation group. The most frequent complication was pharyngocutaneous fistula. The quality of life, measured at least two years after salvage surgery, showed a significant difference in social functioning in disadvantage of the chemoradiation group.

**Conclusion:** With chemoradiation protocols for laryngeal or hypopharyngeal cancers the organ can be preserved. However, salvage surgery is accompanied by high complication rates.

**Keywords:** chemoradiation, salvage surgery, radiotherapy, complications, organ preservation

## Introduction

Since the Veterans Affairs Cooperative (VA) study <sup>1</sup> was published in the early nineties, treatment of advanced laryngeal and hypopharyngeal cancer with chemoradiation has become increasingly popular. The VA study <sup>1</sup> reported that approximately two thirds of the patients retained their organ after induction chemotherapy and radiotherapy without a difference in survival compared to combined surgery and radiotherapy. In a prospective study by the Radiation Therapy Oncology Group,<sup>2</sup> a similar high rate of organ preservation after concomitant chemoradiation was achieved, while survival was found to be similar to primary surgical treatment.

The goal of organ preservation protocols for laryngeal and hypopharyngeal cancer is to preserve natural speech and swallowing. In a recent study, Hanna et al <sup>3</sup> showed that although chemoradiation and surgery have a different effect on the quality of life, the overall QOL scores of both groups seem similar after an average of 15 months. For the patients who recur or who have residual disease after organ preservation protocols, salvage surgery is the only treatment option. Loss of the larynx is the price for a chance of cure. A number of studies report increased complication rates associated with salvage surgery compared to primary surgery. <sup>4,5,6</sup>

The goal of this study was to determine the rate and severity of complications associated with salvage surgery (laryngectomy) after chemoradiation in comparison to salvage surgery after radiotherapy alone for laryngeal or hypopharyngeal cancers. Furthermore, the Quality of life after salvage surgery after the 2 primary treatment modalities was compared.

## Material and methods

Between 1995 and 2004 twenty-four patients were treated with salvage laryngectomy at the department of Otolaryngology Head and Neck Surgery of the Erasmus Medical Centre Rotterdam and in the department of Otolaryngology Head and Neck Surgery of the University hospital Leiden in the Netherlands after previous chemotherapy and radiotherapy.

The group treated after chemoradiation consisted of sixteen men and seven women. Ages ranged between 46 and 71 year. The primary tumour sites were the hypopharynx in 11 patients, supraglottic larynx in 8 and the base of tongue in 5. (Table I) Previous treatment consisted of induction chemotherapy and radiotherapy in 16 patients and concomitant chemotherapy and radiotherapy in 8 patients. Seventeen patients were salvaged for recurrent disease, 5 patients for residual disease and two patients underwent laryngectomy for a second primary tumour.

In the same period one hundred and three patients were treated with salvage laryngectomy for recurrent disease after radiotherapy. This group consisted of ninety-three men and ten women. Ages ranged between 32 and 85 years. The primary tumour sites were the larynx (glottic (N=65) and supraglottic (N=32)) and the hypopharynx (N=6). (Table II)

The medical records were studied for tumour stage, treatment, operation reports and post-operative complications.

Two different questionnaires were sent to the patients: 1) EORTC Quality of Life Questionnaire (QLQ) – C30 Dutch version 3.0<sup>7,8</sup> 2) EORTC – Head & Neck (H & N 35).<sup>9</sup> The EORTC QLQ – C 30<sup>7,8</sup> consists of six functional scales: physical (five items), role (two items), emotional (four items), cognitive (two items) and global health status (two items); three symptoms scales: fatigue (three items), nausea/vomiting (two items) and pain (two items) and six single items: dyspnoea, insomnia, appetite loss, constipation, diarrhoea and financial difficulties. In total, there were 30 questions. The patients had to answer the questions by indicating one of four categories (1 = not at all, 2 = not much, 3 = moderate, 4 = very much). Two questions had to be answered on a 7-point scale (1 = very bad – 7 = excellent). Higher scores for functional scales represent better quality of life. For the symptom oriented scales and items, a higher score corresponds to a worse condition.

The EORTC QLQ – H & N 35<sup>9</sup> is a diagnosis specific questionnaire for patients with head and neck cancer. It consisted of 35 questions concerning problems that are attributable to the head and neck cancer and side effects of the treatment. The patients had to answer the questions by indicating one of four categories (1 = not at all, 2 = not much, 3 = moderate, 4 = very much) as in the EORTC QLQ – C30.<sup>7,8</sup> A higher score corresponds to a worse Quality of Life.

### **Data analysis**

The Mann Whitney U test and the Pearson Chi-square test were used to calculate the significant differences between the two groups.

### **Results**

Of the 24 patients treated with salvage laryngectomy after chemoradiation, nine patients were treated with a total laryngectomy with a partial pharyngectomy and a reconstruction with a pectoralis major muscle flap. Six patients were treated with a total laryngectomy and pharyngectomy while a free jejunum graft was used for reconstruction. One patient was treated with a total laryngectomy, pharyngectomy, unilateral neck dissection and reconstructed with a jejunum graft and a pectoralis major flap. Eight patients had a laryngectomy with primary closure. In seven patients a unilateral neck dissection and in 9 patients a bilateral neck dissection was also performed. (Table III)

In the patients who recurred after irradiation, 66 patients underwent a total laryngectomy with a partial pharyngectomy and primary closure. In eleven patients a total laryngectomy and a neck dissection and a reconstruction with a pectoralis major flap were performed. In three cases a reconstruction with a free jejunum graft was performed. (Table IV)

In neither group any per-operative complications were recorded. In the chemoradiation group, twenty-two patients (92%) suffered of complications in the direct post-operative period (< 3 months). (Table V) Most of these (N=12, 50%) developed a

pharyngocutaneous fistula. In only two cases surgical treatment was needed. In all other patients conservative treatment of the fistula was successful. Five patients (21%) had postoperative haemorrhage and needed surgery. In this group one patient suffered of postoperative haemorrhage and also an ischemic jejunum graft, which was replaced by a new one.

In the radiotherapy-alone group, fifty patients (50%) had complications in the post-operative period (< 3 months). The most frequent complication was again a pharyngocutaneous fistula (N=20, 19%). (Table V) Most patients (N=18) were treated conservatively. In this group two patients died in the direct post-operative period. Both deaths were due to pulmonary failure.

Late complications (> 3 months postoperatively) in both groups were swallowing restrictions (25% in chemoradiation group vs. 8% in radiation group) (Table V) In both groups most patients were treated by endoscopy with dilation of the pharynx or upper oesophagus. In the chemoradiation group, 2 patients had a near total obstruction of the oesophagus necessitating a jejunum graft in one patient and a percutaneous gastrostomy in another. In the radiation group, pharyngeal dilation was sufficient treatment for all patients. The other frequent complication in both groups was constriction of the tracheostoma. In the chemoradiation group three patients (13%) needed a surgical procedure. In the other group five patients (5%) needed a surgical procedure.

The Quality of life after was measured in 7 patients after salvage laryngectomy. Eleven questionnaires were sent to all patients alive. Seven patients (63%) returned the filled questionnaires. In the other group (after radiotherapy) 30 questionnaires were sent out. Twenty patients (67%) returned the filled questionnaires. The patients in the chemoradiation group had significant more troubles in social functioning and in eating with others. They also had more problems with sticky saliva. (Table VI + VII) Patients after salvage surgery after chemoradiation had more social difficulties. These results suggest that the quality of life after a longer period is equal in both groups.

## *Discussion*

Since 1991, after the Veterans Affairs (VA) Cooperative study was presented, organ preservation protocols consisting of chemoradiation for advanced laryngeal and hypopharyngeal cancers became more popular. A large meta-analysis<sup>10</sup> revealed that the survival rate increased significantly when chemotherapy was added to loco-regional treatment. However, this study included all head and neck cancers. Another study<sup>1</sup> addressing combined chemotherapy and radiotherapy of laryngeal cancer showed that organ preservation could be achieved without a difference in survival compared to combined surgery and radiotherapy. A randomized trial<sup>11</sup> in Europe for treatment of hypopharyngeal carcinoma showed no difference in survival after treatment with chemoradiation compared to surgery and radiotherapy. However, with combined chemotherapy and radiotherapy the larynx could be preserved in the majority of patients.<sup>12,13,14,15</sup>

Although with chemoradiation the larynx is anatomically preserved, function may be impaired. Especially, swallowing can be compromised due to permanent tissue damage (radiotherapy induced fibrosis and xerostomia).<sup>16</sup>

Surgery is reserved for salvage treatment in case of local or regional recurrence. However, in this group of patients the postoperative complication rate is high.<sup>6</sup> The frequency of complications in salvage surgery after induction chemotherapy and radiotherapy ranges between 33%<sup>17</sup> and 61%.<sup>18</sup> The most frequent complication described by Sessler et al<sup>18</sup> were pharyngocutaneous fistula and wound breakdown. Kraus et al<sup>17</sup> also found pharyngocutaneous fistula the most frequent complication. In a more recent study by Leon et al,<sup>5</sup> the post-operative complication rate was 21% following salvage surgery after chemoradiation. In this study, pharyngocutaneous fistula was the predominant complication. In our study, we found a post-operative complication rate of 92%. A reason for the low complication rate found by Leon et al is that relatively limited procedures (mostly total laryngectomy alone) were performed.

We found a significant difference in complication rates associated with surgery after chemoradiation vs. radiotherapy alone (92% vs. 50%). In both groups the most frequent complication was a pharyngocutaneous fistula, as reported in other studies. Part of the reason for this difference can be attributed to the extent of surgery. In the chemoradiation group more extensive resections with more extensive reconstructions were performed. Also, the primary stages of the cancers were more advanced in this group. However, the much higher rate of complications can also partly be attributed to the more toxic effect of chemoradiation on tissues compared to radiotherapy alone. Histological, the effect of chemoradiation intensifies the changes produced by radiotherapy alone, influencing wound healing. There is proportionally greater obliterative endarteritis and increased fibrosis.<sup>19</sup> We believe that a reconstruction with non-irradiated, well-vascularized tissue is necessary for better wound healing. These patients might also suffer from pharyngocutaneous fistulas, but we think that the healing period is shorter. Teknos<sup>19</sup> described that free tissue transfer might even be better for reconstruction of the hypopharynx after chemoradiation. Surgical complications are significantly reduced.



We found no studies comparing complications of salvage surgery after induction versus concomitant chemotherapy, an issue that could also not be addressed by us due to small patient groups.

The quality of life was measured at least two years after salvage surgery. The only significant difference found was that the patients in the chemoradiation group had more trouble in social functioning and in social eating. No studies, including this one have addressed short term QoL, which might be influenced by complications suffered.

In conclusion, although in the majority of patients a functional larynx can be preserved with chemoradiation protocols for primary laryngeal or hypopharyngeal cancers, in case of recurrent disease salvage surgery is accompanied by high complication rates. The surgeon should keep in mind that chemoradiation not only cures the cancer, but also devastates the tissue. Therefore, special care and good planning of the operation is necessary. The patients should be well informed about the operation, the direct post-operative period and the prolonged rehabilitation period.

### *Acknowledgments*

The authors thank Professor L. Feenstra, MD, PhD for his support in preparing this paper

## References

1. Wolf G.T., Hong W.K., Fisher S.G. Induction chemotherapy plus radiation compared with surgery plus radiation in patients with advanced laryngeal cancer. The department of veterans affairs laryngeal cancer study group. *N Engl J Med.* 1991; 324(24): 1685-1690
2. Forastiere AA, Groepfert H, Maor M et al. Concurrent chemotherapy and radiotherapy for organ preservation in advanced laryngeal cancer. *N Engl J Med.* 2003; 349: 2091-2098
3. Hanna E, Sherman E, Cash D et al. Quality of life for patients following total laryngectomy vs chemoradiation for laryngeal preservation. *Arch Otolaryngol head neck surg.* 2004; 130: 875-879
4. Agra IM, Carvalho AL, Pontes E et al. Postoperative complications after en bloc salvage surgery for head and neck cancer. *Arch Otolaryngol head neck surg.* 2003; 129: 1317-1319
5. Leon X, Quer M, Orus C, Lopez M, Gras JM, Vega M. Results of salvage surgery for local or regional recurrence after larynx preservation with induction chemotherapy and radiotherapy. *Head Neck.* 2001; 23: 733-738
6. Lavertu P, Bonafede JP, Adelstein DJ et al. Comparison of surgical complications after organ-preservation therapy in patients with stage III or IV squamous cell head and neck cancer. *Arch Otolaryngol head neck surg.* 1998; 124: 401-406
7. Aaronson NK, Ahmedzai S, Bergman B, et al. The European Organization for Research and Treatment of Cancer QLQ-C30: a quality of life instrument for use in international clinical trials in oncology. *J Natl Cancer Instr.* 1993; 85: 365-376
8. Bjordal K, Ahlner-Elmqvist M, Tollesson E et al. Development of a European Organization for Research and Treatment of Cancer (EORTC) questionnaire module to be used in quality of life assessments in head and neck cancer patients: EORTC Quality of Life Study Group. *Acta Oncol.* 1994; 33: 879-885
9. Bjordal K, Hammerlid E, Ahlner-Elmqvist M et al. Quality of life in head and neck cancer patients: validation of the European Organization for Research and Treatment of Cancer Quality of life Questionnaire – H & N 35. *J Clin Oncol.* 1999; 17: 1008-1019
10. Pignon JP, Bourhis J, Domenge C, Designe L. Chemotherapy added to locoregional treatment for head and neck squamous-cell carcinoma: three meta-analysis of updated individual data. MACH-NC Collaborative Group. Meta-analysis of chemotherapy on head and neck cancer. *Lancet.* 2000; 355: 949-955
11. Lefebvre JL, Chevalier D, Luboinski B, Kirkpatrick A, Collette L, Sakhmoud T. Larynx preservation in pyriform sinus cancer : preliminary results of a European Organization for Research and Treatment of Cancer phase III trial. EORTC Head and Neck Cancer Cooperative Group. *J. Nat Cancer Inst.* 1996; 88(13): 890-899
12. Wei WI The dilemma of treating hypopharyngeal carcinoma: more or less. *Arch Otolaryngol Head and Neck Surg.* 2002; 128: 229-232
13. Adelstein DJ, Lavertu P, Saxton JP et al. Mature results of a phase III randomized trial comparing concurrent chemoradiotherapy with radiation therapy alone in patients with stage II and IV squamous cell carcinoma of the head and neck. *Cancer.* 2000; 88 (4): 876-893

14. Kim S, Wu HG, Heo DS, Kim KH, Sung MW, Park CI. Advanced hypopharyngeal carcinoma treatment results according to treatment modalities. *Head and Neck*. 2001; 23(9): 713-717
15. Prades J.M., Schmitt T.M., Timoshenko A.P. et al. Concomitant chemoradiotherapy in pyriform sinus carcinoma. *Arch. Otolaryngol. Head Neck Surg*. 2002; 128 (4): 384-388
16. Balm AJM, Schornagel JH, Rasch CRN. De rol van gelijktijdige chemotherapie en radiotherapie bij de behandeling van lokaal uitgebreide tumoren van larynx, farynx en mondholte. *Ned Tijdschr Geneeskd*. 2005; 149(2): 61-64
17. Kraus DH, Pfister DG, Harrison LB et al. Salvage laryngectomy for unsuccessful larynx preservation therapy. *Ann Otol Rhinol Laryngol*. 1995; 104(12): 936-941
18. Sassler AM, Esclamado RM, Wolf GT. Surgery after organ preservation therapy: Analysis of wound complications. *Arch Otolaryngol head neck surg*. 1995; 121: 162-165
19. Teknos TN, Myers LL, Bradford CR, Chepeha DB. Free tissue reconstruction of the hypopharynx after organ preservation therapy: Analysis of wound complications. *Laryngoscope*. 2001; 111: 1192-1196

**Table I Primary tumour site and classification in the chemoradiation group**

Primary site	Classification
Supraglottic larynx	<p>T4N3M0, T2N2cM0,  T3N2cM0, T4N1M0,  T3N0M0, T3N2bM0,  T3N2aM0, T3N2cM0</p>
Hypopharynx	<p>T4N2cM0, T2N2aM0 ,  T2N2aM0, T4N1M0,  T3N0M0, T4N2cM0,  T3N0M0, T3N2cM0,  T4N2aM0, T4N2cM0,T3N2bM0</p>
Base of Tongue	<p>T4N2bM0, T4N0M0,  T4N2cM0, T4N1M0,  T4N2bM0</p>

**Table II      Primary tumour site and classification in the radiation group**

Primary site	Classification
Larynx    N=97	<p>TisN0M0    N=5</p> <p>T1N0M0    N=20</p> <p>T2N0M0    N=46</p> <p>T3N0M0    N=14</p> <p>T4N0M0    N=2</p> <p>T2N1M0    N=4</p> <p>T3N1M0    N=4</p> <p>T2N2cM0    N=1</p> <p>T3N2cM0    N=1</p>
Hypopharynx    N=6	<p>T1N0M0    N=3</p> <p>T2N0M0    N=1</p> <p>T4N0M0    N=1</p> <p>T2N1M0    N=1</p>

**Table III      Operations performed as salvage surgery after chemoradiation**

Operation	N =
Total laryngectomy, partial pharyngectomy, unilateral neck dissection	3
Total laryngectomy, partial pharyngectomy, bilateral neck dissection	3
Total laryngectomy, total pharyngectomy, free jejunum graft	2
Total laryngectomy, total pharyngectomy, free jejunum graft, unilateral neck dissection	3
Total laryngectomy, total pharyngectomy, free jejunum graft, bilateral neck dissection	1
Total laryngectomy, partial pharyngectomy, Pectoralis major flap	1
Total laryngectomy, partial pharyngectomy, unilateral neck dissection, Pectoralis major flap	3
Total laryngectomy, partial pharyngectomy, bilateral neck dissection, Pectoralis major flap	5
Total laryngectomy, partial pharyngectomy	2
Total laryngectomy, total pharyngectomy, free jejunum graft, unilateral neck dissection, Pectoralis major flap	1

Table IV                      Operations performed as salvage surgery after radiotherapy

Operation	N =
Total laryngectomy, partial pharyngectomy, unilateral neck dissection	16
Total laryngectomy, partial pharyngectomy, bilateral neck dissection	6
Total laryngectomy, total pharyngectomy, free jejunum graft	1
Total laryngectomy, total pharyngectomy, free jejunum graft, unilateral neck dissection	1
Total laryngectomy, total pharyngectomy, free jejunum graft, bilateral neck dissection	1
Total laryngectomy, partial pharyngectomy, unilateral neck dissection, Pectoralis major flap	9
Total laryngectomy, partial pharyngectomy, bilateral neck dissection, Pectoralis major flap	2
Total laryngectomy, partial pharyngectomy	66
Total laryngectomy, partial pharyngectomy, radial forearm free flap	1

**Table V Post-operative complications**

	Complications	chemoradiation N =	Radiotherapy N=
< 3 months	Postoperative haemorrhage	5 (21%)*	3 (3%)
	Wound dehiscence	7 (29%)	15 (15%)
	Fistula	12 (50%)*	20 (19%)
	Ischemic jejunum graft	1 (4%)	-
	Pneumothorax	1 (4%)	-
	CVA	2 (8%)	-
	Infection of urogenital tract	1 (4%)	-
	Bleeding of stomach	2 (8%)	3 (3%)
	Pneumonia	-	2 (2%)
	Death		
	> 3 months	swallowing dysfunction	6 (25%)
Speech problems		2 (8%)	-
Fistula		2 (8%)	1 (1%)
Constriction of tracheostoma		5 (21%)*	9 (9%)
Pain		1 (4%)	-
Wound dehiscence			

\*: There is a significant difference ( $p < 0.05$ ) between the two groups.



Table VI Results from EORTC QLQ – C30 questionnaire <sup>7,8</sup>

	TLE after chemoradiation Median	TLE after radiotherapy Median
Global health status	6	5
Functional scales		
Physical functioning	1.4	1.4
Role functioning	1.3	1.8
Emotional functioning	1.3	1.0
Cognitive functioning	1.5	1.0
Social functioning	2.0*	1.0
Symptoms scales		
Fatigue	1.7	1.3
Nausea and vomiting	1.0	1.0
Pain	1.0	1.0
Dyspnoea	2.0	2.0
Insomnia	2.0	1.0
Appetite loss	1.0	1.0
Constipation	1.0	1.0
Diarrhoea	1.0	1.0
Financial difficulties	2.0	1.0

\*: There is a significant difference ( $p < 0.05$ ) between the two groups.

Table VII Results from EORTC QLQ – H & N 35 questionnaire <sup>9</sup>

	TLE after chemoradiation Median	TLE after radiotherapy Median
Pain	1.3*	1.0
Swallowing	1.5	1.3
Senses problems	2.5	2.5
Speech problems	1.7	1.3
Trouble with social eating	1.5*	1.0
Trouble with social contact	1.2	1.0
Less sexuality	1.0	2.3
Teeth	1.0	1.0
Opening mouth	1.0	1.0
Dry mouth	1.0	1.0
Sticky saliva	2.0*	1.0
Coughing	1.0	1.0
Felt ill	1.0	1.0
Pain killers	1.0	1.0
Nutritional supplements	1.0	1.0
Feeding tube	1.0	1.0
Weight loss	1.0	1.0
Weight gain	1.0	1.0

\*: There is a significant difference ( $p < 0.05$ ) between the two groups.

## **Chapter VII**

**General discussion**

The larynx is the most commonly involved site of head and neck cancer in the Netherlands.<sup>1</sup> Tumours may arise from any of the three subsites of the larynx: supraglottis (30%), glottis (66%) and subglottis (4%). Tumours in different subsites have a different prognosis, which is reflected in treatment protocols.

The Dutch Cooperative Group for Head and Neck Tumours (NWHHT) has established a guideline for treatment of laryngeal carcinoma in the different sites and stages.<sup>2</sup>

Treatment of laryngeal cancer is aimed at tumour control, with increasing emphasis on organ preservation, the organ being a *functional* larynx.

It has been shown that this approach does not compromise survival and it is nowadays the treatment of choice in the majority of patients, even in patients with advanced stage disease.<sup>2</sup>

The Dutch guideline for treatment of laryngeal carcinomas can be summarized as follows.

Carcinoma in situ (T<sub>is</sub>) or severe dysplasia of the vocal cords should preferably be treated by endoscopic decortification with CO<sub>2</sub>-laser.<sup>3</sup> Radiotherapy is a good alternative. CO<sub>2</sub>-laser treatment is preferable to radiotherapy because it can be used repeatedly, while radiotherapy is reserved for bigger recurrences or second primary tumours.<sup>2</sup>

Treatment of choice for T1-laryngeal carcinoma of all sites is radiotherapy. In case of superficial growing T1a-carcinoma of the vocal cords, CO<sub>2</sub>-laser treatment is a good alternative.

For T2-larynx carcinoma with normal mobility of the vocal cords conventional radiotherapy is the treatment of choice. For T2-carcinomas with impaired vocal cord mobility accelerated radiotherapy is advocated.

T3 and T4-carcinomas of all sites are treated with accelerated radiotherapy. In case of massive cartilage destruction or tumour growth into the soft tissues of the neck, or in case of high stage disease with large tumour bulk and functional impairment of the larynx, multimodality therapy (usually surgery followed by radiotherapy) is indicated. For small supraglottic laryngeal carcinoma a horizontal supraglottic laryngectomy or endoscopic partial laryngectomy is a good alternative. However, there are criteria, which should be followed strictly for a good result. Patients with a poor pulmonary status and swallowing disorders are not the best candidates for a supraglottic laryngectomy. In the direct post-operative period, there is a high risk for aspiration and this might result in complications in patients with poor pulmonary status. High age (65-70 years) is considered to be a contraindication. In our opinion biological age should not be a contraindication *per se*. The co-morbidity should be considered a contraindication as eluded on in chapters II and III.

Accelerated radiotherapy achieves better tumour control than conventional radiotherapy, but the short-term side effects are more severe. In some institutes, such as Rotterdam, all head and neck cancers are treated with accelerated radiotherapy. It must be noted that according to the NWHHT guidelines chemoradiation is still considered to be experimental.<sup>2</sup>

The golden standard for treatment of recurrent laryngeal cancer after radiotherapy is a total laryngectomy. Total laryngectomy usually allows for wide surgical margins, while modern speech prostheses, inserted during the operation, provide good speech rehabilitation. However, although opposed by some surgeons, a partial laryngectomy is a

good alternative to total laryngectomy in selected (chapter II and III) radiotherapy failures. Unlike total laryngectomy, which is a well-defined operation, a partial laryngectomy is not more than a term nominating a number of technically very different procedures all aimed at preserving part of the larynx. The goal of partial laryngectomy is adequate tumour control, while preserving a “natural” and functional larynx, avoiding a tracheostoma. It is generally assumed that partial laryngectomies result in a better quality of life compared to total laryngectomy. Two types of partial laryngectomy for recurrent glottic cancer, endoscopic laser surgery and frontolateral partial laryngectomy, are discussed (Chapter II). It is shown in our study and the literature <sup>4,5</sup> that in 44% of the patients with tumour extension in the anterior commissure and 58 % of the patients without extension in the anterior commissure, the larynx can be preserved with CO<sub>2</sub>-laser treatment. Outcome is worse when recurrences extend into the anterior commissure compared to unilateral extension. A radical removal of the tumour extended in the anterior commissure is difficult and therefore considered a contra-indication. These tumours are also difficult to visualize completely with an endoscope. Before 1997 an external approach was not offered in our institute and some patients refused a total laryngectomy for small recurrent tumours. Although they were told that the recurrence rate was higher because of anterior commissure involvement, they chose for CO<sub>2</sub>-laser treatment. Important is the finding that failure of laser treatment for recurrent glottic cancer does not compromise survival, and that these patients can still be salvaged with a total laryngectomy.

Tumours that extend into the anterior commissure are better treated with an external approach. An external approach provides wider access and better visualization of the tumour, resulting in better surgical margins. In 83% of the patients treated with a frontolateral partial laryngectomy tumour control was achieved with preservation of the larynx. In the literature control rates vary from 75% to 100%.<sup>6-10</sup> Both laser surgery and frontolateral partial laryngectomy resulted in good functional results. We concluded that if the surgeon is familiar with the different techniques of and indications for partial laryngectomy, this could be a good and satisfying treatment in a selected patient group with recurrent glottic cancer. The selection criteria for the various procedures are described in chapter II.

Another external partial procedure is the supracricoid laryngectomy with cricohyoidoepiglottopexy (CHEP) (chapter III). The concept of this procedure is very different from the concept of the procedures described above. While in case of laser surgery and fronto-lateral partial laryngectomy as much of the larynx is preserved in order to *maintain* a functional unit, in case of supracricoid laryngectomy with CHEP non-diseased tissue is resected in order to *create* a new functional unit. It had been shown that this procedure achieves good oncological and functional outcome in the primary treatment of early glottic cancer,<sup>11-14</sup> but few reports address supracricoid laryngectomy with CHEP for radiation failures. The scarce information available, indicates that concern exists about functionality of the remaining larynx after previous radiotherapy. The healing period and therefore the rehabilitation period might be complicated and prolonged due to the effect of radiotherapy on the tissue. In our series of fourteen patients with a recurrence after radiotherapy treated with a supracricoid laryngectomy with CHEP, no local recurrences and 2 regional recurrences were found. Although, the follow up period of this study is relatively short (average 16 months). The disease free

survival in the literature of the supracricoid laryngectomy with CHEP after radiotherapy varies from 83-100%.<sup>15-16</sup> But also in these studies the follow-up period is also relatively short ( 36 months<sup>16</sup>) and the patient groups are small, the largest group being fifteen patients.<sup>16</sup> This is understandable because the selection criteria for the supracricoid laryngectomy after irradiation failure are strict and should be followed without concessions. If concessions are made there is a high risk of poor function and increased risk of irradical margins.

Functional evaluation after the supracricoid laryngectomy with CHEP was measured with flexible endoscopic evaluation of swallowing (FEES) and voice evaluation in a subgroup of eight patients. We found that swallowing was uncompromised. Pre-and post-operative voice evaluation was performed in five patients. The voice measured after the operation is worse than pre-operatively. However, eight patients were subjectively satisfied with their voice. Two patients with a very soft voice were dissatisfied. An explanation for satisfaction with a poor voice could be that most patients are elderly and do not use their voice professionally.

We conclude that supracricoid laryngectomy with cricohyoidoepiglottopexy (CHEP) for recurrent glottic laryngeal cancer after radiotherapy appears to be oncologically safe and generally gives good functional results. Ongoing experience with the different partial procedures has resulted in a shift from fronto-lateral partial laryngectomy towards supracricoid laryngectomy with CHEP in our practice. The main reason is better surgical margins. Also patients after supracricoid laryngectomy with CHEP are less likely to encounter airway problems. The drawback of this procedure however is aspiration, particularly during the rehabilitation period, making it less suitable for pulmonary compromised patients.

The treatment of laryngeal cancer has a great impact on a person's life. In particular total laryngectomy affects crucial functions such as breathing, swallowing and speaking. Moreover, after a total laryngectomy patients have a permanent tracheostoma. There is a cosmetic aspect and some activities, such as swimming, cannot be done as before. They will need special care in order to swim. We investigated the quality of life after partial laryngectomy versus total laryngectomy for recurrent laryngeal carcinomas. (Chapter 4) Twenty-three patients (N=12 partial laryngectomy, N=11 total laryngectomy) with recurrent laryngeal cancer after radiotherapy were included in the study. Quality of life was measured with two questionnaires: (1) EORTC Quality of Life Questionnaire (QLQ) – C30 Dutch version 3.0, (2) EORTC – H & N 35. The only significant differences in quality of life were found to be smell and taste related, however by and large both groups scored equally well.

The speech rehabilitation was evaluated with the Voice Handicap Index. Here also no differences were found. This result was much in contrast to our expectations. We had expected a worse quality of life after a total laryngectomy. One of the reasons why we expected to be so was a cosmetic aspect; a second reason was a permanent tracheostoma; and a third reason what was known from the literature<sup>17,18</sup> describing a better quality of life after a partial laryngectomy versus total laryngectomy. Part of the explanation of our findings is that the questionnaires are not larynx specific and a number of specific differences, such as influence of a permanent tracheostoma, changing speaking valves regularly, may have been missed. Most important is the finding that quality of life of patients after total laryngectomy is better than we had expected

LoTempio et al<sup>18</sup> evaluated quality of life between surgery (total laryngectomy) and organ preservation therapy. They also found no significant differences between the two groups.

The implication of these findings is that the selection criteria for partial laryngectomy are crucial for the success and that they should be followed strictly. The saying “if in doubt, take it out” does reflect our point of view.

Hypopharyngeal carcinomas have the worst prognosis of all head and neck cancers. Tumours metastasise early and patients frequently present with late stage disease.

Unlike for laryngeal carcinoma, the NWHHT has not established consensus guidelines for treatment of hypopharyngeal carcinoma yet. These are expected to be published in 2006. A retrospective inventory of treatment protocols and outcome in the eight head and neck centres in the Netherlands has however been performed in the late nineties (Chapter 5). Between 1985 and 1994 eight hundred ninety-three patients were treated for hypopharyngeal carcinoma in the Netherlands. It was found that the treatment protocols during this period mostly consisted of surgery and radiotherapy, radiotherapy alone or surgery alone. Chemoradiation protocols were very rare at that time (36 of 704 patients).

The overall 5-year survival for patients treated with curative intention was 32%, while the overall survival in the entire group was only 26%. The best results were achieved with multimodality therapy: surgery and radiotherapy. The 5-year survival rate in the literature<sup>20,21</sup> for combined surgery and radiotherapy varies between 25% and 60%.

Given the poor prognosis of these tumours, an alternative to total laryngectomy with relatively high morbidity is important. Chemoradiation, a multimodality treatment that preserves the larynx, has gained popularity over recent years, now being the standard treatment for advanced stage head and neck cancer in many centres. Initially, chemoradiation protocols mostly consisted of induction chemotherapy followed by radiotherapy. The current approach is concomitant chemotherapy and radiotherapy. It is felt this gives a superior tumour control,<sup>22</sup> but on the other hand toxicity and consequently morbidity is increased. The most important reasons to shift from an existing treatment protocol to a new treatment protocol are: 1.) better tumour control / improved survival and/or 2.) reduction of morbidity. In regard to organ preservation several studies<sup>23,24</sup> described that radiotherapy with neoadjuvant chemotherapy is a more effective treatment strategy for hypopharyngeal carcinoma than radiotherapy alone.

On the other hand, a large randomised trial<sup>25</sup> in Europe showed no difference in survival after treatment with induction chemotherapy and radiotherapy compared to surgery and radiotherapy in the treatment of hypopharyngeal carcinoma. However, with combined chemotherapy and radiotherapy the larynx can be preserved in the majority of patients.<sup>23,24,26,27</sup> These findings *suggest* that morbidity can be reduced without compromising cure. However, these studies do not address quality of life and the function of the larynx was never evaluated. It was recently shown<sup>28</sup> that laryngeal functions were impaired after combined treatment with chemotherapy and radiotherapy in a group of patients with advanced stage laryngeal or hypopharyngeal cancer. In this study voice and swallowing were evaluated after chemoradiation. Vocal analysis showed normal results in 1 patient, mild dysphonia in 4, moderate dysphonia in 6, and severe dysphonia in 4 patients. Functional swallowing was seen in 3 patients, mild dysphagia in

7, moderate dysphagia in 2, and severe dysphagia in 2. The success of combined treatment with chemotherapy and radiotherapy is mostly based on disease free survival. The short-term complications and larynx function after treatment are factors which should be investigated, because they may significantly contribute to treatment decisions. Another issue to consider is surgery after chemoradiation. It is known that the quality of tissues is poor after chemoradiation and surgery in general can be difficult and is frequently accompanied by complications.<sup>29-33</sup> Chemotherapy seems to have an additional effect to radiotherapy to the impairment of wound healing. For example, the extent of fibrosis and obliterative endarteritis can increase with combined treatment.<sup>33</sup> In case of recurrent or residual hypopharyngeal cancer, surgery is the only treatment option left. Complications after surgery and quality of life of twenty-four patients who underwent salvage laryngectomy after chemoradiation were studied. (Chapter VI) The control group consisted of 103 patients who underwent salvage laryngectomy after radiotherapy alone. The complication rate in the direct post-operative period was significantly higher (92% vs. 50%) in the chemoradiation group. The most frequent complication found was a pharyngocutaneous fistula. Quality of life, measured at least two years after salvage surgery, showed that social functioning of the chemoradiation group was significantly worse than of the control group. It must be noted that the majority of patients in the study were treated with induction chemotherapy followed by radiotherapy. Concomitant chemoradiation might even result in a higher short *and* long-term morbidity, because of increased toxicity.

Organ preservation protocols for laryngeal and hypopharyngeal cancer in all different forms anatomically preserve the organ while they appear to have a similar oncological outcome compared to surgery and radiotherapy. They can however cause a substantial amount of morbidity and the *function* of the organ may not always be preserved. Furthermore salvage surgery usually requires more extensive surgery and is frequently followed by complications (delayed wound healing, pharyngocutaneous fistula). Long-term functional outcome and quality of life after chemoradiation protocols for cancer of the larynx and hypopharynx are issues that deserve further attention in the near future. As in partial laryngectomy after radiotherapy, we must remain critical of indications and side effects of chemoradiation protocols while we should realize that quality of life after total laryngectomy is not as poor as we might sometimes think.



## References

1. J.A.A.M. van Dijck, J.W.W. Coebergh, S. Siesling, O. Visser. Trends of cancer in the Netherlands 1989-1998. Utrecht: Vereniging van Integrale Kankercentra, 2002
2. Nederlands Werkgroep Hoofd-Halstumoren. Richtlijn larynxcarcinoom. 1999
3. Maurizi M, Almadori G, Plaudetti G, Eugenio D, Galli J. Laser carbon dioxide cordectomy versus open surgery in the treatment of glottic carcinoma: Our results. *Otolaryngol Head Neck Surg.* 2005; 132: 857-861
4. BlakesleeD, Vaughan CW, Shapsay SM, Simpson GT, Strong MS. Excisional biopsy in selective management of T1 glottic cancer: a three-year follow-up study. *Laryngoscope.* 1984; 94: 488-494
5. Casiano RR, Cooper JD, Lundy DS, Chandler JR. Laser cordectomy for T1 glottic carcinoma: A 10-year experience and videostroboscopic findings. *Otolaryngol Head Neck Surg.* 1991; 104:831-837
6. Kooper DP, van den Broek P, Manni JJ, Tiwari RM, Snow GB. Partial vertical laryngectomy for recurrent glottic carcinoma. *Clin Otolaryngol.* 1995; 20: 167-170
7. Watters GW, Patel SG, Rhys-Evans PH. Partial laryngectomy for recurrent laryngeal carcinoma. *Clin Otolaryngol.* 2000; 25(2): 146-152
8. Rodriguez- Cuevas S, Labastida S, Gonzalez D, Briseno L, Cortes H. Partial laryngectomy as salvage surgery for radiation failures in T1-T2 laryngeal cancer. *Head Neck.* 1998; 20(7):630-633
9. Schwaab G, Mamelle G, Lartigau E, Parise O Jr, Wibault P, Luboinski B. Surgical salvage treatment of T1/T2 glottic carcinoma after failure of radiotherapy. *Am J Surg.* 1994; 168(5): 474-475
10. Nichols RD, Mickelson SA. Partial laryngectomy after irradiation failure. *Ann Otol Laryngol.* 1991; 100(3):176-180
11. Bron L, Brossard E, Monnier P, Pasche P. Supracricoid partial laryngectomy with cricohyoidoepiglottopexy and cricohyoidopexy for glottic and supraglottic carcinomas. *Laryngoscope.* 2000; 110: 627-634
12. Karasalihoglu AR, Yagiz R, Tas A, Uzun C, Adalli MK, Koten M. Supracricoid partial laryngectomy with cricohyoidopexy and cricohyoidoepiglottopexy: functional and oncological results. *J Laryngol Otol.* 2004; 118:671-675
13. Piquet JJ, Chevalier D. Subtotal laryngectomy with cricohyoidoepiglottopexy for the treatment of extended glottic carcinomas. *Am J Surg.* 1991; 162: 357-361
14. Chevalier D, Laccoureye O, Brasnu D, Laccoureye H, Piquet JJ. Cricohyoidoepiglottopexy for glottic carcinoma with fixation or impaired motion of the true vocal cord: 5-year oncologic result with 112 patients. *Ann Otol Rhinol Laryngol.* 1997; 106: 364-369
15. Laccoureye O, Weinstein GS, Naudo P, Cauchois R, Laccoureye H, Brasnu D. Supracricoid partial laryngectomy after failed laryngeal radiation therapy. *Laryngoscope* 1996 ;106(4):495-498
16. Spriano G, Pellini R, Romano G, Muscatello L, Roselli R. Supracricoid partial laryngectomy as salvage surgery after radiation failure. *Head&Neck* 2002;24(8):759-64

17. Weinstein GS, El-Sawy MM, Ruiz C et al. Laryngeal preservation with supracricoid partial laryngectomy results in improved quality of life when compared with total laryngectomy. *Laryngoscope* 2001; 111: 191-199
18. Smith JC, Johnson JT, Cognetti DM, et al. Quality of life, functional outcome, and costs of early glottic cancer. *Laryngoscope* 2003; 113: 68-76
19. Lo Tempio MM, Wang KH, Sadeghi A, Delacure MD, Juillard GF, Wang MB. Comparison of quality of life outcomes in laryngeal cancer patients following chemoradiation vs. total laryngectomy patients. *Otolaryngol Head and Neck Surg.* 2005; 132(6): 948-953
20. Lajtmam Z, Manestar D. A comparison of surgery and radiotherapy in the management of advanced pyriform fossa carcinoma. *Clin Otolaryngol* 2001; 26: 59-61
21. Loré JM, Kaufman S, Sundquist N, Chary KK. Carcinoma of the head and neck: A 5- to 20-year experience with preoperative chemotherapy, uncompromised surgery, and selective radiotherapy. *Ann Surg Oncol.* 2003;10(6): 645-653
22. Pignon JP, Bourhis J, Domenge C, Designé L. Chemotherapy added to locoregional treatment for head and neck squamous-cell carcinoma: three meta-analyses of updated individual data. *Lancet.* 2000; 355: 949-955
23. Prades JM, Schmitt TM, Timoshenko AP et al. Concomitant chemoradiotherapy in pyriform sinus carcinoma. *Arch Otolaryngol Head Neck Surg.* 2002; 128: 384-388
24. Kim S, Wu HG, Heo DS, Sung MW, Park CI. Advanced hypopharyngeal carcinoma treatment results according to treatment modalities. *Head Neck.* 2001; 23(9): 713-717
25. Lefebvre JL, Chevalier D, Luboinski B, Kirkpatrick A, Collette L, Sahnoud T. Larynx preservation in pyriform sinus cancer: preliminary results of a European Organization for Research and Treatment of Cancer phase III trial. EORTC Head and Neck Cancer Cooperative Group. *J Nat Cancer Inst.* 1996; 88(13): 890-899
26. Wei WI. The dilemma of treating hypopharyngeal carcinoma: more or less. *Arch Otolaryngol Head Neck Surg.* 2002; 128: 229-232
27. Adelstein DJ, Lavertu P, Saxton JP et al. Mature results of a phase III randomized trial comparing concurrent chemoradiotherapy with radiation therapy alone in patients with stage II and IV squamous cell carcinoma of the head and neck. *Cancer.* 2000; 88: 876-893
28. Carrara-de Angelis E, Feher O, Brandao Barros AP, Nishimoto IN, Kowalski LP. Voice and swallowing in patients enrolled in a larynx preservation trial. *Arch Otolaryngol Head and Neck Surg.* 2003; 129: 733-738
29. Lavertu P, Bonafede JP, Adelstein DJ et al. Comparison of surgical complications after organ-preservation therapy in patients with stage III or IV squamous cell head and neck cancer. *Arch Otolaryngol head neck surg.*1998; 124: 401-406
30. Sassler AM, Esclamado RM, Wolf GT. Surgery after organ preservation therapy : Analysis of wound complications. *Arch Otolaryngol head neck surg.*1995; 121: 162-165
31. Newman JP, Terris DJ, pinto HA et al. Surgical morbidity of neck dissection after chemoradiotherapy in advanced head and neck cancer. *Ann otol Rhinol laryngol.* 1997; 106: 117-122

32. Ganly I, Patel S, Matsuo J et al. Postoperative complications of salvage total laryngectomy. *Cancer*. 2005; 103: 2073-2081
33. Gokhale AS, Lavertu JP. Surgical salvage after chemoradiation of head and neck cancer: Complications and outcomes. *Curr Oncol Rep*. 2001; 3(1): 72-76



## References used for this Thesis

1. J.A.A.M. van Dijck, J.W.W. Coebergh, S. Siesling, O. Visser. Trends of cancer in the Netherlands 1989-1998. Utrecht: Vereniging van Integrale Kankercentra, 2002
2. Paparella, Shumsick, Gluckman, Meyerhof. *Otolaryngology*. 1999
3. K. Szyfter, Z. Szmeja et al. Molecular and cellular alterations in tobacco smoke-associated larynx cancer. *Mutation research*. 1999; 445: 259-274
4. W.M. Koch. Molecular biology of head and neck tumours. *Otolaryngology – head and neck surgery*, 3<sup>rd</sup> edn. 1998
5. P. Boffeta, W. Ye et al. Risk of cancers of the lung, head and neck in patients hospitalised for alcoholism in Sweden. *Br J cancer*. 2001; 85(5): 678-682
6. N. Homann. Alcohol and upper gastrointestinal tract cancer: the role of local acetaldehyde production. *Addict Biol*. 2001; 6(4): 309-323
7. Nederlands Werkgroep Hoofd-Halstumoren. Richtlijn larynxcarcinoom. 1999
8. Loré J.M., Kaufman S., Sundquist N. et al. Carcinoma of the head and neck: A 5- to 20-year experience with preoperative chemotherapy, uncompromised surgery, and selective radiotherapy. *Ann. Surg. Oncol*. 2003; 10(6), 645-653.
9. Lajtmam Z. & Manestar D. A comparison of surgery and radiotherapy in the management of advanced pyriform fossa carcinoma. *Clin. Otolaryngol*. 2001; 26, 59-61.
10. Toma M, Nibu K, Nakao K et al. Partial laryngectomy to treat early glottic cancer after failure of radiation therapy. *Arch Otolaryngol Head Neck Surg*. 2002; 128:909-912.
11. Ferlito A, Silver CE, Howard DJ, Laccourreye O, Rinaldo A, Owen R. The role of partial laryngeal resection in current management of laryngeal cancer: a Collective review. *Acta Otolaryngol*. 2000; 120:456-465.
12. Groome PA, Macckillop WJ, Rothwell DM et al. Management and outcome of glottic cancer: a population-based comparison between Ontario, Canada and the SEER areas of the United States. *Surveillance, Epidemiology and end results*. 2000; 29(2):67-77.
13. Honocodevar-Boltežar I, Žargi M. Voice quality after radiation therapy for early glottic cancer. *Arch Otolaryngol Head and Neck Surg*. 2000; 126:1097-1100.
14. Nibu K, Kamata S, Kawabata K, Nakamizo M, Nigauri T, Hoki K. Partial laryngectomy in the treatment of radiation-failure of early glottic carcinoma. *Head Neck*. 1997; 19(2):116-120.
15. Moose BD, Greven KM. Definitive radiation management for carcinoma of the glottic larynx. *Otolaryngol Clin North Am*. 1997; 30(1):131-143.
16. Scheck PA, Mallios C, Knegt P, van der Schans EJ. High frequency ventilation in laser surgery of the larynx. *Clin Otolaryngol*. 1984; 9:203-207.
17. Weinstein GS, Laccourreye O. Vertical partial laryngectomys. In: *Organ preservation surgery for laryngeal cancer*. San Diego, California: Singular publishing group, 2000.59-71.
18. Nichols RD, Stine PH, Greenawald KJ. Partial vertical after radiation failure. *Laryngoscope*. 1980; 90(4):571-575.
19. Hirano M, Hirade Y. CO2 laser for treating glottic carcinoma. *Acta Otolaryngol*. 1988; 458:154-157.

20. Mc. Guirt FW, Koufman JA. Endoscopic laser surgery. An alternative in laryngeal cancer treatment. *Arch Otolaryngol Head Neck Surg.* 1987; 113:501-505.
21. Motta G, Esposito E, Cassiano B, Motta S. T1-T2-T3 Glottic tumours : Fifteen years experience with CO2 laser. *Acta Otolaryngol.* 1997; 527:155-159.
22. Wetmore J, Key JM, Suen JY. Laser therapy for T1 glottic carcinoma of the larynx. *Arch Otolaryngol Head Neck Surg.* 1986; 112:853-855.
23. Blakeslee D, Vaughan CW, Shapshay SM, Simpson GT, Strong MS. Excisional biopsy in selective management of T1 glottic cancer: a three-year follow-up study. *Laryngoscope.* 1984; 94:488-494.
24. Casiano RR, Cooper JD, Lundy DS, Chandler JR. Laser cordectomy for T1 glottic carcinoma: A 10-year experience and videostroboscopic findings. *Otolaryngol Head Neck Surg.* 1991; 104:831-837.
25. Outzen KE, Illum P. CO2-laser therapy for carcinoma of the larynx. *J Laryngol Otolology.* 1995; 109:111-113.
26. Kooper DP, van den Broek P, Manni JJ, Tiwari RM, Snow GB. Partial vertical laryngectomy for recurrent glottic carcinoma. *Clin Otolaryngol.* 1995; 20:167-170.
27. Watters GW, Patel SG, Rhys-Evans PH. Partial laryngectomy for recurrent laryngeal carcinoma. *Clin Otolaryngol.* 2000; 25(2):146-152.
28. Rodriguez- Cuevas S, Labastida S, Gonzalez D, Briseno L, Cortes H. Partial laryngectomy as salvage surgery for radiation failures in T1-T2 laryngeal cancer. *Head Neck.* 1998; 20(7):630-633.
29. Schwaab G, Mamelle G, Lartigau E, Parise O Jr, Wibault P, Luboinski B. Surgical salvage treatment of T1/T2 glottic carcinoma after failure of radiotherapy. *Am J Surg.* 1994; 168(5):474-475.
30. Nichols RD, Mickelson SA. Partial laryngectomy after irradiation failure. *Ann Otol Laryngol.* 1991; 100(3):176-180.
31. Hardillo J. Tracheal repair: from wound healing research to prefabricated reconstruction. Katholiek Universiteit Leuven, Leuven Belgium. Thesis. 2001.
32. Herranz J, Martinez-Vidal J, Gavilan J. Horizontal supraglottic laryngectomy: modifications to Alonso's technique. *Operative techniques in otolaryngology-head and neck surgery.* 1993; 4(4):252-257.
33. Lavey RS, Calcaterra TC. Partial laryngectomy for glottic cancer after high-dose radiotherapy. *Am J Surg.* 1991; 162(4):341-344.
34. Hilgers FJM, Ackerstaff AH. Comprehensive rehabilitation after total laryngectomy is more than voice alone. *Folia Phoniatr Logop* 2000;52:65-73.
35. Relic A, Mazemda P, Arens C et al. Investigating quality of life and coping resources after laryngectomy. *Eur Arch Otorhinolaryngol* 2001;258:514-517.
36. Spriano G, Pellini R, RomanoG, et al. Supracricoid partial laryngectomy as salvage surgery after radiation failure. *Head and Neck* 2002;24(8):759-765.
37. Bron L, Pasche P, Brossard E, et al. Functional analysis after supracricoid partial laryngectomy with cricothyroidoepiglottopexy. *Laryngoscope* 2002;112:1289-1293.
38. Müller R, Paneff J, Köllner V, et al. Quality of life of patients with laryngeal carcinoma: a post-treatment study. *Eur Arch Otorhinolaryngol* 2001;258:276-280.
39. Weinstein GS, El-Sawy MM, Ruiz C, et al. Laryngeal preservation with supracricoid partial laryngectomy results in improved quality of life when compared with total laryngectomy. *Laryngoscope* 2001;111:191-199.

40. Smith JC, Johnson JT, Cognetti DM, et al. Quality of life, functional outcome, and costs of early glottic cancer. *Laryngoscope* 2003;113:68-76.
41. Aaronson NK, Ahmedzai S, Bergman B, et al. The European Organization for Research and Treatment of Cancer QLQ-C30: a quality of life instrument for use in international clinical trials in oncology. *J Natl Cancer Instr* 1993;85:365-376.
42. Bjordal K, Ahlner-Elmqvist M, Tolleson E, et al. Development of a European Organization for Research and Treatment of Cancer (EORTC) questionnaire module to be used in quality of life assessments in head and neck cancer patients: EORTC Quality of Life Study Group. *Acta Oncol* 1994; 33:879-885.
43. Bjordal K, Hammerlid E, Ahlner-Elmqvist M, et al. Quality of life in head and neck cancer patients: validation of the European Organization for Research and Treatment of Cancer Quality of life Questionnaire – H & N 35. *J Clin Oncol* 1999;17:1008-1019.
44. Jacobson BH, Johnson A, Grywalski C, et al. The Voice Handicap Index (VHI): development and validation. *Am J of speech-language pathology* 1997;6:66-70.
45. Bron L, Brossard E, Monnier P, Pasche P. Supracricoid partial laryngectomy with cricothyroidoepiglottomy and cricothyroidomy for glottic and supraglottic carcinomas. *Laryngoscope* 2000;110:627-34.
46. Karasalioglu AR, Yagiz R, Tas A, Uzun C, Adalli MK, Koten M. Supracricoid partial laryngectomy with cricothyroidomy and cricothyroidoepiglottomy: functional and oncological results. *J Laryngol and Otol* 2004;118:671-75.
47. Weinstein GS, Laccoureye O, Ruiz C, Dooley P, Challian A, Mirza N. Larynx preservation with supracricoid partial laryngectomy with cricothyroidoepiglottomy. Correlation of videostroboscopic findings and voice parameters. *Ann Otol Rhinol Laryngol* 2002;111:1-7.
48. Piquet JJ, Chevalier D. Subtotal laryngectomy with cricothyroidoepiglottomy for the treatment of extended glottic carcinomas. *Am J Surg* 1991;162:357-61.
49. Chevalier D, Laccoureye O, Brasnu D, Laccoureye H, Piquet JJ. Cricothyroidoepiglottomy for glottic carcinoma with fixation or impaired motion of the true vocal cord: 5-year oncologic result with 112 patients. *Ann Otol Rhinol Laryngol* 1997;106:364-69.
50. Laccoureye O, Weinstein GS, Naudo P, Cauchois R, Laccoureye H, Brasnu D. Supracricoid partial laryngectomy after failed laryngeal radiation therapy. *Laryngoscope* 1996 ;106(4):495-98.
51. Dworkin JP, Meleca RJ, Zacharek MA, Stachler RJ, Pasha R, Abkarian GG, Culatta RA, Jacobs JR. Voice and deglutition functions after the supracricoid and total laryngectomy procedures for advanced stage laryngeal carcinoma. *Otolaryngol head neck surg* 2003;129(4):311-20.
52. Laccoureye O, Laccoureye H, El-Sawy M, Weinstein GS. Supracricoid partial laryngectomy with cricothyroidoepiglottomy. In: Organ preservation surgery for laryngeal cancer. San Diego, California: Singular publishing group, 2000;53-94.
53. Langmore SE. Endoscopic evaluation and treatment of swallowing disorders. New York: Thieme medical Publishers, Inc; 2001. p73-143.
54. Schutte HK, Seidner W. Recommendation by the Union of European Phoniaticians (UEP): standardizing voice area measurement/phonetography. *Folia Phoniatr (Basel)* 1983;35(6):286-88.

55. Wuyts FL, De Bodt MS, Molenberghs G, et al. The dysphonia severity index: an objective measure of vocal quality based on a multiparameter approach. *J Speech Lang Hear Res* 2000;43(3):796-809.
56. Luna-Ortiz K, Nunez-Valencia ER, Tamez-Velarde M, Granados-Garcia M. Quality of life and functional evaluation after supracricoid partial laryngectomy with cricothyroidoepiglottomy in Mexican patients. *J Laryngol Otol* 2004;118:284-88.
57. De Vincentiis M, Minni A, Gallo A, Di Nardo A. Supracricoid partial laryngectomies: oncological and functional results. *Head & Neck* 1998;20:504-09.
58. Ferrand CT. Harmonics-to-noise ratio: an index of vocal aging. *J Voice* 2002;16(4):480-87.
59. Pingree T.F., Davis R.K., Reichman O. et al. (1987) Treatment of hypopharyngeal carcinoma: a 10-year review of 1,362 cases. *Laryngoscope*. 97, 901-904
60. Prades J.M., Schmitt T.M., Timoshenko A.P. et al. (2002) Concomitant chemoradiotherapy in pyriform sinus carcinoma. *Arch. Otolaryngol. Head Neck Surg.* 128, 384-388.
61. Pignon J.P., Bourhis J., Domenge C. et al. (2000) Chemotherapy added to locoregional treatment for head and neck squamous-cell carcinoma: three meta-analyses of updated individual data. *Lancet*. 355, 949-955.
62. Kim S., Wu H.G., Heo D.S. et al. (2001) Advanced hypopharyngeal carcinoma treatment results according to treatment modalities. *Head and Neck*. 23(9), 713-717.
63. Sasaki C.T. & Jassin B. (2001) Cancer of the pharynx and larynx. *Am. J. Med.* 111(8a), 118s-123s.
64. Kraus D.H., Zelefsky M.J., Brock H.A. et al. (1997) Combined surgery and radiation therapy in the management of postcricoid carcinoma. *Clin. Otolaryngol.* 22, 370-374.
65. Wolf G.T., Hong W.K. & Fisher S.G. (1991) Induction chemotherapy plus radiation compared with surgery plus radiation in patients with advanced laryngeal cancer. The department of veterans affairs laryngeal cancer study group. *N. Engl. J. Med.* 324(24), 1685-1690
66. Wei W.I. (2002) The dilemma of treating hypopharyngeal carcinoma: more or less. *Arch Otolaryngol Head and Neck Surg.* 128, 229-232.
67. Lefebvre J.L., Chevalier D., Lubinski B. et al. (1996) Larynx preservation in pyriform sinus cancer : preliminary results of a European Organization for Research and Treatment of Cancer phase III trial. EORTC Head and Neck Cancer Cooperative Group. *J. Nat Cancer Inst.* 88(13), 890-899.
68. Adelstein D.J., Lavertu P., Saxton J.P. et al. (2000) Mature results of a phase III randomized trial comparing concurrent chemoradiotherapy with radiation therapy alone in patients with stage II and IV squamous cell carcinoma of the head and neck. *Cancer*. 88, 876-893.
69. Carrara-de Angelis E., Feher O., Brandao Barros A.P. et al. (2003) Voice and swallowing in patients enrolled in a larynx preservation trial. *Arch Otolaryngol Head and Neck Surg.* 129, 733-738.
70. Forastiere AA, Groppert H, Maor M et al. Concurrent chemotherapy and radiotherapy for organ preservation in advanced laryngeal cancer. *N Engl J Med.* 2003;349:2091-2098



71. Hanna E, Sherman E, Cash D et al. Quality of life for patients following total laryngectomy vs chemoradiation for laryngeal preservation. Arch Otolaryngol head neck surg.2004;130:875-879
72. Agra IMG, Carvalho AL, Pontes E et al. Postoperative complications after en bloc salvage surgery for head and neck cancer. Arch Otolaryngol head neck surg.2003;129:1317-1319
73. Leon X, Quer M, Orus C et al. Results of salvage surgery for local or regional recurrence after larynx preservation with induction chemotherapy and radiotherapy. Head Neck.2001;23:733-738
74. Lavertu P, Bonafede JP, Adelstein DJ et al. Comparison of surgical complications after organ-preservation therapy in patients with stage III or IV squamous cell head and neck cancer. Arch Otolaryngol head neck surg.1998;124:401-406
75. Balm AJM, Schornagel JH, Rasch CRN. De rol van gelijktijdige chemotherapie en radiotherapie bij de behandeling van lokaal uitgebreide tumoren van larynx, farynx en mondholte. Ned Tijdschr Geneesk.2005;149(2):61-64
76. Kraus DH, Pfister DG, Harrison Lb et al. Salvage laryngectomy for unsuccessful larynx preservation therapy. Ann Otol Rhinol Laryngol. 1995;104:936-941
77. Sassler AM, Esclamado RM, Wolf GT. Surgery after organ preservation therapy : Analysis of wound complications. Arch Otolaryngol head neck surg.1995;121:162-165
78. Teknos TN, Myers LL, Bradford CR, Chepeha DB. Free tissue reconstruction of the hypopharynx after organ preservation therapy: Analysis of wound complications. Laryngoscope.2001;111:1192-1196
79. Maurizi M, Almadori G, Plaudetti G, Eugenio D et al. Laser carbon dioxide cordectomy versus open surgery in the treatment of glottic carcinoma : Our results. Otolaryngol Head Neck Surg 2005;132:857-861
80. Lo Tempio MM, Wang KH, Sadeghi A, delacure MD et al. Comparison of quality of life outcomes in laryngeal cancer patients following chemoradiation vs. total laryngectomy patients. Otolaryngol Head and Neck Surg 2005; 132(6):948-953
81. Newman JP, Terris DJ, pinto HA et al. Surgical morbidity of neck dissection after chemoradiotherapy in advanced head and neck cancer. Ann otol Rhinol laryngol. 1997; 106:117-122



## **Samenvatting**

De primaire behandeling van het larynx- en hypofarynx carcinoom vindt het laatste decennium in toenemende mate “orgaansparend”, d.w.z. larynx-sparend, plaats. In geval van het larynxcarcinoom betreft de verandering voornamelijk een verschuiving van standaard bestralingsprotocollen naar gehyperfractioneerde radiotherapie, terwijl hypopharynxcarcinomen tegenwoordig vaak behandeld worden met een combinatie van chemotherapie en radiotherapie in plaats van primaire chirurgie. De belangrijkste verschuiving in behandelprotocollen hebben zich daardoor afgespeeld op het gebied van het hypopharynxcarcinoom. Doel van dit proefschrift is in de eerste plaats te onderzoeken of de larynx bij een recidief larynxcarcinoom na bestraling ook orgaansparend behandeld kan worden en wat voor gevolgen sparende chirurgie voor de larynx functies (slikken en spreken) heeft.

De tweede doelstelling van dit proefschrift is een beeld te krijgen van behandelprotocollen voor het hypopharynx carcinoom in Nederland en wat de verschuiving naar chemoradiatie protocollen voor gevolgen heeft voor de chirurgische behandeling van de recidief carcinomen.

Hoofdstuk 1 is een algemene inleiding over het larynx- en hypopharynxcarcinoom. De incidentie van het larynx- en hypofarynxcarcinoom wordt beschreven en de grootste risicofactoren, i.e. roken en alcohol. In het bijzonder wordt op het effect van sigarettenrook op het ontstaan van larynx- en hypofarynxcarcinomen nader ingegaan. Sigarettenrook bevat diverse stoffen die mutaties in genen kunnen veroorzaken. Deze mutaties hebben invloed op enzym-systemen en celregulatie-systemen, waardoor een maligne onttaarding van het plaveisel epitheel wordt bevorderd. Verder wordt in dit hoofdstuk een overzicht gegeven over de andere hoofdstukken van dit proefschrift.

In hoofdstuk 2 worden twee partiële laryngectomie technieken beschreven. De indicaties voor deze twee technieken worden weergegeven. De oncologische en functionele resultaten van de endoscopische CO<sub>2</sub>-laser behandeling en de fronto-laterale partiële laryngectomie voor de behandeling van het recidief glottisch larynxcarcinoom worden beschreven. Beide technieken hebben goede oncologische resultaten en er worden weinig functionele problemen gevonden. Met de CO<sub>2</sub> laser geneest 44% (uitbreiding in de voorste commissuur) en 58% (zonder uitbreiding in de voorste commissuur) met behoud van hun larynx en met de fronto-laterale partiele laryngectomie in 71%. Belangrijk is dat in geval van een nieuw recidief zonder toegenomen risico op uiteindelijk behandelfalen alsnog een laryngectomie verricht kan worden. De conclusie luidt dat de beschreven partiële laryngectomie technieken, CO<sub>2</sub> laser en de fronto-laterale partiele laryngectomie, goede behandelings-modaliteiten zijn voor het recidief glottisch larynxcarcinoom, mits men zich strikt aan de indicaties houdt.

In hoofdstuk 3 worden de functionele en oncologische resultaten van een derde partiële laryngectomie techniek, de cricohyoïdoepiglottopexy (CHEP), beschreven. Met de CHEP kan de larynx behouden blijven in 79% van de patiënten. Bij acht patiënten is het slikken post-operatief onderzocht door middel van Flexible Endoscopic Evaluation of Swallowing (FEES). Aspiratie is bij geen van de patiënten vastgesteld. De stem is pre- en post-operatief opgenomen en beoordeeld. De stem is slechter na de operatie, hoewel de meeste patiënten subjectief tevreden zijn. Onze conclusie is dat de cricohyoïdoepiglottopexy (CHEP) oncologisch verantwoord lijkt en functioneel is voor de behandeling van het recidief glottisch larynxcarcinoom bij geselecteerde patiënten.

In hoofdstuk 4 wordt het verschil in kwaliteit van leven onderzocht na behandeling van het recidief larynx carcinoom tussen een partiële laryngectomie en een totale laryngectomie. Daaronder wordt ook de stem tussen de twee patiënten groepen apart beoordeeld. Met behulp van de EORTC Quality of Life Questionnaire (QLQ) – C30 Dutch version 3.0 en de EORTC – H & N 35 is de kwaliteit van leven onderzocht. Het verschil dat gevonden is, betreft de kwaliteit van de reuk en smaak. De stem is beoordeeld met de Voice Handicap Index. Er zijn geen verschillen gevonden. Onze conclusie luidt dat er weinig verschil in kwaliteit van leven is tussen behandeling met een partiële danwel totale laryngectomie.

In hoofdstuk 5 wordt de behandeling van het hypofarynxcarcinoom in Nederland beschreven. De behandeling van het hypofarynxcarcinoom in de periode tussen 1985 en 1994 in Nederland is bekeken. De grootste groep patiënten is behandeld met radiotherapie of met chirurgie gecombineerd met radiotherapie. De overall 5-jaars ziekte-vrije overleving na curatieve behandeling is 32%. De ziekte-vrije overleving is beter na combinatie-therapie.

In hoofdstuk 6 is gekeken naar complicaties van salvage chirurgie (chirurgie vanwege een recidief of residu carcinoom) bij patiënten die eerder behandeld zijn geweest met uitsluitend chemoradiatie of met radiotherapie. Het aantal complicaties in de post-operatieve periode is significant hoger (92% vs. 50%) in de chemoradiatie groep. De meest voorkomende complicatie is een faryngo-cutane fistel. Kwaliteit van leven, na een langere post-operatieve periode, laat een significant verschil in sociaal functioneren zien ten nadele van patiënten na chemoradiatie.

In de discussie (hoofdstuk 7) wordt een beschouwing van de gevonden resultaten gegeven. De belangrijkste conclusie is dat er zeker plaats is voor orgaansparende behandelingen, maar dat de post-behandel gevolgen en de morbiditeit moeten worden afgewogen tegen de goede kwaliteit van leven die met een totale laryngectomie bereikt kan worden.



## Summary

In the last decade the primary treatment of laryngeal and hypopharyngeal cancer was shifted towards organ preservation, i.e. preservation of the larynx. The treatment of laryngeal cancer was changed from standard radiotherapy towards hyperfractionated radiotherapy. Hypopharyngeal cancer is nowadays mostly treated with a combination of chemotherapy and radiotherapy instead of primary surgery. Therefore, the greatest shift in treatment protocols found was for hypopharyngeal cancer. The goal of this thesis was in the first place to find out whether recurrent laryngeal cancer can be treated with preservation of the larynx and the consequences of organ preservation for the function of the “new” organ. The second goal of this thesis was to find out which treatment protocols are used in the Netherlands for hypopharyngeal cancer. Also, to find the consequences of chemoradiation protocols for surgical treatment of recurrent hypopharyngeal cancer.

Chapter I is a general introduction of laryngeal and hypopharyngeal cancer. The incidences of laryngeal and hypopharyngeal cancer are mentioned. Furthermore, the biggest risk factors, being smoking and alcohol, are described. Especially, the effect of tobacco smoke on the development of laryngeal and hypopharyngeal cancer is described. Tobacco smoke contains several substances, which can cause mutations in genes. The mutations deregulate several enzyme systems and cell regulation systems, which cause degeneration of squamous cell epithelium. An overview of the other chapters of this thesis is given.

In Chapter II two partial laryngectomy techniques are described. The oncological and functional results of the endoscopic CO<sub>2</sub> laser and the frontolateral partial laryngectomy for the treatment of the recurrent glottic laryngeal cancer are described. The indications of both techniques are mentioned. Both techniques have good oncological results and less functional problems were found. With the CO<sub>2</sub> laser 44-58% of the patients are cured with preservation of the larynx; with the frontolateral partial laryngectomy 71% was cured. It is important to realize that in case of a new recurrence, a total laryngectomy can be performed without an extra risk of failure for therapy. Both partial laryngectomy techniques, CO<sub>2</sub> laser and frontolateral partial laryngectomy, are good treatment modalities for recurrent glottic laryngeal cancer. However, the indications for the different techniques are important and should be followed strictly.

In chapter III the functional and oncological results of the third partial laryngectomy technique, cricohyoidoepiglottopexy (CHEP), is described. With the CHEP 79% of the patients are cured with preservation of the larynx. In eight patients a Flexible Endoscopic Evaluation of Swallowing (FEES) was performed to objectify problems swallowing. In none of the patients aspiration was found. Before and after the operation the voice was recorded and judged. After the operation the voice is worst. However, most patients are satisfied with there voice. The CHEP appears oncologically safe and functional for the treatment of recurrent glottic laryngeal cancer in selected patients.

In chapter IV was investigated whether the quality of life is different after a partial laryngectomy versus a total laryngectomy for recurrent laryngeal carcinomas after radiotherapy. Also the voice of both groups of patients was judged. The quality of life was investigated with the EORTC Quality of Life Questionnaire (QLQ) – C30 Dutch version 3.0 and the EORTC – H & N 35 questionnaire. The only difference found was smell and taste related. The voice was judged with the Voice Handicap Index. No differences between the two groups were found. There are no big differences in quality of



life after treatment with a partial or a total laryngectomy. This is mainly caused by the unexpected good quality of life after a total laryngectomy.

In chapter V the treatment of hypopharyngeal cancer in the Netherlands is described. The treatment of hypopharyngeal cancer in the period 1985 – 1994 was investigated. The biggest group of patients was treated with radiotherapy alone or with combined radiotherapy and surgery. The overall 5-year disease-free survival after treatment with curative intention was 32%. The disease-free survival is better after combined surgery and radiotherapy.

In chapter VI, the complications after salvage surgery in patients prior treated with radiotherapy alone or chemoradiation is described. The post-operative complication rate is significantly higher (92% vs. 50%) in the chemoradiation group. The most frequent complication found was a pharygocutaneous fistula. The quality of life, after a longer post-operative period, showed a significant difference in social functioning in disadvantage of the chemoradiation group.

In the general discussion (chapter VII) the found results are discussed. The most important conclusion is that there is place for organ preservation therapy, but we must remain critical of indications and side effects of organ preservation protocols while we should realize that quality of life after total laryngectomy are not as poor as we might sometimes think.



## **Dankwoord**

Allereerst zou ik alle patiënten, die bereid zijn geweest mee te werken aan het onderzoek, willen bedanken.

**Professor Dr. L. Feenstra:**

Beste Professor, dank voor het vertrouwen en de vrijheid om dit onderzoek te mogen doen.

**Dr. J.D.F. Kerrebijn:**

Beste Jeroen, dank voor het bedenken van dit onderzoek welke geleid heeft tot het proefschrift. De begeleiding en samenwerking heb ik als uiterst plezierig ervaren. Je efficiënte ideeën bleven mij keer op keer verbazen. Onze weddenschap was achteraf de beste stimulans.

**Dr. C.A. Meeuwis:**

Beste Cees, dank voor de goede en praktische tips tijdens de besprekingen over ons onderzoek.

**Dr. M.H. Wieringa:**

Beste Marjan, dank voor de diverse SPSS sessies. Het was prettig dat er steeds op korte termijn een afspraak gemaakt kon worden. Hierdoor bleef de vaart erin.

**Dr. P.P. Knegt:**

Beste Dr. Knegt, dank voor het kritisch lezen van de discussie en de goede adviezen.

**Dr. L. Boumans en Drs. E. Eichhorn:**

Beste Leon en Edwin, dank voor de prettige en leerzame periode in het Zuiderziekenhuis. Door de diverse “vrije” vrijdagen is het afronden van het proefschrift versneld.

**Professor Dr. R.J. Baatenburg de Jong:**

Beste Professor, dank voor de mogelijkheid dat ik patiëntgegevens uit het LUMC heb mogen gebruiken voor ons onderzoek.

**Leden van de kleine commissie:**

Beste Professor Dr. P.C. Levendag en Professor Dr. H.W. Tilanus, dank voor het doorlezen van het manuscript en de goede adviezen.



## **Curriculum Vitae**

Aniel Sewnaik werd op 16 november 1972 geboren te Paramaribo, Suriname. In 1991 behaalde hij het eindexamen VWO aan het Vrije Atheneum te Paramaribo. In hetzelfde jaar begon hij aan de studie geneeskunde aan de Erasmus Universiteit Rotterdam. Na het artsexamen in 1999 heeft hij enkele maanden op de afdeling chirurgie van het Ruwaard van Puttenziekenhuis gewerkt. In oktober 1999 begon hij als agnio op de afdeling KNO/Hoofd-Hals Chirurgie in de Daniël den Hoed kliniek. Van 1 maart 2001 tot 1 maart 2006 heeft hij de opleiding tot Keel-, Neus-, Oorarts doorlopen. In 2002 werd de opleiding Master of Science in Clinical Epidemiology aan de NIHES afgerond. Op 1 maart 2006 is hij gestart met de vervolgopleiding oncologie (KNOVOO) aan het Erasmus MC



## **Illustratieverantwoording**

- Cover illustratie    File Name: tobacco\_7784 Description: Picture of a tobacco  
Plant. Source: Wilbur F. Gordy, *A history of the United States for Schools*  
(New York: Charles Scribner's Sons)  
Copyright: 2003, Florida Center for Instructional Technology
- Fig 1, page 26      File Name: tumour stages in larynx by Charles Stephan  
(*Guideline for selection of patients and choice of the right procedure*)

