

# Sideways Displacement and Curved Path of Recti Eye Muscles

Huibert J. Simonsz, DM; Friedrich Harting, DM; Bob J. de Waal; Ben W. J. M. Verbeeten, MD

• We investigated the sideways displacement of recti muscles with the eye in various gaze-positions by making computed tomographic (CT) scans in a plane perpendicular to the muscle cone, posterior to the globe. We found no consistent sideways displacement of the horizontal recti in the up or down gaze or the vertical recti in the left or right gaze. We found a substantial displacement, however, of the contracting and relaxing muscles. Consequently, we made CT scans in a horizontal plane through medial and lateral recti and found that, with the eye in primary position, the recti muscles follow a curved path. The curvature of the path increased following muscle relaxation and decreased following muscle contraction.

(*Arch Ophthalmol* 1985;103:124-128)

Working with the computer model of eye movements of Robinson,<sup>1</sup> we were confronted with uncertainty regarding the quantity of sideslip of eye muscles over the globe. Sideslip is the sideways displacement of muscle and tendon over the globe of, for instance, a lateral rectus muscle in upward gaze or a superior rectus muscle in lateral gaze. A large quantity of sideslip must be inferred, if the eye muscles take the shortest geometric path, under all circumstances. As a consequence, the horizontal eye muscles would act as elevators in upward gaze and as depressors in downward gaze (Fig 1). This is called the bridle-effect.<sup>2,3</sup>

In Duane's syndrome, co-contraction of the horizontal eye muscles sometimes results in elevation or depression of the eye. Under these conditions, the existence of the bridle-effect is incontrovertible. Abnormal eye movements resulting from such muscle sideslip can be treated by suturing the muscle to the sclera at

the equator.<sup>4</sup> Little is known about the occurrence of sideslip in the normal human eye. Robinson's<sup>1</sup> computer model employs an approximation algorithm for muscle sideslip that constructs the muscle path under the following constraints. It is assumed that the muscle follows a straight path from origin to point of tangency, which is a point on the locus of tangents from the origin to the globe. This locus is a circle on the globe. A second assumption is that the path of the muscle from point of tangency to insertion is circular. A third determinant is the angle of departure of the muscle from the insertion. If the sideslip were unrestrained, the muscle would take the shortest path from the locus of tangents to insertion.

In Robinson's model,<sup>1</sup> the resulting angle at the insertion is reduced by multiplying it with the cosine of the angle of eye movement out of the muscle plane. This third determinant restricts sideslip progressively, as the eye moves away from the primary position. It is an elegant approximation, considering the scarcity of empirical data. The computer model was recently extended and improved.<sup>5</sup>

Miller (Joel M. Miller, PhD, written communication, 1983) suggested that computed tomographic (CT) scans could clarify the issue of sideslip to some extent. We have, therefore, made CT scans perpendicular to the muscle cone posterior to the globe, with the eye in primary and 30° secondary positions. In this plane, we found no consistent sideways displacement of either the horizontal recti in the up or down gaze or the vertical recti in the left or right gaze. By sideways displacement, we mean horizontal recti moving up or down and vertical recti moving left or right. Surprisingly, we found a substantial displacement (inward and outward) of the contracting and relaxing muscles. Thus, we also made CT scans in a horizontal plane through medial and lateral recti with the eye in various gaze positions. Our results indicate that the muscles do not follow a straight course from origin to point of tangency, but are curved outward. The curvature straightens on contraction

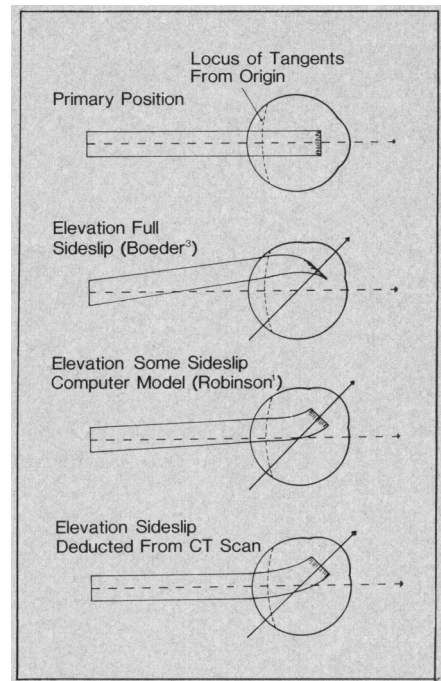


Fig 1.—Drawing to visualize the difference between muscle sideslip over globe and sideways displacement at level of the posterior pole. Redrawn from original made by J.M. Miller. In Robinson's computer model, sideslip was constrained by angle tendon made at insertion. A straight course was assumed from origin to point of tangency. Our results indicate that muscle does not displace at level of posterior pole. CT indicates computed tomographic.

of the muscle and intensifies on relaxation.

## SUBJECTS AND METHODS

Six volunteers were examined. Informed consent was obtained from all subjects. In the coronal series, the subject was lying prone with the neck hyperextended and the chin and forehead resting in a support. A Philips Tomoscan 310 CT scanner was used (voxel:  $\frac{1}{2} \times \frac{1}{2} \times 1\frac{1}{2}$  mm). To obtain a section almost perpendicular to the muscle cone, the subject turned the head 10 to 15° about a vertical axis and the CT scanner was tilted about a frontal axis until the angle between the perpendicular of the scanning plane and the line intersecting meatus acusticus externus and lateral canthus was 15°.

A device with four fixation targets was constructed from four 30° plastic triangles, glued together in a star fashion. The central axis of the fixation device was aligned

Accepted for publication June 18, 1984.

From the Departments of Ophthalmology (Drs Simonsz and Harting) and Computer Tomography (Dr Verbeeten), Academical Medical Centre, and the Netherlands Ophthalmic Research Institute (Dr de Waal), Amsterdam.

Reprint requests to Department of Ophthalmology, Academisch Ziekenhuis der Vrije Universiteit, De Boelelaan 1117, 1007 MB Amsterdam, Holland (Dr Simonsz).

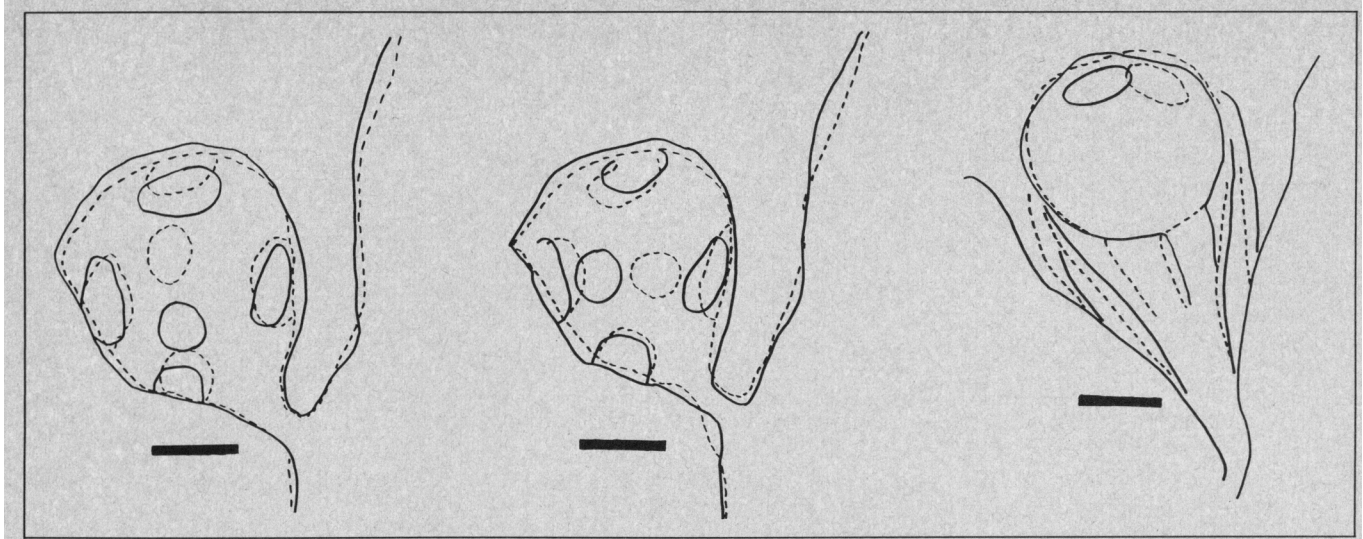


Fig 2.—Hand-drawn copies of superimposed computed tomographic scans, made in opposite gaze positions. Left, Scans perpendicular to muscle cone, up gaze (continuous line), and down gaze (dashed line). Center, Scans perpendicular to muscle cone, lateral gaze (continuous line), and medial gaze (dashed line). Right, Horizontal scans, lateral gaze (continuous line), and medial gaze (dashed line) (subject 1, right eye).

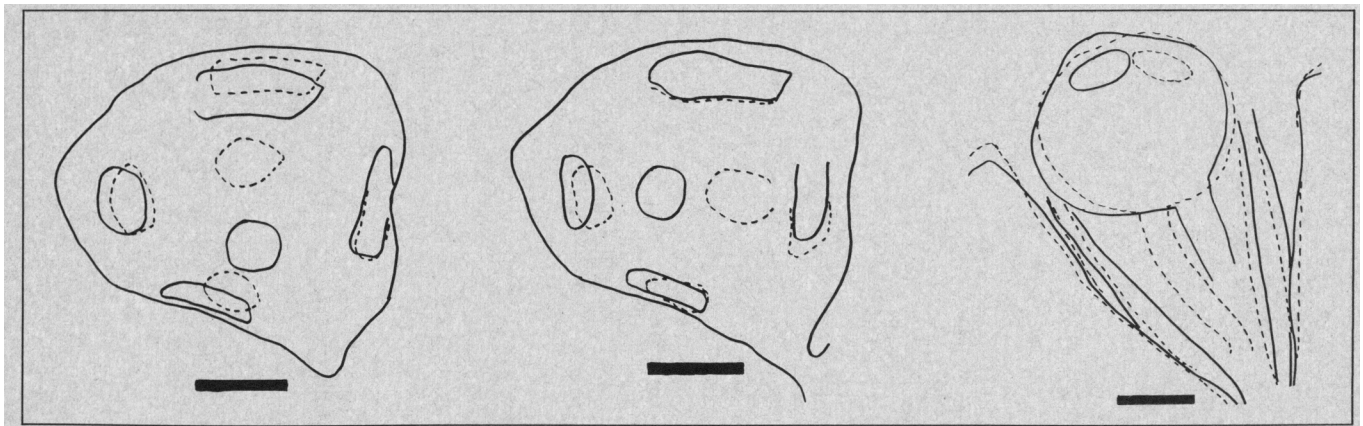


Fig 3.—Hand-drawn copies of superimposed computed tomographic scans, made in opposite gaze positions. Left, Scans perpendicular to muscle cone, up gaze (continuous line) and down gaze (dashed line). Center, Scans perpendicular to muscle cone, lateral gaze (continuous line), and medial gaze (dashed line) (subject 2, right eye).

with the visual axis of the eye of the subject in primary position. To obtain secondary eye positions, the subject was asked to look along a hypotenuse at the tip of a triangle. In the horizontal series, the subject was lying supine with the head in a support. Dots on the inner side of the CT-scanner ring served as fixation targets for 30° left and right gaze. The CT scanner was tilted about a frontal axis of the patient to obtain a plane through medial and lateral recti.

The right eye was examined in subjects 1, 2, 4, and 5. In subjects 3 and 6, the left eye was examined and no horizontal sections were made. Orienting CT scans were made until the posterior pole of the eye was reached. Then six CT scans were made directly behind the globe in rapid succession, with full resolution power, with the eye in primary eye position, four 30° secondary eye positions and repeated in primary eye position. Each scan took about 15 s. Overload of the X-ray tubes made 20 to 30 s-intervals between the last scans mandatory, however.

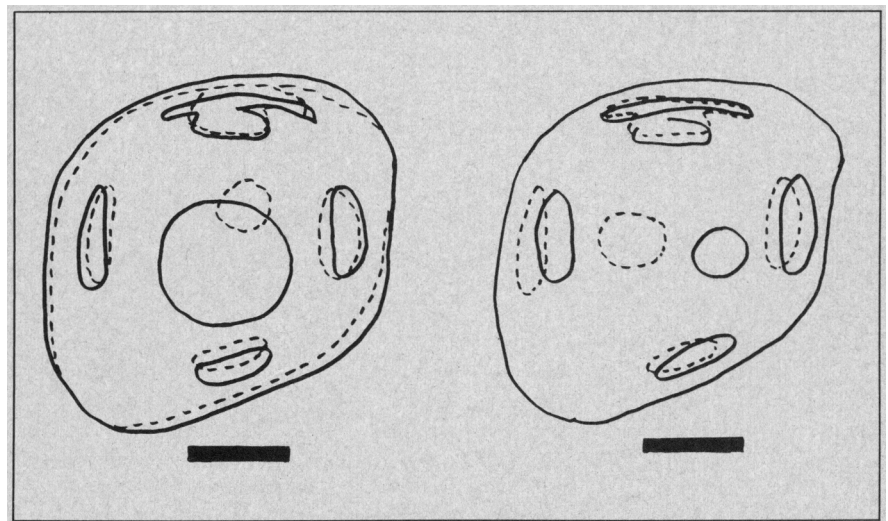


Fig 4.—Hand-drawn copies of superimposed computed tomographic scans, made in opposite gaze positions. Left, Scans perpendicular to muscle cone, up gaze (continuous line), and down gaze (dashed line). Right, Scans perpendicular to muscle cone, lateral gaze (continuous line), and medial gaze (dashed line) (subject 3, left eye).

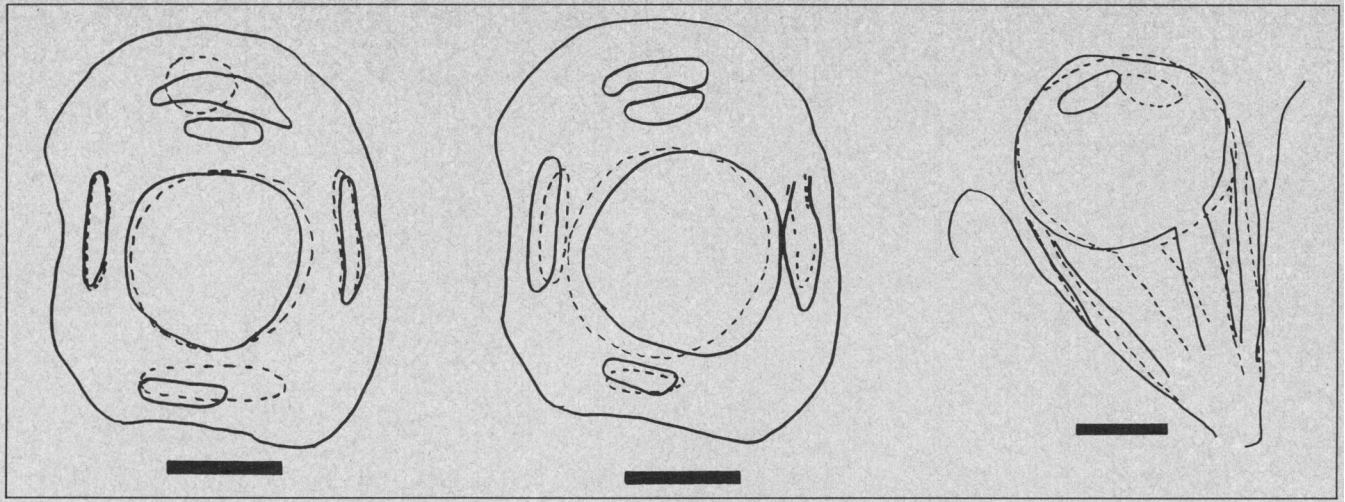


Fig 5.—Hand-drawn copies of superimposed computed tomographic scans, made in opposite gaze positions. Left, Scans perpendicular to muscle cone, up gaze (continuous line) and down gaze (dashed line). Center, Scans perpendicular to muscle cone, lateral gaze (continuous line), and medial gaze (dashed line). Right, Horizontal scans, lateral gaze (continuous line), and medial gaze (dashed line) (subject 4, right eye).

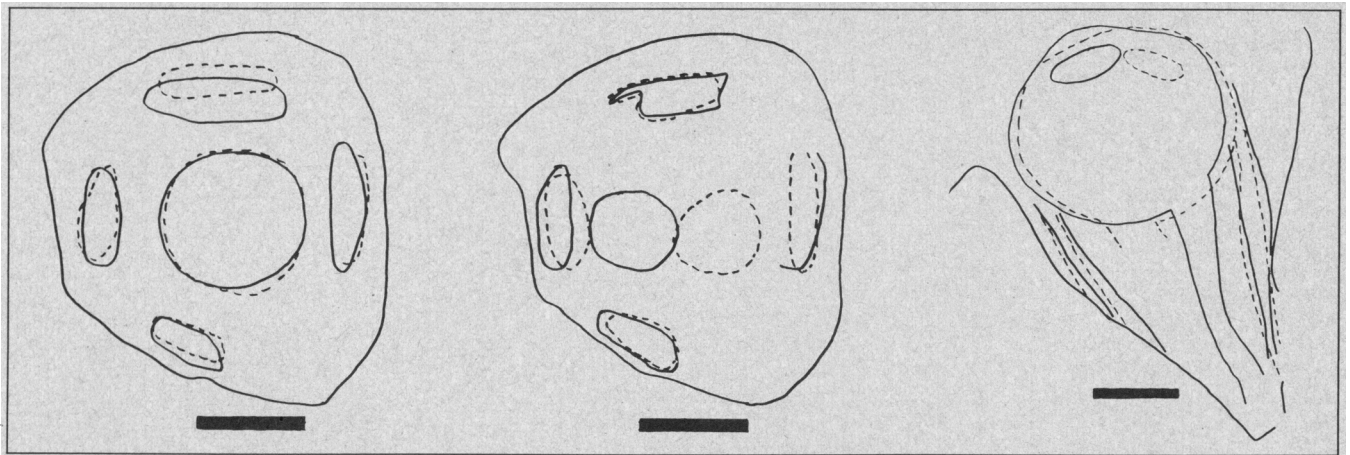


Fig 6.—Hand-drawn copies of superimposed computed tomographic scans, made in opposite gaze positions. Left, Scans perpendicular to muscle cone, up gaze (continuous line), and down gaze (dashed line). Center, Scans perpendicular to muscle cone, lateral gaze (continuous line), and medial gaze (dashed line). Right, Horizontal scans, lateral gaze (continuous line), and medial gaze (dashed line) (subject 5, right eye).

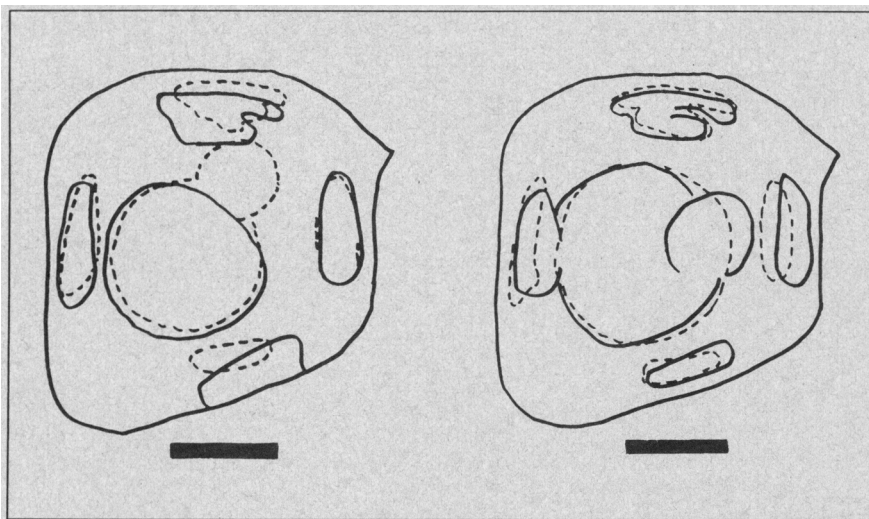


Fig 7.—Hand-drawn copies of superimposed computed tomographic scans, made in opposite gaze positions. Left, Scans perpendicular to muscle cone, up gaze (continuous line), and down gaze (dashed line). Right, Scans perpendicular to muscle cone, lateral gaze (continuous line), and medial gaze (dashed line) (subject 6, left eye).

The data were processed and films were made at three times magnification compared with actual size. Horizontal scans were made in a similar fashion; under these conditions, vertical secondary gaze positions were omitted.

#### RESULTS

To visualize the displacement of the muscles, drawings were made of superimposed scans of opposite gaze positions. The drawings are shown in Figs 2 to 7, corresponding to subjects 1 to 6, respectively. In scans perpendicular to the muscle cone, 30° up gaze was superimposed on 30° down gaze (Figs 2 to 7, left) and 30° lateral gaze was superimposed on 30° medial gaze (Figs 2, left, to 7, left). In horizontal scans, 30° lateral gaze was superimposed on 30° medial gaze (Figs 2, center, to 7, center).

For subject 1, in comparing up-gaze and down-gaze scans (Fig 2, left), no



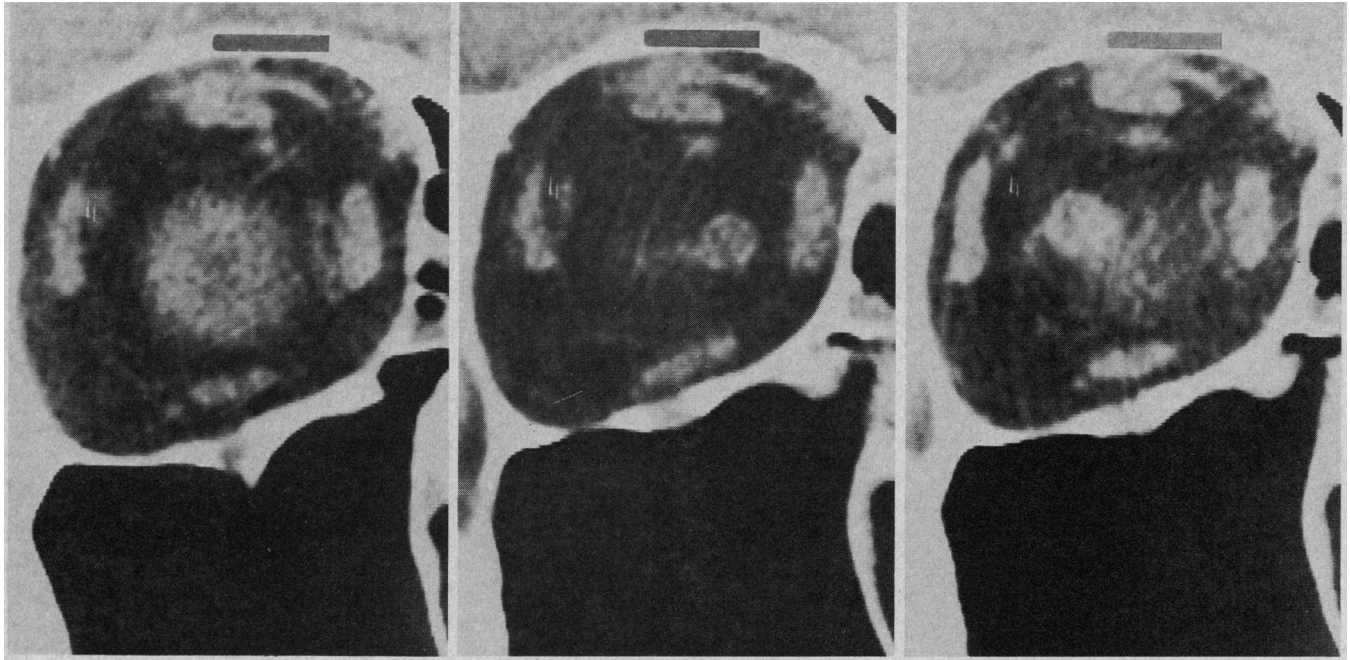


Fig 8.—Selection of scans. Scans perpendicular to muscle cone, left eye. Primary position, lateral gaze, and medial gaze (subject 3).

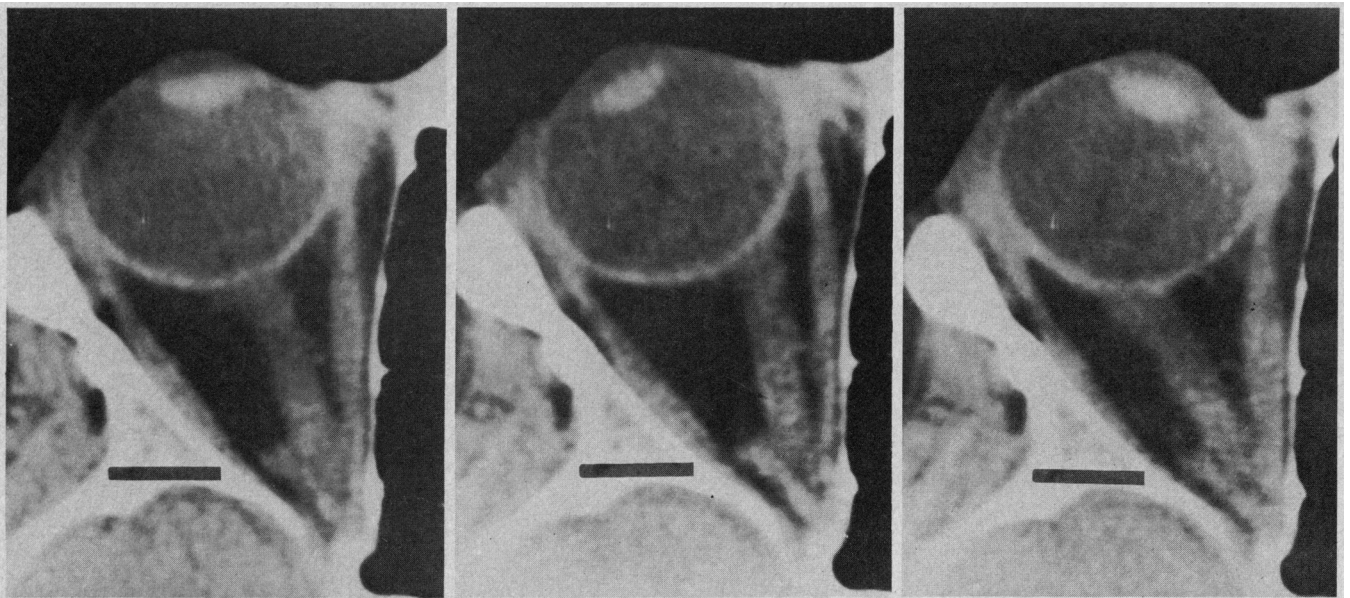


Fig 9.—Horizontal scans, right eye. Primary position, lateral gaze and medial gaze. In all scans, bar equals 1 cm. See results section for further explanation (subject 4).

sideways displacement of the horizontal recti is seen. The contracting muscles, superior rectus in up gaze and inferior rectus in down gaze, come off the orbital wall. For lateral and medial gaze positions (Fig 2, center), no sideways displacement of inferior rectus is seen. The superior rectus, however, does displace about 1 mm, in the direction predicted from the concept of muscle sideslip. The contracting muscles come off the orbital wall, as in Fig 2, left. The plane of the section is further toward the apex of the

orbit, however. In the drawing of the horizontal scans, the curved course of the horizontal eye muscles is conspicuous, with straightening of the course on contraction (Fig 2, center). In subject 2 (Fig 3, left and right), no sideways displacement of any of the recti muscles occurs, except in the case of the inferior rectus on lateral gaze. Note that this sideways displacement is opposite to that which would be expected. Three of the four contracting muscles in the four gaze positions displace inward. The lateral

rectus, however, does not seem to move inward on contraction, but downward. In the horizontal sections (Fig 3, right), the curved path is not as conspicuous as in subject 1. In subject 3 (Fig 4, left), the up-gaze section was through the posterior pole. The scan made in down gaze is slightly more posterior. No sideways displacement of the horizontal recti is seen, nor of the vertical recti in Fig 4, right. The inferior rectus has displaced slightly medially on lateral gaze, contrary to that which would be expected. There



is inward displacement of the contracting muscles, except of the superior rectus.

In subject 4 (Fig 5, left and center), all sections are through the posterior pole. No sideways displacement occurs. Inward displacement of contracting muscles is evident, except for the lateral rectus. In Fig 5, left, the section through the superior rectus and levator differ greatly, because one section is through those parts of the muscles that are tightly connected, while the other is through the parts which are separated. In the horizontal scans (Fig 5, center), the curved course of the horizontal muscles is seen. The medial rectus in particular straightens its course on contraction. In subject 5 (Fig 6, left and center), no sideways displacement of any of the recti muscles occurs. Inward displacement of contracting muscles is only evident in superior rectus and medial rectus.

The sections of up and down gaze are through the posterior pole. In the horizontal scans (Fig 6, right) the curved course of the horizontal recti is not as evident as in other subjects. In subject 6 (Fig 7), no sideways displacement occurs of any of the four recti muscles. All four contracting muscles show a considerable inward displacement. All sections are through the posterior pole. A sampling of the original CT scans is given in Figs 8 and 9.

Note from the drawings that it was not always possible to maintain exactly the same 1½-mm section plane throughout the series. Subjects had a tendency to press the head further into the support. This was especially the case for subject 1.

#### COMMENT

We found no consistent sideways displacement of the horizontal recti in vertical eye movements or vertical recti in horizontal eye movements, in the plane perpendicular to the muscle cone, posterior to the globe. It is important to realize that sideways displacement is not the same as sideslip over the globe. One is relative to the bony orbit, the other is relative to the globe. Even when the muscle does

not displace at the level of the posterior pole, a small amount of sideslip will probably occur. We selected the area of the posterior pole for our studies to standardize the procedure and to obtain the best contours. It is possible that sideways displacement of these muscles was not observed because of the configuration of the connective tissue septa in the orbit.

Koornneef<sup>6</sup> has shown that the connective tissue septa peripheral to the orbit run parallel to the orbital wall with connections to muscles and periorbit. They probably thereby constrain sideways displacement, though they permit lengthening and shortening of the muscle. Recent experiments by Miller et al,<sup>7</sup> in which radiopaque markers were implanted along the upper and lower margins of a lateral rectus muscle in monkeys, showed 2-mm displacement of the muscle at the level of the point of tangency, if the eye moved from primary position to 25° up gaze or 25° down gaze. It should be noted that this point of tangency is slightly more anterior than the plane we used for CT scanning.

The second part of our findings is more difficult to interpret. Why should recti muscles bulge outward? We think this may be caused by a build-up of pressure behind the globe, to some extent contained within the muscle cone. If we extrapolate the basal tension of a lateral rectus muscle, about 8 g (Alan B. Scott, PhD, oral communication, Oct 12, 1983), to the other recti muscles, a total inward pull of about 30 g is found. This is a considerable force and it must give rise to a build-up of pressure behind the globe. What connective tissue contains this pressure? Where does this pressure taper off?

We suggest that the pressure is, to some extent, contained within the muscle cone and thereby causes a slight bulging outward of the recti muscles. We found no alternative explanation for the curved course of the muscles, with the eye in primary position. The optic nerve, possibly pulling the contracting or pushing the relaxing muscle, may help to explain the phenomena of decrease in curva-

ture on contraction and increase in curvature on relaxation. The fact, however, that the space around the optic nerve is almost void of connective-tissue septa<sup>6</sup> does not support this assumption.

Another possibility is that the course of the muscle changes because of lack of space. As the muscle thickens, it might push itself away from the bony orbit. This could be the case for the medial rectus in particular. Apart from considering these two alternative explanations for change in shape on contracting and relaxation, it should be noted that in comparing two scans, two different sections of the muscle are seen, because the muscle has lengthened or shortened. The pressure behind the globe should amount to about 3 mm Hg, assuming a pull of 30 g for the recti muscles together and an effective cross-sectional area of the globe and adnexa of 7 sq cm. The latter figure was deducted from retrobulbar-pressure measurements on corpses by the authors (unpublished data, February 1984). In these experiments, a standardized weight was applied to the globe while recording retrobulbar pressure. It seems reasonable to assume that the retrobulbar pressure rises considerably in extreme gaze positions and during saccades.

The course of the connective tissue septa in some of the anatomic sections of Koornneef<sup>6</sup> lend support to the idea of containment of pressure within the muscle cone. Bulging outward of connective tissue, septa between adjacent recti can be seen (Koornneef<sup>6</sup> chapter 4, Figs 8 through 10). This can be interpreted as containment of pressure within these septa. We think the suspension of the eye is aided by the recti muscles, pulling the eye against the fat-tissue compartments behind the eye.

This study was supported in part by grant J3-Ha-1311(1-1) of the Deutsche Forschungsgemeinschaft (Dr Härting).

Professor D.A. Robinson, Professor G. Kommerell, and J.M. Miller, PhD, provided encouragement and made comments. J.M. Miller suggested the investigational possibility to us and gave us the use of Fig 1. Milan van Tuin, Albert Bouman, Peter Staaks, Ageeth van Aarst, and Eddy Oldenburg assisted in making the scans.

#### References

1. Robinson DA: A quantitative analysis of extraocular muscle cooperation and squint. *Invest Ophthalmol* 1975;14:801-825.
2. Krewson WE: The action of the extraocular muscles: A method of vector analysis with computations. *Trans Am Ophthalmol Soc* 1950;48:443-486.
3. Boeder P: The co-operation of extraocular

muscles. *Am J Ophthalmol* 1961;51:469-481.

4. Scott AB: Strabismus-muscle forces and innervations, in Lennerstrand G, Bach-y-Rita (eds): *Basic Mechanisms of Ocular Motility and Their Clinical Implications*. New York, Pergamon Press, pp 181-191.

5. Miller JM, Robinson DA: A binocular strabismus model: Simulations and tests. *Invest Oph-*

*thalmol* 1982;22(suppl):161.

6. Koornneef L: *Spatial Aspects of Orbital Musculo-fibrous Tissue in Man*. Amsterdam, Swets and Zeitlinger, 1977.

7. Miller JM, Robinson DA, Scott AB, et al: Side-slip and the action of the extraocular muscles. *Invest Ophthalmol* 1984;25(suppl):182.