

# Length-Tension Curves of Human Eye Muscles During Succinylcholine-Induced Contraction

H. J. Simonsz,† G. H. Kolling,\* B. van Dijk,† and H. Kaufmann\*

**We have made intraoperative, continuous-registration, length-tension diagrams of detached eye muscles in 80 strabismus patients under general anaesthesia. In 47 of these we repeated the measurements after contraction evoked by succinylcholine chloride. In contracting horizontal and vertical rectus muscles, we found a linear relation between length and tension. In contracting oblique muscles, however, the relation between length and tension was frequently nonlinear. In superior oblique palsies, the superior oblique was found to be stiff after elongation and before injection of succinylcholine, and it did not contract after injection of succinylcholine. The ipsilateral inferior oblique did contract after injection of succinylcholine, but with a higher spring constant than usual (ie, contracture of the ipsilateral antagonist). In three cases the superior oblique contracted vividly after administration of succinylcholine despite the presence of excyclotropia, stereopsis, torticollis (two cases) and a hyper-tropia that increased in adduction, in down-gaze, in adduction and down-gaze and on ipsilateral head-tilt. In a case of general fibrosis syndrom we found almost normally contracting vertical recti, which is compatible only with a supranuclear or misdirectional cause. These cases demonstrate the usefulness of the assessment of the length-tension diagram of an eye muscle during surgery, before and during contraction evoked by succinylcholine chloride. Invest Ophthalmol Vis Sci 29:1320-1330, 1988**

We have made intraoperative, continuous-registration, length-tension diagrams of detached eye muscles in 80 strabismus patients under general anaesthesia. In 47 of these we repeated the measurements during contraction evoked by succinylcholine chloride. In this article, we will first discuss the properties of length-tension diagrams of eye muscles in general, then present data on the group of 47 patients, and finally we will discuss a selection of cases more extensively.

The tension in a contracting muscle is caused by: (1) the tension generated actively by the sarcomeres; and (2) the tension resulting from passive stretch of the connective tissue of the muscle. The relation between the latter and muscle length is exponential (Fig. 1).<sup>1</sup> In other words, the tension is zero at lengths shorter than a certain length (in rabbits, this length is approximately equal to the primary position length<sup>2</sup>),

increases slowly when the muscle is stretched from primary position length onwards, to increase ever more rapidly thereafter, until the muscle tears.

The tension generated actively by the sarcomeres, at a given level of innervational stimulation, is low when the muscle is short, is at its highest, approximately at average in situ length (or slightly more than that), and declines again when the muscle is stretched further. The reason for the maximum tension development occurring at this particular length is that approximately at this particular length the intertwining actine and myosine molecules are engaged over a distance that permits the largest possible number of actine-myosine cross-bridges to contract unencumbered (Fig. 2).<sup>3</sup>

It has been found previously that the relation between length and tension of a contracting eye muscle is linear at higher levels of stimulation.<sup>1,4,5</sup> In other words, a contracting eye muscle behaves like an ordinary coil spring, in that the tension rises proportionately to the length. What mechanism is responsible for this linear relation between length and tension? How can the relation between length and tension of a contracting eye muscle be linear when both of its components, ie, tension generated by the sarcomeres (active component) and tension resulting from stretch of the connective tissue (passive component) are nonlinear? When a contracting, short muscle is stretched, at first the tension generated by the sarcomeres rises proportionately to the length. As the

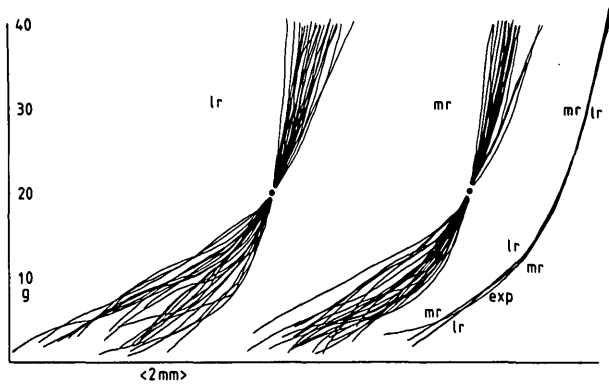
---

From the \*Augenlinik für Schielbehandlung und Neuroophthalmologie, Klinikum der Justus-Liebig-Universität, Giessen, West Germany, and the †Netherlands Ophthalmic Research Institute, Amsterdam, The Netherlands.

Supported by fellowships of the Alexander von Humboldt Foundation, Bonn, West Germany and of the Royal Dutch Academy of Arts and Sciences (HJS).

Submitted for publication: October 6, 1987; accepted March 16, 1988.

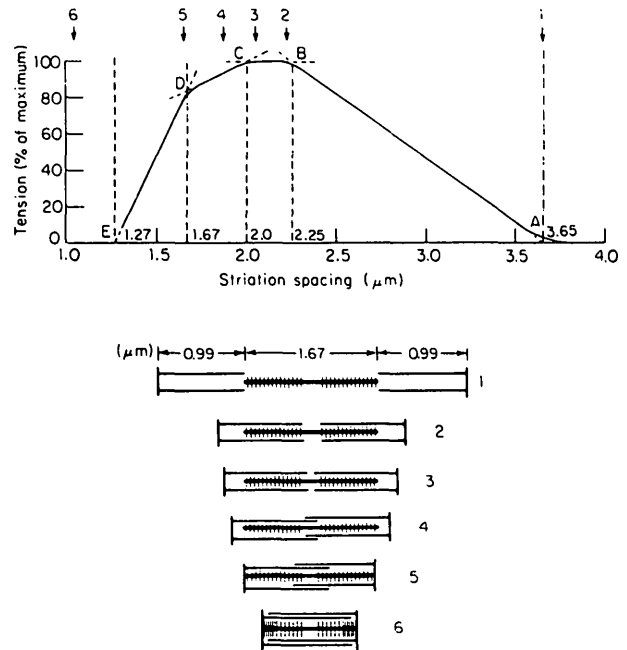
Reprint requests: Dr. H. J. Simonsz, oogarts, Netherlands Ophthalmic Research Institute, P.O. Box 12141, NL 1100 AC Amsterdam, The Netherlands.



**Fig. 1.** All length-tension diagrams were composed of a left limb (registration during tension increase) and a right limb (registration during tension decrease). For an example of a complete length-tension diagram, see Figure 4. All left limbs of curves of detached lateral rectus (left) and medial rectus (middle) muscles of all patients that had first surgery for uncomplicated horizontal squint (Group A), were superimposed through an arbitrarily chosen common point (solid circles) at which the tension was 20 g. Estimated averages for all lateral (L) and medial (M) rectus muscles are very similar (right). "EXP" refers to the exponential approximation (made after subtraction of the hysteresis, 3.25 g on average), used in our modified Robinson computer model of eye movements.<sup>20</sup>

muscle is stretched further and the tension generated by the sarcomeres decreases, the tension resulting from stretch of the connective tissue increases so much more, however, that the overall tension is still increasing proportionately to the length. Clearly, whether or not the relation will be linear depends upon the amount of connective tissue in the muscle and the structure of the muscle. Some skeletal muscles, like the sartorius muscle, have little connective tissue and the active component predominates in the length-tension curve. Hence, its relation between length and tension is nonlinear (Fig. 3). A gastrocnemius muscle, on the other hand, has much connective tissue and its relation between length and tension is almost linear.<sup>6</sup> Eye muscles also have very much connective tissue,<sup>2</sup> and hence the length-tension relation of a contracting eye muscle is almost linear. Only at low levels of innervation or stimulation does the length-tension curve become nonlinear, as the exponential length-tension relation of the connective tissue of the muscle predominates. It has also been found that the spring constant (= stiffness) of a contracting eye muscle remains approximately the same whether it contracts moderately or strongly.<sup>1,4,5</sup>

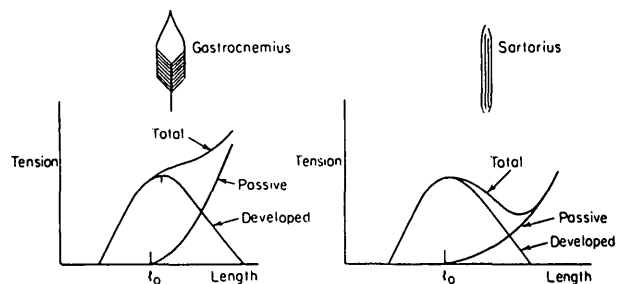
In the experiments that are the subject of this study, we let the eye muscles contract by intravenous administration of succinylcholine chloride while registering length and tension. Acetylcholine and succinylcholine chloride cause contraction of extraocular eye muscles<sup>2,7-9</sup> by preferentially stimulating multiply innervated muscle fibers. These fibers have acetyl-



**Fig. 2.** Tension developed by the actine-myosine crossbridges of a muscle at varying length. Maximum tension is developed at (or at slightly more than) average in situ length. Below the molecular basis for the curve is depicted; as the actine and myosine slide in each other, the number of crossbridges increases; unlimited shortening is not possible, however, as space is limited.

choline receptors not only in the neuromuscular junction, but on their entire cell membrane.<sup>2</sup>

Several authors have tried to relate the length-tension properties of eye muscles, assessed during surgery, to surgical outcome.<sup>10-18</sup> The results have generally not met expectations, however. In most cases only the passive component was measured. It has also at times been difficult to estimate the primary position length after the muscle had been detached from



**Fig. 3.** Length-tension curves of contracting skeletal muscles differ because their structure and amount of connective tissue (causing the passive component) differ. Like the gastrocnemius muscle, eye muscles also have much connective tissue and hence the length-tension curve of a contracting eye muscle is approximately linear. (This and the previous figure were taken, with permission, from ref. 6. Professor McMahon wishes to emphasize that he made these drawings to clarify the length-tension diagram; they do not represent experimental results.)

the globe. When the primary position length is not known exactly, the data can be difficult to interpret. As a case in point, we have found that both a fibrotic and a paretic muscle are stiff—at completely different rates of elongation, however.

### Materials and Methods

The measurement procedure has been described elsewhere.<sup>1</sup> In short, a length and tension measuring device<sup>19</sup> was fixed during surgery rigidly above the head of the patient. It consisted of a 2 mm hardened steel shaft, suspended by precision microball bearings and equipped with a shaft position encoder and an eddy current motor. The torque generated by the eddy current motor in the shaft and the position of the shaft were assessed electronically. The frame on which it was mounted consisted of 30 mm steel posts fixed to the railing of the operating table, a 20 mm steel traverse bar above the chest of the patient and a 20 mm steel bar that could be clamped tight in any position rectangular to the traverse bar. The head of the patient was fixed rigidly on the circular cushion of the steel head-support of the operating table by a wide silk plaster around the forehead of the patient and the head support. A 4.0 silk suture was passed through the muscle to be measured and wrapped around the shaft with a tight knot. The position of that part of the shaft and the suture were kept in line with the muscle to be measured. When measuring oblique muscles, the head of the patient was rotated contralaterally and the measuring device was positioned such that the muscle was pulled upon in a frontal plane. The torque generated in the shaft was slowly (taking more than 45 seconds either way) increased and decreased, exerting a pull that varied between 0 and 40 g.

In 47 patients, we repeated the measurements after intravenous injection of succinylcholine chloride, 1 mg/kg body weight, starting the first registration 1 min after the injection. The dose of 1 mg/kg was chosen somewhat arbitrarily. Asmussen<sup>2</sup> found maximal contraction of the inferior oblique muscle of the rabbit to occur at about 0.05 mM/l (bathing solution), equal to about 15 mg/l, and he found no contraction below 0.005 mM/l. The amount of succinylcholine chloride that could be administered during one operation was limited, however, and succinylcholine chloride was given not only twice for the measurements but also at intubation. Although the maximum tension developed may have been influenced by the dose, the spring constant during the succinylcholine-induced contraction, in all likelihood, was not due to the fact that the spring constant of a contracting eye muscle remains approximately the same at different levels of stimulation.<sup>1,4,5</sup> The

interval between any two injections of succinylcholine chloride was at least 15 min, hence residual drug effects during the second measurement were avoided. Calibration of the length-tension measuring device was as described previously.<sup>1</sup> The starting friction of the shaft, caused by the precision micro ballbearings was less than 1 gram × millimeter.

All patients gave written informed consent.

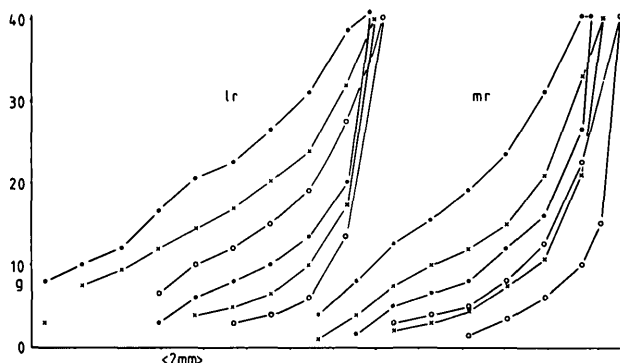
### Results

Patient data and the spring constants of the contracting eye muscles, equal to the slope of the length-tension curve, are listed in the Table that comprises Appendix 1. The spring constants are, for convenience, expressed in unit gram per degree of eye rotation, assuming a radius of the globe of 11.7 mm, conforming to 24.6 mm axial length. Then 1° on the surface of the globe equals 0.2042 mm. Cases 1, 2 and 3 have been described previously<sup>1</sup> (case numbers 9, 5 and 11 in that article).

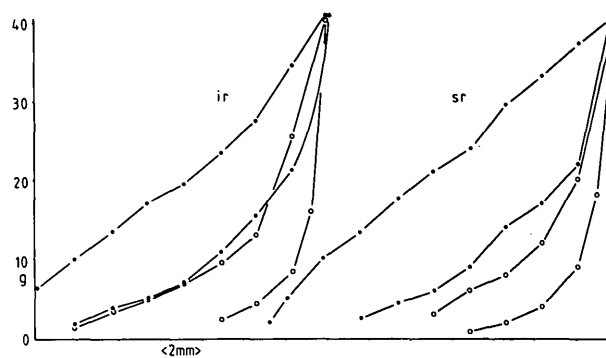
In a series of patients that underwent first surgery for uncomplicated horizontal squint (group A), the estimated average of all length-tension curves of non-contracting medial and lateral rectus muscles of all patients with uncomplicated convergent and divergent squint (Fig. 1) could be approached, after subtraction of the hysteresis (3.25 g on average in the detached muscles) with an exponential equation, which would read:

$$\text{Tension (g)} = 1.0104 \times (e^{0.34024 \times \text{mm length change}} - 1) \quad (1)$$

In these patients we found spring constants of 0.35 to 0.55 g per degree of eye rotation (g/deg) for the linear length-tension curves of contracting medial and lateral rectus muscles (Fig. 4). Only one contracting lateral rectus muscle (case 15) had a higher spring constant, 0.73 g/deg. In some cases we repeated the measurement 4 and 6 min after the injection of succinylcholine chloride, ie, at diminishing levels of stimulation. In these cases we found similar spring constants at different levels of contraction. We also found similar spring constants for agonist and ipsilateral antagonist in most cases. When the spring constant of one muscle of a pair of antagonists had gone up, the ipsilateral antagonist was also stiffer, with an occasional exception (case 27). All length-tension relations of contracting eye muscles in group A were linear, except for a medial rectus muscle in case 4 (Fig. 5). In contracting vertical rectus muscles (group B), we also found a linear relation between length and tension, with spring constants that were approximately similar to those of horizontal recti (Fig. 6). In one patient (case 13) who had a congeni-



**Fig. 4.** Length-tension diagrams of lateral and medial rectus muscles of case 5. In Figures 4-12, the traces of two or three muscles are set side by side for comparison. All length-tension diagrams were composed of a left limb (registration during tension increase) and a right limb (registration during tension decrease). The difference between the two limbs was caused by hysteresis, mainly friction of the muscle in its sheaths. Open circles: before injection of succinylcholine chloride, 1 mg/kg of body weight; solid circles: registration starting 1 min after injection; crosses: registration starting approximately 4 min after injection. In the first measurement after injection of succinylcholine chloride, seemingly larger hysteresis is caused by diminishing action of succinylcholine chloride.



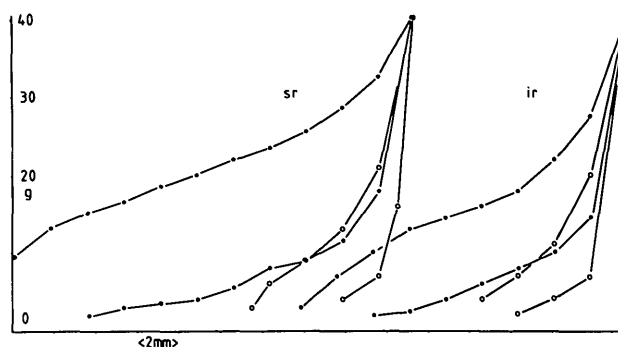
**Fig. 6.** Inferior and superior rectus muscles of case 7.

oblique muscles contracted little after injection of succinylcholine chloride. The stiffness of oblique muscles (often rough estimates as the curves were frequently nonlinear) were comparable to those of recti muscles. Vividly and equally contracting oblique muscles were found mainly in young patients, the oldest patients being 10 and 19 years old.

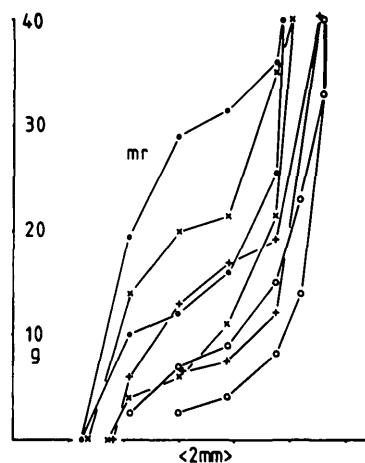
In other cases the superior oblique muscle was found to be stiff (after elongation), and it did not

tal, vertical nystagmus, the spring constants were exceptionally low (Fig. 7).

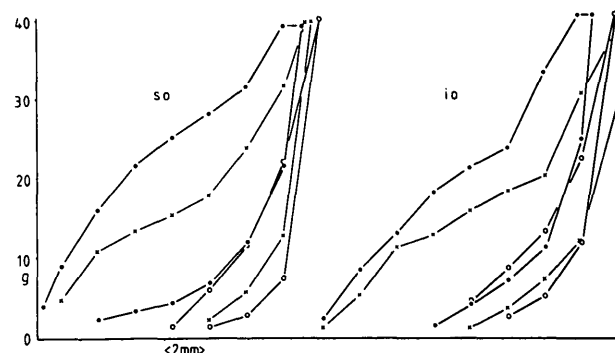
All cases in whom oblique muscles were measured (group C) were diagnosed as either strabismus sursoadductorius (upshoot in adduction) or as trochlear palsy. In those cases where both oblique muscles contracted vividly (ie, similar length-tension curves for inferior and superior obliques) and equally (not compatible with a superior oblique palsy), the relation between length and tension was frequently nonlinear (Figs. 8, 9). In some cases (35, 42 and 43), both



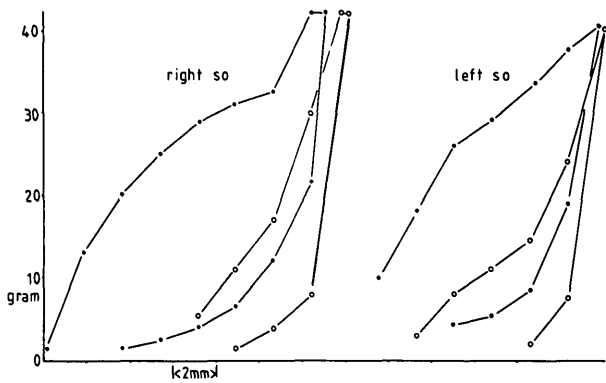
**Fig. 7.** Superior and inferior rectus muscles of case 13. The spring constants of these muscles after contraction evoked by succinylcholine chloride, equal to the slope of the curves, were conspicuously low. The patient had a congenital, vertical nystagmus.



**Fig. 5.** Medial rectus muscle of case 4. This was the only nonlinear length-tension diagram in all cases of first surgery for uncomplicated horizontal squint. The patient had convergence excess.



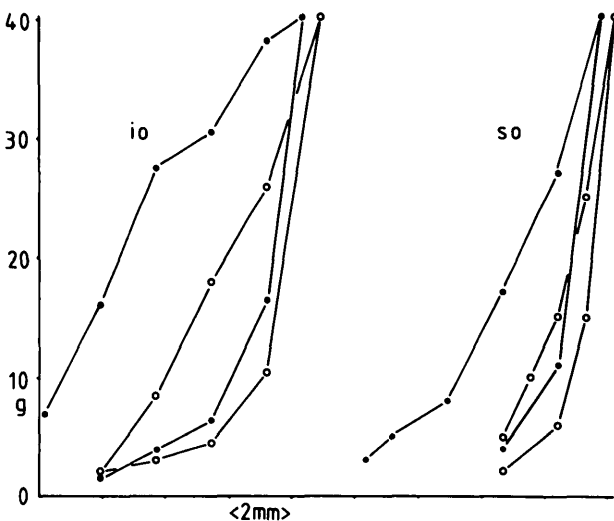
**Fig. 8.** Superior and inferior oblique of case 9. Note nonlinearity.



**Fig. 9.** Right and left superior oblique muscles of case 44. Note non-linearity. Cases 9 (Fig. 8), 24 and 44 had a hypertropia increasing in adduction, in down-gaze, in adduction-and-down-gaze and on ipsilateral head-tilt. They had excyclotropia, stereopsis and torticollis (2 cases). The superior oblique muscles contracted vividly, however, after injection of succinylcholine chloride. In all likelihood these patients had not a superior oblique palsy but monolateral strabismus sursoadductorius (upshoot in adduction).

contract after injection of succinylcholine chloride, compatible with a diagnosis of a trochlear palsy (Fig. 10). In these cases, the ipsilateral inferior oblique muscle did contract after injection of succinylcholine chloride, but with a higher spring constant than usual, compatible with a contracture of the ipsilateral antagonist. The latter picture was seen more frequently in older patients.

In three cases the superior oblique contracted vividly after administration of succinylcholine despite the presence of excyclotropia, stereopsis, torticollis



**Fig. 10.** Superior and inferior oblique muscles of case 14. Note increased stiffness (after elongation) and absence of contraction of the superior oblique muscle after administration of succinylcholine chloride because of palsy. Note also increased stiffness of the inferior oblique muscle, ie, contracture of the ipsilateral antagonist.

(two cases) and a hypertropia that increased in adduction, in down-gaze, in adduction-and-down-gaze and on ipsilateral head-tilt.

## Discussion

Almost all horizontal recti of patients who underwent first surgery for uncomplicated horizontal squint (group A) had linear length-tension relations with spring constants between 0.35 and 0.55 g/deg of eye rotation during contraction evoked by succinylcholine chloride (Fig. 4). One lateral rectus muscle (case 15) had a spring constant of 0.73 g/deg. The vertical rectus muscles also had linear length-tension relations, with spring constants in a similar range (Fig. 6). The range of spring constants of horizontal rectus muscles that we found during contraction evoked by succinylcholine chloride corresponds with the range of spring constants of horizontal recti muscles in the awake state. This can be deduced from earlier measurements of the spring constant in passive, horizontal eye rotation in awake volunteers. The spring constant in passive, horizontal eye rotation is composed of the spring constants of the medial and lateral rectus muscles and the spring constant of the adnexa of the eye. (We found in our modified Robinson computer model of eye movements<sup>20,21</sup> that the horizontal action of the vertical rectus and oblique muscles is almost negligible.) If the spring constant during succinylcholine chloride-induced contraction and the spring constant in the awake state correspond, then the spring constant in passive, horizontal eye rotation in the awake state should be slightly more (due to the elasticity of the adnexa of the eye) than the sum of the spring constants of both horizontal recti. This has indeed been found: Collins et al<sup>22</sup> found 0.99 g/deg, on average, for pulling the eye from 30° of adduction to 30° of abduction or vice versa. We found 0.91 g/deg for pulling the eye from 5° of adduction into abduction.<sup>1</sup> (In both of these experiments, innervation to the eye muscles was kept constant by letting the patient fixate a target with the other eye. For the sake of simplicity it is assumed in the above reasoning that, under static conditions, in the awake state and while the eye is in primary position, the spring constant of a rectus muscle is roughly equal to the spring constant at higher levels of contraction.) One might argue that the spring constant during succinylcholine chloride-induced contraction and the spring constant during the awake state cannot be compared, because the exact degree of recruitment of the different kinds of eye muscle fibers during the awake state under static conditions is unknown, whereas succinylcholine chloride stimulates the mul-

tively innervated fibers preferentially. It seems likely, however, that the slow, multiply innervated fibers are recruited almost continuously, and therefore determine the spring constant of the muscle under static conditions to a large extent.<sup>23,24</sup> Pursuing this line of thought, attempts have been made recently to correlate the succinylcholine-induced ocular position to postoperative alignment in strabismus surgery.<sup>25</sup> The only nonlinear length-tension diagram was in case 4, a girl with convergence excess (Fig. 5). In one patient (case 13) who had a congenital, vertical nystagmus, the spring constants were exceptionally low (Fig. 7).

In oblique muscles (group C), the relation between length and tension was frequently nonlinear, also when both oblique muscles contracted vividly and equally. Whether this is due to pathological changes in these muscles, to their connective tissue or muscle fiber type composition being quantitatively or qualitatively different, or whether these findings are related to their smaller change in length *in vivo*, as compared to recti muscles,<sup>26</sup> is unclear at present. The fact that we found nonlinearity of similar shape in the length-tension curves of superior and inferior oblique muscles distracts from the possibility that the nonlinearity was an artefact. In some cases (35, 42 and 43), both oblique muscles contracted little after injection of succinylcholine chloride, possibly because the muscles were still under the influence of the alcuronium chloride or vecuronium bromide given at intubation. All measurements were performed, however, at least 25 min after administration of either muscle relaxant. Moreover, lack of contraction after administration of succinylcholine chloride was never seen in the rectus muscles of group A. The spring constants of oblique muscles (often rough estimates as the curves were frequently nonlinear) were comparable to those of rectus muscles. This is amazing because the oblique muscles are thinner than rectus muscles.

In superior oblique palsies, the superior oblique muscle was found to be stiff after elongation, before injection of succinylcholine chloride, and it did not contract after injection of succinylcholine chloride (Fig. 10). In those cases the ipsilateral inferior oblique did contract after injection of succinylcholine chloride, but with a higher spring constant than usual (ie, contracture of the ipsilateral antagonist). Increased stiffness, after elongation, was also seen in rectus muscle palsies. In superior oblique muscle palsies, however, this increased stiffness after elongation may also have been caused by the superior oblique muscle getting stuck in the trochlea.

The results of all measurements of oblique muscles were fully compatible with the clinical findings ex-

cept in cases 9, 24 and 44 (19, 10 and 15 years old, respectively). In these three cases the superior oblique muscle contracted vividly after administration of succinylcholine chloride despite the presence of a vertical divergence that increased in adduction, in down-gaze, in adduction-and-down-gaze and on ipsilateral head-tilt (Bielschowsky's head-tilt test) (Figs. 8, 9). They had excyclotropia, stereopsis and torticollis (two cases). The finding of a vividly contracting superior oblique muscle is incompatible with the diagnosis of a superior oblique palsy. Hence, in our opinion some cases of congenital superior oblique palsy that are diagnosed using the criteria mentioned above may in fact be unilateral strabismus sursoadductorius (upshoot in adduction). The fact, however, that the Bielschowsky head-tilt test can be positive in this motility disorder, implies that real under- or overactions are at work.

The increase of vertical divergence from adduction-upgaze to adduction-downgaze seemed a good additional parameter of a superior oblique palsy. Likewise, a superior oblique palsy is more likely if the differences between the vertical deviations in Bielschowsky's head-tilt test is larger when the test is performed in down-gaze as compared to up-gaze.<sup>27</sup> The latter distinction parallels the more frequent occurrence of chin-down head posture together with head-tilt in superior oblique palsies as opposed to head-tilt only, in monolateral strabismus sursoadductorius.

In reoperations (group D), the muscles were generally found to be stiffer than in first operations, except in case 11. Three cases (20, 34 and 47) had had total tenotomies between 32 and 41 years previously. Two of the three tenotomized muscles contracted modestly, despite being detached from the globe for years. This may seem amazing, but it must be realized that a totally tenotomized muscle is often connected to the globe by the remains of the muscle sheath, so that some use and exercise of the muscle is still possible. In case 20 we found a normal length-tension diagram, after administration of succinylcholine chloride, of the antagonist of the tenotomized muscle, with a spring constant of 0.35 g/deg. This exception to the general rule of ipsilateral antagonists having similar spring constants is explained by the tenotomy of the lateral rectus muscle. After surgery, which consisted of reattachment of the lateral rectus muscle to the original insertion and a 7 mm recession of the medial rectus muscle, the patient had a 15° divergence. Three weeks later another operation was performed. The length-tension diagram of the lateral rectus muscle was more or less unchanged, although this was recorded without detaching the muscle from the globe, as no operation on the lateral rectus muscle

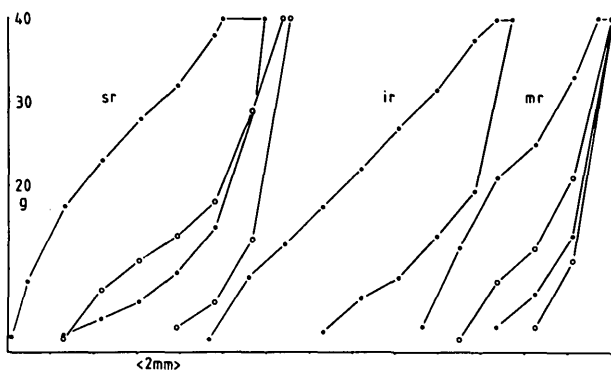


Fig. 11. Superior rectus and inferior rectus muscles of the left eye and medial rectus muscle of the right eye of case 40 (general fibrosis syndrome). Although vertical eye movements were absent in the left eye, its vertical rectus muscles contracted almost normally after administration of succinylcholine chloride. This finding is compatible only with a supranuclear or misdirectional cause for the general fibrosis syndrome, at least in this case. A large recession of the lateral rectus muscle of the right eye had been performed previously, explaining the increased stiffness of the medial rectus muscle on that side.

was performed. Interestingly, the medial rectus muscle now had a spring constant of 0.80 g/deg. Whether this was caused by the muscle being slack after the large recession or by decreased motility of the eye due to the reattachment of the stiff lateral rectus muscle, remains a matter of conjecture. It is certainly surprising that the spring constant of an eye muscle can rise that quickly. The speed of the change parallels the speed of the release of a contracture of a medial rectus muscle in cases of lateral rectus palsy, after injection

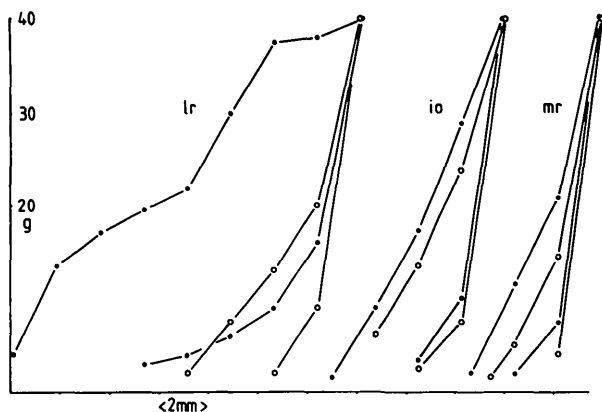


Fig. 12. Lateral rectus, inferior oblique and medial rectus muscles of case 32 (Graves' disease). This patient had a large exocycloptropia ( $18^\circ$  in primary position). No thick inferior oblique muscle could be identified in a CT scan. When assessing the length-tension diagrams of medial rectus, lateral rectus and inferior oblique muscles, however, we found both the medial rectus and the inferior oblique to be stiff and to lack contraction after succinylcholine chloride, whereas the lateral rectus contracted vividly, albeit with a spring constant that was higher than normal. Hence, it was likely that the large exocycloptropia was indeed caused by a fibrosed inferior oblique muscle.

of botulinum.<sup>28</sup> It is possible that the contracture of a slack muscle is not caused by changes in the connective tissue of the muscle, like in Graves' disease, but by changes in the sarcomeres themselves.

All length-tension diagrams after administration of succinylcholine chloride of patients with palsies other than superior oblique palsy (group E) were according to expectations, except that of case 40. In this 8-year-old girl with general fibrosis syndrome (the patient's mother and other family members were also affected) we found almost normally contracting vertical recti of the left eye were virtually absent (the left eye made small and slow horizontal movements, with pupillary constriction on adduction, when the patient was asked to look up or down). The fact that intact and hence innervated muscle fibers were present is compatible only with a supranuclear or misdirectional cause for this syndrome, at least in this patient.

In two of the patients with Graves' disease (group F) we found the affected muscles to be stiff and not contracting after administration of succinylcholine chloride. In case 32 we were puzzled by a large exocyclo deviation ( $18^\circ$  in primary position). In a CT scan, no thick inferior oblique muscle could be identified. However, we found both the medial rectus and the inferior oblique to be stiff before injection of succinylcholine chloride, and to lack contraction after injection of succinylcholine chloride, whereas the lateral rectus contracted vividly (Fig. 12). This finding indicated that the large exocyclo deviation was indeed caused by the affected inferior oblique muscle.

The clinical cases discussed above demonstrate the usefulness of the assessment of the length-tension diagram of an eye muscle during surgery, before and during contraction evoked by succinylcholine chloride.

**Key words:** eye movements, eye muscles, length-tension curves, eye muscle palsy, muscle relaxants

### Acknowledgments

We would like to thank nurse I. Klinger and her staff, anesthesiologists F. Salomon, PhD, and E. Grimm, PhD and their staff, and N. Bakker and R. Eckstein for their kind cooperation.

### References

1. Simonsz HJ, Kolling GH, Kaufmann H, and van Dijk B: Intraoperative length and tension curves of human eye muscles and stiffness in passive horizontal eye movement in awake volunteers. *Arch Ophthalmol* 104:1495, 1986.
2. Asmussen G: Morphologische, physiologische und pharmakologische Eigenschaften der äusseren Augenmuskeln und ihre Veränderungen nach Denervation. Dissertation, Leipzig, 1978.
3. Gordon AM, Huxley AF, and Julian FJ: The variation in iso-

- metric tension with sarcomere length in vertebrate muscle fibres. *J Physiol* 184:170, 1966.
4. Robinson DA, O'Meara DM, Scott AB, and Collins CC: Mechanical components of human eye movements. *J Appl Physiol* 26:548, 1969.
  5. Collins CC, Scott AB, and O'Meara DM: Elements of the peripheral motor apparatus. *Am J Optom* 46:510, 1969.
  6. McMahon ThA: *Muscles, Reflexes and Locomotion*. Princeton, New Jersey, Princeton University Press, 1984, pp. 8-9.
  7. Duke-Elder WS and Duke-Elder PM: The contraction of the extrinsic muscles of the eye by choline and nicotine. *Proc Roy Soc Biol*, 107:332, 1930.
  8. Bach-y-Rita P, Lennerstrand G, Alvarado J, Nichols K, and McHolm G: Extraocular muscle fibers: Ultrastructural identification of iontophoretically labeled fibers contracting in response to succinylcholine. *Invest Ophthalmol* 16:561, 1977.
  9. Asmussen G, Kiessling A, and Wohlrab F: Histochemische Charakterisierung der verschiedenen Muskelfasertypen in den äusseren Augenmuskeln von Säugetieren. *Acta Anat* 79:526, 1971.
  10. Kaneko H, Koga A, and Adachi K: Quantitative designation of the forced duction test: I. Difference between normal and pathological extra-ocular muscles. *Acta Soc Ophthalmol Jpn* 75:1515, 1971.
  11. Madroszkiewicz M: Oculomyodynamometry: The strength and work of extra-ocular muscles in squint. *Ophthalmologica* 161:491, 1970.
  12. Metz HS and Cohen G: Quantitative forced traction measurements in strabismus. In *Strabismus II, Proceedings of the Fourth Meeting of the International Strabismus Association, Asilomar, Reinecke RD, editor*. New York, Grune & Stratton, 1984, pp. 755-766.
  13. Roth A: Les choix et le dosages opératoires en cas de strabismes dits concomitantes. In *Chirurgie des Strabismes, Bérard PV, Quéré MA, Roth A, Spielmann A, and Woillez M, editors*. Paris, Masson, 1984, pp. 188-204.
  14. Strachan IM, Brown BH, Johnson SG, and Robinson P: An apparatus for measuring forces in strabismus. In *Orthoptics—Past, Present, Future, Moore S, Mein J, and Stockbridge L, editors*. New York, Stratton, 1976, pp. 123-128.
  15. Rosenbaum AL and Meyer JH: New instrument for the quantitative determination of passive forced traction. *Ophthalmology* 87:158, 1980.
  16. Schillinger RJ: The prevention of over-correction and under-correction in horizontal strabismus surgery. *J Pediatr Ophthalmol* 3:38, 1966.
  17. Scott AB, Collins CC, and O'Meara DM: A forceps to measure strabismus forces. *Arch Ophthalmol* 88:330, 1972.
  18. Stephens KF and Reinecke RD: Quantitative force duction. *Trans Am Acad Ophthalmol Otolaryngol* 71:324, 1967.
  19. Simonsz HJ, Crone RA, de Waal BJ, Schooneman M, and Lorentz de Haas HAL: Measurement of the mechanical stiffness in cyclotorsion of the human eye. *Vision Res* 24:961, 1984.
  20. Simonsz HJ and van Dijk B: Analysis of the dosage controversy in recess-resect and Faden surgery with the Robinson computer model of eye movements. *Doc Ophthalmol* 67:237, 1988.
  21. Simonsz HJ, Härting F, de Waal BJ, and Verbeeten BWJM: Sideways displacement and curved path of recti eye muscles. *Arch Ophthalmol* 103:124, 1985.
  22. Collins CC, Carlson MR, Scott AB, and Jampolsky A: Extraocular muscle forces of normal human subjects. *Invest Ophthalmol Vis Sci* 20:652, 1981.
  23. Gornig H, Asmussen G, and Kiessling A: Vorkommen und Bedeutung monophasischer Potentiale im Elektromyogramm der äusserer Augenmuskeln von Kaninchen und Katze. *Graefes Arch Clin Exp Ophthalmol* 196:159, 1975.
  24. Scott AB and Collins CC: Division of labor in human extraocular muscle. *Arch Ophthalmol* 90:319, 1973.
  25. Lingua RW, Azen SP, Walonker F, Levin L, and Baker S: A comparison of the succinylcholine induced ocular position and the postoperative alignment in strabismus. *J Pediatr Ophthalmol Strabismus* 23:69, 1986.
  26. Clement RA: Description of the length-tension curves of the extraocular muscles. *Vision Res* 27:491, 1987.
  27. Kolling GH: Diagnostik und operative Korrektur von Vertikal- und Zyklodeviationen bei Störungen schräger Augenmuskeln. *Habilitationschrift, Giessen*, 1986.
  28. Scott AB and Kraft SP: Botulinum toxin injection in the management of lateral rectus paresis. *Ophthalmology* 92:676, 1985.

## Appendix 1

Table of essential patient data (case number, age, diagnosis and angles of squint) and spring constants of contracting eye muscles found during succinylcholine-chloride induced contraction. The spring constants are, for convenience, expressed in unit gram per degree of eye rotation, assuming a radius of the globe of 11.7 mm, conforming to 24.6 mm axial length. Then 1° on the surface of the globe equals 0.2042 mm. "Exoph" denotes exophoria; "esoph", esophoria; "conv", convergent; "div", divergent; "V", V-pattern; "A", A-pattern; "VD", vertical divergence (negative operation sign indicates left hypertropia); "DVD", dissociated vertical divergence; "rec", recess surgery; "res", resect surgery; "Bielschowsky", VDs in Bielschowsky head-tilt test, on head-tilt to the right and left shoulder, respectively; "sursoadd", strabismus sursoadductorius (upshoot in adduction); "deorsoadd", strabismus deorsoad-

ductorius (downshoot in adduction); "far", angle of squint at far, using alternating cover test; "near", angle of squint at near, using alternating cover test; "ALC", alcuronium chloride and "VEC", vecuronium bromide. The latter two are nondepolarizing muscle relaxants that were given at intubation, 25 to 50 min before the first measurement. When no mention is made of "ALC" or "VEC", no data were available on their administration, "LR", "MR", "SR", "IR", "SO" and "IO" refer to the six eye muscles, preceded by "R" or "L" for right or left eye, respectively; "contr" denotes contraction; "nct" denotes no contraction after injection of succinylcholine chloride; "n1" denotes a nonlinear length-tension curve after contraction evoked by succinylcholine chloride. Cases 1, 2 and 3 have been described previously (Simonsz et al, 1986<sup>1</sup>, case numbers 9, 5 and 11 in that article).



## Appendix 1 (Continued)

Pat.	Age	Diagnosis and angles of squint	Spring constants	Pat.	Age	Diagnosis and angles of squint	Spring constants
Group A: First surgery for uncomplicated horizontal squint				Group C: Strabismus sursoadductorius and superior oblique palsy (continued)			
1	23 y	Div; far: -22°, near: -25°; 10 mg ALC	LLR .35, LMR .35	14	35 y	Left superior oblique palsy; torticollis; VD: -2°, on right/left gaze: -8°/0°, on right + up/down gaze: -4°/-14°, Bielschowsky: -2°/-6°; excyclo: +2°; stereopsis: +20°; 8 mg VEC	LSO nct, LIO 1.18
2	20 y	Conv; far: +25°, near: +25°; 10 mg ALC	LLR .42, LMR .39	16	33 y	Left superior oblique palsy; torticollis; VD: -5°, on right/left gaze: -12°/-1°, on right + up/down gaze: -14°/-11°, Bielschowsky: 0°/-10°; excyclo: +3°; stereopsis: +20°; 6 mg VEC	LSO nct, LIO .43
4	5 y	Conv with excess convergence, left recess/resect surgery for convergence 3 months previously; far: +12°, near: +22°; no ALC or VEC	RMR n1	22	6 y	Conv, V, sursoadd, far: +12°, near +12°, on up/down gaze: +6°/+16°; VD: -3°, on right/left gaze: -15°/+4°, Bielschowsky: not measured; no binocular vision; 0.5 mg VEC	RIO .34, LIO .35 (partly n1)
5	35 y	Decompensated esoph; far: +10°, near +7°; 2 mg ALC	RLR .40, RMR .42	24	10 y	Left microstrabismus, anisometropia with left hypermetropia, torticollis; far: +3°, near +2°; VD: -10°, on right/left gaze: -15°/-2°, on right + up/down gaze: -10°/-19°, Bielschowsky: -2°/-9°; excyclo: +5°; stereopsis: 140°; 1 mg ALC	LSO .49, LIO .43 (LSO more contr than LIO)
8	6 y	Conv; far: +17°, near: +17°; no ALC or VEC	LLR .34, LMR .35	26	6 y	Conv, sursoadd, V, DVD; far: +10° to +17°, on up/down gaze: +9°/+20°, near: +17° to +20°; 1 mg VEC	RIO n1, LIO n1 (both little contr)
10	30 y	Exophoria; far: -16°, near: -20°; stereopsis: 20°; 8 mg ALC	LLR .36, LMR .36	29	21 y	Left superior oblique palsy; torticollis; VD: 0 deg, on right/left gaze: -7°/-1°, on right + up/down gaze: -9°/-8°, Bielschowsky: +1°/-7°; excyclo: +2°; stereopsis: 70°; 4 mg VEC	LSO nct
15	41 y	Decompensated exoph, previous div surgery on right eye 6 months previously; far: -30°, near -38°; VD: -4°; stereopsis: 20°; 8 mg VEC	LLR .73, LMR .55	31	6 y	Conv, sursoadd, V, right amblyopia (0.6); far: +32°, on up/down gaze: +25°/+35°, near: +32°; VD: +5°, on right/left gaze: -3°/+8°; Bielschowsky: not measured; 1 mg VEC	RIO n1, LIO n1 (both modest contr)
19	6 y	Esoph; far: +16°, near: +17°; stereopsis: 20°; 1 mg VEC	LLR .36, LMR .36	35	7 y	Conv, sursoadd, V, DVD, right amblyopia; far: +17°, on up/down gaze: +9°/+21°; VD: dissociated, on right/left gaze: -12°/+6°, but with dark red filter before fixing eye, -4°/0°; 0.5 mg VEC	RIO n1, LIO n1 (both modest contr)
21	45 y	Conv, A, deorsoad; far: +20°, on up/down gaze: +22°/+17°, near: +25°; VD: +9°, on right/left gaze: +10°/+12°, on up/down gaze: +9°/+5°, 8 mg VEC	LLR .53, LMR .48	39	24 y	Right superior oblique palsy; torticollis; far: -5°, on right/left gaze: -1°/-8°; VD: +9°, on right/left gaze: +1°/+18°, on up/down gaze: +7°/+8°, on left + up/down gaze: +15°/+21°, Bielschowsky: +15°/+2°; excyclo: +5°; stereopsis: 400°; 6 mg VEC	RSO nct RIO little contr
23	4 y	Conv, DVD; far: +20°, near: +22°; 0.3 mg VEC	LMR .55				
38	17 y	Conv, sursoadd, DVD, latent nystagmus; far: +34°, on up/down gaze: +30°/+37°; VD: -9°, on right/left gaze: -13°/-7°; 6 mg VEC	LLR .57, LMR .49				
Group B: Vertical recti							
7	15 y	Duane, microphthalmia and amblyopia of the left eye, DVD; far: +5°, near: +5°; VD: -15°; retraction and lid narrowing on adduction of the left eye; 10 mg ALC	LSR .42, LIR .46				
13	26 y	Congenital nystagmus, dampening on down-gaze and on convergence; torticollis: chin up; 8 mg VEC	LSR .21, LIR .22				
18	29 y	Left hypophoria, exoph; far: -4°, near: -8°; VD: +8°; 8 mg VEC	LMR .39, RIR .40				
Group C: Strabismus sursoadductorius and superior oblique palsy							
9	19 y	Decompensated sursoadd, V; far: 0°, on up/down gaze: -7°/+4°, near: -7°; VD: +7°, on right/left gaze: +5°/+13°, on left + up/down gaze: +10°/+12°, Bielschowsky: +10°/+5°; excyclo: 4°; stereopsis: 20°; 10 mg ALC	RSO n1, RIO n1				
12	3 y	Decompensated esoph, V, sursoadd; far: +10°, on up/down gaze: +5°/+20°, near: +15°; VD: +2°, on right/left gaze: -10°/+17°, Bielschowsky: +6°/+6°; stereopsis: TNO and Titmus Fly positive; 1 mg VEC	RIO .37, LIO .37 (RIO little contr)				

## Appendix 1 (Continued)

Pat.	Age	Diagnosis and angles of squint	Spring constants	Pat.	Age	Diagnosis and angles of squint	Spring constants
Group C: Strabismus sursoadductorius and superior oblique palsy (continued)				Group D: Reoperation for horizontal squint (continued)			
41	35 y	Left superior oblique palsy after removal of eyelid tumor 1 year previously; torticollis; VD: -7°, on right/left gaze: -10°/-3°, on right + up/down gaze: -3°/-15°, Bielschowsky: -5°/-10°; excyclo: 7°; stereopsis: 20°; 5 mg VEC	LSO nct, LIO .44 (LIO modest contr)	20	44 y	Total tenotomy of right lateral rectus 32 years previously, conv since 14 years, A; far: +17°, on up/down gaze: +20°/+6°, near: +22°; VD: +4°; adduction of the right eye limited to 15°; during surgery, 10 mm behind the limbus remains of the muscle sheath and 20 mm behind the limbus muscle fibers of the lateral rectus were identified; 6 mg VEC	1st measurem: RLR .68 RMR .36
42	3 y	Left superior oblique palsy, torticollis; far: -7°, near: +1°; VD: -12°, on right/left gaze: -15°/+1°, on up/down gaze: -8°/-17°, on right + up/down gaze: -13°/-18°, Bielschowsky: -4°/-17°; binocular vision; Bagolini positive; 0.5 mg VEC	LSO nct, LIO .55 (LSO little contr, LIO modest contr)			The patient was divergent after reattachment of the right lateral rectus to the original insertion, 7 mm recession of the medial rectus and partial tenotomy of the superior oblique; far: -30°, after three weeks reduced to -15°; then a reoperation was performed;	2nd measurem: RLR 1.18, RMR .79
43	21 y	Left superior oblique palsy; torticollis; VD: -6°, on right/left gaze: -16°/-2°, on right + up/down gaze: -10°/-20°, Bielschowsky: -3°/-19°; excyclo: +2°; stereopsis: 20°; 2 mg VEC	LSO .35, LIO .48 (LSO partly n1, both modest contr)	34	48 y	Consecutive div, 2 previous surgeries for conv 40 years previously, including a total tenotomy of the left medial rectus muscle; far: -20°, near: -22°; adduction of left eye limited to 10 deg; during surgery, 8 mm behind the original insertion remains of the muscle sheath and 16 mm behind the original insertion muscle fibers were identified; 2 mg VEC	LLR .81, LMR nct
44	15 y	Sursoadd, no torticollis; far -3°, near -7°; VD: +2°, on right/left gaze: 0°/+4°, on up/down gaze: +2°/+2°, Bielschowsky: +1°/+5°; excyclo: +11°; stereopsis: 50°; 6 mg VEC	RSO nl, LSO nl, (vivid contr)				
46	18 y	Conv, V, sursoadd, myopia; far: 40°, on up/down gaze: 30°/48°, near: +46°; VD: -2°, on right/left gaze: -2°/+5°, Bielschowsky: -1°/+5°; excyclotropia: 12°; 6 mg VEC	RSO nct, RIO .48 (RIO modest contr)	47	46 y	Total tenotomy of the right medial rectus 41 years previously; far: -36°, near: -40°; adduction of the right eye limited to 5°; 8 mg VEC	RMR .53
Group D: Reoperation for horizontal squint				Group E: Palsies (other than superior oblique palsies)			
3	20 y	Div; previous bilateral medial rectus recess surgery; far: -12°, near: -12°, no ALC or VEC	LLR .57	6	27 y	Medial rectus palsy (as demonstrated by the measurement); far: -10°, on right/left gaze: -8°/-12°, on up/down gaze: -10°/-10°, near: -17°; incyclo: -1°; 8 mg ALC	LLR .68, LMR nct
11	22 y	Conv, 5 previous operations: left eye: medial rectus recession twice, lateral rectus resection and later recession, inferior rectus recession; right eye: medial rectus recession and Faden surgery; far: +10°, on right/left gaze: +2°/+10°, on up/down gaze: +18°/+6°; 10 mg ALC	LLR .32	25	73 y	Bilateral lateral rectus palsy; far: +15°, on right/left gaze: +5°/+22°; abduction of right eye limited to 35°, of left eye limited to 25°; stereopsis 40°; 6 mg VEC	LLR nct, LMR nct
17	23 y	Consecutive div, bilateral medial rectus recessions 18 years previously, A, deorsoadd; far: -20°, on up/down gaze: -20°/-25°, near: -25°; VD: 0°, on right/left gaze: +8°/-7°; 6 mg VEC	RLR .43, RMR .53	28	31 y	Right lateral rectus palsy, previous bilateral horizontal Kestenbaum surgery for congenital nystagmus: recession of the lateral rectus and resection of the medial rectus of the right eye; far: +33°, on right/left gaze: +49°/+20°; stereopsis: 200°; right eye could not abduct further than 25 deg adduction; 6 mg VEC	RLR .61, RMR .57 (RLR little contr)

## Appendix 1 (Continued)

Pat.	Age	Diagnosis and angles of squint	Spring constants	Pat.	Age	Diagnosis and angles of squint	Spring constants
Group E: Palsies (other than superior oblique palsies) (continued)				Group E: Palsies (other than superior oblique palsies) (continued)			
30	47 y	Right partial oculomotorius palsy since 3 years of age, right amblyopia; far: $-30^\circ$ , on right/left gaze: $-25^\circ/-35^\circ$ , on up/down gaze: $-24^\circ/-38^\circ$ ; VD: $-4^\circ$ , on up/down gaze: $-15^\circ/+2^\circ$ , on left + up/down gaze: $-22^\circ/0^\circ$ , near: $-30^\circ$ ; adduction of the right eye limited to $0^\circ$ , up-gaze limited to $5^\circ$ , down-gaze limited to $15^\circ$ ; 6 mg VEC	RLR .63, RMR .41 (RLR modest contr, RMR little contr)	45	35 y	Left Duane, right microstrabismus and amblyopia; far: $+24^\circ$ , near: $+11^\circ$ ; angles with torticollis ( $15^\circ$ left head-turn): far: $+7^\circ$ , near: $+2^\circ$ ; stereopsis: $200^\circ$ ; 2 mg VEC	LLR little contr, LMR .76
				Group F: Graves' disease			
33	25 y	Left lateral rectus palsy, limitation of up-gaze in right eye; far: $+16^\circ$ , on right/left gaze: $+1^\circ/+26^\circ$ , on up/down gaze: $+10^\circ/+5^\circ$ ; VD: $-6^\circ$ , on right/left gaze: $-2^\circ/-12^\circ$ ; stereopsis: $40^\circ$ ; abduction of left eye limited to $7^\circ$ , up-gaze of right eye limited to $30^\circ$ ; 6 mg VEC	LLR nct, LMR .30	27	48 y	Graves; far: $+2^\circ$ , on right/left gaze: $+7^\circ/+2^\circ$ , on down gaze: $+7^\circ$ , near: $+4^\circ$ ; excyclo: $7^\circ$ ; stereopsis: $20^\circ$ , up-gaze limited to $20^\circ$ in right eye and to $0^\circ$ in left eye; 2 mg VEC	LSR .33, LIR .70
37	46 y	Fibrosis syndrome of the left eye; previous left inferior rectus and lateral rectus recessions, later right superior rectus recession and inferior rectus resection; far: (right fixation) $-10^\circ$ , on right/left gaze: $-22^\circ/-5^\circ$ , (left fixation) $-21^\circ$ , near: (right fixation) $-20^\circ$ , (left fixation) $-30^\circ$ ; VD: $+13^\circ$ , on up/down gaze: $+30^\circ/-1^\circ$ , on right/left gaze: $+11^\circ/+19^\circ$ ; 8 mg VEC	RMR .43	32	48 y	Graves, conv, previous left recess/resect surgery 7 months previously; far: $+18^\circ$ , on right/left gaze: $+18^\circ/+25^\circ$ , on up/down gaze: $+14^\circ/+20^\circ$ ; VD: $+1^\circ$ , on right/left gaze: $+1^\circ/+7^\circ$ ; excyclotrophia: $+18^\circ$ , on up/down gaze: $+28^\circ/+17^\circ$ , on right/left gaze: $+19^\circ/+16^\circ$ ; 4 mg VEC	RLR .41 RMR nct RIO nct
40	8 y	Familial congenital fibrosis syndrome, left myopia and amblyopia; previous right lateral rectus recession; torticollis: $15^\circ$ left face turn, $15^\circ$ chin high; the left eye made erratic, slow horizontal eye movements when the patient was asked to look up or down, with pupillary narrowing on adduction, movement of the right eye was limited to $30^\circ$ abduction and to $30^\circ$ adduction, vertical eye movements were absent; far: $-5^\circ$ to $-15^\circ$ , near $-5^\circ$ to $-20^\circ$ ; VD: $+15^\circ$ ; 2 mg VEC	RMR .68 LSR .55 LIR .53	36	73 y	Graves, two previous recess/resect surgeries on left eye; far: $+14^\circ$ , on right/left gaze: $+6^\circ/+19^\circ$ , on up/down gaze: $+15^\circ/+16^\circ$ ; VD: $+4^\circ$ on right/left gaze: $+7^\circ/+3^\circ$ , on up/down gaze: $+6^\circ/5^\circ$ ; excyclotrophia: $+5^\circ$ ; stereopsis: $100^\circ$ ; abduction of right eye limited to $15^\circ$ , adduction of left eye limited to $25^\circ$ , abduction of left eye limited to $35^\circ$ ; 4 mg VEC	RLR .40 RMR .44 (both modest contr)