

PEDIATRICS®

OFFICIAL JOURNAL OF THE AMERICAN ACADEMY OF PEDIATRICS

A Family With Extrinsic Allergic Alveolitis Caused by Wild City Pigeons: A Case Report

Gideon J. du Marchie Sarvaas, Peter J. F. M. Merkus and Johan C. de Jongste
Pediatrics 2000;105:62-
DOI: 10.1542/peds.105.5.e62

This information is current as of December 4, 2006

The online version of this article, along with updated information and services, is located on the World Wide Web at:

<http://www.pediatrics.org/cgi/content/full/105/5/e62>

PEDIATRICS is the official journal of the American Academy of Pediatrics. A monthly publication, it has been published continuously since 1948. PEDIATRICS is owned, published, and trademarked by the American Academy of Pediatrics, 141 Northwest Point Boulevard, Elk Grove Village, Illinois, 60007. Copyright © 2000 by the American Academy of Pediatrics. All rights reserved. Print ISSN: 0031-4005. Online ISSN: 1098-4275.

American Academy of Pediatrics

DEDICATED TO THE HEALTH OF ALL CHILDREN™



A Family With Extrinsic Allergic Alveolitis Caused by Wild City Pigeons: A Case Report

Gideon J. du Marchie Sarvaas, MD; Peter J. F. M. Merkus, MD, PhD; and Johan C. de Jongste, MD, PhD

ABSTRACT. We describe a family in which the mother died of unresolved lung disease and whose 5 children, some of whom had previous signs of asthma, were subsequently affected by extrinsic allergic alveolitis caused by contact with wild city pigeon antigens. The children received systemic corticosteroids for 1 month and inhaled steroids for 24 months, while antigen exposure was reduced as much as feasible. This was followed by a quick clinical recovery and a slow normalization of chest radiographs and pulmonary function indices, especially of diffusion capacity, during a follow-up of 24 months.

Because pigeon-breeder's lung caused by free-roaming city pigeons has not been previously described, it remains unclear whether this family developed the disease because of high antigen exposure or because of increased susceptibility. None of the supposedly high-risk human leukocyte antigen types were found in the children. Whether human leukocyte antigen B7 in 1 child played a role in the course of the illness remains speculative. It is unknown to what extent pigeon-breeder's lung caused by nondomestic birds remains undetected and misdiagnosed as difficult or steroid-resistant asthma. The question remains whether free-roaming city pigeons are indeed a public health risk. We suggest that atypical outdoor antigens be considered in all patients with nonresolving chest disease or therapy-resistant asthma. *Pediatrics* 2000;105(5). URL: <http://www.pediatrics.org/cgi/content/full/105/5/e62>; *birds, extrinsic allergic alveolitis, asthma, outcome, follow-up, human leukocyte antigen.*

ABBREVIATIONS. PBL, pigeon-breeder's lung; IgG, immunoglobulin G; FEV₁, forced expiratory volume in 1 second; FVC, forced vital capacity; TLC, total lung capacity; RV, residual volume; D_LCO, diffusion capacity of the lung corrected for hemoglobin and alveolar volume; HLA, human leukocyte antigen.

Pigeon-breeder's lung (PBL) or bird-fancier's lung is one of the most common forms of extrinsic allergic alveolitis or hypersensitivity pneumonitis.^{1,2} It is caused by progressive immunologic injury of the lung parenchyma after prolonged exposure to avian antigens.^{2,3} Although the exact pathogenic mechanism is unclear, PBL is believed to be secondary to the combination of an immune-

complex and cell-mediated immune response.³ PBL has been described in adults keeping birds but has also been documented in their offspring,⁴⁻⁸ even in children as young as 3 years of age.⁵ PBL presents as an acute illness with fever, dyspnea, and malaise that improves quickly after antigen elimination, or as an insidious process mimicking severe asthma, with general discomfort, coughing, shortness of breath, and weight loss.^{4-6,9} Its diagnosis is based on clinical grounds and a thorough history and careful examination should reveal the antigen exposure and assess the possibility of PBL.^{2,3} Histologic confirmation of extrinsic allergic alveolitis has been advocated by some^{2,8} and not by others.^{9,10} Laboratory findings associated with the disease are elevated antibodies (usually immunoglobulin G [IgG], but also immunoglobulin M and immunoglobulin A in lower titers) that precipitate against pigeon serum, feathers, and/or feces,¹¹ although these are often also present in asymptomatic bird breeders.^{1,3,12} Patients develop obstructive and restrictive lung disease and diminished diffusion capacity of the lung.^{2,3} Short-term recovery after cessation of exposure seems to depend on the age of the patient and the duration of exposure.^{13,14} The scarce long-term follow-up reports on the course of the disease in children suggest a favorable outcome,^{8,14} although fatal or potentially fatal cases have been described.^{4,15} To our knowledge, there have been no reports of children with PBL caused by wild city pigeons. We describe a family in which 5 children developed PBL after the death of their mother attributable to an unknown interstitial lung disease, probably PBL.

CASE REPORT

Three weeks before her death a 34-year-old, previously healthy Pakistani woman, mother of 5 children, developed a flu-like illness with headache, dry cough, nausea, tiredness, and shortness of breath, not responding to a course of oral antibiotic treatment. Fever was absent. On admission to hospital 20 days later, she was tachypneic and dyspneic. Interstitial markings were seen on chest radiograph. A bronchoscopy and bronchoalveolar lavage for acid-fast bacilli and bacterial cultures revealed no pathogens. Antituberculosis therapy was started in combination with corticosteroids because miliary tuberculosis was suspected. Clinical deterioration continued, requiring artificial ventilation with 100% oxygen. Progressive hypoxemia quickly led to circulatory arrest and death 26 days after the initial symptoms. No mycobacteria were cultured and no evidence of autoimmune disease was found. Postmortem examination was refused. Thus, the cause of her lung disease remained unclear.

Within a few months after her death, all 5 of her children 8 to 14 years of age developed a cough with increased sputum production, nausea, anorexia, and varying degrees of shortness of breath, without fever. Two children (nr 2 and 3) were known with

From the Department of Paediatrics, Subdivision of Respiratory Medicine, Erasmus University and University Hospital/Sophia Children's Hospital, Rotterdam, The Netherlands.

Received for publication Sep 13, 1999; accepted Dec 6, 1999.

Address correspondence to Peter J. F. M. Merkus, MD, PhD, Department of Paediatrics, Erasmus University and University Hospital/Sophia Children's Hospital, Dr Molewaterplein 60, 3015 GJ, Rotterdam, The Netherlands. E-mail: merkus@alkg.azr.nl

PEDIATRICS (ISSN 0031 4005). Copyright © 2000 by the American Academy of Pediatrics.

TABLE 1. Clinical and Laboratory Findings

	Patient 1	Patient 2	Patient 3	Patient 4	Patient 5
Age (y)	14	13	12	9	8
Sex	Female	Female	Male	Male	Female
Presenting symptoms					
Cough	+	+	+	+	+
Sputum	+	-	+/-	+/-	+/-
Malaise	+	+	+	+	+
Anorexia	+	-	+	+	+
Weight loss	+	+	+	+	+
Fever	-	-	-	-	-
Dyspnea					
At rest	+	-	-	-	-
On exercise	+	+	+	+	+
History					
Eczema	-	-	+	+	-
Asthma	-	+	+	-	+
Allergy	-	HDM	HDM	-	HDM
Laboratory data					
Precipitins at time of diagnosis	4B, 2L	3B, 2L	0B, 3L	3B, 1L	1B, 2L
Precipitins after treatment	0B, 0L	0B, 1L	2B, 2L	0B, 0L	0B, 1L
Initial total immunoglobulin E (U/mL)	94	977	972	710	819

HDM indicates house dust mite; B, precipitation bands; L, precipitation lines.

asthma with variable airflow obstruction, house dust mite allergy, and eczema, but this time they did not respond to treatment with inhaled budesonide (200 µg twice daily via a spacer) by their general physician. Eventually, all were admitted to a local hospital for analysis and treatment. The father had no symptoms. All children were born in The Netherlands and had not left the country since 1978. The children were bacillus Calmette-Guérin-vaccinated, and there was no indication of a recent tuberculosis contact. The presenting symptoms of all 5 children are listed in Table 1. Weight loss varied between 5 and 9 kg. Diffuse fine crepitations were heard on auscultation. All chest radiographs revealed more or less identical, generalized, fine, reticulo-nodular markings compatible with diffuse interstitial lung disease. Digital clubbing was not evident. Pulmonary function tests confirmed severe obstructive, restrictive, and diffusion abnormalities (Figs 1 and 2).

Diagnosis

Considering the extensive differential diagnosis and suspecting a common infectious cause, patient 1 underwent a transbronchial lung biopsy because all bacterial, viral, and fungal test results were negative. She developed a pneumothorax with a protracted recovery, requiring oxygen therapy and lengthy external drainage for which she was transferred to our hospital. Two of the other children received clarithromycin because of suspected mycoplasma infection but did not improve. Repeated investigation of the children's house and surroundings by public health officials ruled out toxic, occupational, or infectious sources. A striking finding was the abundant presence of city pigeons in the vicinity, with nesting sites against the back of the house. In retrospect, the mother regularly cleaned the fire escape of bird droppings and feathers by hand, usually with the help of 1 or more of her children. Determination of specific anti-pigeon antibodies (primarily IgG against pigeon excreta, feathers, and serum) with double-gel immunodiffusion showed strongly positive results in the children (Table 1) but not in the father who had not been involved in the cleaning task. All had precipitins against serum and feathers. In patients 2, 3, and 4, precipitins against excreta were present at diagnosis; later, these were also observed in the other 2 patients. PBL was diagnosed because of the consistency of history and symptoms with the presence of pigeon antigen, precipitation bands, and lines and typical radiologic and ventilatory function abnormalities.

Treatment

Clinical treatment with oxygen supplementation and systemic corticosteroids (prednisolone: 2 mg/kg/day during 1 month) was followed by marked improvement of overall condition and pulmonary function (Figs 1 and 2). Once the diagnosis of extrinsic allergic alveolitis was made, efforts were made to reduce antigen

exposure by getting rid of pigeon nests and sealing off all rear windows. To this day, this has proven to be a rather arduous task. Complete removal of the pigeons has not been feasible and moving to another neighborhood proved too expensive. Therefore, it was decided to continue treatment with inhaled budesonide (400 µg twice daily) as described previously.¹⁷ Meanwhile the rear windows of the home would remain sealed at all times, and the family would be closely monitored. In the outpatient setting, lung function parameters were obtained at regular intervals; chest radiographs were repeated twice yearly until normalized, serum IgG levels were monitored semiquantitatively twice yearly.

Follow-up

Radiologic abnormalities on chest radiograph normalized in patients 3, 4, and 5 within 6 months, and in patient 2 within 12 months. Patient 1 showed a normal chest radiograph and computed tomography scan only after 18 months. Forced expiratory volume in 1 second (FEV₁) and forced vital capacity (FVC) quickly recovered to within normal limits (80%–120% of predicted) in all children, suggesting complete recovery within 6 months. The FEV₁/FVC ratio remained above 85% during the first year of follow-up, only to reach normal values (82%–84%) after 24 months of follow-up. Furthermore, total lung capacity (TLC) demonstrated a quick initial recovery of restrictive lung disease, followed by a more gradual improvement after the first 6 months. The elevated ratio of residual volume (RV) to TLC (RV/TLC) normalized quicker. Diffusion capacity of the lung corrected for alveolar volume and hemoglobin (D_Lco), the most sensitive marker of alveolar involvement, showed the slowest recovery of all parameters. Significant further normalization between 6 and 24 months of follow-up was only observed for FEV₁/FVC and D_Lco. Serum precipitins showed some decline but did not disappear, while clinical improvement was obvious. Total immunoglobulin E levels differed markedly among children, remaining relatively stable within subjects. A check for high-risk human leukocyte antigen (HLA) types B8, DW3, and DW6^{7,16,18} was negative in all. By deduction, the HLA profile of the mother could be reconstructed: A24/A28, B51/B44, Cw-/Cw7, DR4/DR7, DQ8/DQ2. Patient 1, who developed the most serious illness of all 5 children (initial FVC: 16% of predicted), had HLA typing: A24/A1, B51/B7, Cw-/Cw-, CR4/DR15, DQ8/DQ6. Her father had HLA type A1/A1, B62/B63, Cw3/Cw-, DR4/DR7, DQ8/DQ9 and no symptoms.

DISCUSSION

The cause of a rapidly progressive and fatal respiratory failure in a previously healthy young woman seemed to remain unexplained until her 5 children developed respiratory problems after her death. Their clinical picture resembled that of their mother

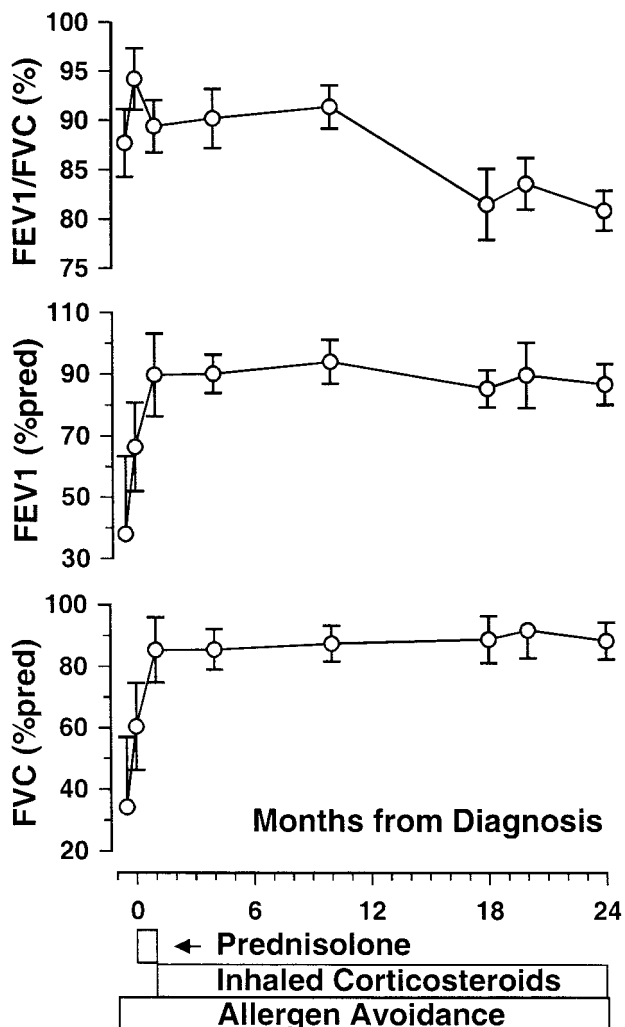


Fig 1. Mean (standard error of the mean: 2) of lung function indices during 24 months of treatment. FVC and FEV₁ are expressed as percent of predicted, FEV₁/FVC is expressed in percent. Periods and modes of treatment and allergen avoidance are shown below the horizontal axis.

except that the course was milder and recovery with proper treatment was successful. Eventually, a diagnosis of extrinsic allergic alveolitis caused by exposure to nondomestic pigeon antigens was made. This report illustrates that PBL can resemble therapy-resistant asthma, that it can coexist with asthma, but that it can also run a rapid fatal course.

Although full elimination of wild pigeons from the neighborhood was not feasible, this article suggests that the effect of inhaled corticosteroids and antigen avoidance on the course of extrinsic allergic alveolitis can be satisfactory in children. Especially, the diffusion capacity of the lung improved during the 2 years of follow-up. A decline of FEV₁/FVC was observed but was not a reliable measure to monitor recovery from restrictive lung disease because it may also reflect increased airway obstruction. That the transbronchial biopsy performed in patient 1 did not contribute to the diagnosis was not unexpected; a low diagnostic yield of transbronchial (50%) and transthoracic (57%) biopsies in children with interstitial lung disease has been described previously.⁹ Pre-

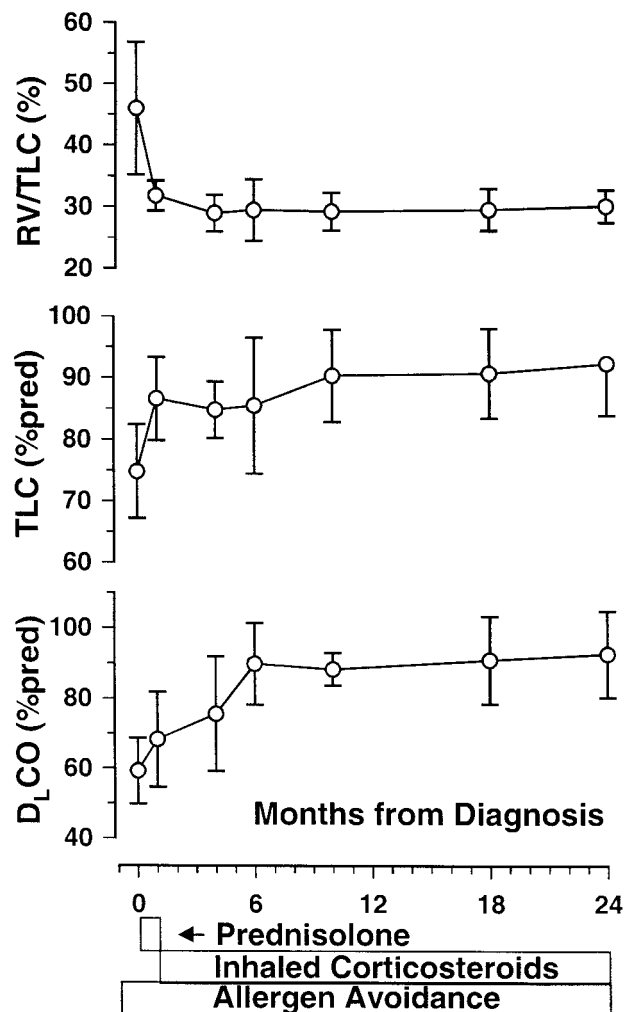


Fig 2. Mean (standard error of the mean: 2) of lung function indices during 24 months of treatment. RV/TLC is expressed as percent, TLC and D_LCO/alveolar volume are expressed as percent of predicted. Periods and modes of treatment and allergen avoidance are shown below the horizontal axis.

cipitating antibody levels diminished in 4 of 5 children and disappeared completely in only 2 patients.

The numerous reports of the disorder are mostly related to intensive occupational exposure in bird breeders, in their households, or in families with domestic pigeons. Never before have wild city pigeons been implicated in causing PBL. The fact that all the children were seriously, but reversibly, affected leads us to conclude that in an urban setting, wild pigeons living in the vicinity of houses can create exposure to pigeon antigens sufficient to cause significant lung disease. Obviously, the question arises whether these animals can be a real public health threat. The abundance of pigeons in the inner-cities all around the world seems, in this light, worrisome.

The death of the mother and the simultaneous occurrence of disease in her 5 children described may be attributed to prolonged exposure to high antigen levels. Alternatively, this family may have been abnormally susceptible to developing this immunologic response. Therefore, patients and their father were HLA-typed, but high-risk HLA types^{7,16,18} were

not found. Interestingly, however, patient 1 with the most severe lung disease showed expression of HLA B7, and this antigen has been implicated to play a role in cryptogenic fibrosing alveolitis.¹⁹ This may have made her more susceptible to the antigens than her siblings. Whether the HLA- typing of the father results in protection against PBL remains unknown, because he probably experienced less antigen exposure than the children.

CONCLUSION

This case report illustrates that: 1) PBL or bird fancier's lung can develop in children who do not fancy these birds at all; 2) diagnosis can be made without biopsies; 3) occurrence of the disease is not necessarily associated with the reported HLA genotypes reported in the literature; 4) good recovery can be observed in children after antigen avoidance in combination with inhaled corticosteroids when complete allergen elimination is not feasible; and 5) normalization of chest radiograph and lung function takes considerably longer than clinical improvement and diffusion capacity can demonstrate a steady recovery during at least 24 months. We suggest that atypical outdoor antigens be considered in all children with nonresolving chest disease or steroid-resistant asthma.

ACKNOWLEDGMENT

We thank Professor Dr C. Hilvering for his valuable contribution to this article.

REFERENCES

1. Reed CE, Sosman A, Barbee RA. Pigeon-breeder's lung: a newly observed interstitial pulmonary disease. *JAMA*. 1965;193:261-265
2. Diseases of altered immunologic activity. In: Fraser RS, Paré JAP, Fraser RG, Paré PD, eds. *Synopsis of Diseases of the Chest*. Philadelphia, PA: WB Saunders; 1994:392-444
3. Zacharisen MC, Fink JN. Hypersensitivity pneumonitis. In: Bireman

- CW, Pearlman DS, Shapiro GG, Busse WW, eds. *Allergy, Asthma, and Immunology From Infancy to Adulthood*. Philadelphia, PA: WB Saunders; 1996:559-566
4. Vergesslich KA, Gotz M, Kraft D. Bird breeder's lung with conversion due to fatal alveolitis. *Dtsch Med Wochenschr*. 1983;108:1238-1242
5. Wolf SJ, Stillerman A, Weinburger M, Smith W. Chronic interstitial pneumonitis in a 3-year-old child with hypersensitivity to dove antigens. *Pediatrics*. 1987;19:1027-1029
6. Balasubramaniam SK, O'Connell EJ, Yunginger JW, McDougall JC, Sachs MI. Hypersensitivity pneumonitis due to dove antigens in an adolescent. *Clin Pediatr*. 1987;26:174-176
7. Schatz M, Patterson R, Fink J, et al. Pigeon breeders disease. III. A study of a family exposed to doves. *Clin Exp Immunol*. 1976;24:33-41
8. Yee WFH, Castile RG, Cooper A. Diagnosing bird fancier's disease in children. *Pediatrics*. 1990;85:848-852
9. Fan LL, Kozinetz CA, Deterding RR, Brugman SM. Evaluation of a diagnostic approach to pediatric interstitial lung disease. *Pediatrics*. 1998;101:82-85
10. Raghu G. Interstitial lung disease: a diagnostic approach. Are CT scan and lung biopsy indicated in every patient? *Am J Respir Crit Care Med*. 1995;151:909-914
11. Reynaud C, Slosman DO, Polla BS. Precipitins in bird breeder's disease: how useful are they? *Eur Respir J*. 1990;3:1155-1161
12. Toubas D, Prevost A, Deschamps F, Pinon JM. Les alveolites allergiques extrenseques d'origine professionnelle. *La Presse Medicale*. 1995;24:1391-1396
13. Allen DH, Williams GV, Woolcock AJ. Bird breeder's hypersensitivity pneumonitis: progress studies of lung function after cessation of exposure to the provoking antigen. *Am Rev Respir Dis*. 1976;114:555-566
14. Grammer LC, Roberts M, Lerner C, Patterson R. Clinical and serologic follow-up of four children and five adults with bird-fancier's lung. *J Allergy Clin Immunol*. 1990;85:655-660
15. Krasnich J, Patterson R, Stillwell BC, Basaran MG, Walker LH, Kishore R. Potentially fatal hypersensitivity pneumonitis in a child. *Clin Pediatr (Phila)*. 1995;34:388-391
16. Sennekamp J, Rittner C, Vogel F, Tauberecht I. Distribution of the HLA antigens in patients with pigeon breeder's lung. *Schweiz Med Wochenschr*. 1978;108:315-317
17. Carlsen KH, Leegaard J, Lund OD, Skjaervik H. Allergic alveolitis in a 12-year-old boy: treatment with budesonide nebulizing solutions. *Pediatr Pulmonol*. 1992;12:257-259
18. Berrill WT, van Rood JJ. HLA-DW6 and avian hypersensitivity. *Lancet*. 1977;2:248
19. Turton CWG, Morris LM, Lawler SD, Turner-Warwick M. HLA in cryptogenic fibrosing alveolitis. *Lancet*. 1978;1:507-508

A Family With Extrinsic Allergic Alveolitis Caused by Wild City Pigeons: A Case Report

Gideon J. du Marchie Sarvaas, Peter J. F. M. Merkus and Johan C. de Jongste
Pediatrics 2000;105;62-
DOI: 10.1542/peds.105.5.e62

This information is current as of December 4, 2006

Updated Information & Services	including high-resolution figures, can be found at: http://www.pediatrics.org/cgi/content/full/105/5/e62
References	This article cites 12 articles, 2 of which you can access for free at: http://www.pediatrics.org/cgi/content/full/105/5/e62#BIBL
Subspecialty Collections	This article, along with others on similar topics, appears in the following collection(s): Allergy & Dermatology http://www.pediatrics.org/cgi/collection/allergy_and_dermatology
Permissions & Licensing	Information about reproducing this article in parts (figures, tables) or in its entirety can be found online at: http://www.pediatrics.org/misc/Permissions.shtml
Reprints	Information about ordering reprints can be found online: http://www.pediatrics.org/misc/reprints.shtml

American Academy of Pediatrics

DEDICATED TO THE HEALTH OF ALL CHILDREN™

