



The APO*E3-Leiden mouse as an animal model for basal laminar deposit

Mike Kliffen, Esther Lutgens, Mat J A P Daemen, Ebo D de Muinck, Cornelia M Mooy and Paulus T V M de Jong

Br. J. Ophthalmol. 2000;84;1415-1419
doi:10.1136/bjo.84.12.1415

Updated information and services can be found at:
<http://bjo.bmj.com/cgi/content/full/84/12/1415>

These include:

References

This article cites 29 articles, 16 of which can be accessed free at:
<http://bjo.bmj.com/cgi/content/full/84/12/1415#BIBL>

11 online articles that cite this article can be accessed at:
<http://bjo.bmj.com/cgi/content/full/84/12/1415#otherarticles>

Rapid responses

You can respond to this article at:
<http://bjo.bmj.com/cgi/eletter-submit/84/12/1415>

Email alerting service

Receive free email alerts when new articles cite this article - sign up in the box at the top right corner of the article

Topic collections

Articles on similar topics can be found in the following collections

[Ophthalmology](#) (1574 articles)
[Experimental Medicine](#) (521 articles)

Notes

To order reprints of this article go to:
<http://www.bmjournals.com/cgi/reprintform>

To subscribe to *British Journal of Ophthalmology* go to:
<http://www.bmjournals.com/subscriptions/>

The APO*E3-Leiden mouse as an animal model for basal laminar deposit

Mike Kliffen, Esther Lutgens, Mat J A P Daemen, Ebo D de Muinck, Cornelia M Mooy, Paulus T V M de Jong

Abstract

Aim—To investigate the APO*E3-Leiden mouse as an animal model for age related maculopathy (ARM) related extracellular deposits.

Methods—Eyes were obtained from APO*E3-Leiden transgenic mice on a high fat/cholesterol (HFC) diet (n=12) or on a normal mouse chow (n=6), for 9 months. As controls, eyes were collected from APO-E knockout mice on the same diets. From each mouse one eye was processed for microscopic evaluation and immunohistochemistry with a polyclonal antibody directed against human apo-E. Electron microscopy was also performed.

Results—All 12 eyes of the APO*E3-Leiden mice on an HFC diet contained basal laminar deposit (BLD; class 1 to class 3), whereas two of six APO*E3-Leiden mice on normal chow showed BLD class 1. The ultrastructural aspects of this BLD were comparable with those seen in early BLD in humans, and BLD showed immunoreaction with anti-human-apo-E antibodies. No BLD was found in any of the control mice. Drusen were not detected in any of the mice.

Conclusion—These results indicate that APO*E3-Leiden mice can be used as animal model for the pathogenesis of BLD, and that a HFC diet enhances the accumulation of this deposit. Furthermore, this study supports the previously suggested involvement of dysfunctional apo-E in the accumulation of extracellular deposits in ARM.

(Br J Ophthalmol 2000;84:1415–1419)

The late stages of age related maculopathy (ARM) are called age related macular degeneration (AMD), and are subdivided into dry AMD (geographic atrophy) and wet AMD (neovascular AMD).¹ These late stages are the main cause of blindness in the elderly population in the Western world.^{2,3} Many histopathological changes can be seen in ARM.^{4,5} Among these changes are drusen and basal laminar deposit (BLD), which are both assumed to be important determinants of AMD.^{6–11} Basal laminar deposit and drusen are both extracellular deposits. Basal laminar deposit is located between the cell membrane of the retinal pigment epithelium (RPE) and its basement membrane.^{4,5} Drusen are located between the basement membrane of the RPE and the remainder of Bruch's membrane, or external to a diffuse thickening of the inner aspect of

Bruch's membrane.^{4,5} Unfortunately, the chemical composition and origin of BLD and drusen have been only partly clarified, mainly by immunohistochemical techniques.^{12–15}

Recently, we have demonstrated the presence of apolipoprotein-E (apo-E) in drusen and BLD.¹⁶ Apo-E is a transport molecule for very low density lipoproteins, high density lipoproteins, and chylomicrons, and contains a low density lipoprotein (LDL) receptor binding site to facilitate cellular recognition, internalisation, and degradation of lipoprotein particles.¹⁷ Furthermore, we have found a decreased risk for AMD in people carrying an apo-ε4 allele compared with people homozygous for apo-ε3.¹⁶ These results suggest the involvement of apo-E in AMD.

One of the major problems in studying ARM and its associated deposits is the lack of fresh macular material from human ARM eyes, and the absence of an animal model. Therefore, we investigated whether ARM associated age related deposits were present in APO*E3-Leiden transgenic mice. These mice carry a dysfunctional form of human apo-E3, that was discovered in a family from the Dutch town Leiden. These patients have hyperlipoproteinemia and develop early onset atherosclerosis.¹⁸

Materials and methods

MICE

All procedures complied with the Association for Research in Vision and Ophthalmology statement for the use of animals in ophthalmic and vision research.

Transgenic mice expressing the human APO*E3-Leiden gene (and producing a dysfunctional form of human apo-E3), and APO-E knockout mice were generated as described earlier.^{18,19} For the present study, mice of the F10 generation were used. Before entry into the study, animals were kept on a standard mouse chow (SRM-A, Hope Farms, Woerden, Netherlands). At the mean age of 37 (SD 0.6) weeks, 12 APO*E3-Leiden mice and 12 APO-E knockout mice were put on a high fat/cholesterol (HFC) diet containing 15% cacao butter, 0.5% cholate, 1% cholesterol, 40.5% sucrose, 10% corn starch, 1% corn oil, and 4.7% cellulose (Hope Farms) for 9 months. Six APO*E3-Leiden mice and 12 APO-E knockout mice received standard mouse chow for 9 months.

The mice in this study were primarily used for research on atherosclerosis.²⁰ All mice were housed under standard conditions on the shelf below the top one in a room with normal fluorescent light exposure. After completion of the

Department of Pathology, Erasmus University, Rotterdam, Netherlands
M Kliffen
C M Mooy

Department of Ophthalmology
C M Mooy

Department of Epidemiology and Biostatistics
P T V M de Jong

Department of Cardiology, University of Maastricht, Netherlands
E Lutgens
E D de Muinck

Department of Pathology
M J A P Daemen

Netherlands Ophthalmic Research Institute and Department of Ophthalmology Academic Medical Center, Amsterdam, Netherlands
P T V M de Jong

Correspondence to:
Dr M Kliffen, Department of Pathology, JN1 room 206, Erasmus University, PO Box 1738, 3000 DR Rotterdam, Netherlands
kliffen@path.fgg.eur.nl

Accepted for publication
10 July 2000

diet according to protocol, each mouse was anaesthetised with xylazine (0.0025 ml/g) and ketamine (0.001 ml/g) intraperitoneally, and the arterial tree was perfused with 0.9% NaCl (3 minutes) and 10% phosphate buffered formalin (pH 7.4, 3 minutes), both containing 20% nitroglycerine. Subsequently, both eyes were taken out and fixed overnight in 10% phosphate buffered formalin. One of the eyes (random) of each mouse was used for this study and the central retina was embedded in paraffin for histopathological classification and immunohistochemistry.

HISTOPATHOLOGICAL CLASSIFICATION OF MOUSE CENTRAL RETINA

Paraffin sections (5 µm) were stained with haematoxylin and eosin, the periodic acid Schiff reaction, and Mallory staining. The retinas were histologically classified according to the independent grading of both drusen and BLD. This classification of drusen and BLD has been described earlier in human eyes.⁵⁻²¹ In brief: no BLD (class 0); small solitary patches of BLD (class 1); a thin continuous layer of BLD (class 2); a thick layer of BLD of at least half the height of the RPE cells (class 3). No drusen (class 0); 1-3 drusen (class 1); 4-10 drusen (class 2); many or confluent drusen (class 3).

IMMUNOHISTOCHEMISTRY

Paraffin sections (5 µm) of all retinas were mounted on 3-amino-propyl-tri-oxy-silane (Sigma, St Louis, MO, USA) coated glass slides. After dewaxing and rehydration they were rinsed with water and phosphate buffered saline, and incubated with 5.5 mU/ml pronase E (Sigma, St Louis, MO, USA) for 6 minutes at 37°C. The slides were then placed in a Sequenza Immunostaining Workstation (Life Sciences International, Velthoven, Netherlands), and incubated for 30 minutes with a rabbit polyclonal antibody directed against human apo-E (kindly supplied by L Havekes from the Gaubius Laboratory, Leiden, Netherlands). This antibody does not cross react with mouse apo-E. After washing with phosphate buffered saline, the slides were incubated for 30 minutes with biotinylated secondary antibodies (Multilink, 1:75 dilution, Biogenex, San Ramon, MO, USA). The slides were washed again and incubated for 30 minutes with alkaline phosphatase conjugated streptavidin (Biogenex, San Ramon, MO, USA, dilution 1:50). Finally the slides were rinsed with 0.2 M TRIS-HCl pH 8.0, and stained for 30 minutes with 0.3% new fuchsin/TRIS-HCl pH 8.0 in combination with Naphthol-AS-MX-sulphate (Sigma, St Louis, MO, USA). The sections were counterstained with Mayer's haematoxylin for 15 seconds, rinsed for 10 minutes with water, and covered. In negative controls, the primary antibody was replaced by normal rabbit serum (Dako, Glostrup, Denmark, dilution 1:10).

ELECTRON MICROSCOPY

Electron microscopy was performed on two eyes from each study group (n=8) to compare the ultrastructural aspects of this mouse BLD

with human BLD. The eyes were prepared for electron microscopy as described earlier.²² They were embedded in epoxy resin, after dehydration with a grading series of acetone. Ultrathin sections (70-80 nm thickness) were mounted on uncoated mesh 300 copper grids. After staining for 30 minutes with uranyl acetate and 2 minutes with lead citrate, the sections were examined with a Zeiss EM 902 transmission electron microscope.

Results

HISTOPATHOLOGICAL CLASSIFICATION OF MOUSE CENTRAL RETINA

All 12 eyes of the APO*E3-Leiden mice on a HFC diet for 9 months contained BLD. Five eyes had BLD class 1, six eyes had BLD class 2, and one eye had BLD class 3 (Fig 1A). Of the six APO*E3-Leiden mice fed a normal mouse chow, two eyes contained BLD class 1, three eyes had no BLD (Fig 1B), and one eye could not be investigated properly because of overlapping tissue layers after processing.

None of the APO-E knockout mice (either on HFC or normal diet) contained any BLD (that is, class 0) or any type of drusen (Fig 1C and D). There were no differences between the retinas of APO*E3-Leiden mice and APO-E knockout mice by light microscopy.

None of the eyes had any type of drusen.

IMMUNOHISTOCHEMICAL LOCALISATION OF APOLIPOPROTEIN-E

Human apo-E was immunohistochemically localised in BLD in all eyes of APO*E3-Leiden mice containing BLD (Fig 1E). In APO*E3-Leiden mice a diffuse staining was noted throughout the BLD and over some plasma remnants in blood vessels.

No positive staining with the apo-E antibody in APO-E knockout mice was found.

ELECTRON MICROSCOPY

Ultrastructurally, the major part of BLD (located between the RPE cell membrane and its basement membrane) in these APO*E3-Leiden mice appeared as homogeneous basement membrane-like material (Fig 2), but also minute amounts of fibrous long spacing collagen were present (not shown).

Discussion

We have demonstrated the presence of BLD in all eyes from APO*E3-Leiden mice on a HFC diet for 9 months. Additionally, 33% of eyes from APO*E3-Leiden mice on a normal mouse chow also showed BLD. This mouse BLD showed positive immunoreactivity for human apo-E. Because the human apo-E antibody does not cross react with mouse apo-E, and APO-E knockout mice did not show positive immunoreactivity at all, it is reasonable to assume that the immunoreactivity of BLD in APO*E3-Leiden mice was solely due to the presence of human apo-E.

Various ratios between the individual components of human BLD have been described.^{4 22 23} The ultrastructural aspects of the mouse BLD we have found in this study are comparable with early BLD in humans.²⁴

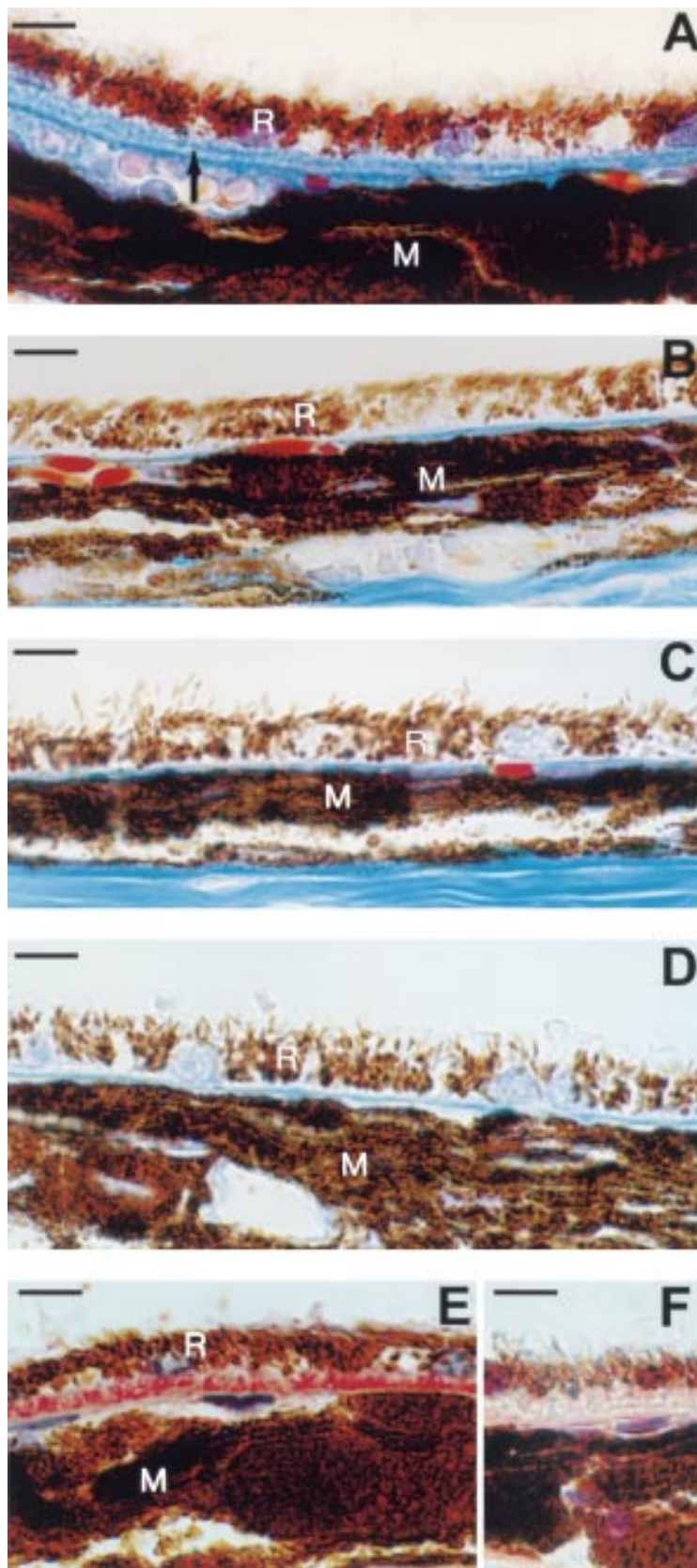


Figure 1 Light microscopic images of (A) a continuous layer (class 2) of basal laminar deposit (arrow), between the retinal pigment epithelium (R) and Bruch's membrane, in the central retina of an APO*E3-Leiden mouse on a high fat/cholesterol (HFC) diet. (B) the central retina from an APO*E3-Leiden mouse on normal chow, without basal laminar deposit (BLD class 0). Note the thin Bruch's membrane between the RPE (R) and the choroidal melanin (M). (C, D) The central retinas of APO-E knockout mice (without BLD) on a (C) normal, and (D) HFC diet, respectively. (E, F) a continuous layer (class 2) of basal laminar deposit, between the RPE and Bruch's membrane, in the central retina of an APO*E3-Leiden mouse on an HFC diet. (E) Stained with an anti-human apo-e antibody (BLD stains red). (F) Negative control. Scale bar indicates 10 μ m.

Vesicular deposits such as those described in diffuse thickening of Bruch's membrane (sometimes referred to as basal laminar deposit) were not seen in this BLD.⁴

It has been reported recently that wild type C57BL/6 mice on an HFC diet do not develop light microscopically detectable amounts of extracellular deposits, although some diffuse thickening of Bruch's membrane was demonstrated with electron microscopy.²⁵ The eyes used in this study were obtained from mice that were used in an atherosclerosis related research project. The perfusion fixation technique (based on formaldehyde) that was used in this study resulted in optimal eye tissue preservation for (immuno)histochemical purposes. However, this technique is not optimal for electron microscopy, and could have created some artefacts. Therefore, we only used electron microscopy for the location and ultrastructure of relatively large amounts of BLD, and not for possible minute changes not detectable by light microscopy (for example, in Bruch's membrane). Further studies especially designed for electron microscopy need to be done in order to elucidate the changes in RPE and Bruch's membrane in these mice.

Recently, we have demonstrated apo-E in BLD and drusen in human maculas, and we have found a decreased risk for AMD in people carrying an apo- ϵ 4 allele compared with people homozygous for apo- ϵ 3.¹⁶ Most animals, including mice, carry only one allele of apo-E that is E4-like.²⁶ This allele is much more efficient in its function (for example, in its receptor binding properties) than apo-E3.²⁷ It is thought that this is one of the reasons that normal mice are very resistant to the development of atherosclerosis.²⁸ It has been demonstrated previously that APO*E3-Leiden and APO-E knockout mice on an HFC diet develop severe atherosclerosis,²⁹ with many features that are characteristic of human atherosclerotic plaques.²⁰ Therefore, we have chosen the APO-E knockout mice as a control group instead of normal (apo-E4 carrying) mice, which would not have developed this severe atherosclerosis. APO*E3-Leiden and APO-E knockout mice on normal mouse chow do not develop atherosclerosis. The fact that more BLD was found in this model in atherosclerotic APO*E3-Leiden animals than in non-atherosclerotic APO*E3-Leiden animals supports the association between AMD and atherosclerosis that has been found in human epidemiologic studies.³⁰ On the other hand APO-E knockout mice on an HFC diet do develop atherosclerosis but no BLD. Therefore, it seems likely that BLD in these APO*E3-Leiden mice is related to a dysfunctional apo-e, and that this BLD is attenuated by atherosclerosis/hyperlipidaemia.

Drusen and Bruch's membrane contain various amounts of phospholipids and neuro-lipids. These lipids are assumed to cause a diffusion barrier between the choriocapillaris and the RPE, but the mechanism by which these lipids accumulate is unknown.³¹⁻³⁴ Most research points to accumulation of inappropriately metabolised products from the RPE, but

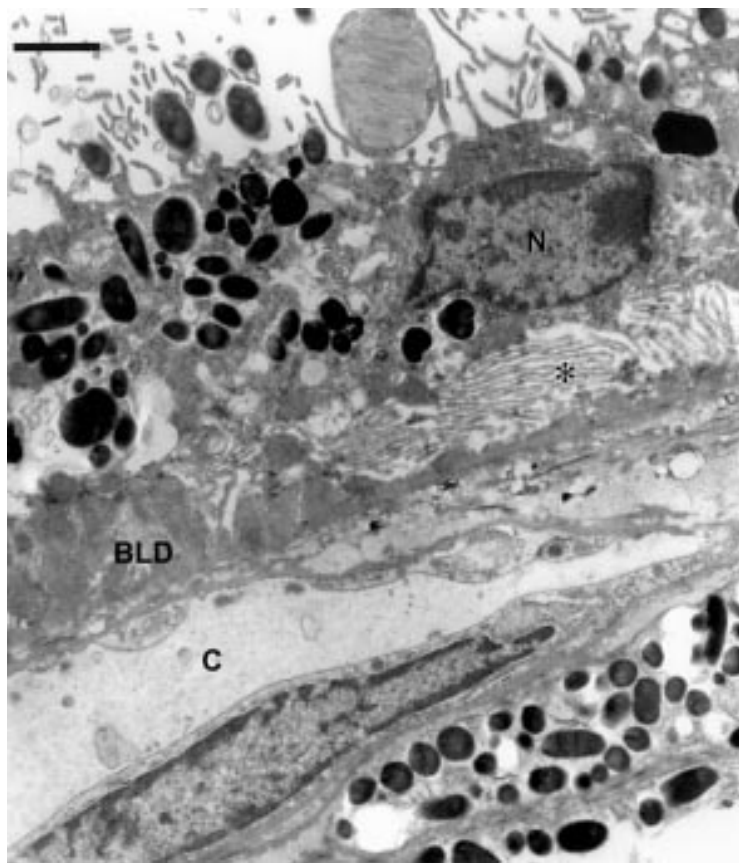


Figure 2 Electron micrograph of basal laminar deposit (BLD) class 2, between the cell membrane of the retinal pigment epithelium (RPE) and the basement membrane of the RPE, in a central retina from an APO*E3-Leiden mouse on a high fat/cholesterol diet. Furthermore, there is an increase and elongation of the basal infoldings of the RPE (*). Uranyl acetate/lead citrate staining. Scale bar indicates 1.1 μm . N = nucleus of RPE; C = choriocapillaris.

also serum derived origin should be considered. Since APO*E3-Leiden has a lower affinity for the LDL receptor, and causes a higher plasma level of apo-E,³⁵ APO*E3-Leiden in BLD could be derived from the choriocapillaris. On the other hand it could be hypothesised that apo-E plays a part in the transport of retinal lipids, which have a high turnover, especially in the photoreceptors. A dysfunctional APO*E3-Leiden could alter the lipid transport system, and cause accumulation of BLD. Degeneration of photoreceptors is a main event in the end stages of ARM. Therefore, the presence of apo-E in BLD could be due to the known involvement of apo-E in the repair of damaged neural tissue.³⁶ Recently, Schneeberger *et al* demonstrated the presence of apo-E in the subretinal space in several forms of exudative retinal detachments, which could support this hypothesis.³⁷ Furthermore, apo-E also accumulates in extracellular deposits in Alzheimer's disease, another neurodegenerative disease.^{38, 39} Another explanation for the presence of apo-E in BLD could be the fact that apo-E is easily bound to glycosaminoglycans, molecules that are known to be present in BLD.^{12, 13, 40}

One of the major problems in studying ARM is the lack of fresh human tissue necessary for most of the biochemical techniques. Furthermore, the macular area in the eye consists of

only a small amount of tissue. A piece of macular tissue of one eye (about 0.1 cm^3) contains about 2 mg total protein. Highly specialised techniques—for example, two dimensional polyacrylamide gel electrophoresis and two dimensional electrophoresis on cellulose acetate membranes, have to be used to cope with these small amounts of human eye tissue.^{11, 13} Therefore, the APO*E3-Leiden mouse model could prove to be helpful for further investigation (on the origin) of BLD. It also provides an opportunity to collect BLD within a few minutes post mortem, which is necessary for many biochemical techniques, but almost impossible from a human source. Additionally, this animal model could be used, despite the lack of a real macula, in intervention studies in order to prevent the accumulation of BLD, which is histologically an important feature associated with the development of ARM.

In conclusion our results indicate that APO*E3-Leiden mice can be used as an animal model for the pathogenesis of BLD, and that an HFC diet enhances the accumulation of this deposit. Furthermore, this study supports the previously suggested involvement of dysfunctional apo-E in the accumulation of extracellular deposits in ARM.

- Bird AC, Bressler NM, Bressler SB, *et al*. An international classification and grading system for age-related maculopathy and age-related macular degeneration. *Surv Ophthalmol* 1995;**39**:367–74.
- Klein R, Klein BEK, Linton KLP. Prevalence of age-related maculopathy. The Beaver Dam eye study. *Ophthalmology* 1992;**99**:933–43.
- Klaver CCW, Wolfs RCW, Vingerling JR, *et al*. Age-specific prevalence and causes of blindness and visual impairment in an older population. *Arch Ophthalmol* 1998;**116**:653–8.
- Green WR, Enger C. Age-related macular degeneration histopathologic studies. The 1992 Lorenz E. Zimmerman Lecture. *Ophthalmology* 1993;**100**:1519–35.
- Kliffen M, van der Schaft TL, Mooy CM, *et al*. Morphologic changes in age-related maculopathy. *Microsc Res Tech* 1997;**36**:106–22.
- Bird AC. Bruch's membrane change with age. *Br J Ophthalmol* 1992;**76**:166–8.
- Pauleikhoff D, Barondes MJ, Minassian D, *et al*. Drusen as risk factors in age-related macular disease. *Am J Ophthalmol* 1990;**109**:38–43.
- Green WR, McDonnell PJ, Yeo JH. Pathologic features of senile macular degeneration. *Ophthalmology* 1985;**92**:615–27.
- Sarks SH. Ageing and degeneration in the macular region: a clinico-pathological study. *Br J Ophthalmol* 1976;**60**:324–41.
- Sheraidah G, Steinmetz R, Maguire J, *et al*. Correlation between lipids extracted from Bruch's membrane and age. *Ophthalmology* 1993;**100**:47–51.
- Kliffen M, de Jong PTVM, Luider TM. Protein analysis of human maculae in relation to age-related maculopathy. *Lab Invest* 1995;**73**:267–72.
- Kliffen M, Mooy CM, Luider TM, *et al*. Analysis of carbohydrate structures in basal laminar deposit in aging human maculae. *Invest Ophthalmol Vis Sci* 1994;**35**:2901–5.
- Kliffen M, Mooy CM, Luider TM, *et al*. Identification of glycosaminoglycans in age-related macular deposits. *Arch Ophthalmol* 1996;**114**:1009–14.
- Mullins RF, Russell SR, Anderson DH, *et al*. Drusen associated with aging and age-related macular degeneration contain proteins common to extracellular deposits associated with atherosclerosis, elastosis, amyloidosis, and dense deposit. *FASEB J* 2000;**14**:835–46.
- Mullins R, Johnson LV, Anderson DH, *et al*. Characterization of drusen-associated glycoconjugates. *Ophthalmology* 1997;**104**:288–94.
- Klaver CC, Kliffen M, van Duijn CM, *et al*. Genetic association of apolipoprotein E with age-related macular degeneration. *Am J Hum Genet* 1998;**63**:200–206.
- Mahley RW. Apolipoprotein E: cholesterol transport protein with expanding role in cell biology. *Science* 1988;**240**:622–30.
- Van den Maagdenberg AM, Hofker MH, Krimpenfort PJ, *et al*. Transgenic mice carrying the apolipoprotein E3-Leiden gene exhibit hyperlipoproteinemia. *J Biol Chem* 1993;**268**:10540–5.
- Van Ree JH, van den Broek WJ, van der Zee A, *et al*. Inactivation of Apo-e and Apo-c1 by two consecutive rounds of

- gene targeting: effects on mRNA expression levels of gene cluster members. *Hum Mol Genet* 1995;4:1403-9.
- 20 Lutgens E, Daemen MJAP, Kockx M, *et al.* Atherosclerosis in APO*E3-Leiden transgenic mice: from proliferative to atheromatous stage. *Circulation* 1999;99:276-83.
 - 21 Van der Schaft TL, de Bruijn WC, Mooy CM, *et al.* Histologic features of the early stages of age-related macular degeneration. A statistical analysis. *Ophthalmology* 1992;99:278-86.
 - 22 Van der Schaft TL, de Bruijn WC, Mooy CM, *et al.* Is basal laminar deposit unique for age-related macular degeneration? *Arch Ophthalmol* 1991;109:420-5.
 - 23 Löffler KU, Lee WR. Basal linear deposit in the human macula. *Graefes Arch Clin Exp Ophthalmol* 1986;224:493-501.
 - 24 Van der Schaft TL, de Bruijn WC, Mooy CM, *et al.* Basal laminar deposit in the aging peripheral human retina. *Graefes Arch Clin Exp Ophthalmol* 1993;231:470-5.
 - 25 Miceli MV, Newsome DA, Tate DJ, *et al.* Pathologic changes in the retinal pigment epithelium and Bruch's membrane of fat-fed atherogenic mice. *Curr Eye Res* 2000;20:8-16.
 - 26 Chan L, Li W-H. Apolipoprotein variation among different species. *Curr Opin Lipidol* 1991;2:96-103.
 - 27 Wilson C, Wardell MR, Weisgraber KH, *et al.* Three-dimensional structure of the LDL receptor-binding domain of human apolipoprotein E. *Science* 1991;252:1817-22.
 - 28 Breslow J. Mouse models of atherosclerosis. *Science* 1996;272:685-8.
 - 29 Van Vlijmen BJ, van den Maagdenberg AM, Gijbels MJ, *et al.* Diet-induced hyperlipoproteinemia and atherosclerosis in apolipoprotein E3-Leiden transgenic mice. *J Clin Invest* 1994;93:1403-10.
 - 30 Vingerling JR, Dielemans I, Bots ML, *et al.* Age-related macular degeneration is associated with atherosclerosis. The Rotterdam study. *Am J Epidemiol* 1995;142:404-9.
 - 31 Pauleikhoff D, Zuels S, Sheraidah GS, *et al.* Correlation between biochemical composition and fluorescein binding of deposits in Bruch's membrane. *Ophthalmology* 1992;99:1548-53.
 - 32 Holz FG, Sheraidah G, Pauleikhoff D, *et al.* Analysis of lipid deposits extracted from human macular and peripheral Bruch's membrane. *Arch Ophthalmol* 1994;112:402-6.
 - 33 Starita C, Hussain AA, Marshall J. Decreasing hydraulic conductivity of Bruch's membrane: relevance to photoreceptor survival and lipofuscinoses. *Am J Med Genet* 1995;57:235-7.
 - 34 Moore DJ, Hussain AA, Marshall J. Age-related variation in the hydraulic conductivity of Bruch's membrane. *Invest Ophthalmol Vis Sci* 1995;36:1290-7.
 - 35 Havekes L, de Wit E, Gevers Leuven J, *et al.* Apolipoprotein E*3-Leiden. A new variant of human apolipoprotein E associated with familial type III hyperlipoproteinemia. *Hum Genet* 1986;73:157-63.
 - 36 Boyles JK, Zoellner CD, Anderson LJ, *et al.* A role for apolipoprotein E, apolipoprotein A-I, and low density lipoprotein receptors in cholesterol transport during regeneration and remyelination of the rat sciatic nerve. *J Clin Invest* 1989;83:1015-31.
 - 37 Schneeberger SA, Iwahashi CK, Hjelmeland LM, *et al.* Apolipoprotein E in the subretinal fluid of rhegmatogenous and exudative retinal detachments. *Retina* 1997;17:38-43.
 - 38 Strittmacher WJ, Saunders AM, Schmedel DE, *et al.* Apolipoprotein E: high avidity binding to b-amyloid and increased frequency of type 4 allele in late-onset familial Alzheimers disease. *Proc Natl Acad Sci USA* 1993;90:1977-81.
 - 39 Strittmacher WJ, Roses AD. Apolipoprotein E and Alzheimer disease. *Proc Natl Acad Sci USA* 1995;92:4725-7.
 - 40 Van der Schaft TL, Mooy CM, de Bruijn WC, *et al.* Immunohistochemical light and electron microscopy of basal laminar deposit. *Graefes Arch Clin Exp Ophthalmol* 1994;232:40-6.

Video Report (www.bjophthalmol.com)

Capsule staining and mature cataracts: a comparison of indocyanine green and trypan blue dyes. *D F Chang*